

SCIENTIFIC REPORT

Pseudo-endophthalmitis after intravitreal injection of triamcinolone

F K P Sutter, M C Gillies

Br J Ophthalmol 2003;**87**:972-974

Aims: To describe an unusual endophthalmitis-like reaction after an intravitreal injection of triamcinolone acetonide in four patients.

Methods: Retrospective case series.

Results: Four patients are reported with an endophthalmitis-like reaction following an intravitreal injection of triamcinolone acetonide. There was a dense vitreous haze with severe reduction of fundus view in all cases. One case was treated as an infectious endophthalmitis but the vitreous tap showed no evidence of an endophthalmitis and no bacterial or fungal growth in culture. In all four cases, the vitreous haze cleared without specific treatment. The anterior chamber remained quiet in all cases but one, which was examined 30 minutes after the injection, and there was no periorbital inflammation or pain.

Conclusion: Pseudo-endophthalmitis after an intravitreal injection of triamcinolone acetonide seems to be a distinct clinical entity that may resolve without specific treatment.

Intravitreal triamcinolone acetonide is an increasingly popular treatment for inflammatory eye disease, neovascular age related degeneration, and macular oedema, though most reports of its efficacy are based on uncontrolled studies and case reports.¹⁻⁵ The results of controlled trials are not yet available. We have found that the treatment has a significant but manageable adverse event profile.⁶

Triamcinolone acetonide, a crystalline, milky liquid, remains in the vitreous for a few days after injection as a discrete white cloud with little or no reaction in the surrounding vitreous (Fig 1A). Prominent floaters are therefore commonly encountered after treatment but these usually subside within a few days as the material drops out of the visual axis. We report here four cases with an endophthalmitis-like clinical picture after an intravitreal triamcinolone injection.

CASE REPORTS

Written informed consent was obtained in all cases. Triamcinolone acetonide, 0.1 ml (4 mg), (Kenacort A-40, Bristol-Myers Squibb Pharmaceuticals, Australia) was injected intravitreally through the pars plana using a 30 gauge needle. The injection was performed in a minor procedure room with topical and subconjunctival anaesthesia under aseptic conditions with the surgeon using sterile gloves. The eye received one drop of half strength betadine before both the subconjunctival and intravitreal injections. Chloramphenicol ointment (10 mg/g) was instilled at the conclusion of the procedure.

Case 1

A 70 year old male patient presented with a subfoveal choroidal neovascular membrane due to age related macular degeneration in his left eye. Best corrected visual acuity was 6/24-1. He had lost central vision in his right eye as a result of choroidal neovascularisation 2 years before. The episode occurred before the availability of photodynamic therapy. An intravitreal injection was offered to the patient based on encouraging uncontrolled reports of its efficacy for choroidal neovascularisation in humans and animal models.^{7,8}

One week later, the visual acuity had dropped to hand movement and a marked haze of the left vitreous was observed. The patient stated that he had noticed a diffuse haze immediately after the injection which had not cleared. There was no view of the retina but the anterior chamber was quiet (no cells or flare) and the patient reported no pain or tenderness. Postoperative endophthalmitis was suspected and the patient was admitted to Sydney Eye Hospital. A vitreous aspiration biopsy was performed followed by the injection of vancomycin 1 mg/0.1 ml and ceftazidime 2.25 mg/0.5 ml. The smears from the centrifuged vitreous aspirate contained vitreous strands with many small triamcinolone crystals and only a few cells (Fig 2). The cultures for bacteria and fungi were negative. The vitreous infiltration cleared very slowly and vision improved to 6/120 after 2 months. In the left macula

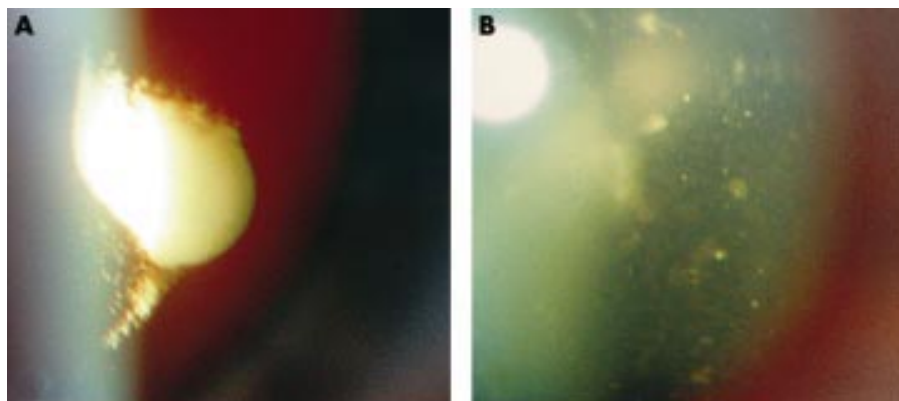


Figure 1 A discrete white cloud of triamcinolone crystals with no or little reaction in the surrounding vitreous 3 days after injection (A). Dense vitreous haze caused by presumed triamcinolone pseudo-endophthalmitis 4 days after injection (case 3) (B).

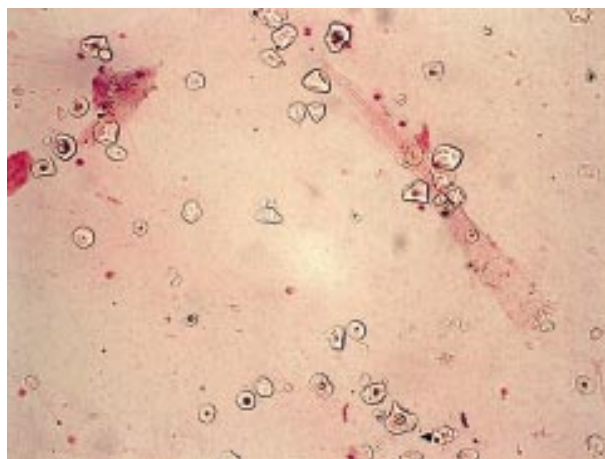


Figure 2 Smear from centrifuged vitreous aspirate of case 1 containing vitreous strands with many small triamcinolone crystals and only a few cells. (Haematoxylin and eosin, $\times 250$)

there was an area of central atrophy with no evidence of exudation or scarring. Intraocular pressure remained within normal limits at all times.

Case 2

An 87 year old female patient presented with visual acuity 6/18 in both eyes. Ophthalmological examination and fundus fluorescein angiography showed geographic atrophy in the right eye and a minimally classic choroidal neovascular membrane in the left eye. Triamcinolone acetonide 4 mg was injected intravitreally as described above. One week later visual acuity had dropped to 2/60 and there was a diffuse vitreous haze obscuring any view of the fundus. There were no inflammatory signs in the anterior chamber and the patient did not report any discomfort. The intraocular pressure was 25 mm Hg. No biopsy was taken, no specific treatment was started, and the vitreous cleared gradually. After 10 weeks the visual acuity had increased to 6/60 and intraocular pressures returned to normal. Three months after the injection, the vitreous was entirely clear and the visual acuity had increased to 6/45. The decline in visual acuity from the pre-injection level was felt to be consistent with the subretinal neovascularisation.

Case 3

A 77 year old male patient presented to his ophthalmologist with exudative age related macular degeneration of the right eye. He was referred to a retinal specialist but lost central vision of his right eye completely within 3 weeks, because of an unusually aggressive process. One year later he presented with visual complaints in his left eye. Best corrected visual acuity was counting fingers in the right eye and 6/9 in the left. Fundus fluorescein angiography showed a small classic choroidal neovascular membrane within 50 μm of the centre of the left macula. Because of the extremely aggressive course of the disease in the fellow eye, a combined treatment with intravitreal triamcinolone and photodynamic therapy was proposed to the patient. Triamcinolone acetonide 4 mg was injected intravitreally as described above and photodynamic therapy was planned for 2 days later. Two days after the injection, visual acuity had dropped to counting fingers at 1 metre. There was some residual subconjunctival haemorrhage temporally but no injection in the nasal aspect of the conjunctiva. The anterior chamber was completely quiet, there was no hypopyon, no cells and no flare. The lens showed moderate cataract formation with some cortical opacities superotemporally as noted before the injection. In the vitreous there was a

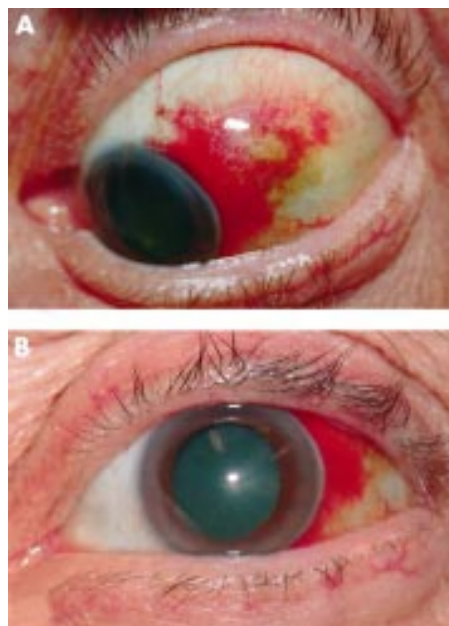


Figure 3 Small brownish-yellow spot at the site of injection superior-temporally (A). The eye is otherwise quiet (B).

dense haze (Fig 1B) completely obscuring the view of the fundus. At the site of injection there was a small brownish-yellow spot but the area was otherwise quiet (Fig 3). The patient denied any pain or discomfort.

Pseudo-endophthalmitis was suspected and treatment was withheld in favour of observation. Four days later the visual acuity had increased to 6/15–2 and the vitreous infiltration had cleared markedly allowing some visualisation of the fundus. Another week later, visual acuity was 6/15+1 and photodynamic therapy was performed with a good view of the macula.

Case 4

A 55 year old female patient was treated with intravitreal triamcinolone for diabetic macular oedema as part of an ongoing randomised controlled trial. Best corrected visual acuity was 6/30 in the left eye. The intravitreal injection was uneventful, but the patient complained of ocular discomfort half an hour later. The slit lamp examination showed punctate keratopathy and 2+ cells (or particles) in the anterior chamber. In the vitreous there was a diffuse haze as well as 4+ cells or particles. The visual acuity had dropped to counting fingers at 25 cm and there was a very poor view of the fundus.

Two days later the anterior chamber had cleared but there was still a diffuse haze and the visual acuity was only counting fingers at 2 metres. Two weeks after treatment the vitreous haze had cleared and the visual acuity was back to 6/30.

DISCUSSION

These four cases of an acute episode of marked anterior vitreous haze after an injection of triamcinolone share several common features. In all cases, impaired vision was noted immediately or very soon after the injection. Examination of the anterior vitreous revealed heavy particulate infiltration precluding a view of the retina. No patient reported any pain or swelling, and the anterior chamber remained quiet in all cases but one where the examination was performed immediately after the procedure. The vitreous haze cleared gradually over the ensuing weeks, without specific treatment in the second, third, and fourth cases, and without any other apparent adverse events.

At this stage, the cause of this acute vitreous haze remains uncertain. The clinical picture has some features of an infectious endophthalmitis, but the lack of pain, swelling, and anterior segment reaction, coupled with the spontaneous resolution without antibiotic therapy are not consistent with an infectious process. Possibly the true course of the infection was masked by the intravitreal steroid, but this seems unlikely without antibiotic cover. The one case that was tapped was culture negative. An acute reaction to the vehicle of the drug is theoretically possible (the vehicle contains 6.9 mg sodium chloride for isotonicity, 15 mg benzyl alcohol as a preservative, 7.5 mg carmellose sodium, and 0.4 mg polysorbate 80), but judging from the analysis of the vitreous tap in case 1, a true inflammatory reaction (immune or infectious) seems unlikely. Furthermore, triamcinolone was originally chosen as a candidate steroid for intraocular injection because the vehicle seemed to be well tolerated by rabbit eyes.^{9 10}

It is perhaps pertinent that in all four cases the triamcinolone seemed to be dispersed throughout the vitreous rather than forming the discrete mass that is usually observed after the injection. We found that jamming of the triamcinolone in the needle upon injection was not uncommon before we switched from a 30 gauge to a 27 gauge needle. It is possible that there was partial jamming of the crystalline steroid in the barrel of the needle as the injection was given, resulting in spraying of the drug into the vitreous at a high velocity causing in a type of suspension. In that case the observed particulate matter might be particles of triamcinolone. This possibility is consistent with the immediacy of the loss of vision after the injection which was reported by all four patients, and which one would not expect with an inflammatory reaction which would begin 2 or 3 days later. Consistent with this possibility also are the findings from the vitreous tap performed on the first patient where there were a large number of small triamcinolone crystals but very few inflammatory cells in the smear (Fig 2).

The true incidence of acute vitreous haze after an intravitreal injection of triamcinolone is unknown. The four cases described are drawn from a sample of around 600 injections at the Sydney Eye Hospital and in the private practice of one of the authors over the past 8 years. Remarkably, none of first three patients described were sufficiently concerned about their problem to contact their doctor before their scheduled post-injection check and the fourth patient was examined only because of post-injection irritation of the eye, so it is possible that less severe manifestations of the phenomenon have gone undetected. In our randomised clinical trial of intravitreal triamcinolone for exudative age related macular degeneration, none of the 75 patients receiving the injection exhibited acute vitreous haze at the formal 1 week post-injection study examination.⁶

It is important to note that this paper neither recommends nor supports the use of intravitreal triamcinolone for any condition until adequate data are available from properly designed clinical studies. Investigators performing these studies need to be aware, however, that acute vitreous haze is an uncommon event after an intravitreal injection of triamcinolone, that it does not appear to be associated with other serious adverse events, and that it may resolve spontaneously without treatment. Naturally, one has to bear in mind that the clinical picture and course of a true infectious endophthalmitis may be altered in the presence of steroids in the vitreous and that any deviation from the relatively benign course exhibited by the four cases presented would need to be treated aggressively as an infectious endophthalmitis.

Authors' affiliations

F K P Sutter, M C Gillies, Save Sight Institute, Department of Clinical Ophthalmology and Eye Health, The University of Sydney, Sydney, Australia

Correspondence to: Dr F Sutter, Universitäts Spital Zürich, Augenklinik, Frauenklinikstrasse 24, CH-8091, Zürich, Switzerland; sutter-adler@gmx.ch

Accepted for publication 20 December 2002

REFERENCES

- 1 **Antcliff RJ**, Spalton DJ, Stanford MR, *et al*. Intravitreal triamcinolone for uveitic cystoid macular edema: an optical coherence tomography study. *Ophthalmology* 2001;**108**:765-72.
- 2 **Greenberg PB**, Martidis A, Rogers AH *et al*. Intravitreal triamcinolone acetonide for macular oedema due to central retinal vein occlusion. *Br J Ophthalmol* 2002;**86**:247-8.
- 3 **Jonas JB**, Sofker A. Intraocular injection of crystalline cortisone as adjunctive treatment of diabetic macular edema. *Am J Ophthalmol* 2001;**132**:425-7.
- 4 **Martidis A**, Duker JS, Puliafito CA. Intravitreal triamcinolone for refractory cystoid macular edema secondary to birdshot retinochoroidopathy. *Arch Ophthalmol* 2001;**119**:1380-3.
- 5 **Young S**, Larkin G, Branley M, *et al*. Safety and efficacy of intravitreal triamcinolone for cystoid macular oedema in uveitis. *Clin Exp Ophthalmol* 2001;**29**:2-6.
- 6 **Gillies MC**, Simpson JM, Luo W, *et al*. A randomized clinical trial of a single dose of intravitreal triamcinolone for neovascular age-related macular degeneration. One year results. *Arch Ophthalmol* 2003;**121**:667-73.
- 7 **Penfold PL**, Gyory JF, Hunyor AB, *et al*. Exudative macular degeneration and intravitreal triamcinolone. A pilot study. *Aust N Z J Ophthalmol* 1995;**23**:293-8.
- 8 **Ishibashi T**, Miki K, Sorgente N *et al*. Effects of intravitreal administration of steroids on experimental subretinal neovascularization in the subhuman primate. *Arch Ophthalmol* 1985;**103**:708-11.
- 9 **Hida T**, Chandler D, Arena JE *et al*. Experimental and clinical observations of the intraocular toxicity of commercial corticosteroid preparations. *Am J Ophthalmol* 1986;**101**:190-5.
- 10 **McCuen B W 2nd**, Bessler M, Tano Y, *et al*. The lack of toxicity of intravitreally administered triamcinolone acetonide. *Am J Ophthalmol* 1981;**91**:785-8.



Pseudo-endophthalmitis after intravitreal injection of triamcinolone

F K P Sutter and M C Gillies

Br J Ophthalmol 2003 87: 972-974

doi: 10.1136/bjo.87.8.972

Updated information and services can be found at:

<http://bjo.bmj.com/content/87/8/972.full.html>

References

These include:

This article cites 10 articles, 4 of which can be accessed free at:

<http://bjo.bmj.com/content/87/8/972.full.html#ref-list-1>

Article cited in:

<http://bjo.bmj.com/content/87/8/972.full.html#related-urls>

Email alerting service

Receive free email alerts when new articles cite this article. Sign up in the box at the top right corner of the online article.

Topic Collections

Articles on similar topics can be found in the following collections

[Choroid](#) (434 articles)
[Eye \(globe\)](#) (538 articles)
[Neurology](#) (1036 articles)

Notes

To request permissions go to:

<http://group.bmj.com/group/rights-licensing/permissions>

To order reprints go to:

<http://journals.bmj.com/cgi/reprintform>

To subscribe to BMJ go to:

<http://group.bmj.com/subscribe/>