

## EXTENDED REPORT

## Retinectomy for treatment of intractable glaucoma: long term results

A M Jousen, P Walter, C P Jonescu-Cuypers, K Koizumi, V Poulaki, K U Bartz-Schmidt, G K Krieglstein, B Kirchhof

*Br J Ophthalmol* 2003;87:1094–1103

**Aim:** To report long term efficacy and complications of retinectomy as an intraocular pressure lowering procedure for intractable glaucoma.

**Methods:** This was a consecutive interventional case series. In 44 consecutive eyes (39 patients, 22 men and 17 women) retinectomy was performed to lower the intraocular pressure (IOP) in patients with uncontrolled IOP (>35 mm Hg for more than 4 months) despite conventional filtering surgery and drug treatment. Pars plana vitrectomy was performed and the peripheral retina was surgically excised to various degrees. The procedure was concluded by an intraocular gas tamponade of 20% C<sub>3</sub>F<sub>8</sub>. Included were patients with neovascular glaucoma (12 eyes), infantile and juvenile glaucoma (three eyes), secondary glaucoma due to aphakia (13 eyes), severe ocular trauma (seven eyes), uveitis (seven eyes), and glaucoma in Ehlers-Danlos syndrome (two).

**Results:** All patients underwent successful surgical retinectomy. All patients were followed for 5 years. Mean postoperative IOP after 4 years was 15.7 (SD 9.4) mm Hg, representing a decrease of IOP by 61% compared to the preoperative level (41.2 (9.4) mm Hg). In 52.3% of eyes long term regulation of IOP could be achieved without complications. Retinectomy was least effective in neovascular glaucoma because of central retinal vein occlusion (CRVO). Eyes with glaucoma secondary to uveitis showed a tendency towards low IOP levels with subsequent phthisis bulbi. The initial visual acuity of all patients was lower than 20/50 (mean 1.8 (0.8) logMAR) in the treated eye. Final visual acuity was 2.3 (0.6) logMAR. 21 out of 44 cases developed retinal complications (retinal detachment or proliferative vitreoretinopathy (PVR)) after surgery, requiring silicone tamponade in 11 eyes (52%) either for persistent low IOP or for PVR. Nine eyes developed phthisis, seven of which were enucleated during the follow up.

**Conclusions:** Long term results after retinectomy demonstrate its efficacy in otherwise intractable glaucoma. Efficacy and safety of retinectomy are dependent on the underlying disease.

See end of article for authors' affiliations

Correspondence to: Bernd Kirchhof, MD, Department of Vitreoretinal Surgery, Center for Ophthalmology, Joseph Stelzmannstrasse 9, 50931 Köln, Germany; jousenA@aol.com

Accepted for publication 9 March 2003

Surgery of glaucoma unresponsive to conventional surgical and medical strategies has been frustrating and disappointing. In general, the surgical options aim either at an increased outflow of aqueous humour or at a reduction of aqueous secretion. There is no consensus as to what is the best or reference treatment. Long term success of conventional filtration procedures for intractable glaucoma is hampered by scarring of the filtering zone.<sup>1</sup>

Inhibition of wound healing through antiproliferative drugs is only partially successful and often complicated by avascular filtering blebs, uncontrolled fluid leakage, and increased risk of infections.<sup>2–5</sup> Cyclodiode treatment is perhaps regarded as the “standard treatment” for many of such cases. However, cyclodestructive treatment has a narrow therapeutic window in many cases. Owing to the immense reparative capacity of the ciliary epithelium, cyclodestructive procedures, to be effective, require to destroy more than 90% of the epithelium, bearing the risk of overtreatment and phthisis.<sup>6</sup> Nevertheless, in a series of 200 eyes reported by Bloom and coworkers, the incidence of phthisis was less than 1%.<sup>7</sup>

Alternatively, “palliative treatment” would be the standard treatment for blind eyes with raised intraocular pressure—with patients being prescribed cycloplegics and steroids for symptoms of pain or inflammation. A small number of patients are offered enucleation. The latter treatments, of course, do not preserve vision. Moreover, even in functionally lost eyes, enucleation is frequently not an acceptable option for the patients, who want to preserve a comfortable and cosmetically acceptable eye. Retinectomy would be particularly attractive alternative to “palliative treatments” if it was shown

to preserve the small residual vision in some patients and also prevent sympathetic ophthalmia.

Retinectomy opens a new posterior outflow path for aqueous to the absorbing choroid.<sup>8,9</sup> A large opening in the retina cannot close by wound healing with the advantage that the pressure lowering effect of a retinectomy should therefore persist. However, the efficacy might be dependent on the origin of the intractable glaucoma. Still, long term efficacy and side effects of the retinectomy remain to be elucidated.

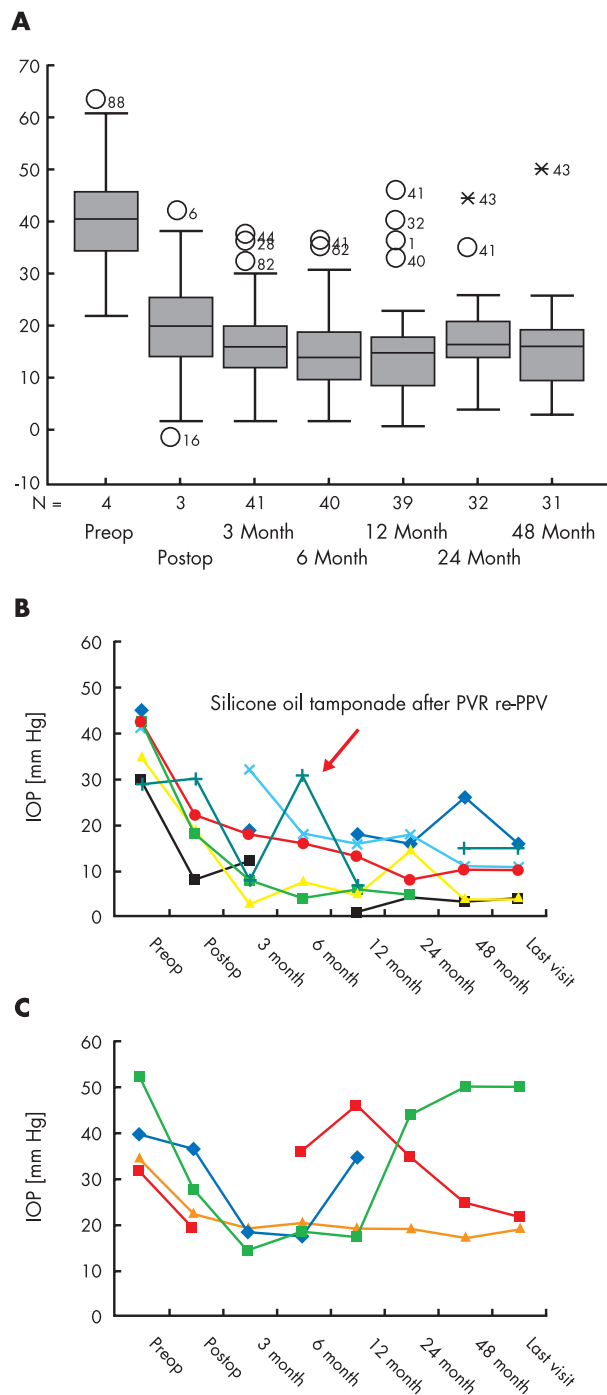
## METHODS

A consecutive interventional case series was performed on patients with intractable glaucoma recruited during 1994–6 at the centre of ophthalmology in Cologne, Germany. All patients were followed up for more than 4 years.

We set up a prospective pilot study on 39 consecutive patients, 22 men and 17 women, in which 44 eyes were treated.

## Study population

Inclusion criteria were glaucoma unresponsive to conventional surgical strategies (filtrating and cyclodestructive procedures), in which retinectomy was performed to lower IOP by re-routing the aqueous humour. All eyes except for two cases were legally blind with a visual acuity of less than 5% (<1.3 log MAR). Retinectomy was performed to lower the intraocular pressure (IOP) in patients with uncontrolled IOP (>35 mm Hg for more than 4 months) despite maximum tolerable therapy and appropriate conventional surgery. The intention of the surgery was to relieve pain by decreasing the



**Figure 1** (A) Intraocular pressure, mean and standard deviation in all patients. Eyes which are outside the 95% and 98% percentile are displayed with their respective numbers (1–44) (circles and stars respectively)—for example, it is seen, that IOP in eye no 32 remains higher from 3 months to 12 months. Apart from these exceptions, there is a significant and persistent pressure lowering effect after retinectomy. (B) Individual IOP development in patients with glaucoma secondary to uveitis. Each line represents a single eye. One of the eyes (dark green line) was enucleated because of phthisis bulbi, two other eyes remained permanently hypotonic with IOP levels below 7 mm Hg. (C) Individual IOP development in patients with neovascular glaucoma after central vein occlusion. Each line represents a single eye. One eye (blue line) was removed from the follow up after 1 year because of painful phthisis.

IOP, to obviate the use of systemic carbonic anhydrase inhibitors, and to preserve the eye without discomfort and ensure cosmetically acceptability. All patients gave their informed

consent to be treated by retinectomy described to them as a new investigational approach. Retinectomy was contrasted with cyclodestructive therapy, enucleation, or evisceration, as is traditionally indicated in these eyes.

### Intervention

General anaesthesia was used in all patients. Thirty minutes before surgery, IOP was lowered to near “normal” values by intravenous administration of 100 ml mannitol<sup>10</sup> to reduce the risk of choroidal effusion from sudden pressure drop at the beginning of the operation (paracentesis).

Retinectomy was done in a modification of a previously reported protocol.<sup>10</sup> Briefly, a standard three port vitrectomy was performed under the operating microscope. The lens, if still present, was removed by endophacoemulsification. Panretinal photocoagulation in eyes with active neovascularisation was applied, except for the area of the retina to be excised.

The superior retinal quadrants, either temporal or nasal, were selected for resection outside the vascular arcade. The area of excision was demarcated by endodiathermy. The retina was aspirated and excised using a vitrectomy probe while the central retina was secured by liquid perfluorocarbon. The retinectomy usually extended 2–4 clock hours. A larger area was chosen in patients with either choroidal atrophy or previous laser scars. The size of the retinectomy was independent of the preoperative IOP in all cases. Retinectomy was applied to the edge of the retinectomy to secure retinal attachment. The procedure was concluded by a fluid-air exchange. The air then was replaced by non-expandable 16% C<sub>3</sub>F<sub>8</sub> gas. All treatments were given in accordance with the guidelines of national legislation and the declaration of Helsinki. After surgery preoperative drugs were discontinued, except in cases of persistent high IOP. If not otherwise indicated, topical cycloplegics and combination antibiotic/steroid preparations were continued as needed for several weeks after surgery.

### Main outcome measures

The main outcome measures of the study are intraocular pressure, visual acuity, and attachment of the remaining retina. The final success rate was determined as eyes with no loss of light perception, normal IOP (>7 and <22 mm Hg), and attached retina over a period of 5 years.

Preoperative evaluation included measurement of visual acuity and IOP using Goldmann applanation tonometry, gonioscopy, anterior and posterior slit lamp biomicroscopy, indirect ophthalmoscopy, and ultrasonography, when required. Visual field testing was performed in patients with visual acuity above 20/200 (1.0 logMAR) allowing for kinetic perimetric testing.

Visual acuity was measured in a decimal system and expressed in logMAR units according to Table 1. For measurement of the visual acuity, patients were examined at 5 metres distance using standardised Snellen charts. Since visual acuity in most of the examined eyes depicted values much below 1.3 logMAR, testing was performed at 1 metre distance and the values were expressed as arbitrary logMAR units for “hand movements, perception of light with or without intact projection.”

Patients were examined daily from postoperative day 1 to day 7, and then biweekly up to 12 month after surgery. Thereafter, follow up was transferred to the referring ophthalmologists and patients were only seen for treatment of complications. Questionnaires were sent out to determine the outcome measurement in patients followed outside the department. Postoperative examinations included IOP measurement, anterior and posterior slit lamp biomicroscopy, indirect ophthalmoscopy, and ultrasonography when required. Regulation of the IOP was considered a level of IOP between 7 and 22 mm Hg.

**Table 1** IOP course depending on diagnosis (number of eyes is shown in parentheses). All values are mean (SD)

Diagnosis	Preop	Postop	3 months	6 months	12 months	24 months	>48 months
All eyes	41 (9.45) (n=44)	21.5 (10.2) (n=36)	16.8 (8.9) (n=41)	15.3 (8.0) (n=40)	15.3 (10.0) (n=39)	17.4 (8.2) (n=32)	15.5 (9.2) (n=31)
Neovascular glaucoma	41 (9.25) (n=12)	21.5 (10.2) (n=11)	18.2 (7.9) (n=11)	17.9 (8.4) (n=11)	19.1 (12.8) (n=10)	21.3 (12.6) (n=8)	20.8 (13.6) (n=8)
PDR	50.5 (7.9) (n=6)	17.2 (6.3) (n=5)	16.6 (5.7) (n=6)	17.2 (6.3) (n=5)	13.8 (4.9) (n=5)	15.3 (6.5) (n=4)	16 (8.5) (n=4)
CVO	39.7 (8.8) (n=4)	27 (7.4) (n=4)	18 (2.6) (n=3)	23.5 (8.4) (n=4)	29.7 (13.2) (n=4)	33 (12.1) (n=3)	31 (16.7) (n=3)
Uveitis	35	8	9	5	3		
Herpes keratitis	46	35	37	12		10 (enucleation)	
Trauma	37.85 (7.1) (n=7)	21.8 (6.8) (n=6)	25 (9.2) (n=7)	18.1 (9.0) (n=7)	19.1 (10.6) (n=7)	19.5 (5.1) (n=6)	16.1 (5.7) (n=6)
Uveitis	37.7 (6.4) (n=7)	19.4 (7.9) (n=5)	14.3 (9.6) (n=7)	15.4 (10.4) (n=5)	9.4 (6.3) (n=7)	11 (6.1) (n=6)	11.5 (8.4) (n=6)
Glaucoma due to aphakia in congenital cataracts	43.1 (10.3) (n=13)	20.4 (3.7) (n=8)	13.6 (7.5) (n=11)	12.7 (6.5) (n=12)	14.1 (9.3) (n=11)	17.6 (5.2) (n=10)	16.5 (8.1) (n=9)
Others	34.6 (10.8) (n=5)	15.4 (9.2) (n=5)	12.8 (6.4) (n=5)	12 (6.4) (n=5)	14.1 (9.3) (n=4)	15.5 (2.1) (n=2)	14.5 (6.4) (n=2)
Juvenile and infantile glaucoma							
Ehlers-Danlos syndrome							

### Subgroup analysis

As potential predictors for a significant change in IOP levels after surgery preoperative, intraoperative, and postoperative observations were considered. As preoperative factors diagnosis, age, sex, IOP, and duration of IOP elevation, visual acuity and, if possible, visual fields were examined as well as previous cyclodestructive or filtering surgery. Intraoperative factors like haemorrhages, postoperative complications such as proliferative vitreoretinopathy (PVR), and re-retinectomy were also taken into consideration.

Patients were subdivided into these groups. The subgroups were then analysed regarding a significant effect on IOP normalisation using  $\chi^2$  test.

### RESULTS

The underlying types of glaucoma were congenital cataract (12 +1 aphakic eyes), uveitis (seven eyes), severe trauma (seven eyes), neovascular glaucoma (12 eyes), congenital and juvenile glaucoma (three eyes), and Ehlers-Danlos syndrome (two eyes).

#### Control of IOP

The mean preoperative IOP was 41 (SD 9.4) mm Hg (n=44). The highest IOP was recorded with neovascular glaucoma ranging from 40 to 63 mm Hg (50.5 (7.9) mm Hg, n=6). Postoperative IOP decreased in all patients by a minimum of one third of the preoperative value within the first postoperative week (n=43; 20.1 (8.2) mm Hg, p<0.05), except for one eye with glaucoma secondary to trauma and one eye with previous uveitis. Early postoperative hypotony, which is known from filtering procedures, was not noted. From 3 months after surgery up to at least 4 years after surgery the mean IOP levels in all eyes ranged from 15.3 (8.0) mm Hg to 16.8 (8.9) mm Hg and did not significantly alter during this time (p<0.05) (Fig 1). However, IOP values were not provided at each time point for all eyes initially included. Thus, the presented overall mean values may suggest a false positive result. In 29% (13 out of 44 cases) of the cases the follow up of at least 48 months was not complete. Detailed information for the reasons for the dropout in these cases is given below.

In order to identify the influence of the underlying diagnosis on the postoperative IOP development, IOP levels were compared with respect to the preoperative diagnosis (Table 1). The preoperative IOP levels did not significantly differ between the different groups. In contrast, the postoperative IOP level, demonstrated a threefold difference between the group with highest and the group with lowest postoperative IOP levels (p<0.005). Postoperative IOP levels were highest in patients with neovascular glaucoma following central retinal vein occlusion (CRVO, n=4), ranging from 18 (2.6) mm Hg 6 months after surgery to 31 (16.8) mm Hg 48 months after surgery. In proliferative diabetic retinopathy associated neovascular glaucoma three eyes (out of six) demonstrated stable postoperative IOP levels of between 16 and 24 mm Hg. Two eyes were lost to phthisis and one eye required extensive surgical revision for PVR and vitreous haemorrhage. In severe ocular trauma (eight eyes) IOP levels decreased during the follow up (n=7; p<0.05), but remained above a mean of 15 mm Hg. However, two patients required silicone oil tamponade for PVR retinal detachment and for ocular hypotony and phthisis.

Eyes with glaucoma secondary to uveitis developed the lowest postoperative IOP levels ranging from 15.4 (10.4) mm Hg 6 months after surgery to 11.5 (8.4) mm Hg at the last follow up visit more than 5 years after surgery.

In all groups there was no significant correlation between the immediate postoperative IOP levels as measured 4–6 days after surgery and the final outcome (p>0.05). Similarly, IOP levels at 3, 6, and 12 months after surgery did not significantly correlate with the final IOP levels which showed a tendency towards lower levels.

**Table 2** Development of visual acuity with respect to diagnosis subgroups

Diagnosis	Preoperative visual acuity: (mean: logMAR)	3 months postoperative visual acuity: (mean: logMAR)	12 months postoperative visual acuity: (mean: logMAR)	24 months postoperative visual acuity: (mean: logMAR)	48–60 months postoperative visual acuity: (mean: logMAR)
Neovascular glaucoma	20/100–LPd 2.0 (0.8) n=12	20/400–LPd 2.2 (0.3) n=12	HM–nLP 2.3 (0.4) n=7	CF–nLP 2.5 (0.5) n=6	CF–nLP 2.6 (0.6) n=6
Trauma	20/200–nLP 2.0 (0.9) n=7	CF–nLP 2.5 (0.5) n=7	HM–nLP 2.6 (0.4) n=7	HM–nLP 2.6 (0.5) n=6	HM–nLP 2.6 (0.5) n=6
Uveitis	20/50–nLP 1.3 (0.8) n=7	20/50–nLP 1.9 (0.8) n=7	20/100–CF 1.3 (0.4) n=5	20/400–LPi 1.9 (0.4) n=5	20/400–LPd 2.2 (0.5) n=5
Glaucoma due to aphakia in congenital cataracts	20/200–nLP 1.6 (0.5) n=13	20/200–nLP 2.1 (0.7) n=11	20/200–nLP 1.7 (0.5) n=13	20/200–nLP 1.8 (0.7) n=11	20/400–nLP 2.2 (0.7) n=10
Others (juvenile and infantile glaucoma, Ehlers-Danlos syndrome)	20/100–20/400 1.1 (0.6) n=5	20/200–nLP 1.9 (1.0) n=4	20/200–LPd 1.7 (0.7) n=4	20/400 1.3 (0) n=2	20/800–CF 1.6 (0.1) n=2

nLP = no light perception; LP d = defective light projection; LP i = intact light projection; HM = hand movements; CF = counting fingers.

### Visual acuity

The course of visual acuity with respect to diagnosis subgroups is shown in Table 2. In all diagnosis groups the mean logMAR acuity deteriorated during the 5 year follow up. Long term functional results exclude blind eyes, which were enucleated and did not complete the follow up.

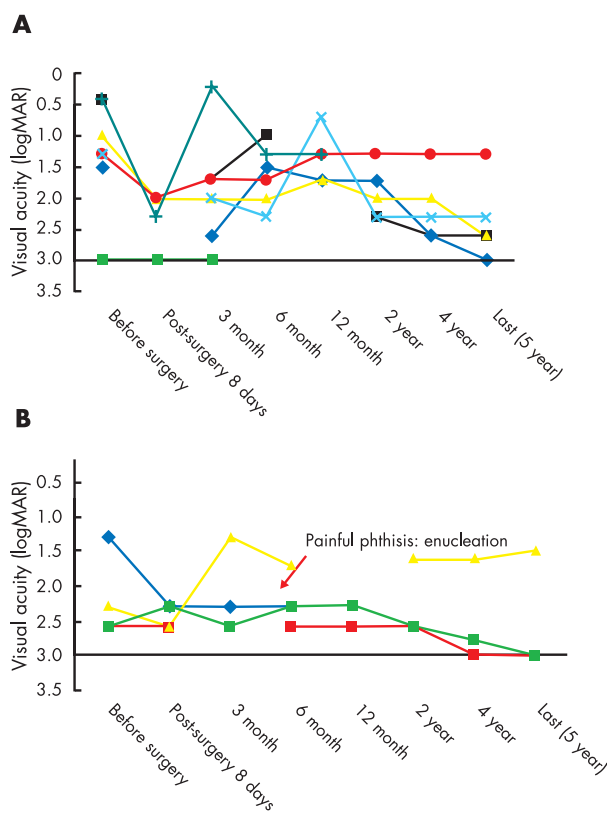
The individual development of visual acuity in patients with glaucoma secondary to uveitis and CRVO is shown in Figure 2. Visual acuity deteriorates significantly in patients with uveitis ( $p < 0.05$ ). Patients with central vein occlusion exhibited a lower preoperative visual acuity (2.2 (0.61) logMAR) compared to uveitis patients (1.2 (0.89) logMAR).

### Final success rate

The final success rate was determined as eyes with no loss of light perception, normal IOP ( $>7$  and  $<22$  mm Hg), and attached retina over a period of 5 years. Eyes with no light perception before surgery were considered as finally successful if IOP was normal and no retinal detachment or PVR was apparent. Applying these criteria, 43.2% of the patients (19 eyes of the total 44 cases) were finally successful after a 5 year follow up.

Twenty seven eyes (61.4%) were considered successful after 1 year follow up. After 2 years 25 patients (56.8%) could be classified as successful. The patients being successful at the 2 year time point were likely to be finally successful after more than 48 months ( $p < 0.05$ ). One patient was lost to follow up. Reasons for late failure after more than 2 years of follow up was loss of light perception in three cases and IOP levels above 22 mm Hg in one case. Persistent hyptonony after 5 years was noted in one eye which was hypotonous already at 1 year after surgery but had an intermediate period of IOP levels above 7 mm Hg at 2 year follow up (Table 3).

Only two out of 12 eyes with neovascular glaucoma were finally successful. The reasons for failure were hypotony in four patients, loss of light perception in three eyes, and persistent high IOP in two eyes. There was no significant correlation with either of the subgroups of PDR, CRVO, or other causes of neovascular glaucoma. In uveitis, four out of seven treatments failed over 5 years. Reasons for failure were hypotony and phthisis and loss of light perception. The most stable long term result was achieved in glaucoma secondary to congenital cataract and aphakia. Eight out of 12 eyes (66.6%) were considered finally successful. Failure was secondary to loss of light perception (two eyes), retinal complications (one eye), and persistent IOP above 22 mm Hg (one eye).



**Figure 2** (A) Individual development of visual acuity in patients with glaucoma secondary to uveitis. Each line represents a single eye. One of the eyes (green line) was enucleated because of phthisis bulbi, two other eyes remained permanently hypotonic with IOP levels below 7 mm Hg. (B) Individual development of visual acuity in patients with neovascular glaucoma after central vein occlusion. Each line represents a single eye. One eye (blue line) was removed from the follow up after 1 year because of phthisis.

### Reduction in medication

The clinical success of the retinectomy is also reflected by less need for antiglaucoma medication. The preoperative pressure lowering medication in comparison with the required treatment after 5 years is shown in Table 4 with respect to the diagnosis subgroups. Except for one patient with juvenile glaucoma, none of the patients required systemic treatment with carbonic anhydrase inhibitors (CAI) 5 years after retinectomy.

All patients with uveitis were free of IOP lowering drugs as were patients with trauma. In congenital cataract glaucoma

**Table 3** IOP regulation in relation to different subgroups

Subgroup	No of eyes (%), n=44	No of eyes (%) with a normalisation of IOP after 5 year follow up	p Value ( $\chi^2$ test)
Women	19 (43.1)	7 (36.8)	0.01
Men	25 (56.8)	16 (64)	
Age (years) $\geq 37$	20 (45.5)	7 (35.0)	0.04
Age (years) $< 37$	24 (54.5)	15 (62.5)	
Preoperative IOP (mm Hg)			0.23
22–30	6 (13.6)	3 (50)	
$\geq 30$ –40	16 (36.4)	10 (62.5)	
$\geq 40$ –50	16 (36.4)	11 (68.7)	
$\geq 50$	6 (13.6)	3 (50)	
Preoperative visual acuity (logMAR)			0.26
3	6 (13.6)	4 (75)	
2–2.6	11 (25)	5 (45.4)	
1.3–1.7	17 (38.6)	12 (70.5)	
0.2–1	10 (22.7)	5 (50)	
Diagnosis			0.18
Neovascular glaucoma	12 (27.2)	4 (33.3)	
Trauma	7 (15.9)	6 (85.7)	
Uveitis	7 (15.9)	4 (57.1)	
Glaucoma due to aphakia in congenital cataracts	13 (29.5)	9 (69.2)	
Others	5 (11.3)	2 (40)	
Number of previous surgeries			0.26
none	18 (40.9)	10 (55.5)	
1–5	16 (36.9)	10 (62.5)	
$\geq 5$	10 (22.7)	6 (60.0)	
Previous fistulating surgery			0.06
Yes	8 (18.1)	7 (87.5)	
No	36 (81.8)	16 (44.4)	
Previous cyclodestructive surgery			0.05
Yes	17 (38.6)	11 (64.7)	
No	27 (61.3)	10 (37.0)	
Complications: PVR, detachment			0.23
Yes	21 (47.7)	11 (52.4)	
No	23 (52.5)	11 (47.8)	
Silicone oil tamponade			
Yes	11	10 (90.9)	
No	10	0	

**Table 4** Influence of retinectomy on IOP lowering medication

Diagnosis	Preop	Preop	>48 month	>48 month
	Syst CAI	Topical (No of medications)	Syst CAI	Topical
Neovascular glaucoma	8/12	mean 1.3	none	7/12 none 1/12 drozolamide and $\beta$ blocking agent
Trauma	5/7	mean 1.5	none	4/7 none 2/7 drozolamide and $\beta$ blocking agent 1/7 drozolamide
Uveitis	5/7	mean 2	none	none (2 patients steroids)
Glaucoma due to aphakia in congenital cataracts	8/13	mean 2.5	none	7/13 none 2/13 drozolamide 1/13 drozolamide and $\beta$ blocking agent
Others Juvenile and infantile glaucoma, Ehlers-Danlos syndrome	2/5	mean 2.8*	2/5 *	2/5 triple treatment

\*In 3/5 cases the follow up was not completed. 2 cases required systemic CAI and topical treatment, but maintained successful IOP control under that medication.

only two patients required topical CAI and one patient required a combination treatment with CAI and  $\beta$  blocking agents compared to 2.5 topical medications before surgery. Similarly, in glaucoma following severe ocular trauma, both systemic and topical medication could be stopped in all patients and in four out of seven, respectively.

### Complications

Seven out of 44 eyes (15.9 %) completed the 5 year follow up uneventfully. They required neither surgical revision nor did they develop phthisis or lost "light perception."

A total of 13 eyes did not complete the follow up of at least 48 months. Five out of these eyes had to be enucleated during

the follow up because of phthisis. Five eyes out of this subgroup required re-vitreotomy and silicone oil tamponade, either because of PVR or persistent hypotony with IOP levels below 7 mm Hg. In these eyes IOP measurements were influenced by the postoperative tamponade with silicone oil and do not reveal the result of the primary retinectomy. Two patients did not continue follow up visits despite successful postoperative IOP control for 2 years.

Intraoperative adverse effects such as intraocular bleeding were not noted. During the early hypertensive postoperative period, one eye in a patient with Ehlers-Danlos syndrome was lost because of rupture of the globe.

### Dysregulation of the IOP: persistent glaucoma or hypotony

Persistent IOP levels above 22 mm Hg (elevated intraocular pressure) or below 7 mm Hg (hypotony) were considered as major complications and failure of the treatment.

Persistent elevated IOP was apparent in four out of 44 cases (9%), of which three required permanent silicone oil tamponade due to extensive PVR reaction or previous hypotony. IOP levels in these cases remained below 25 mm Hg in two cases and 30 mm Hg in one case.

Despite good IOP control over more than 1 year postoperatively, at 2 years after surgery the IOP was raised to levels between 40 and 50 mm Hg in one case with neovascular glaucoma secondary to CRVO. Persistent glaucoma did not correlate to the origin of the glaucoma. Temporary or persistent IOP elevation, however, correlated with silicone oil tamponade ( $p < 0.01$ ). In five eyes with persistent elevated IOP during the first year of follow up an enlargement of the primary retinectomy was performed. Thereafter, three eyes were stable with normal IOP for the rest of the follow up and were considered finally successful, while in two patients phthisis ensued and the eyes had to be enucleated.

Persistent hypotony was found in 11 patients (four eyes uveitis, three eyes PDR, one eye congenital glaucoma, and one eye congenital cataract). Persistent hypotony was associated with phthisis bulbi in seven patients. Out of the 43 patients 32 (74%) did not show persistent hypotony during the 5 year follow up.

The reason for the persistent hypotony was PVR in two cases. Overtreatment was considered responsible for hypotony in the remaining nine patients, in which the size of retinectomy extended over more than 3 clock hours. In six eyes laser coagulation to the choroid (two cases) or silicone filling (four eyes) was performed to elevate IOP through reduction of choroidal outflow. These measures allowed IOP levels to be maintained above 7 mm Hg until the last follow up visit. The effect of previous filtering and cyclodestructive treatment on the outcome of the retinectomy is discussed in the subgroup analysis.

### Retinal complications

Twenty one out of 44 cases (47.7%) required surgical revision because of retinal complications, mainly PVR and persistent hypotony. Hypotonous eyes were associated with traction retinal detachment. Rhegmatogenous detachment was not found.

After surgical revision, 11 out of the 21 eyes (52.4%) demonstrated successful IOP regulation at the long term follow up. Compared to the eyes without retinal complications ( $n = 23$ ), there was no significant worsening of the prognosis towards the long term IOP development (11 out of 23 eyes with appropriate IOP levels (47.8%),  $p > 0.23$ ) (Table 3). Postoperative retinal complications were correlated with deterioration of visual acuity, determined as a loss of at least three lines ( $p < 0.03$ ) and to loss of light perception.

Retinal complications were seen in seven out of 12 eyes with aphakia from congenital cataract (58.3%), in three out of

seven patients with traumatic glaucoma (42.7%), and five out of seven patients with uveitis. PVR was the major cause of retinal complications in the first two groups, persistent hypotony requiring silicone oil tamponade in the uveitis cases.

In contrast, in neovascular glaucoma, a low grade PVR, secondary to persistent vitreous haemorrhages, was only seen in two out of 12 cases. In seven out of 10 patients in which pan-retinal laser photocoagulation was performed for treatment of neovascular glaucoma, this might have had a preventive effect on PVR formation.

The incidence of retinal complications correlated with previous glaucoma surgeries ( $p < 0.04$ ), but there was no significant difference between cyclodestructive or filtering surgery ( $p = 0.34$ ). Out of 11 cases which had had vitrectomy before retinectomy, four eyes developed PVR and required re-treatment (36.3% versus 47.7% in all cases), indicating that previous retinal surgery did not significantly increase the risk of retinal complications after retinectomy.

### Loss of light perception

Loss of light perception was considered as failure of the treatment. Out of 43 cases six (13.9%) presented without light perception before surgery. In 12 cases (27.9%) loss of light perception occurred during the follow up. There was no correlation between postoperative loss of light perception and the diagnosis.

Loss of light perception was secondary to PVR and retinal detachment in three out of 12 cases (25%) and as a consequence of persistent hypotony and phthisis bulbi in five eyes (41.6%). In two cases of CRVO with preoperative visual acuity of defective light projection (2.6 logMAR) and unregulated IOP, loss of light perception was apparent after the third and fourth year of the follow up respectively. Progressive atrophy of the optic disc with loss of light perception 4 years after surgery was seen in one patient. In Ehlers-Danlos syndrome (one patient) the eyeball ruptured on the fourth postoperative day with IOP of 25 mm Hg and sudden loss of "perception of light." Otherwise "loss of light perception" gradually occurred earliest in patients with the worst initial visual acuity ( $n = 12$ ;  $p < 0.01$ ).

### Subgroup analysis


As potential predictors for a significant change in IOP levels after retinectomy preoperative, intraoperative, and postoperative observations were considered. As preoperative factors diagnosis, age, sex, visual acuity and, if apparent, intraoperative factors like haemorrhages and postoperative complications such as PVR and re-retinectomy were also taken into consideration (Table 2). Moreover, the influence of the lens status was examined. The results are given in Table 3.

Except for the ocular trauma, which was seen only in male patients, there was no prevalence towards sex in any diagnostic group. There was also no correlation between sex and postoperative IOP course.

As expected, the mean age of patients with neovascular glaucoma ( $n = 12$ ; 55 (16.1) years) was significantly higher than patients presenting with glaucoma of aphakia after surgery of congenital cataracts ( $n = 12$ ; 19.4 (7.6) years) or patients with glaucoma secondary to uveitis ( $n = 7$ ; 30.8 (9.8) years) ( $p < 0.01$ ). The age at surgery, however, did not significantly correlate to the long term IOP regulation ( $p = 0.43$ ).

In this study the lens status did not significantly influence the long term IOP regulation ( $p = 0.35$ ). Thirty four out of 44 patients were aphakic when entering the study (77.3%). In 50% of the aphakic eyes a successful regulation of IOP was achieved compared to seven out of 10 eyes in pseudophakic or phakic eyes (70%)

The number of previous surgeries did not correlate to a successful IOP regulation ( $p = 0.45$ ). However, each form of the treatment, either filtering or cyclodestructive treatment with



**Figure 3** Clinical composite image of retinectomy.

no preference for one of them, had a positive correlation towards the IOP regulation.

Postoperative retinal complications did not influence long term IOP regulation. In neovascular glaucoma only 33.3% of eyes demonstrated successful IOP regulation after 5 years. However, in severe ocular trauma 85.7% of eyes were found to have IOP levels between 7 and 22 mm Hg in the long term. Similarly, controlled IOP was achieved in congenital/aphakic glaucoma (69.2%) and in uveitis (57.1 %).

## DISCUSSION

We report 5 year follow up of 44 eyes after retinectomy to lower the intraocular pressure in otherwise intractable glaucoma. This series of eyes was considered “intractable” by an experienced glaucoma surgeon (Krieglstein). Thus, either previous conventional treatments failed (cyclodestruction, filtering surgery) or were considered ineffective. Thus, our series is a negative selection of eyes that were already largely damaged by glaucoma and otherwise scheduled for enucleation.

Conventional filtering of cyclodestructive procedures in these eyes are reported to be initially effective<sup>11-13</sup>; however, the long term follow up is affected by either regeneration of the ciliary epithelium as subsequent IOP elevation or by complete secretory failure of the ciliary epithelium resulting in hypotony. Visual loss secondary to hypotony is reported to be a major complication—for example, after cyclophotocoagulation.<sup>14</sup> Filtering devices, even when placed internally (such as Molteno and Baerveldt implants), are subject to wound healing and secondary closure with a loss of filtration ability.<sup>13, 15, 16</sup> Molteno implants have an increasing rate of failure over time especially in young patients and patients with neovascular glaucoma.<sup>17</sup> Konen and co-workers (Konen, personal communication) suggest a drainage to the subchoroidal space which seems to be less responsive to wound healing but still occludes after 1 year of follow up. When the anterior outflow is permanently blocked, such as in advanced neovascular glaucoma or in dysgenesis of the chamber angle, then conventional filtering procedures are unsatisfactory and alternative outflow routes are required.

Posterior aqueous rerouting of the choroid through a retinectomy was first suggested in 1994.<sup>9</sup> Since a retinal hole does not “heal,” such a “filtration site” will remain open. Thus,

IOP regulation via the posterior outflow route and uncompromised aqueous secretion should be advantageous with respect to the long term pressure lowering effect.

The retina itself will not regrow. Nevertheless, the authors believe that there is a slight risk of small retinectomies closing, if the excised area is covered by a whitish material that is probably related to fibrous proliferation after surgical or pre-existing damage to the choroid. In this case series such complications were not seen; however, wounding of the choroid of Bruch’s membrane should be avoided.

With respect to quality of life, the most beneficial achievement of the retinectomy was the reduction in systemic and topical medications for most of the patients. In only two patients systemic treatment with carbonic anhydrase inhibitors continued, but then it allowed for IOP normalisation. In other reports of similar cases, the reduction in glaucoma medication together with IOP normalisation is considered a complete success of the treatment.<sup>17</sup> Comparable reports about a discontinuation of systemic and topical medication are limited to a maximum of 1 year follow up.<sup>18</sup> Long term IOP control for 3 years and more required the use of carbonic anhydrase inhibitors after aqueous shunts in 70% of infants with recalcitrant glaucoma.<sup>13</sup>

In contrast with conventional filtering surgery and cyclodestructive procedures, which are limited by long term failure, failure after retinectomy in our patients occurred early and was mostly the result of retinal complications. Proliferative vitreoretinopathy (PVR) was seen in patients in which no complete posterior vitreous detachment was achieved, but was only recognised during the second intervention when the hyaloid had partially detached or was involved in retinal starfold formation. This complication might be amendable by enzyme assisted vitrectomy in the future.

Early postoperative hypotony and subsequent choroidal detachment and haemorrhage are not seen after retinectomy. The excision of the retina does not increase the flow conductivity in an uncontrolled or exceeded manner. After retinectomy no direct fistula is opened, but the remaining Bruch’s membrane and the osmotic balance between choroid and vitreous cavity provide the necessary resistance to prevent hypotony. Furthermore, the tamponade of the vitreous cavity with expandable gas delays the complete release of the opening.

The work by Marshall and coworkers demonstrated a decrease in the flow conductivity of Bruch’s membrane with

age.<sup>19-23</sup> Together with the progressing atrophy of the choriocapillary vessels this might explain the requirement of an enlarged retinectomy area in older patients.

Although there are now only sparse experimental data showing the absorption of the aqueous by the choroid, this mechanism is likely for the following reasons:

(1) There is an osmotic (oncotic) gradient between the vitreous cavity and the uvea. A passive flow can be expected along this gradient.<sup>24 25</sup>

(2) The retinal pigment epithelium actively pumps water towards the uvea.<sup>25</sup>

Panretinal laser coagulation, which destroys both retina and choroid, does not lower IOP.<sup>26</sup> Similarly, a resection of choroidal melanomas ab externo does not decrease the IOP. Foulds and coworkers<sup>27 28</sup> suggest that the atrophic retina on the bare sclera in these cases does not sufficiently decrease the flow conductivity for efficient IOP reduction.

This is supplemented by experimental data from Pederson *et al*, who reported a shunting of posterior chamber aqueous into the subretinal space and across the blood-retinal barrier by a mechanism independent of IOP.<sup>29</sup> Tsuboi and Peterson were able to quantitate the outflow via the choroid experimentally.<sup>30</sup> The outward permeability was 1.98 (0.31)  $\mu\text{l}/\text{min}$  in eyes with retinal detachment and 0.84 (0.15)  $\mu\text{l}/\text{min}$  in control eyes with vitrectomy alone. Thus, outflow via the outer blood-retinal barrier is facilitated after removal of the retina, which acts as a barrier.

Taken together, we speculate that aqueous is drained to and absorbed by the choroid after retinectomy. As indicated above, the pressure lowering effect or "retinectomy" depends on choroidal perfusion. Thus, conditions that reduce choroidal perfusion, such as old age and panretinal photocoagulation scars, might require larger sized retinectomies to re-install normal resistance to outflow. If retinectomy is followed by hypotony, photocoagulation of the exposed choroid might help to reduce surplus outflow. Laser coagulation of the choroid might work as the retinal pigment epithelium overlying the choroid is still intact after retinectomy and absorbs the laser energy. This possibility is currently under investigation.

According to our results, retinectomy can restore an almost normal flow conductivity. If, with any retinectomy, a normal conductivity is re-established in most of the patients, then one size of retinectomy area is adequate for most patients and this size is independent of the preoperative intraocular pressure. However, a larger area should be excised in patients with pre-existing choroidal atrophy or panretinal laser scars. In our study, the area of retinectomy reconstituting normal flow conductivity extended circumferentially over 2-4 clock hours in one of the upper quadrants and in an anterior-posterior direction halfway to the vascular arcade from the ora serrata to the vascular arcade. Ideally, the retinectomy should be located according to the residual visual field (Fig 3). However, the peripheral retinal areas are relevant for the remaining visual field in only a few patients. Thus, we chose the site of the retinectomy in the upper quadrant for the better tamponade by gas. If the retinectomy is performed in areas of previous cryocoagulation or choroidal sclerosis, an enlargement of the resection area freeing intact choroid can help to succeed in IOP reduction. Similarly, if the resorptive capacity of the choroid is reduced by previous panretinal photocoagulation, the size of the retinectomy needs to be increased. Currently, experimental data are being collected to investigate whether there are drainage differences between peripheral and more central parts of the choroid.

During the long term follow up, two groups of patients demonstrated a high risk of hypotony in the long run: patients with underlying uveitis and patients with neovascular glaucoma. In contrast with the early postoperative hypotony after fistulating procedures these eyes developed low IOP from the underlying disease by increasing aqueous insufficiency

(for example, formation of cyclitic membranes). Similar pathology might account for hypotony in neovascular glaucoma, where ongoing neovascularisation of the ciliary body eventually also leads to aqueous insufficiency. Bartz-Schmidt recommends the blood-ocular barrier breakdown by a silicone oil tamponade instead of the gas tamponade.<sup>31 32</sup>

In conclusion, retinectomy may be an alternative to enucleation in otherwise intractable glaucoma. It has the advantage of a lack of initial postoperative hypotony together with a sufficient long term drainage effect. The posterior aqueous rerouting via retinectomy depends on the integrity of the choroid and thus the size and area of retinectomy should be chosen accordingly. The reduction in systemic and topical medications after retinectomy is considered beneficial for the patients. The results of this long term follow up in these refractory cases may encourage further investigations on indications for retinectomy.

## ACKNOWLEDGEMENTS

This study was funded by Köln Fortune and Retinovit Foundation, Köln, Kämpgen Stiftung, Köln and the Werner und Gertrud Müller Stiftung im Stifterverband, Essen.

The authors thank Silke Coburger, PhD, Department of Medical Informatics, University of Köln, for professional statistical advice.

## Authors' affiliations

**A M Jousseaume, P Walter, C P Jonescu-Cuypers, K Koizumi, V Poulaki, G K Kriegelstein, B Kirchhof**, Department of Vitreoretinal Surgery, Center of Ophthalmology, University of Cologne, Germany  
**K U Bartz-Schmidt**, Department of Ophthalmology, University of Tübingen, Germany

## REFERENCES

- 1 **Cordeiro MF**, Chang L, Lim KS, *et al*. Modulating conjunctival wound healing. *Eye* 2000;**14**:536-47.
- 2 **Ayyala RS**, Bellows AR, Thomas JV, *et al*. Bleb infections: clinically different courses of "blebitis" and endophthalmitis. *Ophthalmic Surg Lasers* 1997;**28**:452-60.
- 3 **Lehmann OJ**, Bunce C, Matheson MM, *et al*. Risk factors for the development of post-trabeculectomy endophthalmitis. *Br J Ophthalmol* 2000;**84**:1349-53.
- 4 **Brown RH**, LH Y, Walker SD, *et al*. Treatment of bleb infection after glaucoma surgery. *Arch Ophthalmol* 1994;**112**:57-61.
- 5 **Myers JS**, Yang CB, Herndon LW, *et al*. Excisional bleb revision to correct overfiltration or leakage. *J Glaucoma* 2000;**9**:169-73.
- 6 **Chen TC**, Pasquale LR, Walton DS, *et al*. Diode laser transscleral cyclophotocoagulation. *Int Ophthalmol Clin* 1999;**39**:169-76.
- 7 **Bloom PA**, Tsai JC, Sharma K, *et al*. "Cyclodiode". Trans-scleral diode laser cyclophotocoagulation in the treatment of advanced refractory glaucoma. *Ophthalmology* 1997;**104**:1508-19; discussion 1519-20.
- 8 **Kirchhof B**. The contribution of vitreoretinal surgery to the management of refractory glaucomas. *Curr Opin Ophthalmol* 1999;**10**:117-20.
- 9 **Kirchhof B**. Retinectomy lowers intraocular pressure in otherwise intractable glaucoma: preliminary results. *Ophthalmic Surg* 1994;**25**:262-7.
- 10 **O'Keefe M**, Nabil M. The use of mannitol in intraocular surgery. *Ophthalmic Surg* 1983;**14**:55-6.
- 11 **Seah SK**, Jap A, Min G. Contact transscleral cyclophotocoagulation for end stage glaucoma. *Ann Acad Med Singapore* 1994;**23**:18-20.
- 12 **Kirwan JF**, Shah P, Khaw PT. Diode laser cyclophotocoagulation: role in the management of refractory pediatric glaucomas. *Ophthalmology* 2002;**109**:316-23.
- 13 **Pereira M**, Araujo SV, Wilson RP, *et al*. Aqueous shunts for intractable glaucomas in infants. *Ophthalmic Surg Lasers* 2002;**33**:19-29.
- 14 **Dickens CJ**, Nguyen N, Mora JS, *et al*. Long-term results of noncontact transscleral Nd:YAG cyclophotocoagulation. *Ophthalmology* 1995;**102**:1777-81.
- 15 **Scott IU**, Alexandrakis G, Flynn HWJ, *et al*. Combined pars plana vitrectomy and glaucoma drainage implant placement for refractory glaucoma. *Am J Ophthalmol* 2000;**129**:334-41.
- 16 **Krishna R**, Godfrey DG, Budenz DL, *et al*. Intermediate-term outcomes of 350-mm(2) Baerveldt glaucoma implants. *Ophthalmology* 2001;**108**:621-6.
- 17 **Mills RP**, Reynolds A, Emond MJ, *et al*. Long-term survival of Molteno glaucoma drainage devices. *Ophthalmology* 1996;**103**:299-305.
- 18 **Sihota R**, Sandramouli S, Sood NN. A prospective evaluation of anterior retinal cryoablation in neovascular glaucoma. *Ophthalmic Surg* 1991;**22**:256-9.
- 19 **Hussain AA**, Rowe L, Marshall J. Age-related alterations in the diffusional transport of amino acids across the human Bruch's-choroid complex. *J Opt Soc Am A Opt Sci Vis* 2002;**19**:166-72.

- 20 **Ahir A**, Guo L, Hussain AA, *et al*. Expression of metalloproteinases from human retinal pigment epithelial cells and their effects on the hydraulic conductivity of Bruch's membrane. *Invest Ophthalmol Vis Sci* 2002;**43**:458-65.
- 21 **Starita C**, Hussain AA, Marshall J. Decreasing hydraulic conductivity of Bruch's membrane relevance to photoreceptor survival and lipofuscinoses. *Am J Med Genet* 1995;**57**:235-7.
- 22 **Starita C**, Hussain AA, Pagliarini S, *et al*. Hydrodynamics of ageing Bruch's membrane: implications for macular disease. *Exp Eye Res* 1996;**62**:565-72.
- 23 **Starita C**, Hussain AA, Patmore A, *et al*. Localization of the site of major resistance to fluid transport in Bruch's membrane. *Invest Ophthalmol Vis Sci* 1997;**38**:762-7.
- 24 **Negi A**, Marmor MF. Mechanisms of subretinal fluid resorption in the cat eye. *Invest Ophthalmol Vis Sci* 1986;**27**:1560-3.
- 25 **Negi A**, Marmor MF. The resorption of subretinal fluid after diffuse damage to the retinal pigment epithelium. *Invest Ophthalmol Vis Sci* 1983;**24**:1475-9.
- 26 **Kaufman SC**, Ferris FL, Swartz M. Intraocular pressure following panretinal photocoagulation for diabetic retinopathy. Diabetic Retinopathy Report No 11. *Arch Ophthalmol* 1987;**105**:807-9.
- 27 **Foulds WS**. Do we need a retinal pigment epithelium (or choroid) for the maintenance of retinal apposition? *Br J Ophthalmol* 1985;**69**:237-9.
- 28 **Foulds WS**, D'Amato BE, Burton RL. Local resection versus enucleation in the management of choroidal melanoma. *Eye* 1987;**1**:676-9.
- 29 **Pederson JE**. Experimental retinal detachment. IV. Aqueous humor dynamics in rhegmatogenous detachments. *Arch Ophthalmol* 1982;**100**:1814-16.
- 30 **Tsuboi S**, Pederson JE. Permeability of the blood-retinal barrier to carboxylfluorescein in eyes with rhegmatogenous retinal detachment. *Invest Ophthalmol Vis Sci* 1987;**28**:96-100.
- 31 **Psichias A**, Bartz-Schmidt KU, Thumann G, *et al*. Vitreoretinale Chirurgie in der Behandlung des neovaskulären Glaukoms. *Klin Monatsbl Augenheilkd* 1999;**214**:61-70.
- 32 **Bartz-Schmidt KU**, Thumann G, Psichias A, *et al*. Pars plana vitrectomy, endolaser coagulation of the retina and the ciliary body combined with silicone oil endotamponade in the treatment of uncontrolled neovascular glaucoma. *Graefes Arch Clin Exp Ophthalmol* 1999;**237**:969-75.

## Readers' favourite

**Top 10**

Click on the "Top 10" button on the homepage to see which are the best read articles each month

**[www.bjophthalmol.com](http://www.bjophthalmol.com)**



## Retinectomy for treatment of intractable glaucoma: long term results

A M Joussem, P Walter, C P Jonescu-Cuypers, et al.

*Br J Ophthalmol* 2003 87: 1094-1102

doi: 10.1136/bjo.87.9.1094

---

Updated information and services can be found at:

<http://bjo.bmj.com/content/87/9/1094.full.html>

---

*These include:*

### References

This article cites 30 articles, 10 of which can be accessed free at:

<http://bjo.bmj.com/content/87/9/1094.full.html#ref-list-1>

Article cited in:

<http://bjo.bmj.com/content/87/9/1094.full.html#related-urls>

### Email alerting service

Receive free email alerts when new articles cite this article. Sign up in the box at the top right corner of the online article.

---

### Topic Collections

Articles on similar topics can be found in the following collections

[Angle](#) (788 articles)

[Glaucoma](#) (776 articles)

[Intraocular pressure](#) (786 articles)

[Paediatrics](#) (274 articles)

[Retina](#) (1207 articles)

[Vitreous](#) (124 articles)

[Ophthalmologic surgical procedures](#) (962 articles)

[Lens and zonules](#) (638 articles)

---

### Notes

---

To request permissions go to:

<http://group.bmj.com/group/rights-licensing/permissions>

To order reprints go to:

<http://journals.bmj.com/cgi/reprintform>

To subscribe to BMJ go to:

<http://group.bmj.com/subscribe/>