

BJO at a glance

Creig Hoyt
Editor

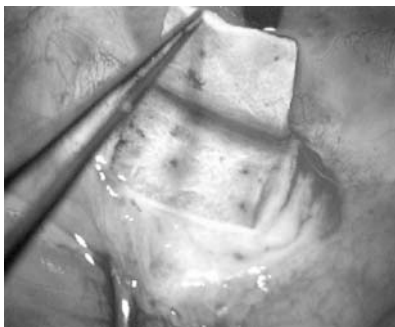
IS MYOPIA RELATED TO INTRAOCULAR PRESSURE?

The precise aetiological factors responsible for the development of myopia are incompletely understood. Intraocular pressure is one of several factors implicated in the pathogenesis of myopia. It has been postulated that elevated intraocular pressure would create scleral stress resulting in axial elongation. Lee and coworkers report a study of 636 Chinese children age 9–11 years who underwent non-contact tonometry, cycloplegic autorefraction, and A-scan biometry. There were no significant intraocular pressure differences between low or high myopes and emmetropes. This study does not support an association between intraocular pressure and refractive error or axial length in children.

See p 5

BACTERIAL CORNEAL ULCER TREATMENT

Bacterial corneal ulceration remains a significant cause of visual disability throughout the world. Prompt topical antimicrobial therapy is the cornerstone for successful treatment. Empirical therapy is usually initiated with a broad spectrum regimen until smear or culture provides the causal organisms. Several drugs have been used in an



See p 95

empirical treatment of corneal ulcers—for example, aminoglycosides, cephalosporins, and fluoroquinolones. Emergence of resistant strains is a major concern when antibiotics such as fluoroquinolones are used as monotherapy. Bosscha and coworkers report the results of a retrospective study of 91 patients with bacterial ulcers treated with a topical combination of polymyxin B, neomycin, and gramicidin. In this study this combination was effective in the safe treatment of suspected corneal ulceration. Among 91 patients there were four perforations and one evisceration.

See p 25

RISK FACTORS FOR ACUTE ENDOPHTHALMITIS

Acute infectious endophthalmitis remains a vision threatening complication of cataract. Although rare, it is a serious and dreaded complication. Wong and Chee report a retrospective case controlled study of 34 patients with acute endophthalmitis presenting within 6 weeks after cataract surgery. Three controls per case were randomly selected from cataract surgery lists matched on the date of operation of cases. This study suggests that the use of silicone intraocular lenses and/or rupture of posterior capsule are risk factors for the development of acute endophthalmitis after cataract surgery.

See p 29

ASSOCIATED RISK FACTORS FOR UVEAL MELANOMA

Cutaneous freckles and naevi have been shown to be risk factors for cutaneous melanoma, possibly reflecting a common aetiological factor such as a genetic predisposition or ultraviolet light exposure. Harbour and coworkers investigated 65 patients with posterior uveal melanoma and 218 controls. In this study there was no association of iris freckles, iris naevi, choroidal naevi, and the development of posterior uveal melanoma. Several investigators have reported an association between uveal melanoma and light iris colour. This is based on the assumption that light iris colour may allow more ultraviolet light to reach the posterior segment. These studies have generally been interpreted to support the aetiological role of ultraviolet exposure and uveal melanoma. Harbour and coworkers studied the same group of patients described in the previous study and found that increased choroidal pigmentation was not protective but may in fact actually be a risk factor for the development of posterior uveal melanoma in white patients. This finding would suggest that ultraviolet exposure is not a significant risk factor for the development of uveal melanoma.

See p 36 and p 39

THE USE OF COLLAGEN IMPLANT WITH DEEP SCLERECTOMY

Deep sclerectomy is a non-penetrating filtration procedure for the treatment of open angle glaucoma. Deep sclerectomy was designed in an attempt to lower the risk of postoperative complications associated with traditional trabeculectomy. Implants have been used in deep sclerectomy in the hope of increasing the success rates of the surgery. Shaarawy and coworkers report a prospective randomised trial of 104 eyes that all underwent deep sclerectomy. Half of them also had collagen implants while another half did not. In this study the use of a collagen implant in deep sclerectomy was associated with increased success rates and lowered the need for postoperative medication.

See p 95



BJO at a glance

Creig Hoyt

Br J Ophthalmol 2004 88: 1
doi: 10.1136/bjo.88.1.1-a

Updated information and services can be found at:
<http://bjo.bmj.com/content/88/1/1.2.full.html>

These include:

**Email alerting
service**

Receive free email alerts when new articles cite this article. Sign up in the box at the top right corner of the online article.

Notes

To request permissions go to:
<http://group.bmj.com/group/rights-licensing/permissions>

To order reprints go to:
<http://journals.bmj.com/cgi/reprintform>

To subscribe to BMJ go to:
<http://group.bmj.com/subscribe/>