

## SCIENTIFIC REPORT

# The efficacy and safety of topical polymyxin B, neomycin and gramicidin for treatment of presumed bacterial corneal ulceration

M I Bosscha, J T van Dissel, E J Kuijper, W Swart, M J Jager

*Br J Ophthalmol* 2004;88:25–28

**Aim:** To evaluate the clinical efficacy and safety of topical polymyxin B, neomycin, and gramicidin for the treatment of suspected bacterial corneal ulceration at the Leiden University Medical Center.

**Methods:** Patients with a diagnosis of a suspected bacterial corneal ulcer between April 1995 and February 2002 were retrospectively identified and reviewed; clinical and microbiological features and response to therapy were analysed. All patients were treated with Polyspectran eye drops.

**Results:** In total, 91 patients were included in this analysis. Bacteriological cultures of 46 patients (51%) were positive and revealed 51 microorganisms. *Staphylococcus aureus* (29.4%) and *Pseudomonas aeruginosa* (23.5%) were the most frequently encountered bacteria. Eighteen patients switched therapy before complete healing of the corneal ulceration, four patients were lost to follow up. Of the 69 patients who completed Polyspectran treatment, re-epithelialisation occurred in 68 patients (99%) and on average took 12.6 (median 8) days. Among 91 patients, there were four perforations and one evisceration. Seven toxic or allergic reactions were reported.

**Conclusion:** This study shows that the combination of polymyxin B, neomycin, and gramicidin is an effective and safe treatment of suspected corneal ulceration.

Bacterial corneal ulceration can result in permanent loss of vision if not treated promptly and appropriately. A perforation of the cornea can develop in less than one day and is associated with virulent pathogens like *Pseudomonas aeruginosa* and *Staphylococcus aureus*.<sup>1</sup>

Prompt topical antimicrobial therapy is the cornerstone for successful treatment of bacterial corneal ulceration. Given the spectrum of causative bacterial pathogens, empirical therapy must be initiated with a broad spectrum regimen until smear or culture provides the identity of the causative organism.<sup>2–4</sup> Several drugs have been used in the empirical treatment of corneal ulcers—for example, amino-glycosides, cephalosporins, and fluoroquinolones. However, emergence of resistant strains is a major concern when antibiotics such as fluoroquinolones are used as monotherapy.<sup>5–7</sup>

The combination of polymyxin B, neomycin, and gramicidin (Polyspectran, Alcon, Gorinchem, The Netherlands) offers a broad spectrum activity against Gram negative as well as Gram positive bacteria including staphylococci, streptococci, and *P aeruginosa*. On the basis of its broad antibacterial activity, we made the combination of polymyxin B, gramicidin, and neomycin the standard treatment of suspected bacterial corneal ulceration. Here, we evaluate retrospectively the clinical efficacy and safety of Polyspectran of all patients treated since 1995.

## METHODS

The medical records of all patients with a diagnosis of a suspected bacterial corneal ulcer between April 1995 and February 2002 were selected for retrospective review.

The codes for the diagnosis “microbiological ulcus corneae” from the Medical Documentation Service of the Leiden University Medical Center were searched to find all patients with corneal ulcers.

A bacterial corneal ulcer was defined as an epithelial defect demonstrated by fluorescein staining, with a stromal infiltrate with or without a hypopyon and no other active ocular infection. A positive microbiological culture was not obligatory to include the case as many patients had been pre-treated with topical antibiotics before attending our clinic.

After medical record review, 20 patients with a diagnosis of a viral (n = 16), a fungal (n = 1), or an Acanthamoeba (n = 3) infection, but without a bacterial ulceration, were excluded from this study. We also excluded patients with a second ulcer (n = 4) if they had been included previously in the study.

The following details were obtained from each chart: the patient’s age, sex, predisposing factors, visual acuity measured with Snellen charts, presenting symptoms, ulcer location, and size. Anterior inflammation was scored by Tyndall score and cells<sup>8</sup> and a hypopyon if present. We recorded associated ocular and systemic conditions, use of topical steroids, healing time, visual outcome, complications, and duration of treatment.

Ulcers were scraped for Gram staining and cultured on sheep blood agar and chocolate agar. These specimens were processed and analysed using standard protocols.<sup>9</sup>

All patients were treated according to a standard protocol consisting of topically administered polymyxin B (7500 IU/ml polymyxin-B-sulfate), neomycin (3500 IU/ml neomycinsulfate), and gramicidin (0.02 mg/ml) eye drops. The eye drops were given hourly and after one day they were progressively tapered according to perceived improvement of the ulcer and the clinical response. Additional treatment included cycloplegics and anti-glaucoma therapy, wherever indicated. Topical corticosteroids or topical/systemic antiviral agents were added if necessary.

The primary outcome measures of efficacy were defined as the time to healing and re-epithelialisation. Cured corneal ulcer was defined as complete re-epithelialisation with regression of stromal infiltrates. Patients were considered to have a poor clinical outcome if a complication occurred, such as corneal perforation or enucleation.

Statistical analysis was performed using SPSS version 10 (SPSS, Chicago, IL, USA). Time to healing was evaluated using Kaplan-Meier life table analysis. Multivariable logistic regression analysis was used to evaluate the contribution on re-epithelialisation of the ulcer of the various parameters documented.

**Table 1** Characteristics of 91 patients with bacterial corneal ulceration

Parameter	Patients (n=91)	%
Age (years)		
≤29	21	23
30–49	20	22
50–69	19	21
≥70	31	34
Gender		
Female	47	52
Male	44	48
Ulcer location		
Central	40	44
Inferior	28	31
Peripheral	13	14
Superior	10	11
Size of epithelial defects (mm <sup>2</sup> )		
1 < x ≤ 5	65	71
5 < x ≤ 10	15	17
10 < x ≤ 15	4	4
>15	7	8
Hypopyon	36	40
Fibrin	16	18
HypHEMA	3	3
Contact lens	34	37.4
Soft	29	
Rigid gas-permeable	1	
Bandage	4	
Corneal conditions	32	35.2
Dystrophy/keratopathy	17	
Herpetic keratopathy	10	
Corneal transplant	7	
Keratitis sicca	3	
Melting, descemetocele	2	
Keratoconus	1	
Pterygium	1	
Associated lid conditions	21	23.1
Ectropion	10	
Lagophthalmos	3	
Trichiasis	3	
Entropion	3	
Blepharitis	2	
Trauma	12	13.2
Post operative	7	7.7
Cataract extraction	2	
Loose suture	2	
Other	4	
No pathology	9	9.9
Previous topical medication	51	56.0
Antibiotics	35	
Corticosteroids	20	
Antiviral	10	
Other	2	

## RESULTS

Ninety one patients (44 male, 47 female; median age 53 (Inter Quartile Range, IQR 30–77) years were included in the study. Patient characteristics are summarised in table 1. The median diameter of the ulcers was 3 mm (IQR: 2–6). There was a direct proportional association between age and ulcer size—that is, elderly patients had the largest size ulcers. Anterior chamber inflammation was absent in 18 patients (20%), mild inflammation (1 to 2+ Tyndall effect and cells) was present in 42 patients (50%), whereas signs of severe anterior chamber inflammation (3 to 4+ Tyndall effect and cells) were present in nine patients (10%). In 18 patients (20%) corneal ulceration precluded assessment of the anterior chamber. In all but nine patients, one or more predisposing local factors could be identified. Soft contact lens wear was common and encountered in 29 (32%) patients.

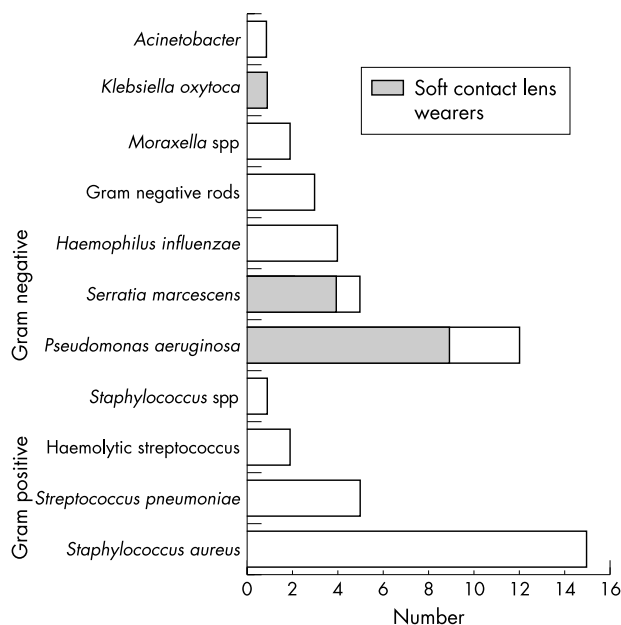
From 91 patients, 81 Gram stains were taken and 86 cultures were performed. Of 81 Gram stain specimens, 46 (51%) identified the putative etiological microorganism: 24

(26%) Gram negative bacilli, 22 (24%) Gram positive cocci, and 11 (12%) Gram positive bacilli were identified. Of the 46, ten specimens showed multiple microorganisms. Bacteriological cultures were positive in 46 patients (51%) in whom the Gram stain already identified a bacterial cause of infection; overall, 51 species of bacteria were cultured from the 86 corneal smears. Thirty two patients had been given local antibiotic treatment before referral and of these patients, 13 (40%) yielded a positive culture, as compared with 33 (61%) of 54 patients who did not get topical antibiotic eye drops before referral. A variety of organisms was identified (fig 1). Gram positive bacteria were mainly *S aureus*, Gram negative bacteria mostly *Pseudomonas* species.

In all patients, Polyspectran treatment was initiated as soon as the clinical diagnosis was made. Of the 91 patients, 69 patients (76%) completed this treatment up to complete re-epithelialisation or another outcome. In 18 patients treatment changed before complete re-epithelialisation, whereas four patients were lost to follow up after two, three, and eight days respectively. Six of the 18 patients were switched to aminoglycoside monotherapy on the basis of culture results. Another six patients switched therapy because Polyspectran was not available in the local pharmacy. In four patients treatment was modified because of an adverse effect and in two patients because the clinical response was deemed insufficient. In the 18 patients who switched treatment, complete corneal re-epithelialisation occurred in 17 of 18 ulcers (94%). The average diameter of these ulcers was 10 mm<sup>2</sup> (median 6 (IQR 4–8) mm<sup>2</sup>), twice as large as compared with the whole group.

In the patients who completed treatment, corneal re-epithelialisation occurred in 68 of 69 ulcers (99%), and took on average 12.6 days (median 8 (IQR 4–14) days). Thus, within one week of treatment initiation, about half of the patients exhibited corneal epithelial closing (fig 2A).

The single most important determinant of time to complete re-epithelialisation was the ulcer size on diagnosis ( $p < 0.0001$ ) (fig 2B). The time to complete re-epithelialisation did not differ ( $p = 0.08$ ) between patients with a positive or negative culture, though there was a trend towards



**Figure 1** Gram negative bacteria are the most commonly isolated organisms, among which *Pseudomonas aeruginosa* predominate. *Staphylococcus aureus* is the Gram positive bacterium most frequently encountered.

somewhat longer healing time in the former group (fig 2C). The healing time of ulcers with Gram positive bacteria did not differ ( $p=0.60$ ) from that with Gram negative bacilli on smear (fig 2D).

Of 91 patients, data on the visual acuity of 81 patients were analysed. For the whole group, the median visual acuity before treatment was 20/200 (IQR 20/600–20/40). Visual acuity improved to 20/40 (IQR 20/400–20/25) after full re-epithelialisation, indicating that visual acuity had improved.

**Complications**

Among the 91 patients, only five patients (5%) had a poor clinical outcome of perforation ( $n=4$ ) or evisceration ( $n=1$ ). A 77 year old male with rheumatoid arthritis had a culture-negative corneal ulcer that perforated on day seven and healed within two weeks. A 30 year old female had used steroid eye drops for years because of a chronic Herpetic keratitis. After 10 days a perforation occurred and the ulcer healed by day 22 (no microorganism was cultured). A 51 year old male with rheumatoid arthritis switched treatment to ofloxacin on the second day because of presumed toxicity. On day 12 the patient had a corneal perforation in an *S aureus* proven ulcer. An 85 year old man had an ulcer caused by an *S aureus* in a thin dystrophic cornea. On the third day, treatment was changed into gentamicin. After 45 days the cornea perforated; the infection was considered cured after 65 days. A 75 year old woman with a pre-existent blind painful eye suffered from a toxic reaction to Polyspectran. After six days the patient wished to eviscerate her painful eye.

**Safety**

Untoward ocular events related, or possibly unrelated, to polymixin B, neomycin, and gramicidin therapy were mild and resolved without treatment. Among the 91 corneal ulcer patients enrolled in this study, seven (8%) untoward ocular events were encountered: in four patients a toxic punctate epitheliopathy occurred that necessitated a treatment modification in two. Three patients apparently suffered a mild allergic reaction evidenced by eyelid oedema, chemosis, and

hyperaemia of the conjunctiva. This reaction led to a modification of treatment in only one patient.

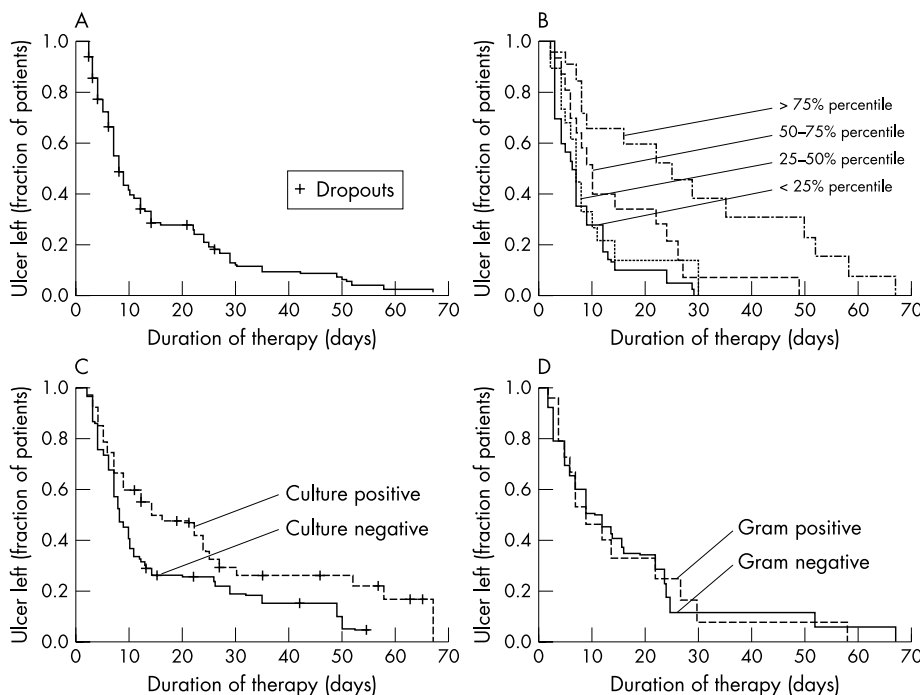
**DISCUSSION**

The outcomes of the present retrospective study indicate that the topical application of polymyxin B, neomycin, and gramicidin (Polyspectran) is highly effective in the treatment of bacterial corneal ulcers. This treatment results in an as rapid re-epithelialisation and similar recovery of visual acuity as the application of fortified topical cephalosporins, aminoglycosides or, more recently, fluoroquinolones.<sup>10-14</sup>

The choice of the combination of polymyxin B, neomycin, and gramicidin for the treatment of corneal ulcers was made on its broad spectrum antibacterial activity covering all commonly encountered pathogens causing corneal ulcers. More than one component of the combination shows bactericidal activity to these pathogens. Furthermore, the in-hospital policy for prevention of antibiotic resistance requires that antibiotics reserved for second line treatment of serious infections in the hospital, (for example, fluoroquinolones, third generation cephalosporins) should not be considered first choice drugs in a topical treatment.

If signs and symptoms are suggestive of bacterial corneal infection then prompt antimicrobial treatment is indicated. Parameters directing the choice of antimicrobial treatment of an infection include: (1) activity of the drug against the causative microorganism, (2) the possibility to reach effective concentrations of the drug at the site of infection, (3) the toxicity of the drug and any known drug allergy, (4) the chance of emergence of antibiotic resistance, and last but not least (5) costs and in-hospital policy regarding usage of antibiotics.

To obtain a definite microbiological diagnosis, scrapings should be obtained before the start of empirical antibiotic therapy,<sup>3</sup> though empirical treatment and close follow up of small ulcers is justifiable.<sup>15 16</sup> In our study, culture of corneal smears were positive in about half of the cases, and yielded the typical pathogens reported in earlier studies.<sup>17 18</sup> The culture and antibiotic sensitivity testing is important especially if primary resistance is anticipated: for instance, the



**Figure 2** (A) Re-epithelialisation in patients treated with Polyspectran. In 14 days, about 75% of the corneal ulcers were healed. (B) The relation between ulcer size and time to healing. (C) Culture negative ulcers appear to have a shorter time to heal compared with ulcers with a positive culture. (D) There is no difference in time to healing at ulcers with positive or negative Gram stain.

isolation of fluoroquinolone- or ceftazidim-resistant *Pseudomonas* spp in institutions that rely on fluoroquinolone or cephalosporin drops in the empirical treatment of corneal ulcers. We did not observe primary failure of therapy caused by antibacterial resistance.

In this study, 68 of 69 patients with corneal ulcers received and completed topical treatment with polymyxin B, neomycin, and gramicidin. All of these ulcers displayed complete healing after, on average, 12.5 (median 8) days. Of the culture proven group (n = 46), the average time to healing was 14.4 days. Our findings compare favourably to those of Prajna *et al* (2001)<sup>19</sup> who compared ofloxacin versus ciprofloxacin drops in 217 patients with culture-positive bacterial ulcers. They found that the time to corneal ulcer healing amounted to 13.7 days (treated with ofloxacin) and 14.4 days (treated with ciprofloxacin).

We observed only a few adverse effects, none of them serious, and the rate of corneal perforation or complete loss of visual acuity compares favourably with that reported in other studies. It seems even better compared with the worrying increased rate of corneal perforation after topical fluoroquinolone treatment reported by Mallari *et al*<sup>20</sup> and others.<sup>21</sup> Also in our study, one patient developed a corneal perforation under ofloxacin treatment.

The Department of Ophthalmology chose a commercially available antibiotic eye drop with a broad-spectrum antibacterial activity, a good clinical effectiveness, and few side effects. This study shows that the combination of polymyxin B, neomycin, and gramicidin is effective and safe in the treatment of suspected corneal ulceration.

#### Authors' affiliations

**M I Bosscha, W Swart, M J Jager**, Department of Ophthalmology, Leiden University Medical Center, Leiden, The Netherlands

**J T van Dissel**, Department of Infectious Diseases, Leiden University Medical Center, Leiden, The Netherlands

**E J Kuijper**, Departments of Medical Microbiology, Leiden University Medical Center, Leiden, The Netherlands

Correspondence to: M I Bosscha, Department of Ophthalmology, Leiden University Medical Center, PO Box 9600, 2300 RC Leiden, The Netherlands; [m.i.bosscha@lumc.nl](mailto:m.i.bosscha@lumc.nl)

Accepted for publication 26 May 2003

## REFERENCES

- 1 **Ostler HB**. Disease of the Cornea. In: Mitchell CW, ed. *Disease of the external eye and adnexa*. Baltimore: Wilkins & Wilkins, 1993:137-252.
- 2 **Jones DB**. Decision-making in the management of microbial keratitis. *Ophthalmology* 1981;**88**:814-20.
- 3 **Allan BD**, Dart JK. Strategies for the management of microbial keratitis. *Br J Ophthalmol* 1995;**79**:777-86.
- 4 **Jones DB**. A plan for antimicrobial therapy in bacterial keratitis. *Trans Am Acad Ophthalmol Otolaryngol* 1975;**79**:95-103.
- 5 **Smith A**, Pennefather PM, Kaye SB, *et al*. Fluoroquinolones: place in ocular therapy. *Drugs* 2001;**61**:747-61.
- 6 **Goldstein MH**, Kowalski RP, Gordon YJ. Emerging fluoroquinolone resistance in bacterial keratitis: a 5-year review. *Ophthalmology* 1999;**106**:1313-18.
- 7 **Alexandrakis G**, Alfonso EC, Miller D. Shifting trends in bacterial keratitis in south Florida and emerging resistance to fluoroquinolones. *Ophthalmology* 2000;**107**:1497-502.
- 8 **Hogan MJ**, Kimura SJ, Thygeson P. Signs and symptoms of uveitis. I. Anterior uveitis. *Am J Ophthalmol* 1959;**47**:155-70.
- 9 **Murray PR**, Baron EJ, Pfaller MA, *et al*. *Manual of Clinical Microbiology*, 7 ed. Washington DC: ASM Press, 1999.
- 10 **O'Brien TP**, Maguire MG, Fink NE, *et al*. Efficacy of ofloxacin vs ceftazolin and tobramycin in the therapy for bacterial keratitis. Report from the Bacterial Keratitis Study Research Group. *Arch Ophthalmol* 1995;**113**:1257-65.
- 11 **Panda A**, Ahuja R, Sastry SS. Comparison of topical 0.3% ofloxacin with fortified tobramycin plus ceftazolin in the treatment of bacterial keratitis. *Eye* 1999;**13**(Pt 6):744-7.
- 12 **Hyndiuk RA**, Eiferman RA, Caldwell DR, *et al*. Comparison of ciprofloxacin ophthalmic solution 0.3% to fortified tobramycin-ceftazolin in treating bacterial corneal ulcers. Ciprofloxacin Bacterial Keratitis Study Group. *Ophthalmology* 1996;**103**:1854-62.
- 13 Ofloxacin monotherapy for the primary treatment of microbial keratitis: a double-masked, randomized, controlled trial with conventional dual therapy. The Ofloxacin Study Group. *Ophthalmology* 1997;**104**:1902-9.
- 14 **Gangopadhyay N**, Daniell M, Weih L, *et al*. Fluoroquinolone and fortified antibiotics for treating bacterial corneal ulcers. *Br J Ophthalmol* 2000;**84**:378-84.
- 15 **McLeod SD**. The role of cultures in the management of ulcerative keratitis. *Cornea* 1997;**16**:381-2.
- 16 **McLeod SD**, Kolahdouz-Isfahani A, Rostamian K, *et al*. The role of smears, cultures, and antibiotic sensitivity testing in the management of suspected infectious keratitis. *Ophthalmology* 1996;**103**:23-8.
- 17 **Levey SB**, Katz HR, Abrams DA, *et al*. The role of cultures in the management of ulcerative keratitis. *Cornea* 1997;**16**:383-6.
- 18 **Gritz DC**, Whitcher JP Jr. Topical issues in the treatment of bacterial keratitis. *Int Ophthalmol Clin* 1998;**38**:107-14.
- 19 **Prajna NV**, George C, Selvaraj S, *et al*. Bacteriologic and clinical efficacy of ofloxacin 0.3% versus ciprofloxacin 0.3% ophthalmic solutions in the treatment of patients with culture-positive bacterial keratitis. *Cornea* 2001;**20**:175-8.
- 20 **Mallari PL**, McCarty DJ, Daniell M, *et al*. Increased incidence of corneal perforation after topical fluoroquinolone treatment for microbial keratitis. *Am J Ophthalmol* 2001;**131**:131-3.
- 21 **Morlet N**, Minassian D, Butcher J. Risk factors for treatment outcome of suspected microbial keratitis. Ofloxacin Study Group. *Br J Ophthalmol* 1999;**83**:1027-31.



## The efficacy and safety of topical polymyxin B, neomycin and gramicidin for treatment of presumed bacterial corneal ulceration

M I Bosscha, J T van Dissel, E J Kuijper, et al.

*Br J Ophthalmol* 2004 88: 25-28  
doi: 10.1136/bjo.88.1.25

---

Updated information and services can be found at:  
<http://bjo.bmj.com/content/88/1/25.full.html>

---

*These include:*

### References

This article cites 18 articles, 4 of which can be accessed free at:  
<http://bjo.bmj.com/content/88/1/25.full.html#ref-list-1>

### Email alerting service

Receive free email alerts when new articles cite this article. Sign up in the box at the top right corner of the online article.

---

### Topic Collections

Articles on similar topics can be found in the following collections

[Cornea](#) (383 articles)  
[Eye \(globe\)](#) (543 articles)  
[Ocular surface](#) (455 articles)

---

### Notes

---

To request permissions go to:  
<http://group.bmj.com/group/rights-licensing/permissions>

To order reprints go to:  
<http://journals.bmj.com/cgi/reprintform>

To subscribe to BMJ go to:  
<http://group.bmj.com/subscribe/>