

PostScript

LETTERS

If you have a burning desire to respond to a paper published in *BJO*, why not make use of our "rapid response" option?

Log onto our website (www.bjophthalmol.com), find the paper that interests you, and send your response via email by clicking on the "eLetters" option in the box at the top right hand corner.

Providing it isn't libellous or obscene, it will be posted within seven days. You can retrieve it by clicking on "read eLetters" on our homepage.

The editors will decide as before whether to also publish it in a further paper issue.

Norrie disease and peripheral venous insufficiency

Norrie disease (ND) is a rare X linked recessive disorder in which affected males are blind at birth or in early infancy. About one third develop progressive sensorineural deafness. In addition, about 25% of affected males have varying degrees of developmental delay. The ocular findings include bilateral retinal folds, retinal detachment, vitreous haemorrhage, and bilateral retrolental masses consisting of haemorrhagic vascular and glial tissue (vitreoretinal dysplasia).

Histopathological examination of the eyes of an 11 week foetus with ND showed no evidence of primary neuroectodermal maldevelopment of the retina, suggesting that later disordered retinal vascular development may be a more likely disease mechanism.¹

More than 100 different mutations of the ND gene, *NDP*, have been identified.² Germ line mutations in *NDP* have also been identified in X linked familial exudative vitreoretinopathy (FEVR) and in retinopathy of prematurity (ROP). Somatic *NDP* mutations have been implicated in retinal telangiectasis (Coats disease). These findings suggest a role for the Norrie protein in normal retinal angiogenesis. The reported association of ND with peripheral vascular disease in affected males in a large Costa Rican pedigree,³ suggests that *NDP* may also play a role in non-ocular angiogenesis.

We present the second report of Norrie disease associated with peripheral vascular insufficiency, further supporting an angiogenic role for *NDP*.

Case report

A 53 year old man with bilateral congenital glaucoma and vitreoretinal dysplasia underwent ophthalmological review, peripheral vascular examination, and molecular genetic testing. He complained of poor vision since birth. He had undergone an enucleation of his right eye in young adulthood secondary to uncontrolled glaucoma resulting in intractable pain. Vision was hand movement. Anterior segment examination revealed Haab's striae, a shallow anterior chamber

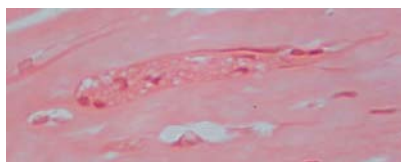


Figure 1 High power photomicrograph of corneal stroma showing a distinct, enlarged nerve bundle.

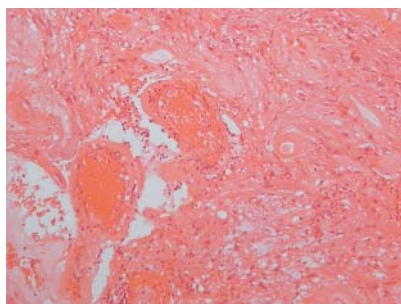


Figure 2 Medium power photomicrograph of markedly disorganised retina with loss of normal architectural features and intense gliosis. Prominent vessels with hyaline walls are present.

and drainage angle dysgenesis. Marked retinal atrophy and optic nerve head calcified drusen had been noted in his left eye before the development of a dense cataract.

He had no evidence of mental retardation. He had sensorineural deafness and had suffered with bilateral lower leg ulceration secondary to peripheral venous insufficiency for over 30 years, necessitating a varicose vein operation at the age of 19 years. Following surgery he has worn support stockings.

A histopathological study of his right eye revealed hypertrophy of corneal nerves (fig 1), a finding which has not been previously reported in association with ND. The ciliary body was seen to be drawn into a preretinal fibrous band at its posterior limit; while the retina had lost its normal architecture and was severely gliotic with cysts and extensive compact lamellar bone formation (fig 2).

The association of congenital glaucoma, vitreoretinal dysplasia, and sensorineural deafness in this male patient raised the possibility of ND. Mutation screening of *NDP* revealed a two base pair deletion in exon 2, resulting in a stop codon and truncation, thereby confirming the clinical suspicion of ND. His two affected maternal uncles were also found to have ND associated with peripheral venous insufficiency and lower leg ulceration.

Comment

These cases represent further evidence of a potential role of *NDP* in vascular development. Mutations in *NDP* have been reported

in several retinal disorders which are characterised by vascular abnormalities, including Coats disease, Stage 5 ROP, and X linked FEVR, suggesting that the protein product of *NDP*, Norrin, may be involved in normal retinal angiogenesis. The association of ND with peripheral venous insufficiency seen in the family reported here and in the Costa Rican pedigree³ suggest that Norrin may also play a role in extraocular angiogenesis.

Further light has been shed on the possible roles of Norrin with the development of an *NDP* knockout mouse model.^{4,5} The retinal vasculature is abnormal by postnatal day 9, with abnormal vessels in the inner retina and few vessels in the outer retina.⁴ The main vasculature of the cochlea, at the stria vascularis, is also abnormal, with eventual loss of two thirds of the vessels. It was therefore proposed that one of the principal functions of Norrin in the ear is to regulate the interaction of the cochlea with its vasculature—further supportive evidence of an important angiogenic role for the Norrie gene.

We present the second report of Norrie disease associated with peripheral vascular disease. This association suggests that *NDP* has an important role in angiogenesis in the eye and other non-ocular tissues.

Acknowledgements

We are grateful to the patients who kindly agreed to take part in this study. The mutation analysis was kindly undertaken in the Massachusetts General Hospital Neurogenetics DNA Diagnostic Laboratory (Director: Katherine B Sims MD).

M Michaelides, P J Luthert, A T Moore

Institute of Ophthalmology, University College London, London, UK

M Michaelides, R Cooling, A T Moore

Moorfields Eye Hospital, London, UK

H Firth

Department of Medical Genetics, Addenbrooke's Hospital, Cambridge, UK

Correspondence to: Mr M Michaelides, Institute of Ophthalmology, University College London, 11-43 Bath Street, London EC1V 9EL, UK; michel.michaelides@ucl.ac.uk

Accepted 23 March 2004

References

- 1 **Parsons MA**, Curtis D, Blank CE, *et al*. The ocular pathology of Norrie disease in a fetus of 11 weeks' gestational age. *Graefes Arch Clin Exp Ophthalmol* 1992;**230**:248-51.
- 2 **Black G**, Redmond RM. The molecular biology of Norrie's disease. *Eye* 1994;**8**:491-6.
- 3 **Rehm HL**, Gutierrez-Espeleta GA, Garcia R, *et al*. Norrie disease gene mutation in a large Costa Rican kindred with a novel phenotype including venous insufficiency. *Hum Mutat* 1997;**9**:402-8.
- 4 **Richter M**, Gottanka J, May CA, *et al*. Retinal vasculature changes in Norrie disease mice. *Invest Ophthalmol Vis Sci* 1998;**39**:2450-7.
- 5 **Rehm HL**, Zhang DS, Brown MC, *et al*. Vascular defects and sensorineural deafness in a mouse model of Norrie disease. *J Neurosci* 2002;**22**:4286-92.

Count and size of macular drusen correlated with the parafoveal annular reflex

Age related macular degeneration is one of the most frequently occurring reasons for decreased vision in the elderly population in Western countries.¹ It is divided in a non-exudative form with formation of drusen of the retinal pigment epithelium, and the exudative form with subfoveal chorioretinal neovascularisation and subretinal exudation. Since the subretinal alterations typical for age related macular degeneration may lead to a change in the superficial contour of the retina, it was the aim of this study to evaluate whether the visibility of the macular wall reflex depends on the presence and size of macular drusen as part of age related macular degeneration.

The study included 47 rhesus monkey (*Macaca mulatta*) (77 eyes) for which 60° colour fundus photographs were obtained. Only fundus photographs with the central fundus region fully illuminated were evaluated. The entire study group was divided into eyes of monkeys with unilateral experimental glaucoma (n=36 eyes) or experimental temporary unilateral occlusion of the central retinal artery (n=18), and normal eyes (n=23). The detectability of the parafoveal annular reflex was assessed using a score ranging between "0" for "no parafoveal annular reflex detectable" to "3" for "clear detectability of the parafoveal annular reflex" (figs 1, 2). The reproducibility of the semi-quantitative assessment of the parafoveal annular reflex had been determined in a previous study.² The coefficient of variation for the re-assessment of the ophthalmoscopic detectability of the parafoveal annular reflex was 0.08. The degree of age related macular degeneration was evaluated by counting the number of drusen, separately in the foveal region and in the extrafoveal region within the temporal vascular arcade. The mean size of the drusen was graded into three grades: "1" for very small (30 µm or less) and "3" for very large (larger than 100 µm). The possibility to grade the severity of age related macular degeneration on fundus photographs has already been described in detail previously.³ For assessment of the visibility of the retinal nerve fibre layer, the fundus was divided into eight sectors: temporal inferior, temporal horizontal, temporal superior, superior, nasal superior, nasal horizontal, nasal inferior, and inferior. In each sector, the visibility of the retinal nerve fibre bundles was estimated using a subjective grading ranging from "0" for "no fibre bundles detectable" to "8" for "abundant nerve fibre bundles visible." The technique has already been described in detail.⁴ All eyes included in this study had not undergone any experimental procedure. The study design complied with the National Institutes of Health's as well as the University of Iowa's institutional guidelines for the care and use of laboratory animals, and guidelines of ARVO. All experimental procedures and the fundus photography were performed at Iowa City.

In an univariate statistical analysis, the detectability of the macular wall reflex was significantly and negatively correlated with the number and total area of macular drusen (p=0.05), score of the visibility of the retinal nerve fibre layer as a whole and especially in the temporal horizontal fundus region (p<0.001), and age (p<0.001). A multiple

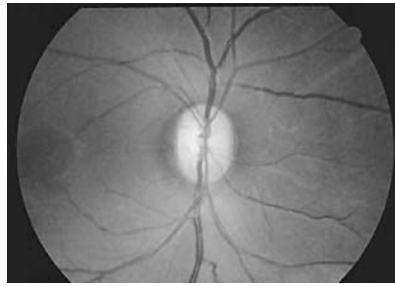

Figure 1 Fundus photograph of a monkey with clearly visible macular annular reflex in an eye without macular drusen and good visibility of the retinal nerve fibre layer.

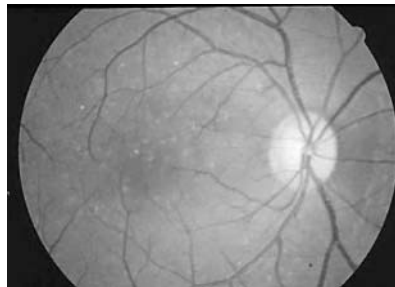


Figure 2 Fundus photograph of a monkey without detectable macular annular reflex in an eye with multiple macular drusen.

linear regression analysis confirmed that the ophthalmoscopic visibility of the macular annular reflex was significantly and negatively correlated with the number and total area of the drusen in the foveal region (p<0.001), visibility of the retinal nerve fibre layer in the temporal fundus region (p<0.001), and age (p=0.01).

The results suggest that the detectability of the macular annular reflex depends on presence and amount of non-exudative age related macular degeneration. It is parallel to other studies in which the visibility of the macular annular reflex decreased with increasing optic nerve damage, presumably because the loss of optic nerve fibres and retinal ganglion cells decreased the height of the macular annular wall and because of that, its ophthalmoscopic visibility.^{2,5} From a clinical point of view, it may suggest that examination of the macular annular reflex may be useful in screening patients for age related macular degeneration. The presence of the macular annular reflex may be taken as hint for the anatomic integrity of the fovea.

U Vossmerbaeumer, J B Jonas

Department of Ophthalmology, Mannheim Medical School, Ruprecht-Karls-University of Heidelberg, Germany

S S Hayreh

Departments of Ophthalmology and Visual Sciences, College of Medicine, University of Iowa, Iowa City, IA 52242, USA

Correspondence to: Dr U Vossmerbaeumer, Universitäts-Augenklinik, Theodor-Kutzer-Ufer 1-3, D-68167 Mannheim, Germany; urs.vossmerbaeumer@augen.ma.uni-heidelberg.de

doi: 10.1136/bjo.2004.043752

Accepted for publication 10 February 2004

Supported by grant EY-1576 from the US National Institutes of Health, in part by unrestricted grants from Research to Prevent Blindness, Inc, New York, USA.

References

- 1 Vingerling JR, Dielemans I, Hofman A, *et al*. The prevalence of age-related maculopathy in the Rotterdam Study. *Ophthalmology* 1995;**102**:205-10.
- 2 Hayreh SS, Jonas JB. Ophthalmoscopic detectability of the parafoveal annular reflex in the evaluation of the optic nerve. An experimental study in rhesus monkeys. *Ophthalmology* 2000;**107**:1009-14.
- 3 Kirkpatrick JN, Spencer T, Manivannan A, *et al*. Quantitative image analysis of macular drusen from fundus photographs and scanning laser ophthalmoscope images. *Eye* 1995;**9**:48-55.
- 4 Jonas JB, Hayreh SS. Influence of experimental chronic high-pressure glaucoma on age-related macular degeneration in rhesus monkeys. *Invest Ophthalmol Vis Sci* 2000;**41**:2972-7.
- 5 Safran AB, Lupolover Y, Berney J. Macular reflexes in optic atrophy. *Am J Ophthalmol* 1984;**98**:494-8.

Spontaneous bilateral giant tears of the retinal pigment epithelium

In 1981, Hoskin *et al*¹ described retinal pigment epithelial tears as a newly recognised severe complication of pigment epithelial detachment. Retinal pigment epithelial tears, which may occur either spontaneously or after laser photocoagulation to treat pigment epithelial detachment and choroidal neovascularisation (CNV) in diseases such as age related macular degeneration (AMD), usually cause sudden visual loss at the time of tearing. We report a case of spontaneous bilateral giant tears of the retinal pigment epithelium (RPE).

Case report

A 79 year old woman was referred on 18 January 2002, because of sudden visual loss in the left eye of 2 weeks' duration. In October 2001, the patient had undergone bilateral phacoemulsification and lens implantation by her local ophthalmologist. She had no apparent complications post-operatively, and the postoperative visual acuity (VA) was 20/250 in the right eye and 20/20 in the left eye; however, she noticed sudden decreased vision in the left eye on 3 January 2002, and visited the local ophthalmologist 5 days later.

When she presented to our hospital, her VA was 20/200 in right eye and hand movements in the left eye. The intraocular pressure was 18 mm Hg in the right eye and 19 mm Hg in the left eye. The external eye examination, pupillary responses, and results of slit lamp examinations were normal in both eyes except for poor mydriasis. Intraocular lenses were fixed in the capsular bag in both eyes. Results of fundus examination showed bilateral widespread pigment epithelial detachments overlying areas of bare choroid, which measured 7×8 disc diameters in the right eye and 9×10 disc diameters in the left eye, and adjacent sheets of retracted and rolled RPE (fig 1). A fluorescein angiogram of the right eye demonstrated hyperfluorescence of the denuded choroid in the early phase, which lightened slightly in the late phase, that blocked fluorescence corresponding to the retracted RPE, and appeared to have cystoid macular oedema (figs 2, 3). A fluorescein angiogram of the left eye disclosed persistent intense hyperfluorescence of the exposed

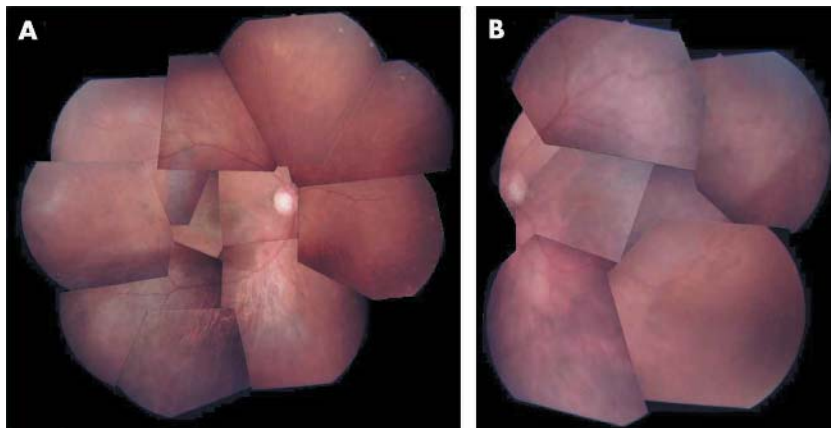


Figure 1 (A) Composite fundus photograph of the right eye. (B) Composite fundus photograph of the left eye. Widespread pigment epithelial detachments overlay areas of bare choroid and adjacent sheets of rolled retinal pigment epithelium.

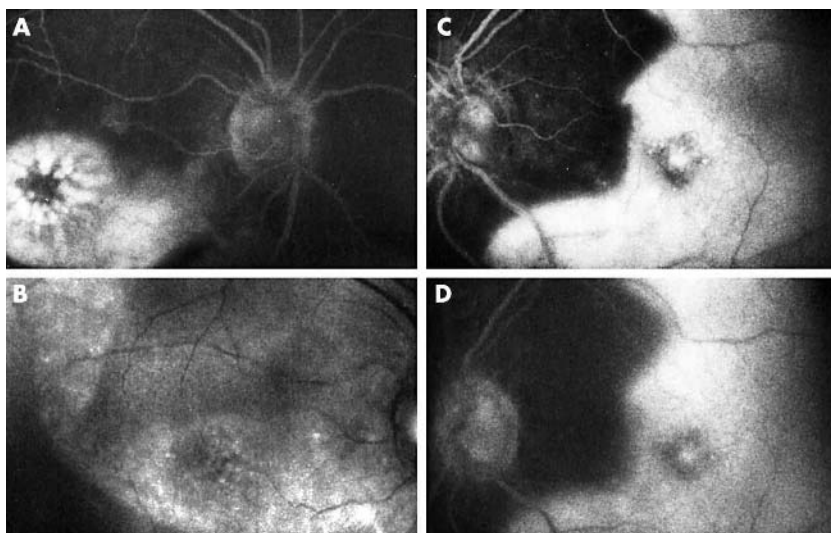


Figure 2 (A) Fluorescein angiogram (FA) of right eye in the early phase. (B) FA of the right eye in the late phase. (C) FA of the left eye in the early phase. (D) FA of the left eye in the late phase. The angiogram of the right eye shows hyperfluorescence of the denuded choroid in the early phase, which lightened slightly in the late phase. The angiogram of the left eye shows persistent intense hyperfluorescence of the choroid.

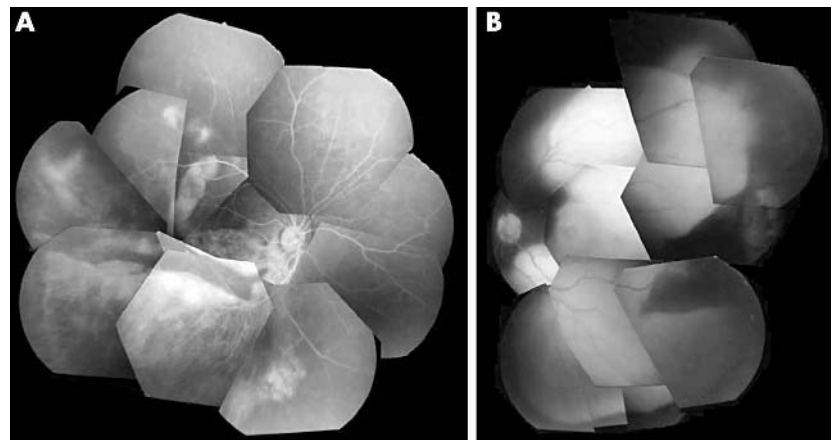


Figure 3 (A) Composite fluorescein angiogram (FA) of the right eye. (B) Composite FA of the left eye. Persistent blocked fluorescence corresponds to the rolled RPE.

choroid, blocked fluorescence consistent with the rolled RPE (figs 2, 3). An indocyanine green (ICG) angiogram of the left eye revealed fluorescence of the large choroidal vessels in the area of the bare choroid and no obvious evidence of CNV. Fundus examination using scanning laser ophthalmoscopy with a diode laser (780 nm) sharply defined the folded RPE (fig 4). From these findings, we diagnosed bilateral tears of the RPE.

Comment

In this case, the fluorescein angiogram showed ill defined light hyperfluorescence in the right eye and well defined intense hyperfluorescence in the left eye, corresponding to the region of the exposed choroid and pigment epithelial detachments. The ICG angiogram of the left eye demonstrated persistent light hyperfluorescence consistent with the bare choroid. On fluorescein angiogram, intense hyperfluorescence was reported in an area of exposed choroid when a RPE tear occurred, and over time the edges were not clearly defined and the fluorescence lightens because of proliferation and infiltration of the pigment epithelial cells on the bare choroid along the margin of the tear.² In an ICG angiogram, it then was reported that hyperfluorescence of an area of exposed choroid in the late phase indicates that the tear may be fresh because of tissue staining in Bruch’s membrane by leakage from the choriocapillaris.³ Accordingly, we identified the RPE tears in our patient as an old tear in the right eye and a fresh one in the left eye.

Many reports have been published that a RPE tear is caused by photocoagulation to treat CNV and pigment epithelial detachment in diseases such as AMD because scarring and retraction of the RPE by photocoagulation may result in tangential tractional forces along the RPE that weaken it.¹ Lois *et al*⁴ reported that low intraocular pressure after trabeculectomy causes a RPE tear because of mechanical stress between Bruch’s membrane and the RPE following increased subretinal fluids caused by leakage from the choriocapillaris. There have been no reports that cataract surgery causes a RPE tear, but the possibility that it caused the tear in the left eye in this case cannot be completely excluded. However, in our case, we thought that there was little relation between cataract surgery and the tear, because no complications occurred during surgery and intraocular inflammation after surgery was unremarkable. Although we considered that the RPE in our patient might be weak by nature, there was nothing in the family history or the presence of systematic diseases that affected the connective tissue.

In the present case, the tears measured 7×8 disc diameters in the right eye and 9×10 disc diameters in the left eye. Although the large size of the pigment epithelial detachment might be important in the pathogenesis of RPE tears,⁵ most tears in previous reports were no more than about 5 disc diameters. Accordingly, the tears in this case were much larger compared with previous reports and also bilateral.

In this case, fundus examination using scanning laser ophthalmoscopy with a diode laser defined the folded RPE more sharply than any other examination. It may be useful to observe the rolling shape of the RPE. In conclusion, the possibility that cataract surgery caused the RPE tear in the left eye cannot be completely excluded, but this case

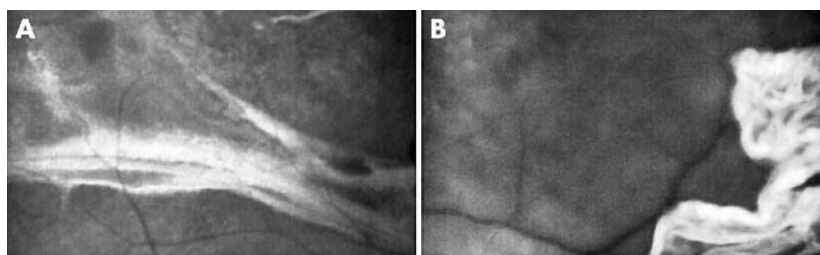


Figure 4 (A) Fundus photograph of the right eye using scanning laser ophthalmoscopy with a diode laser. (B) Fundus photograph of the left eye using scanning laser ophthalmoscopy with a diode laser. The retracted RPE is well defined.

represented a rare report of spontaneous bilateral giant tears.

N Izumi, F Mori, S Ishiko, N Kitaya, T Hikichi, H Mizumoto, A Yoshida

Department of Ophthalmology, Asahikawa Medical College, Asahikawa, Japan

Correspondence to: F Mori, MD, PhD, Department of Ophthalmology, Asahikawa Medical College, Midorigaoka-Higashi 2-1-1, Asahikawa 078-8510, Japan; morinao@d5.dion.ne.jp

doi: 10.1136/bjo.2004.043729

Accepted for publication 17 March 2004

References

- Hoskin A, Bird C, Sehmi K. Tears of detached retinal pigment epithelium. *Br J Ophthalmol* 1981;**65**:417-22.
- Chuang EL, Bird AC. Repair after tears of the retinal pigment epithelium. *Eye* 1988;**2**:106-13.
- Arroyo JG, Schatz H, McDonald R, et al. Indocyanine green videoangiography after acute retinal pigment epithelial tears in age-related macular degeneration. *Am J Ophthalmol* 1997;**123**:377-85.
- Lois N, Sehmi KS, Hykin PG. Giant retinal pigment epithelial tear after trabeculectomy. *Arch Ophthalmol* 1999;**117**:546-7.
- Cantrill HL, Ramsay RC, Knobloch WH. Rips in the pigment epithelium. *Arch Ophthalmol* 1983;**101**:1074-9.

Ocular findings as a presenting sign of hydroa vacciniforme

Hydroa vacciniforme (HV) is an unusual photosensitivity disease of unknown aetiology which starts in childhood and is characterised by vesiculopapular eruptions on the exposed area of the body.^{1,2} Ocular manifestations of this disease are uncommon but can include conjunctivitis, vesicular eruptions of the conjunctiva and cornea that resemble phlyctenular keratoconjunctivitis,³ corneal infiltration with vascularisation,⁴ and keratouveitis.^{5,6} However, no cases of HV have been reported in the ophthalmic literature in over 40 years, and in contrast with previously reported cases, to our knowledge, this is the first case of a patient with HV who presented initially only with ocular findings.

Case report

A 6 year old Indian boy was referred to the Proctor Foundation with a 3 month history of recurrent, self resolving episodes of redness, pain, and photophobia in his right eye associated with a "bump" on his temporal conjunctiva. Aside from an episode of "cold sores" on his lips 2 weeks before his presentation, he had no cutaneous complaints.

On examination, visual acuity was 20/20 right eye and 20/25 left eye. The conjunctiva of the right eye was injected temporally, and the inferotemporal cornea had a faint anterior and diffuse deep stromal haze with vessels, consistent with an interstitial keratitis. The patient was given a presumed diagnosis of phlyctenular keratoconjunctivitis and treated with topical corticosteroid drops. Three months later, his symptoms returned in association with a vesicular crusting reaction of his lower lip and upper ears. A conjunctival scraping was obtained for polymerase chain reaction testing, and a purified protein derivative (PPD) and chest x ray were ordered to rule out herpes simplex virus and *Mycobacterium tuberculosis*, respectively, as causative aetiologies of the patient's findings. The tests yielded negative results.

Twenty three months after his initial presentation, the patient returned with an acute, unilateral, granulomatous, anterior uveitis in the left eye and vesicular crusting of his lips and upper ears. The uveitis responded to treatment with topical corticosteroid drops. Serological testing for varicella zoster virus IgG, toxoplasma IgG, erythrocyte sedimentation rate (ESR), angiotensin converting enzyme (ACE), lysozyme, rapid

plasma reagin (RPR), and fluorescent treponema antibody absorption (FTA-abs) test were all negative.

Six months later, the patient returned with red eyes and vesicular skin lesions of his ears (fig 1A), lips (fig 1B), arms, and fingers. Slit lamp examination revealed a sclerokeratitis temporally in both eyes (fig 1C and D). Both corneas were slightly oedematous temporally with deep stromal vessels. There was also a mild iritis in the left eye. Oral prednisone was started to treat a possible systemic inflammatory cause for his sclerokeratitis, and a papulovesicular lesion of the ear was biopsied. Serological testing for ANA, ANCA, anti-SNA, anti-SS-A, anti-RNP, and anti-Smith was performed; all results were negative.

Histopathological examination of the biopsied lesion revealed an epidermotropic lymphoid infiltrate with focal epithelial necrosis consistent with the diagnosis of hydroa vacciniforme (fig 2A). The infiltrate was of T cell lineage, confirmed by immunoperoxidase staining, with diffuse expression of CD3 (fig 2B); scattered CD8 positive lymphocytes were present (fig 2C). In situ hybridisation identified the presence of Epstein-Barr virus encoded small nuclear RNA in a minority (~10%) of the lymphocytes present, suggesting the diagnosis of a hydroa vacciniforme-like lymphoproliferative disorder (fig 2D). Genotypic analysis via a polymerase chain reaction method revealed no evidence of a clonal rearrangement of T cell receptor genes.

The patient was treated for hydroa vacciniforme with oral prednisone, ganciclovir, and precautions about ultraviolet light exposure. Since starting therapy for hydroa vacciniforme, he has not had any flares of ocular inflammation, and he has only suffered one episode of dermal inflammation. At the last follow up visit, 40 months after his initial presentation, the patient demonstrated no ocular inflammation, and his best spectacle corrected visual acuity was 20/20 both eyes. He is currently being maintained on ganciclovir therapy. The patient's parents

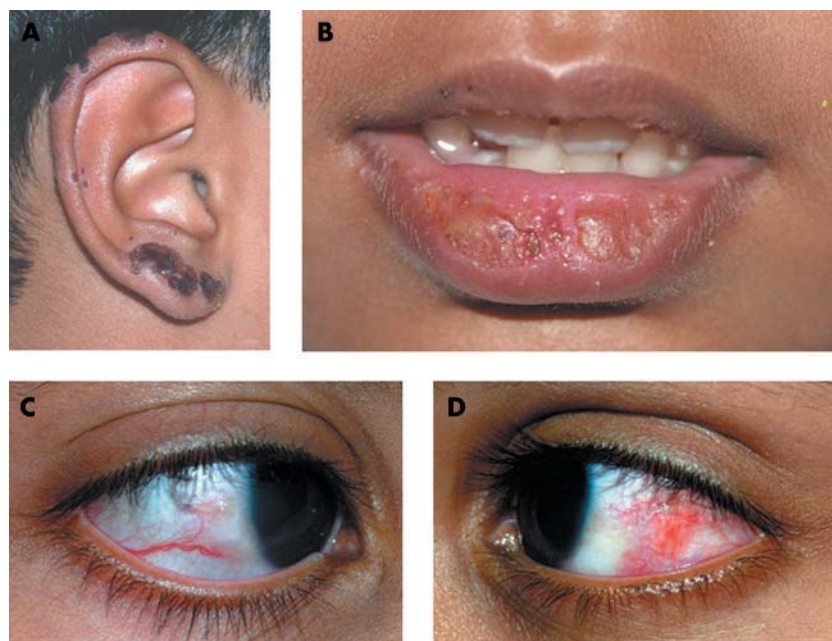


Figure 1 Hydroa vacciniforme lesions on the left ear (A) and lower lip (B). Sclerokeratitis temporally in right (C) and left (D) eyes.

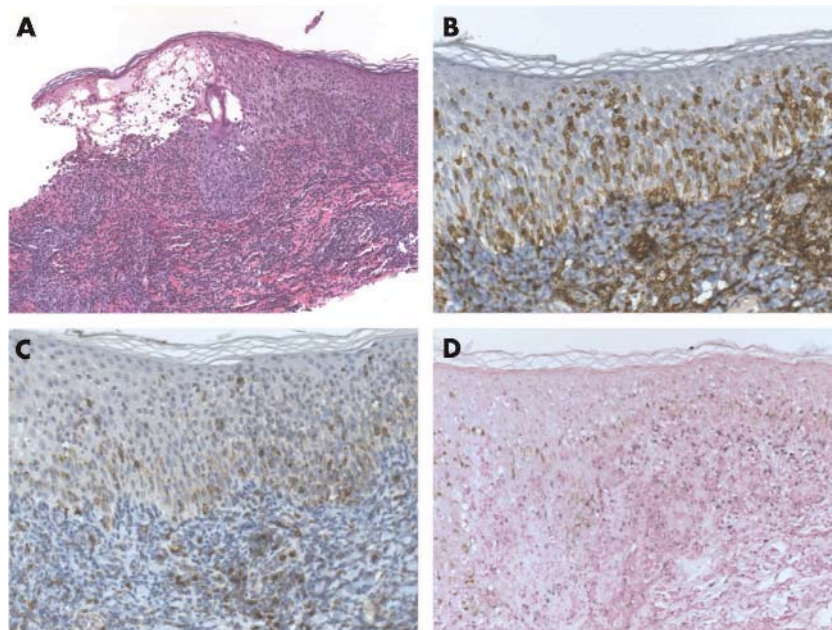


Figure 2 (A) Dense infiltration of lymphoid cells with epidermal necrosis consistent with hydroa vacciniforme (haematoxylin and eosin, original magnification $\times 40$). (B) Immunoperoxidase staining demonstrating diffuse expression of CD3 (original magnification $\times 100$). (C) Immunoperoxidase staining demonstrating scattered staining for CD8 (original magnification $\times 100$). The immunoperoxidase chromagen in (B) and (C) is diaminobenzidine (DAB) with a haematoxylin counterstain. Appropriate positive and negative control staining was also observed (data not shown). (D) In situ hybridisation demonstrating the presence of Epstein-Barr virus encoded small nuclear RNA transcripts in a minority of the lymphocytes (original magnification $\times 100$). The antisense probe in this preparation shows dark black nuclear staining in positive cells, while the sense (control) probe demonstrated no nuclear labelling (data not shown). The counterstain is nuclear fast red.

deny recalling a history of Epstein-Barr virus (EBV) infection in the past.

Comment

Hydroa vacciniforme was initially described by Bazin in 1862,⁷ and the estimated prevalence of this disease is at least 0.34 cases per 100 000.⁸ Patients typically present with vesicles or bullae on an erythematous base that occur primarily on light exposed body areas and develop within several days of sun exposure. With time, these lesions become progressively necrotic and ultimately heal with varioliform scars.⁹

Although laboratory testing has revealed no haematological, biochemical, or immunological abnormalities in affected patients, recent investigations have found that the cutaneous lesions of hydroa vacciniforme are associated with latent infection with the EBV,^{1 2 10} and in situ hybridisation confirmed the presence of EBV RNA synthesis in our patient's skin lesions.

Although many dermatologists recognise that EBV associated hydroa vacciniforme-like skin lesions may have malignant potential, it is not yet clear whether this disease is inflammatory or neoplastic.¹⁰ Iwatsuki and associates² have recently reported that three of their six patients with atypical hydroa vacciniforme progressed to overt haematological neoplasms 2–14 years after onset of their cutaneous findings. Chen and associates¹¹ subsequently reported a patient with a CD8+ cutaneous T cell lymphoma that presented with, rather than progressed from, hydroa vacciniforme-like skin lesions. Together, these reports suggest that hydroa

vacciniforme may not only progress from a smouldering stage to a lymphoid malignancy, but that it could itself be a lymphoid neoplasm. Therefore, our patient may be at increased risk for the development of an EBV related lymphoma, for which he will be monitored closely.

Ocular involvement secondary to hydroa vacciniforme is uncommon and typically occurs coincidentally with an outbreak on the face.³ Occasionally, ocular findings occur at a later time than cutaneous findings, which may be the result of the protection afforded by the eyelids.⁴ Although his later ocular findings occurred simultaneously with facial lesions of hydroa vacciniforme, in the very beginning, our patient manifested only ocular symptoms and findings, including an interstitial keratitis. To our knowledge, this is the first case of hydroa vacciniforme in which ocular findings preceded the onset of cutaneous lesions. Therefore, based on our report, the differential diagnosis for interstitial keratitis in young children should include hydroa vacciniforme.

B H Jeng, T P Margolis

Francis I Proctor Foundation and the Department of Ophthalmology, University of California San Francisco, San Francisco, CA, USA

N S Chandra

Department of Ophthalmology, Kaiser Permanente Medical Center, Martinez, CA, USA

T H McCalmont

The UCSF Dermatopathology Service, Departments of Dermatology and Pathology, University of California San Francisco, San Francisco, CA, USA

Correspondence to: Todd P Margolis, MD, PhD, Francis I Proctor Foundation, University of California, San Francisco, 95 Kirkham Street, San Francisco, CA 94143, USA; tpms@itsa.ucsf.edu

doi: 10.1136/bjo.2004.043125

Accepted for publication 22 March 2004

Supported by the Heed Ophthalmic Foundation Fellowship, Cleveland, Ohio (BHJ); Research to Prevent Blindness, New York, New York (TPM).

References

- Iwatsuki K, Xu Z, Takata M, *et al*. The association of latent Epstein-Barr virus infection with hydroa vacciniforme. *Br J Dermatol* 1999;**140**:715–21.
- Iwatsuki K, Ohtsuka M, Akiba H, *et al*. Atypical hydroa vacciniforme in childhood: from a smouldering stage to Epstein-Barr virus-associated lymphoid malignancy. *J Am Acad Dermatol* 1999;**40**:283–4.
- Stokes WH. Ocular manifestations of hydroa vacciniforme. *Arch Ophthalmol* 1940;**23**:1131–45.
- Crews SJ. Hydroa vacciniforme affecting the eye. *Br J Ophthalmol* 1959;**43**:629–34.
- Wisuthsarewong W, Leenutaphong V, Viravan S. Hydroa vacciniforme with ocular involvement. *J Med Assoc Thai* 1998;**81**:807–10.
- Bennion SD, Johnson C, Weston WL. Hydroa vacciniforme with inflammatory keratitis and secondary anterior uveitis. *Pediatr Dermatol* 1987;**4**:320–4.
- Bazin E. *Lesions theoriques et cliniques sur les affections generiques de la place*. Paris: Delabrage, 1862; vol 1:132.
- Gupta G, Man I, Kemmett D. Hydroa vacciniforme: a clinical and follow-up study of 17 cases. *J Am Acad Dermatol* 2000;**42**:208–13.
- Bickers DR, Demar LK, DeLeo V, *et al*. Hydroa vacciniforme. *Arch Dermatol* 1978;**114**:1193–6.
- Cho K-H, Kim C-W, Heo D-S, *et al*. Epstein-Barr virus-associated peripheral T-cell lymphoma in adults with hydroa vacciniforme-like lesions. *Clin Exp Dermatol* 2001;**26**:242–7.
- Chen H-H, Hsiao C-H, Chiu H-C. Hydroa vacciniforme-like primary cutaneous CD8-positive T-cell lymphoma. *Br J Dermatol* 2002;**147**:587–91.

An unusual strategy for fixation in a patient with bilateral advanced age related macular disease

Patients with central scotomas must use peripheral retina in place of the damaged fovea. Many patients exhibit a "preferred" retinal locus (PRL) for fixation.^{1–4} Previous studies have only described monocular fixation behaviour. This case report describes a patient who successfully uses a novel strategy of observing with two non-corresponding PRLs in different eyes for different tasks.

Case report

A 78 year man attended the clinic with a 7 year history of exudative age related macular disease (AMD) in the right eye and an 18 month history of exudative AMD in the left eye. The patient reported using his right eye for distance vision and his left eye for reading. He covered the contralateral eye for both tasks. He has no history of amblyopia. As a young man, the patient used his right eye for rifle shooting. He is right handed.

On fundus examination, both eyes show disciform scars at the macula, with a larger lesion in the right eye. Best corrected visual acuity was 0.92 logMAR (6/48) in the right eye and 0.60 logMAR (6/24) in the left. Contrast sensitivity, measured using a Pelli-Robson chart, was 1.05 log units in each eye.

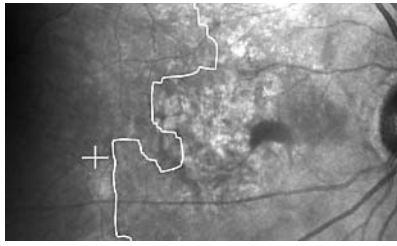


Figure 1 Scanning laser ophthalmoscope image of the right eye. White cross shows fixation centre, white line shows perimeter of dense scotoma.

With optical correction (using hyperocular lenses) reading speed was 85 words/minute, using the left eye. "Fluent" reading can be defined as being faster than 80 words/minute.³

Fixation behaviour was measured for each eye using a scanning laser ophthalmoscope (SLO). The patient was asked to observe a cross-shaped target of height 2.5° for a period of 10 seconds. Fixation stability was assessed during this task by calculation of the bivariate contour ellipse area (BCEA).⁶ The BCEA is a measure of the area of an ellipse which encompasses a given proportion of fixation points (in this case, 68%). Smaller BCEA values correspond to more precise fixation. BCEA values were 14 900 minutes of arc² for the right eye and 5360 minutes of arc² for the left. BCEA values for normally sighted observers are typically around 450 minutes of arc².⁷

The size of the dense scotoma was measured using SLO microperimetry, with stimuli being Goldmann III size targets of 200 cd/m² presented for 200 ms.⁸ Digitised SLO images were recorded (figs 1 and 2).

Comment

The left eye had better distance visual acuity, a smaller dense scotoma and a less peripheral, more stable PRL than the right eye. It is unsurprising that this patient uses this eye for reading. Unexpectedly, he found his right eye (which has poorer distance visual acuity) to be of more use for navigation and other distance tasks. Such visual behaviour can not be explained on the basis of the retinal lesions. It is assumed that the previous dominance of this patient's right eye must play a part in determining which eye is preferred for distance vision. Examination of the SLO images shows a large area of healthy retina adjacent to the PRL in the right

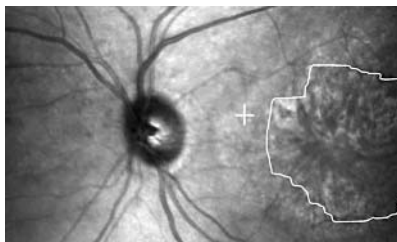

Figure 2 Scanning laser ophthalmoscope image of the left eye. White cross shows fixation centre, white line shows perimeter of dense scotoma.

eye whereas in the left eye the PRL is constrained by the optic disc and the macular lesion.

Although the PRLs are in the same quadrant of retina in each eye, the PRL in the right eye is further away from the previously normal fovea than that in the left. The fact that the patient covers his better seeing left eye while looking to the distance reinforces the fact that these loci are not in corresponding retinal locations. On detailed questioning, the patient cited the greatest difficulty with his vision being for wiring a plug or setting a combination lock on a suitcase: tasks requiring good binocular function.

This patient's behaviour suggests that for distance vision, a large "window" of functioning retina is of more use than a smaller region of retina with better visual acuity. It also indicates that it is possible to use different, non-corresponding preferred retinal loci in each eye for different tasks. It is not straightforward to predict which retinal location, or even which eye, patients will use from clinical features alone.

This patient has selected different PRLs for near and distance vision to partially ameliorate the symptoms of his macular disease. Although unable to perform detailed binocular tasks, he is able to navigate successfully, to read correspondence, and to remain independent.

Acknowledgements

The authors thank Jenni Turner for referring the patient to us and the patient for his enthusiastic cooperation in the writing of this case report. MDC is supported by Guide Dogs for the Blind Association ophthalmic research grant 2000–29a. SAK is supported by a Colin Kunkler Memorial Fellowship.

M D Crossland, S A Kabanarou, G S Rubin

Institute of Ophthalmology, University College London and Moorfields Eye Hospital NHS Trust, London, UK

Correspondence to: Dr M D Crossland, Institute of Ophthalmology, 11–43 Bath Street, London EC1V 9EL, UK; m.crossland@ucl.ac.uk

doi: 10.1136/bjo.2004.046573

Accepted for publication 16 April 2004

References

- 1 Von Noorden GK, Mackensen G. Phenomenology of eccentric fixation. *Am J Ophthalmol* 1962;**53**:642–61.
- 2 White JM, Bedell HE. The oculomotor reference in humans with bilateral macular disease. *Invest Ophthalmol Vis Sci* 1990;**31**:1149–61.
- 3 Fletcher DC, Schuchard RA, Watson G. Relative locations of macular scotomas near the PRL: effect on low vision reading. *J Rehabil Res Dev* 1999;**36**:356–64.
- 4 Timberlake GT, Mainster MA, Peli E, et al. Reading with a macular scotoma. I. Retinal location of scotoma and fixation area. *Invest Ophthalmol Vis Sci* 1986;**27**:1137–47.
- 5 Whittaker SG, Lovie-Kitchin J. Visual requirements for reading. *Optom Vis Sci* 1991;**70**:54–65.
- 6 Steinman RM. Effect of target size, luminance, and color on monocular fixation. *J Opt Soc Am* 1965;**55**:1158–65.
- 7 Crossland MD, Rubin GS. The use of an infrared eyetracker to measure fixation stability. *Optom Vis Sci* 2002;**79**:735–9.
- 8 Sunness JS, Bressler NM, Maguire MG. Scanning laser ophthalmoscopic analysis of the pattern of visual loss in age-related geographic atrophy of the macula. *Am J Ophthalmol* 1995;**119**:143–51.

MAILBOX

Potential complications of phakic IOLs

I read with interest the case report of Ashraff *et al.*,¹ where a posterior chamber phakic intraocular lens (PCPIOL) was used in a pseudophakic eye with axial myopia and pseudoexfoliation for the management of anisometropia. I would like to highlight a potential problem in such eyes: dislocation of PCPIOL into the vitreous cavity.

PCPIOLs are inserted blindly behind the iris and, depending on the design, allow their haptics to rest at the structures of the posterior chamber or float in it. Ultrasound biomicroscopy (UBM) identified haptic-zonules contact and lens rotation for the implantable contact lens (ICL)² and the phakic refractive lens (PRL),³ although these PCPIOLs are intended to fixate at the ciliary sulcus and float in the posterior chamber respectively. Because of this potential haptic-zonules contact and lens rotation of PCPIOLs the entire zonular apparatus should be intact and healthy.

Pseudoexfoliation is characterised by progressive zonular disruption and axial myopia by zonular weakness and both conditions may lead to zonular defects. Although phakodonesis and iridodonesis may point towards zonular insufficiency, those signs may be absent in a number of eyes with occult zonular defects as shown in UBM studies.⁴ Such zonular defects may result in spontaneous dislocation of the PCPIOL into the vitreous cavity. Two cases have been described already where PCPIOLs dislocated into the vitreous cavity through such defects. Kaya *et al.*⁵ reported a case of dislocation of a silicone PCPIOL into the vitreous cavity following mild head injury 3 weeks postoperatively in a highly myopic eye (–19 DS). Another case of dislocation of a myopic PRL into the vitreous cavity has been reported by the European Clinical Trial with PRL group (Philipson B. PRL (phakic posterior chamber IOL)—the 12 month results of the European clinical trial. Presented at the XXI Congress of the ESCRS-Munich 2003). I have recently reported a case of spontaneous dislocation of a PRL into the vitreous cavity in a young healthy female with high myopia 2 months postoperatively (spherical equivalent –19.5 D).⁶

The reported cases stress the importance of health and integrity of zonular apparatus in the long term stability of PCPIOLs. Since pseudoexfoliation is a progressive disease that may lead to progressive zonular disruption and spontaneous IOL-bag dislocation into the vitreous cavity even many years after cataract surgery,⁷ I think that PCPIOLs should not be used in pseudophakic eyes with pseudoexfoliation.

H Eleftheriadis

Southend General Hospital, UK; h.eleftheriadis@btinternet.com

doi: 10.1136/bjo.2004.045088

Accepted 19 February 2004

References

- 1 Ashraff NN, Kumar BV, Das A, et al. Correction of pseudophakic anisometropia in a patient with pseudoexfoliation using an implantable contact lens. *Br J Ophthalmol* 2004;**88**:309.

- 2 **Trindade F**, Pereira F, Cronemberger S. Ultrasound biomicroscopic imaging of posterior chamber phakic intraocular lens. *J Refract Surg* 1998;**14**:497–503.
- 3 **Garcia-Feijoo J**, Hernandez-Matamoros JL, Mendez-Hernandez C, *et al*. Ultrasound biomicroscopy of silicone posterior chamber phakic intraocular lens for myopia. *J Cataract Refract Surg* 2003;**29**:1932–9.
- 4 **McWhae JA**, Crichton AC, Rinke M. Ultrasound biomicroscopy for the assessment of zonules after ocular trauma. *Ophthalmology* 2003;**110**:1340–3.
- 5 **Kaya V**, Kevser MA, Yilmaz OF. Phakic posterior chamber plate intraocular lenses for high myopia. *J Refract Surg* 1999;**15**:580–5.
- 6 **Eleftheriadis H**, Amoros S, Bilbao R, *et al*. Spontaneous dislocation of a phakic refractive lens into the vitreous cavity. *J Cataract Refract Surg* (in press).
- 7 **Jehan FS**, Mamlis N, Crandall AS. Spontaneous late dislocation of intraocular lens within the capsular bag in pseudoexfoliation patients. *Ophthalmology* 2001;**108**:1727–31.

BOOK REVIEW

ABC of Eyes, 4th ed.

P T Khaw, P Shah, A R Elkington. London: BMJ Publishing Group, 2004, pp 93; £25. ISBN 0 7279 1659 9.

The *ABC of Eyes* by consultant ophthalmologist P Shah and professors P T Khaw and A R Elkington and is now one of the most well established introductory textbooks to ophthalmology. Using a symptom based approach that characterises the ABC series, this book comprehensively covers all of the most common complaints in ophthalmology. It owes its success to its renowned simplicity and straightforward explanations, which appeal to the wider audience of readers who are not experts in the field. The fourth edition has been fully updated with an accompanying CD-Rom for those who prefer e-books to printed ones. This new edition continues to describe the ABCs of eyes with superb accomplishment.

The contents of the book begin with an introductory chapter that takes the reader through history taking and examination techniques in ophthalmology, specifying what may be achieved without the use of specialised equipment and when to refer to a

specialist. The following chapters describe the diagnosis and management of essential topics like the red eye, trauma, glaucoma, squints, and cataracts. New chapters have been added to this fourth edition—on age related macular degeneration and the global impact of eye disease. Summary tables provide a quick and concise reference to the main text and tip boxes give useful hints that draw from the authors' wealth of clinical experience. Clinical signs are well illustrated by colour photographs. Complicated microsurgical techniques and physiological mechanisms are effectively explained using clear and understandable diagrams.

The main strength of the book is the authors' ability to describe complex concepts in simple accessible terms for the professional and the layperson. Since I first used this textbook as a medical student, each successive edition has been improved on and updated without any loss of clarity. This latest edition includes important recent advances in ophthalmology, such as photodynamic therapy for age related macular degeneration. With its comprehensive list of support organisations for those affected by visual impairment in the United Kingdom, this book is also a useful resource for practising ophthalmologists and the general public alike. The authors have also considered the global impact of visual impairment and blindness in their new chapter, a topic that is rapidly gaining increasing recognition with the World Health Organization's "Vision 2020: the right to sight" initiative to eliminate avoidable blindness by 2020. As a basic reference text to ophthalmology, there is isn't a topic left uncovered, but this is not a practical manual to help the layperson manage eye disease themselves. Instead, the authors rightly recommend referral to an eye specialist where appropriate.

I have no doubt that there will be future editions of the *ABC of Eyes* and that the book will continue to maintain its popularity. There is future scope in developing the accompanying CD into a more interactive tool—for example, as an aid to diagnosis.

Overall, this book deserves to be on the shelves of every junior doctor, GP, nurse, and member of the public with an interest in ophthalmology.

D Atan

Bristol Eye Hospital, Lower Maudlin Street,
Bristol BS1 2LX, UK;
denize.atan@bristol.ac.uk

NOTICES

4th International Congress on Autoimmunity

The 4th International Congress on Autoimmunity will take place 3–7 November 2004 in Budapest, Hungary. The deadline for the receipt of abstracts is 20 June 2004. Further details: Kenes International Global Congress Organisers and Association Management Services, 17 Rue du Cendrier, PO Box 1726, CH-1211 Geneva 1, Switzerland (tel: +41 22 908 0488; fax: +41 22 732 2850; email: autoim04@kenes.com; website: www.kenes.com/autoim2004).

Ophthalmic Anesthesia Society

The 18th Annual Meeting of the Ophthalmic Anesthesia Society will be held on 1 – 3 October 2004 in Chicago, USA. For further details: Ophthalmic Anesthesia Society (OAS), 793-A Foothill Blvd, PMB #119, San Luis Obispo, CA 93405 USA (tel: 001 805 534 0300; fax: 001 805 534 9030; email: info@eyeanesthesia.org; website: www.eyeanesthesia.org).

Glaucoma Society Silver Jubilee Meeting 2004

The Silver Jubilee Meeting and Dinner for the Glaucoma Society will be held on 3 December 2004 at the Royal College of Physicians in Regents Park, London. The meeting will take place between 8.30am and 5pm and the dinner will be held between 6.30pm and 10pm. For further information, please contact: Janet Flowers, Administrator, 29 Quarry Hill, Grays, Essex, RM17 5BT (tel: 01375 383172; e-mail: glausoc@ukeire.freeseve.co.uk).

Amsterdam Retina Debate

The Amsterdam Retina Debate will be held on 10 December 2004 at the Academic Medical Centre, Amsterdam, The Netherlands. For further information, please contact: Nicolaes Tulp Institute; tel: +31 20 566 8585; fax: +31 20 696 3228; email: retinadebate@amc.uva.nl



An unusual strategy for fixation in a patient with bilateral advanced age related macular disease

M D Crossland, S A Kabanarou and G S Rubin

Br J Ophthalmol 2004 88: 1479-1480

doi: 10.1136/bjo.2004.046573

Updated information and services can be found at:

<http://bjo.bmj.com/content/88/11/1479.full.html>

These include:

References

This article cites 8 articles, 2 of which can be accessed free at:

<http://bjo.bmj.com/content/88/11/1479.full.html#ref-list-1>

Article cited in:

<http://bjo.bmj.com/content/88/11/1479.full.html#related-urls>

Email alerting service

Receive free email alerts when new articles cite this article. Sign up in the box at the top right corner of the online article.

Notes

To request permissions go to:

<http://group.bmj.com/group/rights-licensing/permissions>

To order reprints go to:

<http://journals.bmj.com/cgi/reprintform>

To subscribe to BMJ go to:

<http://group.bmj.com/subscribe/>