

## SCIENTIFIC REPORT

## Multidrug resistant proteins: P-glycoprotein and lung resistance protein expression in retinoblastoma

S Krishnakumar, K Mallikarjuna, N Desai, A Muthialu, N Venkatesan, A Sundaram, V Khetan, M P Shanmugam

*Br J Ophthalmol* 2004;88:1521–1526. doi: 10.1136/bjo.2004.047928

**Background/aim:** Retinoblastoma is the commonest primary intraocular tumour in children. Chemotherapy now plays a big part in the treatment of these tumours. There is not much information about the role of the multidrug resistance proteins (MDR)—P-glycoprotein (P-gp) and vault protein lung resistance protein (LRP)—in retinoblastoma. The authors investigated the expression of P-gp and LRP in retinoblastoma and correlated them clinicopathologically.

**Methods:** Among 60 retinoblastomas, 40 tumours were not subjected to preoperative or postoperative chemotherapy and 20 tumours were subjected to postoperative chemotherapy. In this cohort 27 tumours had no invasion and 33 tumours had invasion of choroid, optic nerve, and orbit. P-gp and LRP expression were studied by immunohistochemistry. Immunoanalysis was done semiquantitatively.

**Results:** Among the 60 tumours P-gp was expressed in 23 (38%) tumours and LRP was expressed in 35 (58%). P-gp was expressed in 11/27 (40%) tumours with no invasion and in 12/33 (36%) tumours with invasion. LRP was expressed in 15/27 (55%) tumours with no invasion and in 20/33 (60%) tumours with invasion. Both P-gp and LRP were negative in three tumours with invasion, which had later developed bone marrow metastasis. There was no correlation between P-gp and LRP expression with invasion, differentiation and laterality of the tumours and response to treatment.

**Conclusion:** Retinoblastoma expresses P-gp and LRP intrinsically before chemotherapy and none of these proteins predicted the response to chemotherapy. Thus, further studies are needed to understand the significance of the expression of the P-gp and LRP proteins in retinoblastoma.

Retinoblastoma is the most common primary intraocular tumour in children. Primary chemoreduction is used for intraocular retinoblastoma and systemic chemotherapy is used following enucleation in patients with optic nerve and deep choroidal invasion, orbital extension, and metastatic disease.<sup>1</sup> Because most retinoblastomas showed an initial response to chemotherapy but eventually progressed, Chan and Galle<sup>2–6</sup> observed that retinoblastoma that failed chemotherapy expressed the multidrug resistance protein—P-glycoprotein (P-gp) and they suggested the use of a chemosensitiser ciclosporin A (CSA).<sup>6</sup> CSA theoretically blocked the multidrug resistant P-gp frequently found in retinoblastoma. They suggested that combining CSA with chemotherapy controls intraocular retinoblastoma without requiring radiation.<sup>7</sup> However others have not used CSA in the chemotherapy protocol and have obtained good results.<sup>8–11</sup>

P-gp, is a 170 kD adenosine triphosphate (ATP) dependent transmembrane efflux pump.<sup>12</sup> P-gp has been observed in a number of drug resistant cell lines. Undoubtedly, P-gp

contributes to clinical drug resistance in patients with cancer; however, it clearly is not the sole mechanism of drug resistance. In 1993, Scheper *et al*<sup>13</sup> first described lung resistance protein (LRP) in non-P-glycoprotein drug resistant cell lines. Since its original description, LRP has been identified as the major vault protein. Vaults are complex ribonucleoprotein particles containing at least two high molecular weight proteins and a small RNA molecule in addition to the 110 kd major vault protein. Clinical studies have reported that LRP expression predicts for drug resistance and poor outcome in patients with acute myelogenous leukaemia, ovarian cancer and other cancers.<sup>14, 15</sup> In retinoblastoma, LRP expression has not been studied. There is also not much information about the expression of P-gp in retinoblastomas from Asian Indian children. Thus, we studied the expression of the P-gp and LRP proteins in retinoblastoma and correlated them clinicopathologically.

## METHODS

The study was reviewed and approved by the local ethics committee of our institute, and the committee deemed that it conformed to the generally accepted principles of research, in accordance with the Helsinki Declaration. Paraffin embedded tissue blocks from 60 patients with retinoblastoma between 1997 and 2003 were retrieved. Clinical and pathological information was obtained from medical records and surgical pathology reports. An ocular pathologist (SK) reviewed haematoxylin and eosin stained slides with a double headed microscope.

## Inclusion and exclusion criteria

Inclusion criteria were that all the patients were treated by enucleation and patients had a minimum follow up for 24 months. Exclusion criteria included patients who had received preoperative chemotherapy and those who had received CSA in their chemotherapy protocol.

## Histopathology

Retinoblastomas were microscopically graded into three groups according to the predominant pattern of differentiation.<sup>16</sup> All tumour slides were reviewed and the choroidal invasion was classified as either focal invasion or diffuse invasion of choroid. For optic nerve invasion, prelaminar, postlaminar and the surgical end of the optic nerve were analysed. Invasion of the tumour cells into the orbit was also looked for in the sections. Clinical information regarding orbital recurrence and development of bone marrow metastasis were obtained from the files of the patients.

**Abbreviations:** ATP, adenosine triphosphate; CSA, ciclosporin A; DLP, diode laser photocoagulation; EBRT, external beam radiation therapy; LRP, lung resistance protein; MDR, multidrug resistance proteins; P-gp, P-glycoprotein; TCC, transconjunctival cryopexy

**Table 1** Retinoblastomas enucleated and not subjected to preoperative or postoperative chemotherapy

Study No	Age/sex	Clinicopathological features	P-gp		LRP	
			% Cells	Intensity	% Cells	Intensity
1	1 year/M	both eyes: right eye: PD	0	–	40%	+
2	11 months/F	right eye: WD	0	–	30%	+/-
3	5 years/M	left eye: PD	0	–	0	–
4	7 months/M	right eye: PD	0	–	70%	+
5	45 days/M	right eye: PD	0	–	0	–
6	2 months/M	right eye: WD	70%	+	40%	+
7	10 months/F	right eye: WD	80%	+	0	–
8	10 months/F	left eye: WD	70%	+	70%	+
9	5 months/M	right eye: WD	40%	+	80%	+
10	1½ years/M	right eye: WD	70%	+	0	–
11	2 years/M	left eye: PD	0	–	0	–
12	3 years/M	left eye: MD	0	–	0	–
13	2 years/F	right eye: MD	70%	+	0	–
14	3 months/F	right eye: WD	40%	+	90%	+
15	2 years/M	left eye: MD	40%	+	30%	+
16	2½ years/M	both eyes, left eye: WD	0	–	20%	+
17	1½ years/M	right eye: WD	0	–	0	–
18	4 months/M	both eyes: PD	30%	+/-	70%	+
19	4 years/M	right eye: WD	40%	+/-	80%	+
20	40 days/M	both eyes: right eye: MD	0	–	90%	+
21	18 months/M	right eye: MD	0	–	0	–
22	2 years/M	both eyes: left eye: PD	0	–	0	–
23	2 years/M	both eyes: right eye: PD	30%	+/-	70%	+
24	2 years/F	both eyes: left eye: PD	0	–	0	–
25	8 months/F	left eye: PD; prelaminar optic nerve invasion	0	–	40%	+
26	7 years/F	left eye: MD; post-laminar optic nerve invasion	0	–	60%	+
27	5 years/F	right eye: PD; focal RPE invasion.	0	–	60%	+
28	1 year/F	right eye: PD; diffuse choroidal invasion	20%	+/-	Neg	–
29	3 years/F	right eye: PD; no invasion	0	–	80%	+
30	6 years/F	right eye: PD; iris invasion	0	–	40%	+
31	2 years/F	left eye: PD; full thickness choroidal invasion	0	–	40%	+
32	3 years/M	left eye: PD; prelaminar and post-laminar invasion	0	–	60%	+
33	4 years/M	left eye: PD; diffuse choroidal and post-laminar optic nerve invasion	20%	+/-	40%	+
34	3 years/F	left eye: PD; diffuse choroidal invasion	0	–	60%	+
35	7 years/M	right eye: PD; no invasion	0	–	Neg	–
36	9 months/M	left eye: PD; focal retinal pigment epithelium invasion and prelaminar invasion	0	–	40%	+/-
37	2 years/F	right eye: PD; surgical end of optic nerve involved	20%	+	70%	+
38	18 months/F	left eye: PD; diffuse choroidal, prelaminar optic nerve invasion	0	–	Neg	–
39	2 years/F	right eye: MD; post-laminar optic nerve invasion	0	–	50%	+
40	7 years/F	left eye: PD; no invasion	0	–	30%	+

PD, poorly differentiated; MD, moderately differentiated; WD, well differentiated.

## Treatment

All the 60 tumours were not subjected to preoperative chemotherapy. However, when the tumours had known risk factors for metastasis,<sup>16</sup> such as diffuse invasion of choroid, invasion of the post-laminar portion of the optic nerve, surgical end of the optic nerve, and orbital invasion, the children received treatment with chemotherapy. In bilateral retinoblastoma the eye where the tumour was small was treated with focal therapy. The focal therapies employed were external beam radiation therapy (EBRT), diode laser photocoagulation (DLP), and transconjunctival cryopexy (TCC). The chemotherapy cycles ranged from two to eight cycles. The chemotherapy drugs included carboplatin, vincristine, and etoposide.

## Monoclonal antibodies

P-glycoprotein (clone 5B12), a mouse monoclonal antibody and a prokaryotic recombinant protein corresponding to the C terminal cytoplasmic domain of the P-glycoprotein molecule, was used (Novocastra Laboratories, Newcastle upon Tyne, UK). It was used in a working dilution of 1:30. The immunoreactivity is membrane staining. Human lung resistance related protein (LRP) (110 kD), a mouse monoclonal antibody, was also obtained from Novocastra Laboratories. It was used in a working dilution of 1:200. The immunoreactivity is cytoplasmic staining.

## Immunohistochemistry

Immunohistochemistry was performed on 4 µm thick formalin fixed, paraffin embedded sections mounted on 3-aminopropyltriethoxy silane coated slides. After conventional deparaffinisation and rehydration, endogenous peroxidase activity was quenched by incubation in 3% H<sub>2</sub>O<sub>2</sub> (10 minutes) at room temperature. Pretreatment in a pressure cooker (20 minutes) with citrate buffer (0.1M citric acid and 0.1M trisodium citrate in distilled water; pH -6.0) for P-gp and LRP was performed to unmask epitopes. Next, samples were incubated (60 minutes) in normal rabbit serum (1: 50 in 1% phosphate buffered saline bovine serum albumin), and then with the optimally diluted specific antibody (overnight) at 4°C in a humidified chamber. The monoclonal antibody P-gp and LRP was detected by the Dako LSAB+ System horse-radish peroxidase (Dako Corp, Glostrup, Denmark) for 45 minutes. Bound peroxidase was developed with diaminobenzidine (DAB) and hydrogen peroxide and counterstained with haematoxylin. As control tissues, colon was used for P-gp and lung for LRP.

## Immunoreactivity scoring

Two observers without knowledge of the clinical data independently assessed the expression of P-gp and LRP. The distribution of P-gp and LRP expression was semiquantitatively assessed by estimating both the staining intensity

and the percentage of positively stained cells. The staining intensity was graded as; + for bright staining, +/- for dull staining, and - for absent staining. Three staining categories were established: negative (absent staining), heterogeneous (bright staining in ≤ 10% of tumour cells and dull staining in >10% tumour cells), and positive (bright staining in >10% of the tumour cells).<sup>15</sup>

**Statistical analysis**

Data were analysed for statistical significance using the  $\chi^2$  test. For statistical analysis heterogeneous expression was combined with positive expression and compared against negative expression in tumours with invasion and tumours with no invasion. Statistical analysis was performed

correlating P-gp, LRP expression with laterality of tumours, differentiation and invasion and also correlating between P-gp and LRP expression in the overall cohort. For statistical analysis, moderately differentiated and well differentiated tumours were compared with poorly differentiated tumours.

**RESULTS**

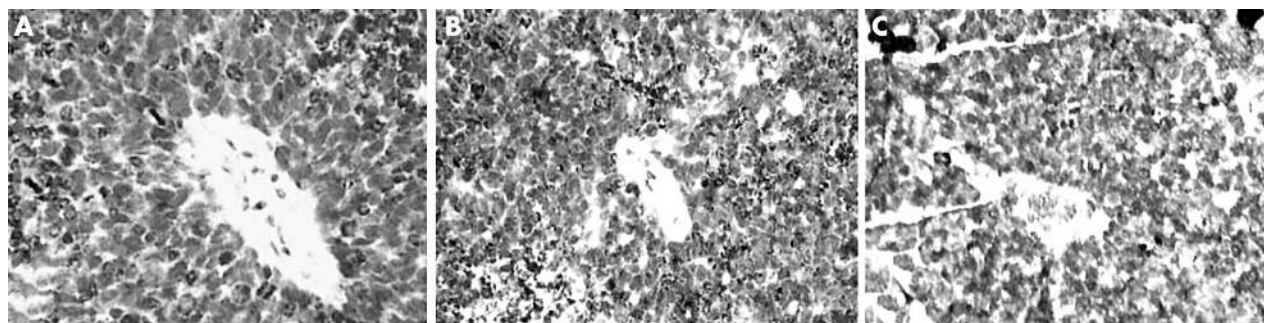
**Clinical information**

A total of 60 tumours were available from 60 eyes for the study. Among them, there were tumours from 34 males and 26 females. There were 47 unilateral retinoblastomas and 13 bilateral retinoblastomas. The age of the children ranged from 40 days to 7 years (median 2 years) There were 40 (in table 1: nos 1–40) tumours, which were not subjected to

**Table 2** Retinoblastomas enucleated and subjected to postoperative chemotherapy

Study No	Age/sex	Clinicopathological features	P-gp		LRP		Chemotherapy	Outcome
			% Cells	Intensity	% Cells	Intensity		
41	3 years/M	right eye: PD diffuse choroidal invasion and post-laminar optic nerve invasion.	70%	+	20%	+/-	7 cycles of triple chemotherapy	No recurrence or metastasis
42	3 years/M	left eye: PD, post-laminar optic nerve invasion	0	-	80%	+	2 cycles of triple chemotherapy	No recurrence or metastasis
43	10 months/M	both eyes, right eye: WD, focal, choroidal, surgical end of optic nerve invasion	0	-	0	-	4 cycles of triple chemotherapy	6 months, child died (bone marrow metastasis)
44	3 years/F	right eye, MD, post-laminar optic nerve invasion	0	-	0	-	6 cycles of triple chemotherapy	No recurrence or metastasis
45	3 years/M	left eye: PD, diffuse choroidal invasion, post-laminar optic nerve invasion	50%	+	70%	+	6 cycles of triple chemotherapy	Orbital involvement. Exenteration done
46	4 years/F	left eye: PD, post-laminar optic nerve invasion	0	-	0	-	4 cycles of triple chemotherapy	No recurrence or metastasis
47	2½ years/M	right eye: PD, diffuse choroidal invasion	0	-	0	-	3 cycles of triple chemotherapy	Orbital recurrence
48	7 years/M	left eye: PD, diffuse choroidal invasion, orbital invasion.	0	-	0	-	Exenteration done, 6 cycles of chemotherapy	Death with bone marrow metastasis
49	2 years/M	post-laminar optic nerve invasion both eyes, right eye: PD, diffuse choroidal invasion, post-laminar optic nerve invasion, orbital invasion	0	-	0	-	6 cycles of triple chemotherapy	BM metastasis
50	5 years/F	both eyes, left eye, WD, focal invasion of choroid post-laminar optic nerve invaded	60%	+	0	-	2 cycles of triple for left eye	No recurrence or metastasis
51	3 years/M	left eye: PD, diffuse choroidal invasion, post-laminar optic nerve invasion	40%	+	90%	+	left eye: 6 cycles of triple chemotherapy	orbital recurrence
52	1 year 8 months/F	left eye: PD diffuse choroidal invasion, post-laminar optic nerve invasion	0	-	0	-	5 cycles of triple chemotherapy	orbital recurrence
53	2 years/M	both eyes: right eye enucleated, PD; diffuse choroidal invasion	0	-	0	-	4 cycles of triple chemotherapy	No recurrence or metastasis
54	2 years/M	both eyes: right eye enucleated, PD; post-laminar optic nerve invasion	60%	+	70%	+	3 cycles of triple chemotherapy	No recurrence or metastasis
55	2 years/M	both eyes: right eye: enucleated, MD; post-laminar optic nerve invasion	0	-	0	-	right eye: triple chemotherapy	No recurrence or metastasis
56	4 years/F	left eye: PD; focal choroidal invasion, post-laminar optic nerve invasion	0	-	60%	+	left eye: 4 cycles of triple chemotherapy	No recurrence or metastasis
57	13 months/F	right eye: PD; focal choroidal invasion, post-laminar optic nerve invasion	0	-	30%	+	right eye: 6 cycles of triple chemotherapy	No recurrence or metastasis
58	3 years/F	right eye: PD; diffuse choroidal invasion; post-laminar optic nerve invasion	20%	+	30%	+	right eye: 7 cycles of triple chemotherapy	No recurrence or metastasis
59	2 years/F	left eye: PD; diffuse choroidal; surgical end of optic nerve involved	0	-	0	-	left eye: 4 cycles of triple chemotherapy	No recurrence or metastasis
60	4 years/M	left eye: PD; diffuse choroidal invasion; post-laminar optic nerve invasion.	20%	+/-	40%	+	left eye: 6 cycles of triple chemotherapy	No recurrence or metastasis.

PD, poorly differentiated; MD, moderately differentiated; WD, well differentiated.



**Figure 1** P-glycoprotein (P-gp) expression in retinoblastoma. (A) Microphotograph showing P-gp in the membrane of the tumour cells (in >10% of the tumour cells with bright intensity) in retinoblastoma with no invasion (DAB with haematoxylin and eosin counterstain,  $\times 200$ ). (B) Microphotograph showing the P-gp in the membrane of the tumour cells (in >10% of the tumour cells with dull intensity) in a child who had orbital recurrence (DAB with haematoxylin and eosin counterstain,  $\times 100$ ). (C) Microphotograph showing the P-gp in the membrane of the tumour cells (in 30–40% of the tumour cells with dull intensity) in retinoblastoma with no invasion (DAB with haematoxylin and eosin counterstain,  $\times 100$ ).

postoperative chemotherapy. There were 20 (in table 2: nos 41–60) tumours enucleated and then the children subjected to post operative chemotherapy because of invasion of choroid/optic nerve and orbit.

### Histopathological information

There were 12 well differentiated, nine moderately differentiated, and 39 poorly differentiated tumours. Among the 60 tumours, 33 tumours had invasion and 27 tumours had no invasion. Among 33 tumours with invasion, 10 had diffuse choroidal invasion and post-laminar optic nerve invasion (of these, three also had associated orbital invasion), five had diffuse choroid alone, three had focal choroid and post-laminar portion of the optic nerve involved, one had focal choroidal invasion and surgical end of optic nerve, one had prelaminar alone, one prelaminar with focal retinal pigment epithelium (RPE) invasion, one RPE invasion alone, one iris invasion alone, one diffuse choroidal and surgical end involved, one surgical end of optic nerve alone, one prelaminar and post-laminar invasion of optic nerve, and seven had post-laminar portion of the optic nerve involved.

### Clinical outcome

Tumours from cases 1–40 (shown in table 1), which were enucleated and not subjected to postoperative chemotherapy, did not recur. For treatment of cases 41–60 (shown in table 2), the children were subjected to postoperative chemotherapy because of the underlying choroidal invasion/optic nerve invasion/orbital invasion. Four children developed orbital recurrence of the tumour and three children developed bone marrow metastasis.

### P-gp expression in tumours with no invasion

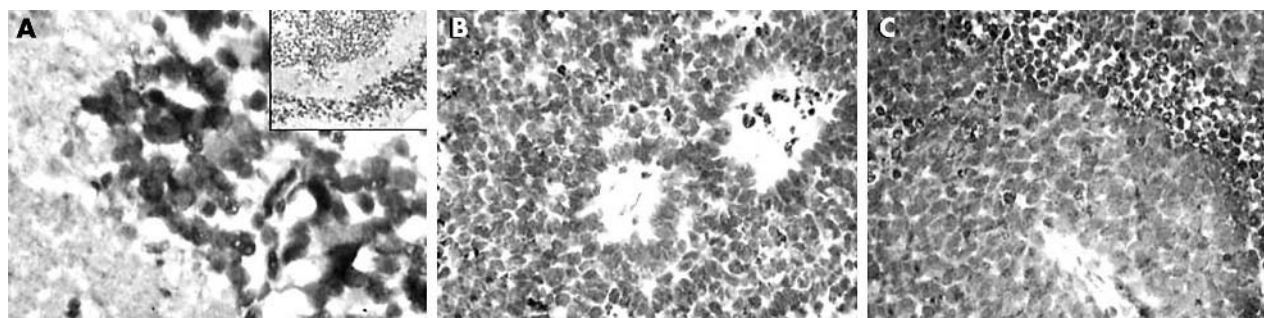
Among the 27 tumours with no invasion, P-gp was expressed in 11 (40%). There were 10 tumours positive for P-gp (five with 70%–80% cells stained with +intensity, three with 40% cells stained with +intensity) and three tumours heterogeneous (30–40% cells stained with +/- intensity). P-gp was negative in 16 tumours.

### LRP expression in tumours with no invasion

Among the 27 tumours with no invasion, LRP was expressed in 15 (55%) tumours. There were 14 tumours positive for LRP (nine with 70%–90% cells stained with +intensity, five with 20%–40% cells stained with +intensity) and one tumour heterogeneous (30% cells stained with +/- intensity). LRP was negative in 12 tumours.

### P-gp expression and LRP expression in tumours with invasion, orbital recurrence, and metastasis

Among 33 tumours with invasion, P-gp was expressed in 10. Among these, seven tumours showed positive staining (four with 50–70% cells stained with +intensity), heterogeneous in three tumours (three with 20% cells stained with +/- intensity). LRP was expressed in 20 tumours; 18 tumours were positive (10 with 60–90% cells stained and eight with 20–50% cells stained with +intensity), two tumours heterogeneous (one with 20% cells stained and one with 40% cells stained with +/- intensity). Among the four children with orbital recurrence P-gp and LRP were positive in two cases each. Among the three children who developed bone marrow metastasis both P-gp and LRP expression were negative.



**Figure 2** Lung resistance protein (LRP) expression in retinoblastoma. (A) Microphotograph showing the LRP in the cytoplasm of the tumour cells (>10% cells stained with bright intensity) in retinoblastoma with no invasion (DAB with haematoxylin and eosin counterstain,  $\times 200$ ). Inset shows the lower magnification of the same. (B) Microphotograph showing the LRP (in >10% of the tumour cells with dull intensity) in retinoblastoma in with invasion (DAB with haematoxylin and eosin counterstain,  $\times 100$ ). (C) Microphotograph showing the LRP (in >10% of the tumour cells with bright intensity) in the pretreatment tumour sample in a child with no invasion. (DAB with haematoxylin and eosin counterstain,  $\times 100$ ).

### Comparison of P-gp and LRP expression with differentiation of the tumours

Among the 12 well differentiated tumours, eight expressed P-gp and seven expressed LRP. Among the nine moderately differentiated tumours, two expressed P-gp, and four expressed LRP. Among the 39 poorly differentiated tumours, 13 expressed P-gp and 24 expressed LRP. There was no correlation between differentiation of the tumours with P-gp and LRP expression.

### P-gp and LRP expression in unilateral and bilateral tumours

Among the 47 unilateral tumours, 17 (36%) expressed P-gp and 30 (64%) expressed LRP. Among the 13 bilateral tumours, four (30%) expressed P-gp and six (46%) expressed LRP. There was no correlation between laterality of the tumours with P-gp and LRP expression. Figure 1 shows the P-gp expression and figure 2 shows the LRP expression in retinoblastoma respectively.

### DISCUSSION

Evidence for a clinically relevant role for multidrug resistance proteins in retinoblastoma is not readily available because these tumours are seldom tested before chemotherapy; moreover, in these bilateral cases, test results of tumours in the enucleated eye that do not require further treatment cannot be considered predictive of the P-gp or LRP expression of retinoblastoma in the retained eye undergoing chemotherapy, because each tumour arises as a result of different second mutation, although they share a common germ line RB1 mutation. Thus, the available data that correlate multidrug resistance proteins expression with outcome of chemotherapy in retinoblastoma are meagre and circumstantial.

In our study P-gp was expressed in 38% (23/60) of tumours and LRP expressed in 58% (35/60) of tumours. Thus, this shows that retinoblastomas express P-gp and LRP intrinsically even previous chemotherapy. P-gp was expressed in 40% of tumours with no invasion and 36% of tumours with invasion. LRP was expressed in 55% of tumours with no invasion and 60% of tumours with invasion. Thus, there was no correlation of these proteins with invasiveness. There was also no correlation of these proteins with differentiation of the tumours and laterality.

Regarding the correlation of these proteins with response to chemotherapy, since the 40 tumours (1–40), were not subjected to any chemotherapy, we cannot correlate the P-gp and LRP expression in the tumour samples with clinical outcome. In the 20 tumours that were subjected to post-operative chemotherapy 13 responded well to postoperative chemotherapy (P-gp was positive in five and LRP was positive in seven). There were seven children who did not do well despite postoperative chemotherapy (four developed orbital recurrence and three bone marrow metastasis; P-gp and LRP were positive in only two tumours). Thus, we were not able to use P-gp and LRP expression to predict the biological behaviour of the tumour.

There is only one study on the expression of MDR proteins in retinoblastoma other than those of Galle and Chan *et al.*<sup>2–6</sup> In a study<sup>17</sup> on Rb cell line HXO-RB, the investigators observed that tumour cell lines expressed both multidrug resistance gene (MDR1) and multidrug associated protein P-gp. However it was only on cell lines, and there was no clinical correlation. Our study results are different from those of Gallie and Chan in that we did not find any correlation between the expression of P-gp and invasiveness of the tumours and response to treatment.

Thus, whether P-gp protein has a rate limiting role in chemotherapy remains a challenging question. Few reports have attempted to correlate the high levels of P-gp found in

carcinomas with outcome. Some studies of acute myelogenous and acute lymphoblastic leukaemia, myeloma, lymphoma, rhabdomyosarcoma, and neuroblastoma have shown that the presence of detectable levels of P-gp correlated with poor prognosis and the absence of this protein with long term disease free survival. However, other studies on leukaemia, lymphoma, and neuroblastoma showed no such correlations.<sup>18</sup>

This is the first study on LRP expression in retinoblastoma. Our study shows that retinoblastoma expresses LRP intrinsically. The major vault protein/LRP was initially described in non-small cell lung cancer cell lines that lacked P-gp. Recently, it became evident that LRP is present in a variety of human cancer cell lines that have not previously been exposed to drugs. In these cell lines the expression of LRP correlated with intrinsic resistance to doxorubicin, vincristine, and platinum compounds.<sup>14</sup> However, we were not able to correlate LRP expression with clinicopathological parameters or with chemotherapy.

Then how do we explain the expression of P-gp in retinoblastoma? Firstly, the distribution of P-gp in normal tissue suggests a physiological role of detoxification, excretion, and protection of vital organs against toxic products and xenobiotics.<sup>19</sup> P-gp expression has been observed in rabbit retina-choroid suggesting the involvement of a multidrug efflux transporter on the RPE and neural retina, which affects intraocular kinetics following systemic and intravitreal administrations of drugs.<sup>20</sup> Thus, the expression of the P-gp by the tumour cells may help in transport of substrates intracellularly and this could be critical for tumour cell growth. Secondly, it could be that P-gp reflects an alternative antigenic marker of a primitive blast phenotype that, in this disease, represents only one of many redundant cell defence mechanisms or survival signals.

Thus, in conclusion, our findings seem to reflect the existence of intrinsically resistant tumour cell clones in retinoblastoma before chemotherapeutic treatment. Interestingly, the presence of P-gp and LRP were unrelated to the response of the tumours to chemotherapy. This suggests that the role of these markers in tumour progression may be independent of their putative role in drug resistance.<sup>21</sup> It is difficult to determine the exact contribution of these markers to clinical drug resistance, as most chemotherapeutic regimens consist of a combination of anticancer drugs with at least one drug not involved in the MDR phenotype. New treatment strategies, directed against those quiescent tumour cells that are not killed by the available drugs, are awaited. Thus, further studies are needed to understand the significance of the expression of the P-gp and LRP proteins in retinoblastoma.

### Authors' affiliations

S Krishnakumar, K Mallikarjuna, N Venkatesan, A Sundaram, Department of Ocular Pathology, Vision Research Foundation, Chennai, Tamil Nadu, India

N Desai, Brown Medical School, Providence, RI, USA

A Muthialu, Feinberg Northwestern School of Medicine, Chicago, IL, USA

V Khetan, M P Shanmugam, Department Ocular Oncology, Medical and Vision Research Foundations, Sankara Nethralaya, Chennai, India

Support: Grant from Vision Research Foundation, Sankara Nethralaya.

Commercial relationships: nil.

Correspondence to: Dr Subramanian Krishnakumar, Department of Ocular Pathology, Vision Research Foundation, Sankara Nethralaya, 18 College Road, Chennai-600 006, Tamil Nadu, India; [drkrishnakumar\\_2000@yahoo.com](mailto:drkrishnakumar_2000@yahoo.com)

Accepted for publication 8 April 2004

## REFERENCES

- Rodriguez-Galindo C, Wilson MW, Haik BG, et al. Treatment of metastatic retinoblastoma. *Ophthalmology* 2003;**110**:1237-40.
- Chan HS, Thorner PS, Haddad G, et al. Multidrug-resistant phenotype in retinoblastoma correlates with P-glycoprotein expression. *Ophthalmology* 1991;**98**:1425-31.
- Chan HS, Canton MD, Gallie BL. Chemosensitivity and multidrug resistant to antineoplastic drugs in retinoblastoma cell lines. *Anticancer Res* 1989;**9**:469-74.
- Chan HS, Thorner PS, Haddad G, et al. Effect of chemotherapy on intraocular retinoblastoma. *Int J Pediatr Hematol Oncol* 1995;**2**:269-81.
- Chan HS, Lu Y, Grogan TM, et al. Multidrug resistance protein (MRP) expression in retinoblastoma correlates with the rare failure of chemotherapy despite cyclosporine for reversal of P-glycoprotein. *Cancer Res* 1997;**57**:2325-30.
- Gallie BL, Budning A, DeBoer G, et al. Chemotherapy with focal therapy can cure intraocular retinoblastoma without radiotherapy. *Arch Ophthalmol*. 1996;**114**: 1321-8, Erratum in: *Arch Ophthalmol*, 1997;**115**:525.
- Chan HS, DeBoer G, Thiessen JJ, et al. Combining cyclosporin with chemotherapy controls intraocular retinoblastoma without requiring radiation. *Clin Cancer Res* 1996;**2**:1499-508.
- Shields CL, De Potter P, Himelstein BP, et al. Chemoreduction in the initial management of intraocular retinoblastoma. *Arch Ophthalmol* 1996;**114**:1330-8.
- Friedman DL, Himelstein B, Shields CL, et al. Chemoreduction and local ophthalmic therapy for intraocular retinoblastoma. *J Clin Oncol* 2000;**18**:12-17.
- Murphree L, Villablanca JG, Deegan WF 3rd, et al. hemotherapy plus local treatment in the management of intraocular retinoblastoma. *Arch Ophthalmol* 1996;**114**:1348-56.
- Greenwald MJ, Strauss LC. Treatment of intraocular retinoblastoma with carboplatin and etoposide chemotherapy. *Ophthalmology* 1996;**103**:1989-97.
- Gerlach JH, Kartner N, Bell DR, et al. Multidrug resistance. *Cancer Surv* 1986;**5**:25-46.
- Scheper RJ, Broxterman HJ, Scheffer GL, et al. Overexpression of a M(r) 110,000 vesicular protein in non-P-glycoprotein-mediated multidrug resistance. *Cancer Res* 1993;**53**:1475-9.
- Scheffer GL, Wijngaard PL, Flens MJ, et al. The drug resistance-related protein LRP is the human major vault protein. *Nat Med* 1995;**1**:578-82.
- Zurita AJ, Diestra JE, Condom E, et al. Lung resistance-related protein as a predictor of clinical outcome in advanced testicular germ-cell tumors. *Br J Cancer* 2003;**88**:879-86.
- Finger PT, Harbour JW, Karcioglu ZA. Risk factors for metastasis in retinoblastoma. *Surv Ophthalmol* 2002;**47**:1-16.
- Liu J, Tang L, Liu X, et al. A gene study on multidrug resistance of retinoblastoma. *Zhonghua Yan Ke Za Zhi* 2001;**37**.
- Fisher GA, Sikic BI. Drug resistance in clinical oncology and hematology. Introduction. *Hematol Oncol Clin North Am* 1995;**9**:xi-xii.
- Duhem C, Ries F, Dicato M. What does multidrug resistance (MDR) expression mean in the clinic? *Oncologist* 1996;**1**:151-8.
- Duvvuri S, Gandhi MD, Mitra AK. Effect of P-glycoprotein on the ocular disposition of a model substrate, quinidine. *Curr Eye Res* 2003;**27**:345-53.
- Pinedo HM, Giaccone G. P-glycoprotein—a marker of cancer cell behavior. *N Engl J Med* 1995;**333**:1417-19.

## Video reports

To view the video reports in full visit our website [www.bjophthalmol.com](http://www.bjophthalmol.com) and click on the link to the video reports.

- Bilateral Abducens Neuromyotonia. *L H Ospina, N Auiaree, D P Anderson*
- Light to dark physiological variation in irido-trabecular angle width. *G M Gazzard, P J Foster, D S Friedman, P T Khaw, S K L Seah*

## Video Suite: Triamcinolone-assisted vitrectomy

- Triamcinolone-assisted removal of the posterior hyaloid to repair retinal detachment due to macular hole in high myopia. *A Ueno, H Enaida, Y Hata, T Nakamura, T Hisatomi, K Fujisawa, T Kubota, T Sakamoto, T Ishibashi*
- Triamcinolone acetamide-assisted Epiretinal Membrane Peeling. *S D M Chen, C K Patel*
- A suture technique to manage a case of severe early flap displacement after laser in situ keratomileusis. *L Spadea, P Pantaleoni, G Bianco*
- Reconstruction of the Ocular Surface in LOGIC Syndrome. *E Moore, V Kumar, J R Ainsworth, S Shah*
- Laser Photocoagulation for Posterior Segment Intraocular Parasites. *T Prabripataloong, S Asawaphureekorn*
- Feeder Vessel Treatment with High Speed ICG Angiography. *D Stanescu-Segall, G Coscas, F Coscas, G Soubrane*
- Endoscopy to aid anterior segment surgery. *J E Moore, A Sharm*
- Penetrating ocular injury due to a fish hook: Surgical removal. *S D M Chen, D Chiu, C K Patel*
- Retinal Ganglion Cell Axon Response to Guidance Molecules. *S F Oster and D W Sretavan*
- Marin-Amat Syndrome. *A Jogiya, C Sandy*
- Excision of subcutaneous Dirofilaria of the eyelid. *D Mallick, T P Ittyerah*
- Thixotropy: a novel explanation for the cause of lagophthalmos after peripheral facial nerve palsy. *M Aramideh, J H T M Koelman, P P Devriese, F VanderWerf, J D Speelman*
- Surgical revision of leaking filtering blebs with an autologous conjunctival graft. *K Taherian, A Azuara-Blanco*
- Dipetalonema Reconditum in the human eye. *T Huynh, J Thean, R Maini*



## Multidrug resistant proteins: P-glycoprotein and lung resistance protein expression in retinoblastoma

S Krishnakumar, K Mallikarjuna, N Desai, et al.

*Br J Ophthalmol* 2004 88: 1521-1526

doi: 10.1136/bjo.2004.047928

---

Updated information and services can be found at:

<http://bjo.bmj.com/content/88/12/1521.full.html>

---

*These include:*

### References

This article cites 19 articles, 8 of which can be accessed free at:

<http://bjo.bmj.com/content/88/12/1521.full.html#ref-list-1>

Article cited in:

<http://bjo.bmj.com/content/88/12/1521.full.html#related-urls>

### Email alerting service

Receive free email alerts when new articles cite this article. Sign up in the box at the top right corner of the online article.

---

### Notes

---

To request permissions go to:

<http://group.bmj.com/group/rights-licensing/permissions>

To order reprints go to:

<http://journals.bmj.com/cgi/reprintform>

To subscribe to BMJ go to:

<http://group.bmj.com/subscribe/>