

SCIENTIFIC REPORT

Genotype-phenotype correlation in a family with Arg135Leu rhodopsin retinitis pigmentosa

K T Oh, D M Oh, R G Weleber, E M Stone, A Parikh, J White, K A DeBoer-Shields, L Streb, C Vallar

Br J Ophthalmol 2004;88:1533–1537. doi: 10.1136/bjo.2004.043653

Aim: To describe the clinical characteristics and disease course of a large family with retinitis pigmentosa (RP) from an Arg135Leu change in rhodopsin.

Methods: 29 patients in this family were evaluated. Goldmann visual fields were performed on 14 affected individuals, Ganzfeld electroretinography (ERG) on eight individuals (11–56 years), and blood samples collected on 10 individuals (11–58 years). Patient visual field data were compared with previously reported patients with different rhodopsin mutations using linear regression.

Results: An Arg135Leu mutation was identified in rhodopsin. Distinct stages of clinical evolution were identified for this family ranging from normal, white dots, classic bone spicules and, finally, ending with extensive retinal pigment epithelium (RPE) atrophy. 9/16 patients over the age of 20 years also demonstrated marked macular atrophy. All patients who underwent full field ERG testing demonstrated non-recordable ERGs. The overall regression model comparing solid angles of visual fields from patients with rhodopsin mutations (Pro23His, Pro347Ala, Arg135Leu) shows significant effects for age ($p=0.0005$), mutation ($p=0.0014$), and interaction between age and mutation ($p=0.018$) with an R^2 of 0.407.

Conclusions: An Arg135Leu change in rhodopsin results in a severe form of RP that evolves through various fundus appearances that include white dots early in life and classic appearing RP later. This transmembrane change in rhodopsin proves to be more severe than in a family with an intradiscal change and a family with a cytoplasmic change.

Retinitis pigmentosa (RP) is characterised by clinical findings of bone spicules, arteriolar attenuation, and optic nerve atrophy. However, there is a wide range of presentation and severity. The clinical appearance of any given patient with RP depends on the stage of the patient in the disorder and the molecular basis of disease. Of the approximately 100 000 patients with RP in the United States, 15–20% of patients have autosomal dominant retinitis pigmentosa (ADRP).^{1–3} The most common molecular causes of ADRP are changes in rhodopsin. Rhodopsin related RP tends to have a milder disease course than other forms of RP.^{1–4} However, Sandberg demonstrated that the severity of rhodopsin related RP was dependent on the site of the sequence variation.⁵ An Arg135Leu mutation in rhodopsin was reported by Sung.^{4,6,7} We describe the clinical characteristics of this mutation in a 13 generation family. This change in rhodopsin demonstrates a very severe course with widespread white dots early that fade into a more classic appearance of RP in adulthood.

SUBJECTS AND METHODS

This study had approval of the institutional review board of the University of North Carolina (UNC). A total of 24 affected

patients, all members of a 13 generation family with ADRP (fig 1), were examined at UNC. Five additional affected and multiple unaffected patients were examined at a family reunion by the author. Patients clearly reported nyctalopia from early childhood and this symptom was used to determine disease status. Affected patients from four different generations and two separate branches of the family came to UNC. Patients underwent a standard eye examination, Goldmann perimetry, electroretinographic testing, and fundus photography. Patients with hand movement or worse vision did not undergo ancillary testing. Full field electroretinography and multifocal electroretinography (mfERG) were performed according to ISCEV standards.^{8,9} Eight patients underwent full field ERG testing with an LKC Veritas system (Gaithersburg, MD, USA). Three patients underwent mfERG using a Veris system (ElectroDiagnostics, Inc, San Mateo, CA, USA). Goldmann visual fields (GVF) were converted to solid angle (in steradians) using described methods.^{10,11} A linear regression model was performed from patients with Arg135Leu, Pro23His and Pro347Ala mutations in rhodopsin¹¹ (JMP SAS, Cary, NC, USA).

Molecular analysis and findings

Ten patients at various disease stages ranging in age from 11–58 years had blood samples sent to the Carver Molecular Ophthalmology Laboratory for analysis. Screening using an amplification refractory mutation system (ARMS)¹² disclosed neither the Pro23His nor Arg135Trp changes in rhodopsin. Samples that had aberrant migration patterns of polymerase chain reaction products, using single stranded conformational polymorphism analysis,^{11,13,14} were sequenced bidirectionally with fluorescent dideoxynucleotides on an ABI model 377 automated sequencer. An Arg135Leu change in rhodopsin was identified in all samples.

RESULTS

Clinical findings

All affected patients in this study, ranging in age from 7–64 years of age, reported symptoms of nyctalopia before 5 years of age. No unaffected patients demonstrated white dots or other signs of RP. Visual acuity ranged from 20/20 to light perception and remained stable until the development of posterior subcapsular cataracts in the third to fourth decade of life (fig 2). Nearly all patients over the age of 16 who were evaluated had cataracts or intraocular lenses with maintained central visual acuity until the fourth to fifth decade of life. However, 9/16 patients over the age of 20 years demonstrated some degree of macular atrophy that compromised central vision (fig 3A). Six of seven patients under the age of 20 years who were examined, demonstrated

Abbreviations: ADRP, autosomal dominant retinitis pigmentosa; ARMS, amplification refractory mutation system; GVF, Goldmann visual fields; mfERG, multifocal electroretinography; RP, retinitis pigmentosa; RPA, retinitis punctata albescens; RPE, retinal pigment epithelium

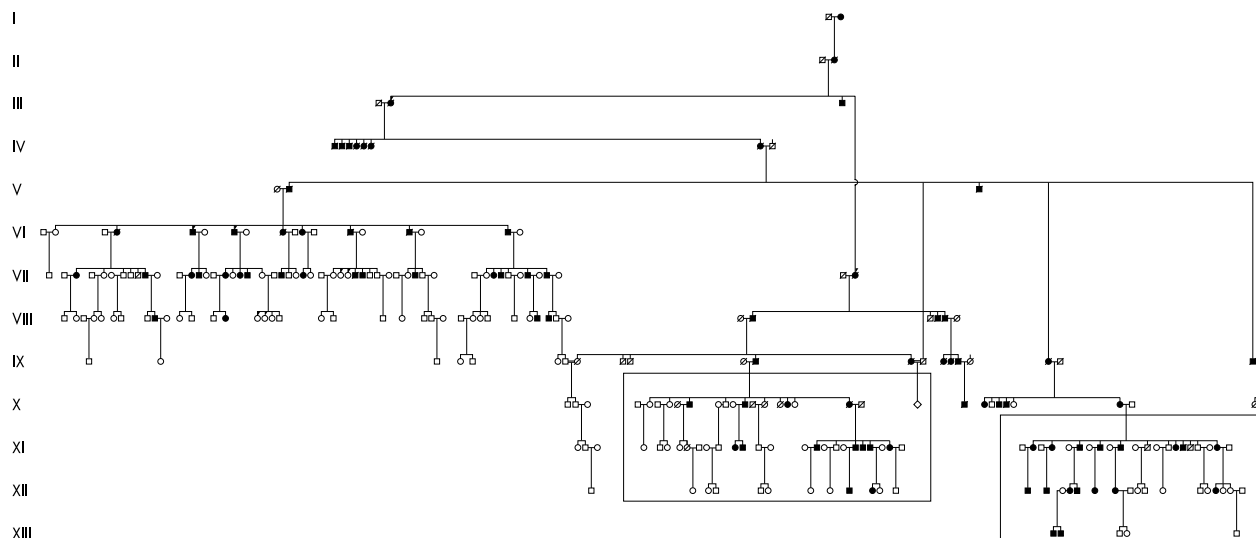


Figure 1 Pedigree. The family, which clearly demonstrates an autosomal dominant pattern of inheritance, could be traced back 13 generations. The branches of the family that participated in the current study are boxed. From the left box, one woman from generation X, five patients from generation XI, and two patients from generation XII were examined. From the right box, seven patients from generation XI, seven patients from generation XII, and two patients from generation XIII were examined at UNC. The majority of living affected and unaffected members of these two branches of the family were examined at the family reunion in western North Carolina.

widespread white dots and minimal RPE changes with only the youngest patient (age 7 years) not demonstrating any definite signs (fig 3B and 3C). In the second to third decades, the white dots fade and are replaced by RPE atrophy and bone spicules (fig 3D) and, finally, the fundus shows marked RPE atrophy and choroidal sclerosis (fig 3E and F).

Electroretinographic findings

We evaluated eight patients with full field electroretinography (ages 11–50 years) and three patients with mfERG. All patients undergoing full field electroretinography showed non-recordable responses. For mfERG testing, only the 16 year old demonstrated recordable retinal function, though no other patients younger than 40 years were tested. Repeat mfERG for this patient 13 months later found considerable further loss of recordable amplitude.

Perimetric findings

Fifteen patients underwent Goldmann perimetry. There was no measurable field with the 14e isoptre by the fourth decade of life. The V4e test target became undetectable by the sixth decade of life (fig 4). When the solid angle of 14e isoptre was compared to the clinical characteristics of the Pro23His and the Pro347Ala change in rhodopsin, there was a significant

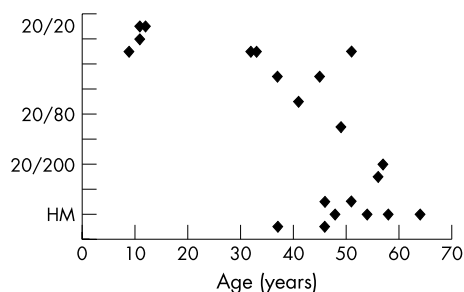


Figure 2 Visual acuity. The central visual acuity of the better seeing eye of each patient is plotted against their age at examination. From this distribution, there is a notable drop off in central visual acuity by the fourth decade of life. Outliers who maintain central visual acuity beyond the fourth decade of life notably have minimal macular atrophy.

difference in the loss of visual field for patients with an Arg135Leu change in rhodopsin compared with the other mutations. The difference between visual field data for patients with the rhodopsin Arg135Leu RP and those with either other change remained significant at the 0.0005 level after Bonferroni correction (fig 5). The overall regression model comparing patients with rhodopsin mutations (Pro23His, Pro347Ala, Arg135Leu) shows significant effects for age ($p = 0.0005$), mutation ($p = 0.0014$), and interaction between age and mutation ($p = 0.018$) with an R^2 of 0.407. Comparison of Arg135Leu change and Pro23His change demonstrated a significant difference in these populations ($p = 0.0002$) but no significance in the effect of age or the interaction of age and mutation. Comparison of Arg135Leu change and Pro347Ala change shows significant effect of age ($p = 0.0001$), mutation ($p = 0.0001$), and the interaction of age with mutation ($p = 0.0003$).

DISCUSSION

Rhodopsin related disease may present with a wide spectrum of severity and clinical features, including regional and diffuse RP,^{15–17} sectoral RP,^{18–23} and congenital stationary night blindness.^{24–27} Sandberg previously identified the importance of the locus of mutations in rhodopsin to a specific patient's disease course, showing that intradiscal variations such as Pro23His carried the mildest course of disease and cytoplasmic variations such as at codon 347 carried the most severe prognosis.^{5–28} The severity of mutations in the intracytoplasmic region of rhodopsin is well documented though only a few clinical studies exist for changes in the transmembrane region.²⁹

Pannarale described one family with an Arg135Trp mutation in rhodopsin with a very severe course. That family demonstrated non-recordable electroretinographic responses by the third decade of life but low, recordable wave forms for younger patients.¹⁷ Thus, changes associated with codon 135 may result in a more severe course.³⁰ The appearance of white dots in association with rhodopsin and, specifically, Arg135Trp rhodopsin related RP, was described by Souied as an early finding in that form of RP.³¹ The term retinitis punctata albescens (RPA) was originally used to denote a specific form of RP.³² Although some have questioned in the

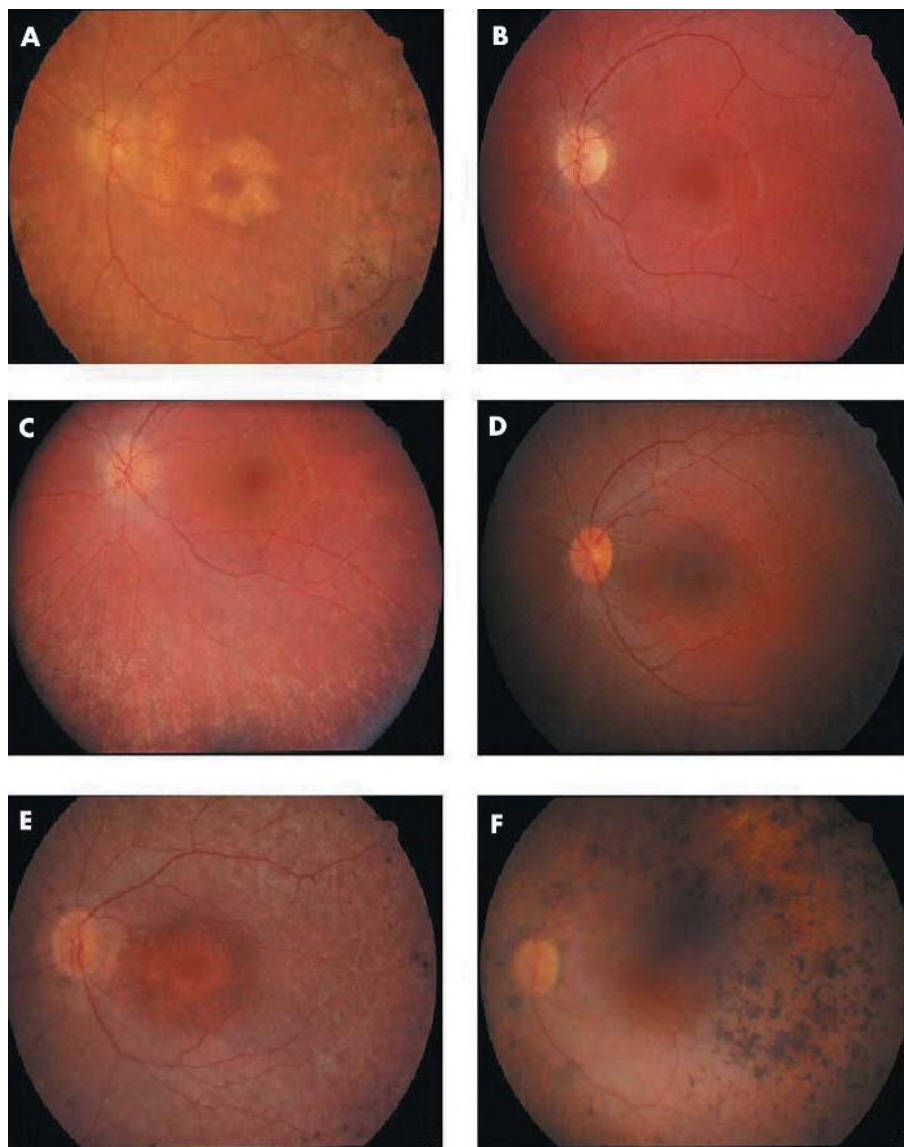


Figure 3 Fundus appearance. (A) Fundus image of affected man, aged 41 years. Note the parafoveal atrophy of the retinal pigment epithelium (RPE). There is RPE atrophy and bone spicules beyond the arcades. Arterioles are attenuated. (B) Fundus image of affected boy, aged 9 years. Note the relative lack of fundus findings. This patient has some pallor to the optic nerve and attenuation of his arterioles. Periphery demonstrated no evidence of RPE atrophy, bone spicules, or white dots. (C) Fundus image of affected girl, aged 11. Note the extensive white dots and RPE mottling in the mid-periphery. Bone spicules are notably absent. (D) Fundus image of affected girl, aged 16. Note the presence of white dots and RPE atrophy. Bone spicules are beginning to develop in the mid-periphery. (E) Fundus image of affected woman, aged 45 years. Note the extensive RPE thinning and atrophy both in the mid-periphery and the macula. The optic nerve is pale and there is arteriolar attenuation. (F) Fundus image of affected man, aged 57 years. Note the extensive RPE clumps in the mid-periphery and visible sclerotic choroidal vessels.

past whether RPA was a specific disorder or simply a phenotype or stage of classic RP,³³ recently, RPA has been recognised as a specific autosomal recessive retinal degeneration that results from mutations in the gene *RLBP1*.^{34–36} Admittedly, though, the white dots in RPA, although similar, are clinically different from those observed in our family.

In summary, we present a family with RP caused by an Arg135Leu mutation in rhodopsin. This family demonstrated a particularly severe course that was worse than families with cytoplasmic or intradiscal mutations in rhodopsin. From a cross sectional study of patients, we inferred the progression of disease for this family. In the first decade of life, affected patients will be symptomatic without clinical signs on fundus examination. By the second decade, patients develop extensive fine white dots at the level of the retinal pigment epithelium in the absence of extensive RPE atrophy or bone

spicules. The white dots fade by the third decade of life leaving bone spicules with widespread RPE atrophy. This appearance steadily worsens with increasing age and is associated with progressive decrease in visual field area. Patients uniformly developed cataracts by the second decade of life and appeared to respond favourably to cataract extraction. However, macular atrophy, as observed in our patients, is not uncommon in patients with changes at codon 135 of rhodopsin.^{7 17 30} Central acuity appeared to be closely related to the degree of macular atrophy.¹⁷

Description of disease natural history is becoming increasingly important with the future of hereditary retinal degenerations directed towards intervention. This family demonstrates how a specific phenotype may be present only for a brief period in a patient's life. While this is not the first paper to describe the association of a white dot phenotype

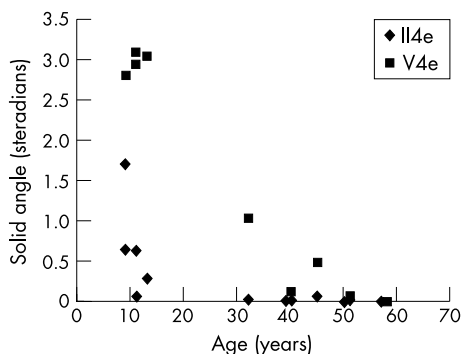


Figure 4 Graph showing solid angle of visual field for patients for II4e and V4e isoptres at their particular age. II4e isoptres are depicted by diamonds and the V4e isoptres are depicted by squares. Note that the II4e isoptre is essentially unrecordable in patients over the age of 35 years and the V4e isoptre is minimally recordable by 50 years of age.

with rhodopsin, we are the first to clearly document that this clinical appearance is largely dependent on the age of the subject. We also further demonstrated the importance of age and genotype for the modelling of disease course as previously described.³⁷ The R^2 value predicts that up to 40.7% of disease variation may be predicted on the basis of patient age and specific genotype. While other factors will influence disease course, this value calls attention to the importance of these two variables. The severity of this particular form of retinitis pigmentosa and the careful understanding of its natural history will be important considerations in the inclusion of patients with this condition in future clinical trials.

ACKNOWLEDGEMENTS

Supported in part by a career development award from the Foundation Fighting Blindness (KTO) and unrestricted grants from the Foundation Fighting Blindness (RGW and EMS), Research to Prevent Blindness (RGW and EMS). The authors thank the assistance of Gary Weaver, MD, Donald Bowden, PhD, and Joan Winnicki from Wake Forest University in identifying this family for further studies. The authors would also like to thank Cassandra Janowski, Andrea Billingslea, and Azadeh Rohanian Perry for their assistance in manuscript preparation and patient care.

Authors' affiliations

K T Oh*, **A Parikh**, **J White**, **K A DeBoer-Shields**, **C Vallar**, Department of Ophthalmology, University of North Carolina, Chapel Hill, NC, USA

D M Oh†, Chapel Hill, NC, USA

R G Weleber, Casey Eye Institute, Oregon Health and Science University, Portland, OR, USA

E M Stone, **L Streb**, Department of Ophthalmology and Visual Sciences, University of Iowa Hospitals and Clinics, Iowa City, IA, USA

*Currently a member of the Retina Eye Center, Augusta, GA, USA.

†Continues freelance biostatistical work in Augusta, GA, USA.

Correspondence to: Richard G Weleber, MD, Casey Eye Institute, 3375 SW Terwilliger, Portland, Oregon 97239-4197, USA; weleber@ohsu.edu

Accepted for publication 24 April 2004

REFERENCES

- Sohocki MM**, Daiger SP, Bowne SJ, et al. Prevalence of mutations causing retinitis pigmentosa and other inherited retinopathies. *Hum Mutat* 2001;**17**:42–51.
- Bunker CH**, Berson EL, Bromley WC, et al. Prevalence of retinitis pigmentosa in Maine. *Am J Ophthalmol* 1984;**97**:357–65.
- Dickinson P**, Mulhall L. A survey of hereditary aspects of pigmentary retinal dystrophies. *Aust N Z J Ophthalmol* 1989;**17**:247–56.

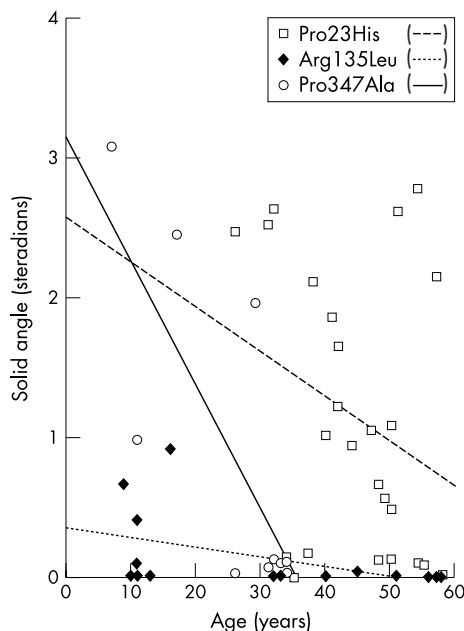


Figure 5 Graph comparing the solid angle of visual field for the I4e isoptre of three mutations in rhodopsin: Pro23His, Pro347Ala, and Arg135Leu. Note that patients with the intradiscal change (Pro23His) have the most recordable visual field over time and that those with the transmembrane change (Arg135Leu) have the worst overall visual fields.

- Sung C-H**, Davenport CM, Hennessey JC, et al. Rhodopsin mutations in autosomal dominant retinitis pigmentosa. *Proc Natl Acad Sci USA* 1991;**88**:6481–6485.
- Sandberg MA**, Weigel-DiFranco C, Dryja TP, et al. Clinical expression correlates with location of rhodopsin mutation in dominant retinitis pigmentosa. *Invest Ophthalmol Vis Sci* 1995;**36**:1934–42.
- Sung C-H**, Schneider BG, Agarwal N, et al. Functional heterogeneity of mutant rhodopsins responsible for autosomal dominant retinitis pigmentosa. *Proc Natl Acad Sci USA* 1991;**88**:8840–4.
- Jacobson SG**, Kemp CM, Sung C-H, et al. Retinal function and rhodopsin levels in autosomal dominant retinitis pigmentosa with rhodopsin mutations. *Am J Ophthalmol* 1991;**112**:256–71.
- Marmor MF**, Zrenner E, for the Standardization Committee of the International Society for Clinical Electrophysiology of Vision (ISCEV). Standard for clinical electroretinography (1994 update). *Doc Ophthalmol* 1995;**89**:199–210.
- Marmor MF**, Hood DC, Keating D, et al. Guidelines for basic multifocal electroretinography (mfERG). *Doc Ophthalmol* 2003;**106**:105–15.
- Weleber RG**, Tobler WR. Computerized quantitative analysis of kinetic visual fields. *Am J Ophthalmol* 1986;**101**:461–8.
- Oh KT**, Weleber RG, Lotery A, et al. Description of a new mutation in rhodopsin, Pro23Ala, and comparison with electroretinographic and clinical characteristics of the Pro23His mutation. *Arch Ophthalmol* 2000;**118**:1269–76.
- Newton CR**, Graham A, Heptinstall LE, et al. Analysis of any point mutation in DNA. The amplification refractory mutation system (ARMS). *Nucleic Acids Res* 1989;**17**:2503–16.
- Bassam BJ**, Caetano-Anolles G, Gresshoff PM. Fast and sensitive silver staining of DNA in polyacrylamide gels. *Anal Biochem* 1991;**196**:80–3.
- Buffone GJ**, Darlington GJ. Isolation of DNA from biological specimens without extraction with phenol. *Clin Chem* 1985;**31**:164–5.
- Andréasson S**, Ehinger B, Abrahamson M, et al. A six-generation family with autosomal dominant retinitis pigmentosa and a rhodopsin gene mutation (arginine-135-leucine). *Ophthalmic Paediatrics and Genetics* 1992;**13**:145–153.
- Dryja TP**. Doyné Lecture. Rhodopsin and autosomal dominant retinitis pigmentosa. *Eye* 1992;**6**:1–10.
- Pannarale MR**, Grammatico B, Iannaccone A, et al. Autosomal dominant retinitis pigmentosa associated with an Arg-135-Trp point mutation of the rhodopsin gene: clinical features and longitudinal observations. *Ophthalmology* 1996;**103**:1443–52.
- Fishman GA**, Stone EM, Sheffield VC, et al. Ocular findings associated with rhodopsin gene codon 17 and codon 182 transition mutations in dominant retinitis pigmentosa. *Arch Ophthalmol* 1992;**110**:54–62.
- Fishman GA**, Stone EM, Gilbert LD, et al. Ocular findings associated with a rhodopsin gene codon 106 mutation: glycine-to-arginine change in autosomal dominant retinitis pigmentosa. *Arch Ophthalmol* 1992;**110**:646–53.

- 20 **Fishman GA**, Stone EM, Gilbert LD, *et al.* Ocular findings associated with a rhodopsin gene codon 58 transversion mutation in autosomal dominant retinitis pigmentosa. *Arch Ophthalmol* 1991;**109**:1387-93.
- 21 **Heckenlively JR**, Rodriguez JA, Daiger SP. Autosomal dominant sectoral retinitis pigmentosa: two families with transversion mutation in codon 23 of rhodopsin. *Arch Ophthalmol* 1991;**109**:84-91.
- 22 **Moore AT**, Fitzke FW, Kemp CM, *et al.* Abnormal dark adaptation kinetics in autosomal dominant sector retinitis pigmentosa due to rod opsin mutation. *Br J Ophthalmol* 1992;**76**:465-9.
- 23 **Kranich H**, Bartowski S, Denton MJ, *et al.* Autosomal dominant "sector" retinitis pigmentosa due to a point mutation predicting an Asn-15-Ser substitution of rhodopsin. *Hum Mol Genet* 1993;**2**:813-14.
- 24 **Dryja TP**, Berson EL, Rao V, *et al.* Heterozygous missense mutation in the rhodopsin gene as a cause of congenital stationary night blindness. *Nat Genet* 1993;**4**:280-3.
- 25 **Dryja TP**. Molecular genetics of Oguchi disease, fundus albipunctatus and other forms of stationary night blindness: LVII Edward Jackson Memorial Lecture. *Am J Ophthalmol* 2000;**130**:547-63.
- 26 **Sieving PA**, Richards JE, Naarendorf F, *et al.* Dark-light: model for nightblindness from the human rhodopsin Gly-90 Asp mutation. *Proc Natl Acad Sci USA* 1995;**92**:880-4.
- 27 **Sieving PA**, Fowler ML, Bush RA, *et al.* Constitutive "light" adaptation in rods from G90D rhodopsin: a mechanism for human congenital nightblindness without rod cell loss. *J Neurosci* 2001;**21**:5449-60.
- 28 **Berson EL**, Rosner B, Weigel-DiFranco C, *et al.* Disease progression in patients with dominant retinitis pigmentosa and rhodopsin mutations. *Invest Ophthalmol Vis Sci* 2002;**43**:3027-36.
- 29 **Berson EL**, Rosner B, Sandberg MA, *et al.* Ocular findings in patients with autosomal dominant retinitis pigmentosa and rhodopsin, proline-347-leucine. *Am J Ophthalmol* 1991;**111**:614-23.
- 30 **Ponjavic V**, Abrahamson M, Andreasson S, *et al.* Autosomal dominant retinitis pigmentosa with a rhodopsin mutation (Arg-135-Trp). *Acta Ophthalmol Scand* 1997;**75**:218-23.
- 31 **Souied E**, Soubrane G, Benlian P, *et al.* Retinitis punctata albescens associated with the Arg135Trp mutation in the rhodopsin gene. *Am J Ophthalmol* 1996;**121**:19-25.
- 32 **Lauber H**. Die sogenannte Retinitis punctata albescens. *Klin Monatsbl Augenheilkd* 1910;**48**:133-48.
- 33 **Deutman AF**. Rod-cone dystrophy: primary, hereditary, pigmentary retinopathy, retinitis pigmentosa. In: Krill AE, eds. *Krill's hereditary retinal and choroidal diseases*. New York: Harper & Row, 1977:479-576.
- 34 **Morimura H**, Berson EL, Dryja TP. Recessive mutations in the RLBP1 gene encoding cellular retinaldehyde-binding protein in a form of retinitis punctata albescens. *Invest Ophthalmol Vis Sci* 1999;**40**:1000-4.
- 35 **Burstedt MS**, Sandgren O, Holmgren G, *et al.* Bothnia dystrophy caused by mutations in the cellular retinaldehyde-binding protein gene (RLBP1) on chromosome 15q26. *Invest Ophthalmol Vis Sci* 1999;**40**:995-1000.
- 36 **Eichers ER**, Green JS, Stockton DW, *et al.* Newfoundland rod-cone dystrophy, an early-onset retinal dystrophy, is caused by splice-junction mutations in RLBP1. *Am J Hum Genet* 2002;**70**:955-64.
- 37 **Oh KT**, Longmuir R, Oh DM, *et al.* Comparison of the clinical expression of retinitis pigmentosa associated with rhodopsin mutations at codon 347 and codon 23. *Am J Ophthalmol* 2003;**136**:306-13.



Genotype-phenotype correlation in a family with Arg135Leu rhodopsin retinitis pigmentosa

K T Oh, D M Oh, R G Weleber, et al.

Br J Ophthalmol 2004 88: 1533-1537

doi: 10.1136/bjo.2004.043653

Updated information and services can be found at:

<http://bjo.bmj.com/content/88/12/1533.full.html>

These include:

References

This article cites 35 articles, 17 of which can be accessed free at:

<http://bjo.bmj.com/content/88/12/1533.full.html#ref-list-1>

Article cited in:

<http://bjo.bmj.com/content/88/12/1533.full.html#related-urls>

Email alerting service

Receive free email alerts when new articles cite this article. Sign up in the box at the top right corner of the online article.

Topic Collections

Articles on similar topics can be found in the following collections

[Retina](#) (1217 articles)

[Eye \(globe\)](#) (543 articles)

Notes

To request permissions go to:

<http://group.bmj.com/group/rights-licensing/permissions>

To order reprints go to:

<http://journals.bmj.com/cgi/reprintform>

To subscribe to BMJ go to:

<http://group.bmj.com/subscribe/>