

## EXTENDED REPORT

## Effect of niacin on the choroidal circulation of patients with age related macular degeneration

T I Metelitsina, J E Grunwald, J C DuPont, G-S Ying

*Br J Ophthalmol* 2004;**88**:1568–1572. doi: 10.1136/bjo.2004.046607

See end of article for authors' affiliations

Correspondence to:  
 Juan E Grunwald,  
 MD, Scheie Eye Institute,  
 Department of  
 Ophthalmology, University  
 of Pennsylvania, 51 North  
 39th Street, Philadelphia,  
 PA 19104, USA;  
[juangrun@mail.med.  
 upenn.edu](mailto:juangrun@mail.med.upenn.edu)

Accepted for publication  
 16 May 2004

**Aim:** To investigate the effects of niacin on choroidal blood flow in age related macular degeneration (AMD).

**Methods:** 12 AMD patients with bilateral drusen and visual acuity of 20/40 or better in the study eye received a single oral dose of niacin (six subjects received 500 mg and six received 250 mg) or matching placebo on two separate occasions. Laser Doppler flowmetry was used to assess relative choroidal blood velocity (ChB<sub>Vel</sub>), volume (ChB<sub>Vol</sub>), and flow (ChB<sub>Flow</sub>) in the foveola of the study eye at baseline, 30, and 90 minutes after dosing.

**Results:** In comparison with placebo, a statistically significant 24% increase in ChB<sub>Vol</sub> was observed 30 minutes after niacin administration (ANOVA,  $p=0.01$ ). In comparison with placebo, a significant decrease in ChB<sub>Vel</sub> of 23% was observed in the 500 mg group ( $p=0.04$ ) and no significant change in ChB<sub>Vel</sub> was seen in the 250 mg group at 30 minutes. No significant changes in ChB<sub>Flow</sub> were detected at 30 or 90 minutes. Also, there were no statistically significant changes in ChB<sub>Vol</sub> or ChB<sub>Vel</sub> at 90 minutes.

**Conclusion:** In comparison with placebo, a significant 24% increase in ChB<sub>Vol</sub> was observed 30 minutes after niacin administration. Owing to simultaneous decrease in ChB<sub>Vel</sub>, however, no significant change in ChB<sub>Flow</sub> was detected.

Immediate release niacin (crystalline nicotinic acid) is a widely used lipid lowering agent which was first introduced in 1954<sup>1</sup> and was the first monotherapy shown to significantly reduce cardiovascular all-cause mortality.<sup>2,3</sup> Niacin inhibits the production of very low density lipoprotein (VLDL) particles by the liver and consequently reduces the levels of circulating VLDL available for conversion to low density lipoproteins (LDL).<sup>4</sup> The oral administration of a standard therapeutic dose of 500 mg of immediate release niacin induces intense flushing reactions in humans.<sup>5</sup> The cutaneous capillary vasodilatation observed after niacin administration is the result of a massive release of prostaglandin PGD<sub>2</sub> from niacin responsive skin cells.<sup>5,6</sup>

Potentially, this vasodilatory quality of niacin could be of use in the treatment of age related macular degeneration (AMD) and other ocular diseases characterised by a decreased choroidal perfusion. Several recent reports have suggested that choroidal blood flow is reduced in AMD.<sup>7–15</sup> Results obtained in our laboratory have shown a significant 37% decrease in choroidal blood flow in subjects with the non-exudative form of macular degeneration.<sup>16</sup> The purpose of this study was to perform a preliminary assessment of the effects of niacin on the choroidal circulation of patients with AMD. Evidence of an effect of niacin on the choroidal circulation could open the way for further studies looking at the efficacy of niacin in the treatment of AMD.

## METHODS

This was a double blinded, randomised, placebo controlled, crossover study, which was carried out in a group of 12 white patients (nine women and three men) ranging in age from 62 to 84 years (mean 72 (SD 7) years). All patients had AMD features similar to those of AMD category 3 or worse of the AREDS study. In each patient, the eye with better visual acuity was considered as the study eye. All study eyes had large drusen and no evidence of choroidal neovascularisation (CNV). Retinal pigment epithelium hypertrophic changes were present in seven eyes and two eyes had a small area of

extrafoveal geographic atrophy. Two patients had exudative AMD with disciform scar in the fellow eye.

External, slit lamp, and funduscopy examination were unremarkable, except for the presence of mild nuclear sclerosis changes in nine study eyes and intraocular lens implants in two eyes. All subjects had visual acuity of 20/40 or better in the study eye and normal intraocular pressure (IOP) of 21 mm Hg or less. Four patients had a history of systemic hypertension and two of them were on antihypertensive medications. All study subjects took the same medications throughout the length of the study.

Seven of the 12 patients enrolled in the study were taking aspirin on a regular basis and they were asked to discontinue this drug the night before the study visit. This was done because aspirin is known to block prostaglandin mediated, nicotinic acid induced flushing<sup>17</sup> and we wanted to prevent blunting of the vasodilatory response.

The study and data accumulation were carried out with approval from University of Pennsylvania institutional review board. Detailed explanations of the study procedures were provided to all study participants. All subjects signed an appropriate institutional review board approved consent form. Since the study was completed before 14 April 2003, a HIPPA consent form was not required. The tenets of the Declaration of Helsinki were followed.

A single dose of immediate release niacin or matching placebo was administered orally on two separate occasions, at least 3 days apart. All subjects were initially randomised to receive either 500 mg of immediate release niacin or matching placebo. Two of the first six patients experienced intense drug related reactions with pronounced cutaneous flushing, strong nausea, dizziness, and loss of balance. Because of these strong side effects we decreased the dose

**Abbreviations:** AMD, age related macular degeneration; CS, contrast sensitivity; CV, coefficient of variability; LDL, low density lipoproteins; VA, visual acuity; VLDL, very low density lipoprotein

of niacin and the next six subjects were randomised to receive either 250 mg of immediate release niacin or placebo.

Placebo pills were designed to be identical to the niacin ones, but they did not contain the active component. To reduce the measurement bias, both the investigators and the patients were blinded to the treatment.

All circulatory measurements were performed in one eye of each patient (study eye). Measurements were obtained in the right eye in eight patients and in the left in four patients. Before administration of the drug, visual acuity (VA) was measured using ETDRS charts at 3.2 metres and contrast sensitivity (CS) testing was performed at 1 metre using Pelli-Robson contrast sensitivity charts.

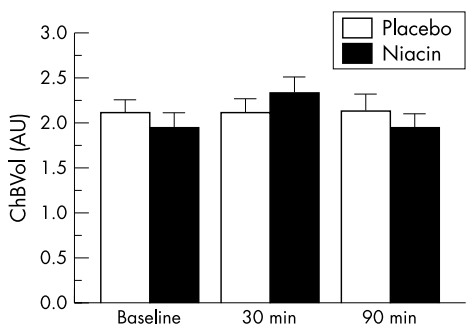
Pupils were dilated with 1% Mydracyl (Alcon, Ft Worth, TX, USA) and 10% Neo-Synephrine (Sanofil-Synthelabo, NY, USA) and VA and CS testing were repeated after dilatation.

Laser Doppler flowmetry (Oculix, Inc, Berwyn, PA, USA) was used to assess the foveolar choroidal circulation. This non-invasive technique provides measurements of relative choroidal blood velocity (ChB<sub>Vel</sub>), volume (ChB<sub>Vol</sub>), and flow (ChB<sub>Flow</sub>) in the centre of the foveola. We have chosen this location because in the centre of the foveola there is no retinal circulation to interfere with our choroidal blood flow determinations.

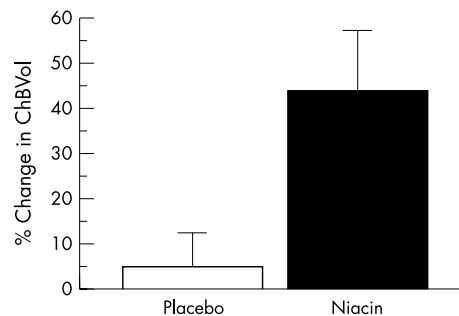
A diode laser beam (670 nm) with a 20 mW intensity and diameter of 200 µm was delivered to the eye through a fundus camera (model TRC; Topcon, Tokyo, Japan). Subjects were asked to fixate on the probing laser beam. Proper fixation was monitored by observation through the fundus camera. The light scattered back was electronically analysed. A detailed description of the technique has been previously reported.<sup>18-21</sup>

Three measurements of choroidal circulation of approximately 30 seconds were obtained while patients were seated in the darkened room. Following ocular circulatory measurements, heart rate (HR) and brachial artery systemic blood pressure were assessed by automated sphygmomanometry (Accutorr 1A, Datascope, Paramus, NJ, USA). IOP was measured by Tonopen in both eyes.

To assess the reproducibility of our blood flow data, we calculated for each of the 12 subjects a coefficient of variability (CV) derived from three subsequent measurements in time (baseline, 30 minutes, and 90 minutes) on the day of placebo administration. CV was calculated using the following formula: CV = (standard deviation/mean) × 100. The mean brachial artery pressure (BpM) was calculated from the systolic blood pressure (BPs) and diastolic blood pressure (BPd) according to the following formula: BpM = BPd + 1/3(BPs - BPd). Perfusion pressure (PP) for the study



**Figure 1** Average choroidal blood volume (ChB<sub>Vol</sub>) in arbitrary units (AU) at baseline, 30 minutes, and 90 minutes after treatment with placebo and niacin for the 12 subjects (500 and 250 mg dose of niacin) analysed together. In comparison with placebo, a significant effect on ChB<sub>Vol</sub> was detected following niacin administration (ANOVA; p=0.01). Error bars correspond to ± 1 SE.



**Figure 2** Percentage change in choroidal blood volume (ChB<sub>Vol</sub>) at 30 minutes after treatment with placebo and niacin for the six subjects who received 500 mg dose of niacin. In comparison with placebo, a significant effect on ChB<sub>Vol</sub> was detected following niacin administration (ANOVA; p=0.03). Error bars correspond to ± 1 SE.

eye was estimated according to the following formula: PP = 2/3BpM - IOP.

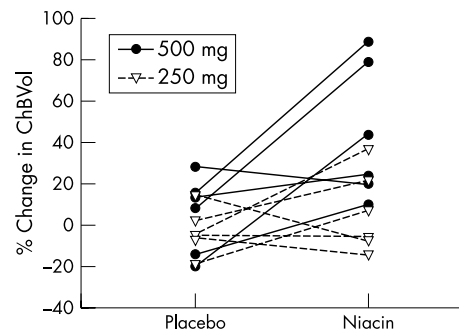
All measurements were repeated 30 and 90 minutes after drug administration. The same protocol was performed on the second study visit, and the alternative drug was tested. None of the study participants was under fasting conditions. An individual masked to treatment information performed analysis of the blood flow measurements using a NEXT computer. VA and CS data obtained at 30 and 90 minutes were compared to those obtained at the baseline after pupillary dilatation.

Statistical analysis of the data was performed using analysis of variance (ANOVA) for repeated measures comparing the effects of niacin with those of placebo. Simple regression analysis was also performed. Statview software (Cary, NC, USA) was used for this purpose. Findings with p ≤ 0.05 were considered to be statistically significant. All circulatory measurements are shown in arbitrary units (AU).

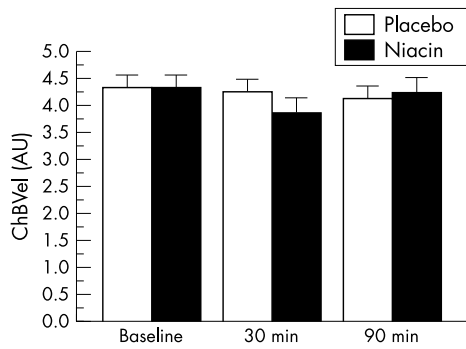
**RESULTS**

When all 12 subjects were analysed together, mean ChB<sub>Vol</sub> at baseline, 30 minutes, and 90 minutes was 0.21 (SD 0.05) AU, 0.21 (0.05) AU, and 0.21 (0.06) AU following placebo, and 0.19 (0.06) AU, 0.23 (0.06) AU, and 0.19 (0.06) AU following administration of niacin, respectively (fig 1). In comparison with placebo, a statistically significant 24% increase in mean ChB<sub>Vol</sub> was observed 30 minutes after niacin administration (ANOVA; p = 0.01).

Most of the circulatory effect of niacin on ChB<sub>Vol</sub> was dose related and derived from the six subjects who received the 500 mg dose. Further analysis carried out in this group of six patients, showed a 39% increase in mean ChB<sub>Vol</sub> at 30 minutes after niacin administration (ANOVA, p = 0.03,



**Figure 3** For each subject, a comparison of the percentage change in choroidal blood volume (ChB<sub>Vol</sub>) 30 minutes following placebo and niacin 250 and 500 mg.

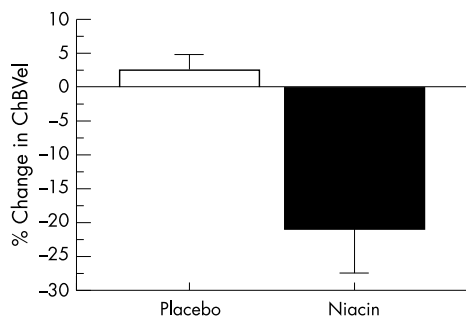


**Figure 4** Average choroidal blood velocity (ChB<sub>Vel</sub>) in arbitrary units (AU) at baseline, 30 minutes, and 90 minutes after treatment with placebo and niacin for the 12 subjects (500 and 250 mg dose of niacin) analysed together. In comparison with placebo, no significant effect on ChB<sub>Vel</sub> was detected following niacin treatment (ANOVA;  $p=0.17$ ). Error bars correspond to  $\pm 1$  SE.

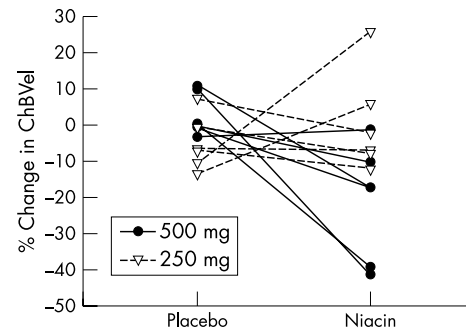
fig 2) in contrast with a 10% increase in mean ChB<sub>Vol</sub> in the group of six subjects who received 250 mg of niacin (ANOVA,  $p=0.36$ ). Figure 3 shows the individual values for percentage change in ChB<sub>Vol</sub> for the subjects who received 250 mg and 500 mg of niacin. There were no statistically significant changes in mean ChB<sub>Vol</sub> at 90 minutes.

In comparison with placebo, there was no statistically significant change in mean ChB<sub>Vel</sub> after niacin administration at 30 minutes or 90 minutes for the group of 12 patients (ANOVA;  $p=0.17$ ; fig 4). Mean ChB<sub>Vel</sub> at baseline, 30 minutes, and 90 minutes were 0.43 (0.09) AU, 0.42 (0.08) AU, and 0.41 (0.08) AU following administration of placebo, and 0.43 (0.07) AU, 0.38 (0.1) AU, and 0.42 (0.1) AU after niacin, respectively. When the analysis of ChB<sub>Vel</sub> was conducted separately for the six subjects who received 500 mg of niacin, however, we found a significant 23% decrease in mean ChB<sub>Vel</sub> at 30 minutes (ANOVA;  $p=0.04$ ; fig 5). No significant effect on mean ChB<sub>Vel</sub> was observed in the niacin 250 mg group. Figure 6 shows the individual values for percentage change in ChB<sub>Vel</sub> for the subjects who received 250 mg and 500 mg of niacin. There were no statistically significant changes in mean ChB<sub>Vel</sub> at 90 minutes.

In comparison with placebo, no statistically significant change in mean ChB<sub>Flow</sub> was detected after niacin at any of the time points (ANOVA;  $p=0.64$ ; fig 7). Mean ChB<sub>Flow</sub> at baseline, 30 minutes, and 90 minutes was 8.1 (2.2) AU, 8.0 (2.5) AU, and 7.8 (2.5) AU following administration of placebo and 7.5 (2.4) AU, 7.9 (2.7) AU, and 7.2 (2.9) AU after niacin, respectively. No changes in ChB<sub>Flow</sub> were detected in



**Figure 5** Percentage change in choroidal blood velocity (ChB<sub>Vel</sub>) at 30 minutes after treatment with placebo and niacin for the six subjects who received 500 mg dose of niacin. In comparison with placebo, a significant effect on ChB<sub>Vel</sub> was detected following niacin administration (ANOVA;  $p=0.04$ ). Error bars correspond to  $\pm 1$  SE.



**Figure 6** For each subject, a comparison of the percentage change in choroidal blood velocity (ChB<sub>Vel</sub>) 30 minutes following placebo and niacin 250 and 500 mg.

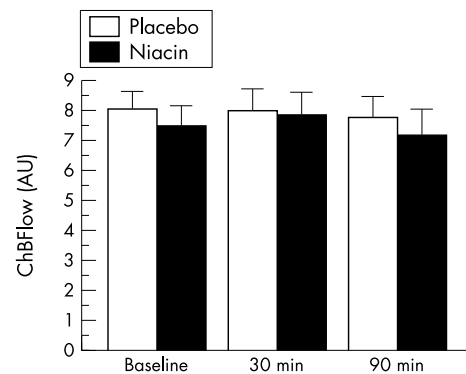
the group of six subjects, who received 500 mg of niacin (ANOVA;  $p=0.93$ ; fig 8).

Because we found no significant change in ChB<sub>Flow</sub> it is important to provide information on the magnitude of the changes that we would be able to detect with our methodology. We have estimated that we have 96% power to detect 20% changes in ChB<sub>Flow</sub> at type I error of 0.05. The coefficients of variability for ChB<sub>Vel</sub>, ChB<sub>Vol</sub> and ChB<sub>Flow</sub> were 6% (4%), 10% (7%) 10% (6%) respectively.

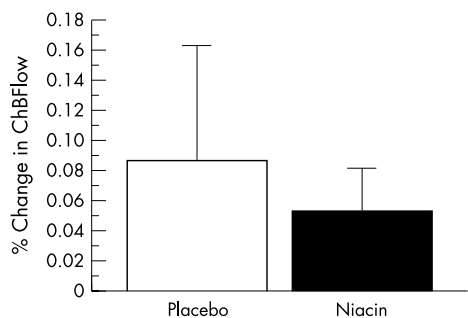
There were no statistically significant changes in mean contrast sensitivity or mean visual acuity at any of the time points (table 1). In comparison with placebo, there was a 9% decrease in BPM at 30 minutes after niacin administration ( $t$  test,  $p=0.02$ ), a 7% increase in heart rate at 30 minutes ( $p=0.01$ ), and a decrease of 9% at 90 minutes ( $p=0.05$ ). A significant decrease in IOP of 23% was also seen at 30 minutes after niacin administration ( $p=0.01$ ).

There was no significant correlation between the percentage changes in BPM, PP, or IOP and the percentage changes in ChB<sub>Vel</sub>, ChB<sub>Vol</sub> and ChB<sub>Flow</sub> after administration of placebo or niacin. We observed a direct correlation of borderline significance between age and the % change in ChB<sub>Vol</sub> at 30 minutes after administration of niacin ( $R=+0.565$ ,  $p=0.055$ ; fig 9); in other words, after niacin administration older individuals tended to show larger increases in ChB<sub>Vol</sub> than younger ones. No such significant correlation was seen after placebo treatment.

From the 12 subjects who participated in the study six experienced side effects related to niacin treatment. Two people experienced intense flushing with nausea, dizziness,



**Figure 7** Average choroidal blood flow (ChB<sub>Flow</sub>) in arbitrary units (AU) at baseline, 30 minutes, and 90 minutes after treatment with placebo and niacin for the 12 subjects (500 and 250 mg dose of niacin) analysed together. In comparison with placebo, no significant effect on ChB<sub>Flow</sub> was detected following niacin administration (ANOVA;  $p=0.64$ ). Error bars correspond to  $\pm 1$  SE.



**Figure 8** Percentage change in choroidal blood flow (ChB<sub>Flow</sub>) at 30 minutes after treatment with placebo and niacin for the six subjects that received 500 mg dose of niacin. In comparison with placebo, no significant effect on ChB<sub>Flow</sub> was detected following niacin administration (ANOVA;  $p=0.93$ ). Error bars correspond to  $\pm 1$  SE.

and loss of balance. These two subjects were not taking aspirin before the study. The other four subjects experienced mild hyperaemia of face and neck. Two of them were taking aspirin before the study and two of them were not. There was no association between flushing reactions and changes in circulatory parameters.

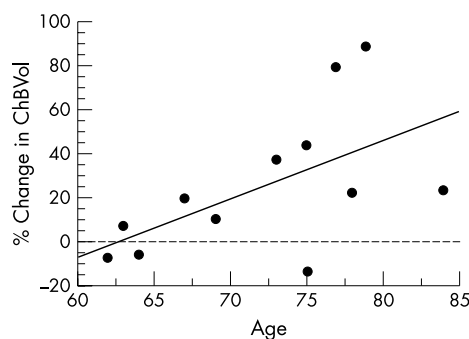
**DISCUSSION**

The peak plasma concentration of niacin occurs about 30 minutes after oral administration.<sup>22</sup> Our results suggest at this time there is a statistically significant increase in ChB<sub>Vol</sub> of 24% when all 12 subjects are analysed together. Concurrently, however, there is also a decrease in ChB<sub>Vel</sub> that is statistically significant in the group of six subjects that received the 500 mg dose. Because the increase in ChB<sub>Vol</sub> is accompanied by a simultaneous decrease in ChB<sub>Vel</sub> there is no significant change in ChB<sub>Flow</sub>. Possibly, this could be due to an autoregulatory attempt to maintain a constant choroidal blood flow.

Interestingly, 30 minutes after niacin we observed a direct correlation of borderline significance ( $p = 0.055$ ) between age and the percentage change in ChB<sub>Vol</sub>. In other words, older individuals tended to show larger increases in ChB<sub>Vol</sub>, suggesting that perhaps older individuals may have less robust autoregulatory responses (fig 9).

This increase in ChB<sub>Vol</sub> seen in our study is similar to the results of Chandra and Friedman,<sup>23</sup> who used the krypton desaturation technique in anaesthetised cats and found decreased choroidal vascular resistance after niacin administration.

Our results show that a larger increase in ChB<sub>Vol</sub> is present in the six patients who received the higher dose of 500 mg (39% increase,  $p = 0.03$ ) than in the group with a lower dose of 250 mg (10% increase,  $p = 0.36$ ). This suggests that the lower concentration of systemically administered niacin may not be sufficient to saturate the receptor sites in the choroidal vasculature to cause a large increase in ChB<sub>Vol</sub>. This finding is in agreement with the results of Chandra and Friedman,<sup>23</sup> who did not detect choroidal circulatory changes with systemic doses but observed decrease in vascular resistance



**Figure 9** Percentage change in choroidal blood volume (ChB<sub>Vol</sub>) 30 minutes after niacin treatment versus age ( $R = +0.565$ ;  $p = 0.055$ ; % change in ChB<sub>Vol</sub> =  $160 + 2.6$  age).

following direct niacin administration through the posterior ciliary artery. This last route of administration most probably achieved a higher concentration in the choroid.

An increase in the ChB<sub>Vol</sub> parameter measured by the LDF technique most probably represents an increase in the number of red blood cells present within the tissue measured by the laser Doppler flowmetry technique. Such an increase may be caused by vasodilatation, capillary recruitment, or increase in the haematocrit.

We have previously reported that ChB<sub>Flow</sub> is reduced by 37% in patients with age related macular degeneration (AMD) in comparison with age matched normal controls. This phenomenon is mainly due to a 33% reduction in ChB<sub>Vol</sub>. Studies showing obliteration of choriocapillaries in the macular area,<sup>24</sup> narrowing of the lumen and loss of the cellularity of choriocapillaries,<sup>25</sup> and thinning of the choroid, especially the choriocapillaris layer<sup>9</sup> provide evidence of AMD related morphological changes that could explain a decrease in choroidal blood volume and flow observed in AMD.

Because of this decrease in ChB<sub>Flow</sub> in AMD it is possible that therapies that increase the circulation of the choroid may be of benefit in the treatment of AMD. Further studies are needed to investigate whether niacin may have a potential role in the treatment of AMD.

Our current study suggests increases in ChB<sub>Vol</sub> in AMD patients after treatment with niacin. Whether this may be of benefit to patients with AMD is beyond the scope of this article. Theoretically, however, it is possible that an increase in ChB<sub>Vol</sub> may facilitate the diffusion of gases and substances across the RPE-Bruch's membrane. This may improve removal of the waste products and metabolic debris from the outer retina, a process that is probably impaired in AMD leading to the accumulation of drusen material.

The circulatory changes observed after niacin ingestion may have a role in the development of reversible nicotinic acid maculopathy, which has been observed in patients taking high doses of niacin as a lipid lowering agent. Gass<sup>26</sup> was the first one to report three cases of nicotinic acid maculopathy. Similar cases were reported by Millay<sup>27</sup> and Callanan<sup>28</sup> in patients who took 1–6 g of niacin daily and recovered upon discontinuation of niacin. A recent study by

**Table 1** Mean number of letters correctly identified during contrast sensitivity and visual acuity testing

		Baseline	30 minutes	90 minutes	p Value (ANOVA)
Contrast sensitivity	Placebo	31.8 (6.6)	31.6 (7.5)	31.4 (7.31)	0.83
	Niacin	32.4 (5.9)	31.8 (5.3)	31.8 (6.0)	
Visual acuity	Placebo	50.6 (10.4)	49.4 (10.3)	49.0 (12.6)	0.89
	Niacin	51.5 (10.8)	49.8 (11.8)	49.3 (13.3)	

Spirn<sup>29</sup> showed the presence of cystoid spaces mainly in the outer plexiform layer. Although the mechanism responsible for this type of reversible maculopathy is not well known, impairment of the blood-retinal barrier does not seem to play a large part, since there is no evidence of increased leakage on fluorescein angiography.<sup>27</sup> Possibly, changes in the choroidal circulation such as the increased ChB<sub>Vol</sub> and decreased ChB<sub>Vel</sub>, observed in our study with the higher doses of nicotinic acid may facilitate extravasation of fluid from the blood vessels leading to a disturbed metabolism of the outer retina with intracellular fluid accumulation.<sup>27</sup>

Our results show a significant increase in heart rate at 30 minutes after niacin, similar to those reported by Gadegbeku *et al*<sup>30</sup> and decrease in heart rate at 90 minutes. These effects represent a compensatory response to a decrease in peripheral vascular resistance and as a result decreased BPm, which we observed 30 minutes after treatment with niacin. They are aimed to maintain constant cardiac output.

Our results do not show any effect of niacin on visual acuity or contrast sensitivity suggesting that the changes in ChB<sub>Vol</sub> and ChB<sub>Vel</sub> do not result in a large effect on visual function.

In summary, our results suggest that therapeutic doses of niacin produce changes in choroidal circulation in AMD patients. Additional studies are needed in order to find out whether this type of therapy may be of benefit in patients with this condition.

#### Authors' affiliations

T I Metelitsina, J E Grunwald, J C DuPont, G-S Ying, Scheie Eye Institute, Department of Ophthalmology, University of Pennsylvania, Philadelphia, PA, USA

Grant/financial support: NIH grant EY 12769, the Vivian S Lasko Research Fund and Research to Prevent Blindness.

Disclosure statement: None of the authors have any conflict of interest regarding the contents of the article.

Commercial relationship: None.

#### REFERENCES

- Knopp RH. Drug treatment of lipid disorders. *N Engl J Med* 1999;**341**:498–511.
- The Coronary Drug Project Research Group. Clofibrate and niacin in coronary heart disease. *JAMA*, 1975;**231**, 360–81.
- Canner PL, Berge KG, Wenger NK, *et al*. Fifteen-year mortality in Coronary Drug Project patients: long-term benefit with niacin. *J Am Coll Cardiol* 1986;**8**:1245–55.
- Clark AB, Holt JM. Identifying and managing patients with hyperlipidemia. *Am J Managed Care* 1997;**3**:1211–19.
- Morrow JD, Awad JA, Oates J, *et al*. Identification of skin as a major site of prostaglandin D2 release following oral administration of niacin in humans. *J Invest Dermatol* 1992;**98**:812–15.
- Morrow JD, Parsons WG, Roberts J. Release of markedly increased quantities of prostaglandin D2 in vivo in humans following the administration of nicotinic acid. *Prostaglandins* 1989;**28**:263–74.
- Pauleikhoff D, Chen JC, Chisholm IH, *et al*. Choroidal perfusion abnormality with age-related Bruch's membrane change. *Am J Ophthalmol* 1990;**109**:211–17.
- Boker T, Fang T, Steinmetz R. Refractive error and choroidal perfusion characteristics in patients with choroidal neovascularization and age-related macular degeneration. *Ger J Ophthalmol* 1993;**2**:10–13.
- Sarks SH. Aging and degeneration in the macular region: a clinicopathological study. *Br J Ophthalmol* 1976;**60**:324–341.
- Sarks SH, Sarks J, Killingsworth C. Evolution of geographic atrophy of the retinal pigment epithelium. *Eye* 1988;**2**:552–8.
- Chen JE, Fitzke FW, Pauleikhoff D, *et al*. Functional loss in age-related Bruch's membrane change with choroidal perfusion defect. *Invest Ophthalmol Vis Sci* 1992;**33**:334–40.
- Holz FG, Wolfensberger TJ, Piguet B, *et al*. Bilateral macular drusen in age related macular degeneration: prognosis and risk factors. *Ophthalmology* 1994;**101**:1522–8.
- Prunte C, Niesel P. Quantification of choroidal blood-flow parameters using indocyanine green video-fluorescence angiography and statistical picture analysis. *Graefes Arch Ophthalmol* 1988;**226**:55–8.
- Friedman E, Ivry M, Ebert E, *et al*. Increased scleral rigidity and age-related macular degeneration. *Ophthalmology* 1989;**196**:104–8.
- Friedman E, Krupsky S, Lane AM, *et al*. Ocular blood flow velocity in age-related macular degeneration. *Ophthalmology* 1995;**102**:640–646.
- Grunwald JE, Hariprasad SM, DuPont J, *et al*. Foveolar choroidal blood flow in age-related macular degeneration. *Invest Ophthalmol Vis Sci* 1998;**39**:385–90.
- Wilkin JK, Wilkin O, Kapp R, *et al*. Aspirin blocks nicotinic acid-induced flushing. *Clin Pharmacol Ther* 1982;**3**:478–82.
- Riva CE, Granstoun SD, Grunwald JE, *et al*. Choroidal blood flow in the foveal region of the human ocular fundus. *Invest Ophthalmol Vis Sci* 1994;**35**:4273–81.
- Riva CE, Harino S, Petrig BL, *et al*. Laser-Doppler flowmetry in the optic nerve. *Exp Eye Res* 1992;**55**:499–506.
- Petrig BL, Riva CE. Optic nerve head laser Doppler flowmetry: principles and computer analysis. In: Kaiser JH, Flammer J, Hendrickson P, eds. *Ocular blood flow*. Basel: Karger, 1996:120–7.
- Riva CE, Mendel M, Petrig BL. Flicker-induced optic nerve blood flow change. In: Kaiser HJ, Flammer J, Hendrickson P, eds. *Ocular blood flow*. Basel: Karger, 1996:128–37.
- Craig CR, Stitzel RE. *Modern pharmacology*. Boston/Toronto: Little, Brown and Company, 1986:1–338.
- Chandra SR, Friedman E. Choroidal blood flow. IV. Effect of vasodilating agents. *Arch Ophthalmol* 1979;**97**:1331–2.
- Duke-Elder S. *System of ophthalmology*. St Louis: CV Mosby, 1966, 9:609–13.
- Korenzweig AB. Changes in the choriocapillaries associated with senile macular degeneration. *Ann Ophthalmol* 1977;**9**:753–64.
- Gass JD. Nicotinic acid maculopathy. *Am J Ophthalmol* 1973;**76**:500–510.
- Millay RH, Klein ML, Illingworth DR. Niacin maculopathy. *Ophthalmology* 1988;**95**:930–936.
- Callanan D, Blodi BA, Martin DF. Macular edema associated with nicotinic acid (niacin). *JAMA* 1998;**279**:1702.
- Spirn MJ, Warren FA, Guyer DR, *et al*. Optical coherence tomography findings in nicotinic acid maculopathy. *Am J Ophthalmol* 2003;**135**:913–44.
- Gadegbeku CA, Dhandayuthapani A, Shrayef MZ, *et al*. Hemodynamic effects of nicotinic acid infusion in normotensive and hypertensive subjects. *Am J Hypertens* 2003;**16**:67–71.



## Effect of niacin on the choroidal circulation of patients with age related macular degeneration

T I Metelitsina, J E Grunwald, J C DuPont, et al.

*Br J Ophthalmol* 2004 88: 1568-1572

doi: 10.1136/bjo.2004.046607

---

Updated information and services can be found at:

<http://bjo.bmj.com/content/88/12/1568.full.html>

---

*These include:*

### References

This article cites 22 articles, 7 of which can be accessed free at:

<http://bjo.bmj.com/content/88/12/1568.full.html#ref-list-1>

### Email alerting service

Receive free email alerts when new articles cite this article. Sign up in the box at the top right corner of the online article.

---

### Topic Collections

Articles on similar topics can be found in the following collections

[Retina](#) (1207 articles)

---

### Notes

---

To request permissions go to:

<http://group.bmj.com/group/rights-licensing/permissions>

To order reprints go to:

<http://journals.bmj.com/cgi/reprintform>

To subscribe to BMJ go to:

<http://group.bmj.com/subscribe/>