

## SCIENTIFIC REPORT

# Long term outcome of secondary glaucoma following vitreoretinal surgery

P Tranos, R Asaria, W Aylward, P Sullivan, W Franks

*Br J Ophthalmol* 2004;88:341–343. doi: 10.1136/bjo.2003.028076

**Purpose:** To determine the long term outcome of secondary glaucoma following retinal reattachment surgery.

**Method:** A longitudinal retrospective study was undertaken of the medical records of patients referred to the Glaucoma Service at Moorfields Eye Hospital following retinal reattachment surgery. The main outcome measures were final intraocular pressure (IOP), progression in cup:disc ratio, and final visual acuity outcome.

**Results:** A total of 70 eyes of 70 patients (41 males and 29 females) were identified and included in the analysis. Mean increase of IOP 2–3 weeks following the first vitreoretinal procedure was 6 (SD 3) mm Hg. After a mean follow up of approximately 4 years the mean IOP had significantly decreased from 33 (SD 10) to 16 (SD 8) mm Hg ( $p < 0.001$ ). The visual outcome of eyes with final IOP less than 6 or greater than 21 mm Hg was significantly worse compared with those eyes with a normal (6–21 mm Hg) range of pressure ( $p = 0.022$  and  $p = 0.009$  respectively). Despite the effective control of IOP in the majority of patients during the follow up period, there was mild progression of the mean vertical cup:disc ratio from 0.6 (SD 0.2) to 0.7 (SD 0.2) ( $p < 0.001$ ).

**Conclusion:** Secondary glaucoma is a major complication following retinal reattachment surgery. Medical treatment is successful in lowering IOP in most patients. In persisting cases surgical treatment is very effective, however it can be associated with an increased risk of postoperative hypotony. Despite apparently adequate IOP control there may be progressive cupping of the optic disc.

Ocular hypertension following vitreoretinal surgery is common, occurring in between 19% and 28% of cases. Some of these cases can go on to develop secondary glaucoma.<sup>1,2</sup> The cause of the glaucoma may either be underlying predisposition to develop glaucoma—for example, Stickler's, Wagner, retinitis pigmentosa—or it can be a complication secondary to the vitreoretinal procedure.<sup>3–5</sup> The current treatment modalities for the management of secondary glaucoma include both medical and surgical procedures with possible use of antimetabolites or filtration tubes. In intractable cases the use of cycloablation treatment has been described.<sup>6</sup>

Although previous studies have predominantly focused on the effect of individual risk factors including silicone oil on the rise of intraocular pressure (IOP),<sup>7–9</sup> little is known regarding the overall long term prognosis of secondary glaucoma following vitreoretinal surgery. The purpose of this study was to assess the efficacy of medical and surgical management and the long term outcome of secondary glaucoma following retinal reattachment surgery.

## PATIENTS AND METHODS

A longitudinal retrospective study was undertaken of the medical records of patients who were referred to the glaucoma service at Moorfields Eye Hospital between March 1998 and February 1999 following retinal reattachment surgery. Patient's demographic, preoperative, intraoperative, and postoperative data were recorded. The main outcome measures were IOP and vertical cup:disc ratio. Intraocular pressure was measured by applanation tonometry and vertical cup:disc ratio was evaluated during slit lamp biomicroscopy using 78 dioptres non-contact lens. These were documented from the time IOP was noted to be consistently high and in cases where postoperative ocular hypertension was associated with progressive cupping of the optic disc, the diagnoses of secondary glaucoma was made. Consistently elevated IOP was defined as any postoperative IOP of at least 25 mm Hg in three or more consecutive follow up visits requiring long term use of antiglaucoma agents. Although mild ocular hypertension is very common following vitreoretinal procedures, we considered patients with IOP persistently greater than 25 mm Hg to be at high risk of developing secondary glaucoma. After medical or surgical antihypertensive intervention, IOP equal or lower than the conventional level of 21 mm Hg was defined as successful in order to facilitate statistical analysis.

Management of secondary glaucoma involved administration of topical  $\beta$  blockers, oral and topical carbonic anhydrase inhibitors, prostaglandin analogues, and non-selective  $\alpha$  agonists. Trabeculectomy with antimetabolites or cyclodestructive procedures, with or without silicone oil removal when applicable, were employed when medical treatment failed to control IOP. In intractable cases of glaucoma, implantation of a drainage tube was carried out.

Relation between final IOP and change in cup:disc ratio with baseline characteristics and possible explanatory variables were evaluated with the independent *t* test for binary categorical variables, one way analysis (ANOVA) for other categorical variables, and linear regression for continuous variables. Comparison of the IOP, cup:disc ratio, and visual acuity between the first and the last follow up review was performed using paired *t* test. To evaluate the relation between progression of cup:disc ratio and final IOP with several explanatory variables simultaneously, a general linear model was applied.

## RESULTS

A total of 70 eyes of 70 patients (41 males and 29 females) were identified and included in the analysis. Clinical characteristics of all patients are summarised in table 1. Although it is difficult to accurately estimate the overall incidence of secondary glaucoma following retinal reattach-

**Abbreviation:** IOP, intraocular pressure

**Table 1** Data summary (70 eyes of 70 patients)

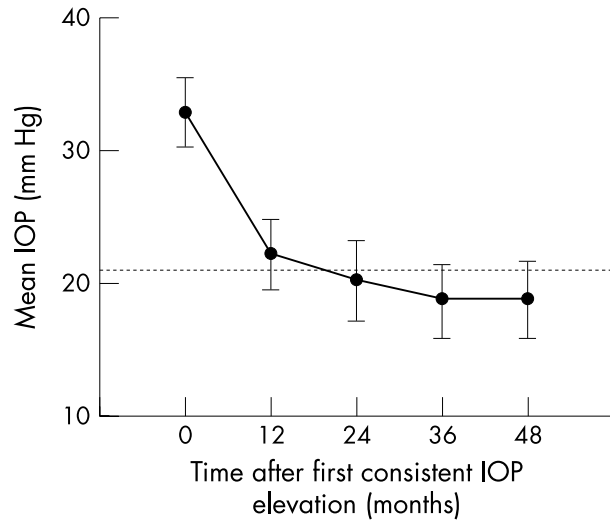
Age (years)	
Range	25 to 85
Mean (SD)	57 (15)
Relevant ophthalmic history	
Myopia*	13 (18%)
Diabetic retinopathy	9 (13%)
Severe ocular injury	7 (10%)
Congenital cataract	4 (6%)
Pre-existing glaucoma	2 (3%)
Uveitis	2 (3%)
Other	8 (11%)
No history	25 (36%)
Lens status	
Phakic	28 (40%)
Aphakic	8 (11%)
Pseudophakic	34 (49%)
Previous vitreoretinal procedure	
Scleral buckle	10 (14%)
Pars plana vitrectomy	63 (86%)
Number of vitreoretinal (VR) procedures	
Range	1 to 6
Mean (SD)	2 (1)
LogMAR visual acuity before first VR procedure	
Range	-0.1 to 2.7
Mean (SD)	1.4 (0.9)
LogMAR visual acuity at the final follow up	
Range	-0.1 to 3.0
Mean (SD)	1.2 (1.0)
Change in IOP (mm Hg)†	
Range	13 to -58
Mean (SD)	-16 (12)
Change in C:D ratio‡	
Range	0-0.5
Mean (SD)	0.1 (0.1)
Intravitreal silicone oil	
Yes	27 (39%)
No	43 (61%)
Removal of silicone oil	
Yes	15 (56%)
No	12 (34%)
Duration of follow up (months)	
Range	5 to 120
Mean (SD)	48 (25)
Number of antiglaucoma agents at final follow up	
Range	0 to 3
Mean (SD)	1.2 (0.9)

SD, standard deviation; IOP, intraocular pressure; C:D ratio, cup:disc ratio.  
 \*Myopia >3 dioptres.  
 †Change refers to: final IOP-IOP at the beginning of follow up period.  
 ‡Change refers to: final C:D ratio-C:D ratio the beginning of follow up period.

ment surgery, we found in our population sample that secondary glaucoma complicated 4.8% of the cases. However the above figure is likely to be overestimated because the number of vitreoretinal procedures was not available for the externally referred cases.

Mean increase of IOP 2-3 weeks following the first vitreoretinal procedure was 6 (SD 3) mm Hg. Sixty two (89%) eyes developed open angle secondary glaucoma whereas in eight (11%) eyes glaucoma was associated with extensive peripheral anterior synechiae or neovascularisation. The median interval between vitreoretinal procedure and persistent ocular hypertension requiring continuing treatment into the late postoperative period was 4.5 months (interquartile range 1 to 18.7 months).

After a mean follow up of approximately four years (fig 1) the mean IOP had significantly decreased from 33 (SD 10) to 16 (SD 8) mm Hg ( $p < 0.001$ ). The corresponding IOP of the fellow eye was virtually unchanged (16 (SD 4) mm Hg,  $p = 0.988$ ) over the same period. Fifty six (80%) of the subjects had final IOP within 6 and 21 mm Hg, six (9%) eyes were hypotonous (IOP < 6 mm Hg) and eight (11%) had IOP greater than 21 mm Hg.



**Figure 1** Mean intraocular pressure (IOP) against time after first consistent IOP elevation following retinal reattachment surgery. The horizontal broken line represents an IOP of 21 mm Hg. The error bars represent 95% confidence interval.

The visual outcome of eyes with final IOP less than 6 mm Hg or greater than 21 mm Hg was significantly worse compared with those eyes with a normal (6-21 mm Hg) range of pressure ( $p = 0.022$  and  $p = 0.009$  respectively), with 50% and 38% of them respectively having no perception of light at the end of the follow up period.

Despite the effective control of IOP in the majority of patients during the follow up period, there was mild progression of the mean vertical cup:disc ratio from 0.6 (SD 0.2) to 0.7 (SD 0.2) ( $p < 0.001$ ). Progression of cup:disc ratio was tested in a general linear regression model while controlling for past ophthalmic history, treatment modality, duration of follow up, number of previous vitreoretinal procedures, presence or removal of silicone oil, cup:disc ratio

**Table 2** Multiple linear regression predicting progression in cup:disc ratio during the follow up period

Variables	Coefficient (b)	Significance (p)
<i>Continuous</i>		
Number of previous vitreoretinal procedures	-0.046	0.033
Baseline cup:disc ratio	-0.366	0.001
Follow up period (months)	0.001	0.301
<i>Categorical</i>		
Treatment modality		
Medical	-0.02	0.617
Surgical		
Relevant past ophthalmic history		
Myopia	<0.001	0.992
Severe ocular injury	0.017	0.828
Congenital cataract	-0.017	0.869
Diabetic retinopathy	-0.189	0.053
No history	-0.114	0.125
Pre-existing glaucoma	-0.117	0.266
Other		
IOP in final follow up review (mm Hg)		
<6	-0.103	0.542
6-21	-0.012	0.901
>21		
Intravitreal silicone oil endotamponade		
Not used	-0.006	0.906
Used and removed	0.148	0.152
Used and not removed		

at baseline, and IOP at the final follow up review (table 2). Progression in the cup:disc ratio was significantly associated with greater number of vitreoretinal operations ( $p = 0.033$ ), smaller cup:disc ratio at baseline ( $p = 0.001$ ), and marginally associated with underlying diabetic retinopathy ( $p = 0.053$ ). Surprisingly, endotamponade with silicone oil, and its subsequent removal or not, did not affect significantly the change in cup:disc ratio suggesting that silicone oil may not be associated with more unfavourable prognosis of secondary glaucoma following retinal reattachment surgery.

In forty three (61%) cases IOP was lowered by means of topical or oral antiglaucoma agents maintaining a mean IOP of 18 (SD 7) mm Hg at the final follow up review. Surgical treatment was required in 27 (39%) cases with 19 (27%) patients undergoing cyclophotocoagulation, four (6%) trabeculectomy with antimetabolites, three (4%) glaucoma drainage tube implantation and one (1%) Nd: Yag peripheral iridotomies. Univariate analysis showed that final mean IOP was significantly lower in the surgical intervention group as opposed to medical treatment alone ( $p = 0.008$ ) and in patients using greater number of antiglaucoma agents ( $p = 0.003$ ). However both of the above variables lost significance ( $p > 0.05$ ) when we corrected the above model for hypotony.

## DISCUSSION

Transient or sustained elevation of IOP is a relatively common occurrence following retinal reattachment surgery.<sup>1,2</sup> Although previous studies have reported effective control of IOP in this type of glaucoma with medical and surgical treatment, little is known about the long term prognosis.<sup>7-9</sup> In our series including many cases of complex retinal detachment requiring multiple vitreoretinal procedures with or without use of silicone oil, reduction of IOP to  $\leq 21$  mm Hg was achieved in the vast majority of patients (89%). However, despite control of IOP, a small but significant ( $p < 0.001$ ) progression of the mean cup:disc ratio was a consistent finding over the follow up period. This may suggest that secondary glaucoma following retinal reattachment surgery may require further reduction of IOP in order to prohibit evolution of nerve fibre loss.

A greater number of previous vitreoretinal procedures was also found to be a risk factor for developing progressive disc changes. This is not surprising as multiple operations are associated with increased incidence of temporary or sustained postoperative ocular hypertension, which can exhaust optic disc reserves resulting in gradual enlargement of disc cup.

The question of whether or not diabetes mellitus is a significant risk factor for glaucoma remains controversial.<sup>10,11</sup> Our results show that diabetic retinopathy may be associated with progression of glaucomatous damage of the optic disc in patients who develop glaucoma following vitreoretinal procedures.

A smaller cup:disc ratio at baseline was also found to be a risk factor for progressive loss of nerve fibres in our population sample. This is probably an erroneous finding reflecting the subjective element of interpreting cup:disc ratio by means of slit lamp biomicroscopy. We speculate that it is attributable to the fact that enlargement of smaller cups are more readily detectable clinically, as opposed to discs with

advanced cupping in which evolution of the cup is possibly more obscured.

Previous studies have shown that despite the encouraging anatomical and visual results obtained from intravitreal silicone oil injection in the management of complicated retinal detachment, glaucoma is the second most common adverse occurrence ranging from 15% to 22% of the cases.<sup>8,9,12</sup> In our series, silicone oil did not appear to be an independent risk factor for intractable IOP or progressive enlargement of cup:disc ratio following vitreoretinal procedures as opposed to eyes that did not undergo intravitreal silicone oil injection.

In conclusion, secondary glaucoma may complicate retinal reattachment surgery and control of IOP is challenging. Medical treatment is successful in lowering IOP in most patients. In persisting cases surgical treatment is very effective, however it can be associated with an increased risk of postoperative hypotony. In addition, despite adequate IOP control there is progressive cupping of the optic disc. This may be due to the retinal pathology or too high target pressure. We accept the limitations of this study as with other retrospective surveys, as in a small number of cases data were not assessable. Further prospective studies with larger sample size would be required in order to define the risk factors for secondary glaucoma and its optimal management.

## Authors' affiliations

P Tranos, R Asaria, W Aylward, P Sullivan, W Franks, Moorfields Eye Hospital, London, UK

Correspondence to: Mr P Tranos, Moorfields Eye Hospital, City Road, London EC1V 2PD, UK; ptranos@doctors.org.uk

Accepted for publication 22 July 2003

## REFERENCES

- 1 **Weinberg RS**, Peyman GA, Huamonte FU. Elevation of intraocular pressure after pars plana vitrectomy. *Albrecht Von Graefes Arch Klin Exp Ophthalmol* 1976;**200**:157-61.
- 2 **Aaberg TM**, Van Horn DL. Late complications of pars plana vitreous surgery. *Ophthalmology* 1978;**85**:126-40.
- 3 **Graemiger RA**, Niemeyer G, Schneeberger SA, et al. Wagner vitreoretinal degeneration. Follow-up of the original pedigree. *Ophthalmology* 1995;**102**:1830-9.
- 4 **Ziakas NG**, Ramsay AS, Lynch SA, et al. Stickler's syndrome associated with congenital glaucoma. *Ophthalmic Genet* 1998;**19**:55-8.
- 5 **Badeeb O**, Trope G, Musarella M. Primary angle closure glaucoma and retinitis pigmentosa. *Acta Ophthalmol (Copenh)* 1993;**71**:727-32.
- 6 **Gedde SJ**. Management of glaucoma after retinal detachment surgery. *Curr Opin Ophthalmol* 2002;**13**:103-9.
- 7 **Jonas JB**, Knorr HL, Rank RM, et al. Intraocular pressure and silicone oil endotamponade. *J Glaucoma* 2001;**10**:102-8.
- 8 **Nguyen QH**, Lloyd MA, Heuer DK, et al. Incidence and management of glaucoma after intravitreal silicone oil injection for complicated retinal detachments. *Ophthalmology* 1992;**99**:1520-6.
- 9 **Henderer JD**, Budenz DL, Flynn HW Jr, et al. Elevated intraocular pressure and hypotony following silicone oil retinal tamponade for complex retinal detachment: incidence and risk factors. *Arch Ophthalmol* 1999;**117**:189-95.
- 10 **Mitchell P**, Smith W, Chey T, et al. Open-angle glaucoma and diabetes: the Blue Mountains Eye Study. *Ophthalmology* 1997;**104**:712-18.
- 11 **Tielsch JM**, Katz J, Quigley HA, et al. Diabetes, intraocular pressure, and primary open-angle glaucoma in the Baltimore Eye Survey. *Ophthalmology* 1995;**102**:48-53.
- 12 **Ni C**, Wang WJ, Albert DM, et al. Intravitreal silicone injection. Histopathologic findings in a human eye after 12 years. *Arch Ophthalmol* 1983;**101**:1399-401.



## Long term outcome of secondary glaucoma following vitreoretinal surgery

P Tranos, R Asaria, W Aylward, et al.

*Br J Ophthalmol* 2004 88: 341-343  
doi: 10.1136/bjo.2003.028076

---

Updated information and services can be found at:  
<http://bjo.bmj.com/content/88/3/341.full.html>

---

*These include:*

### References

This article cites 11 articles, 2 of which can be accessed free at:  
<http://bjo.bmj.com/content/88/3/341.full.html#ref-list-1>

### Email alerting service

Receive free email alerts when new articles cite this article. Sign up in the box at the top right corner of the online article.

---

### Topic Collections

Articles on similar topics can be found in the following collections

[Angle](#) (791 articles)  
[Glaucoma](#) (779 articles)  
[Intraocular pressure](#) (789 articles)

---

### Notes

---

To request permissions go to:  
<http://group.bmj.com/group/rights-licensing/permissions>

To order reprints go to:  
<http://journals.bmj.com/cgi/reprintform>

To subscribe to BMJ go to:  
<http://group.bmj.com/subscribe/>