

## SCIENTIFIC REPORT

# Bloom syndrome: multiple retinopathies in a chromosome breakage disorder

R B Bhisitkul, M Rizen

*Br J Ophthalmol* 2004;**88**:354–357. doi: 10.1136/bjo.2002.011643

**Aim:** To describe multiple retinal abnormalities in a patient with Bloom syndrome, including early macular drusen, diabetic retinopathy, and the onset of leukaemic retinopathy.

**Methods:** Clinical data were collected over 1 year of follow up, and ocular abnormalities in Bloom syndrome were reviewed from the literature.

**Results:** A 39 year old man with a rare autosomal recessive "chromosome breakage" syndrome was followed. A variety of ocular findings have been reported in Bloom syndrome; this patient had hard drusen in both maculae, non-proliferative diabetic retinopathy, and haemorrhagic retinopathy as a herald of acute lymphocytic leukaemia.

**Conclusions:** Bloom syndrome is a rare disorder of genomic instability, in which a variety of ocular abnormalities have been found. Described here are multiple retinal manifestations arising from characteristic systemic associations of diabetes mellitus and leukaemia, as well as macular hard drusen.

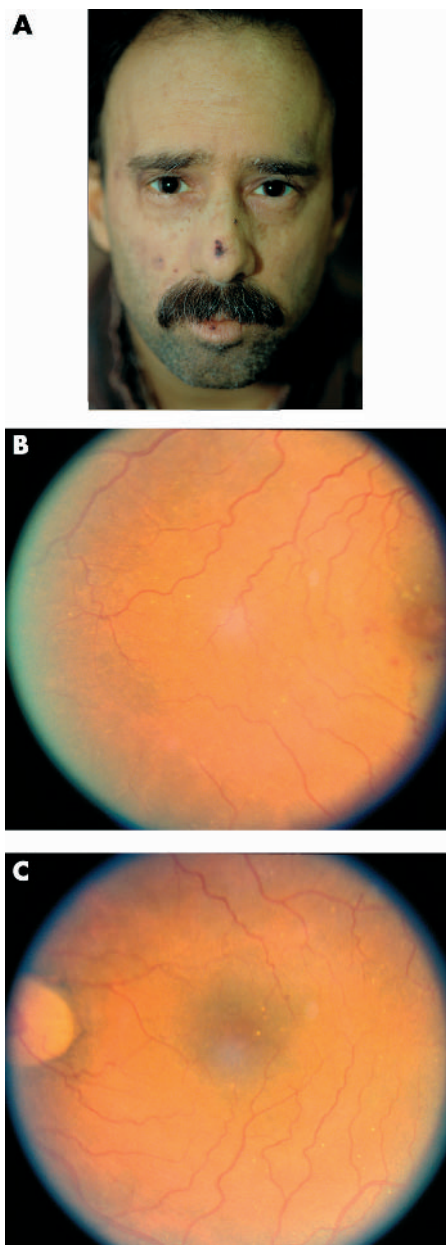
retinopathies secondary to systemic disease, which have not been previously reported.

**B**loom syndrome is a rare, autosomal recessive disease characterised by short stature, immunodeficiency, and a predilection for malignancies and diabetes. Since being first described in 1954,<sup>1</sup> only about 170 cases have been registered worldwide, mostly in patients of Ashkenazi Jewish heritage, but also occurring in other ethnic groups.<sup>2–5</sup> The mutation responsible for Bloom syndrome has been mapped to 15q26.1<sup>6</sup>; the *BLM* gene encodes a RecQ DNA helicase important for DNA repair, defects of which give rise to this "chromosome breakage syndrome."<sup>7</sup> Owing to excessive chromosomal rearrangements in all cell types, somatic mutations occur at a high frequency throughout the patient's life, giving rise to a wide variety of neoplasias and other abnormalities.

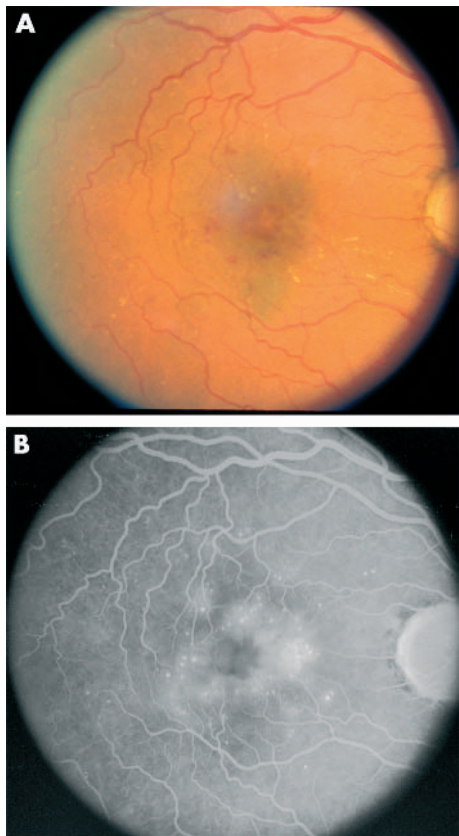
Patients with Bloom syndrome display proportional growth deficiency, with adult height rarely exceeding 5 feet (152 cm). They have a characteristic narrow facies with prominent nose and ears, and often have a telangiectatic facial erythema exacerbated by sunlight. There is a typical high pitched voice, with hypogonadism and infertility being common, especially in male patients. Beginning in childhood the patients are susceptible to multiple lung and ear infections. Diabetes mellitus develops in about 10% of cases.

The excessive rate of acquired mutations confers a high risk of developing neoplasms at a young age, usually in the third decade. These most typically are acute leukaemia and lymphomas as well as a wide variety of carcinomas. Therefore, early mortality is common, with about one third of patients with Bloom syndrome dying in their mid-20s.

Although the ocular manifestations of Bloom syndrome are myriad, they have remained incompletely described. We present a case where multiple independent retinal abnormalities developed in a single patient, including blinding



**Figure 1** (A) Patient photograph showing narrow facies and nasal prominence which are typical of patients with Bloom syndrome. (B, C) Fundus photographs showing punctate macular lesions resembling hard drusen in both eyes.

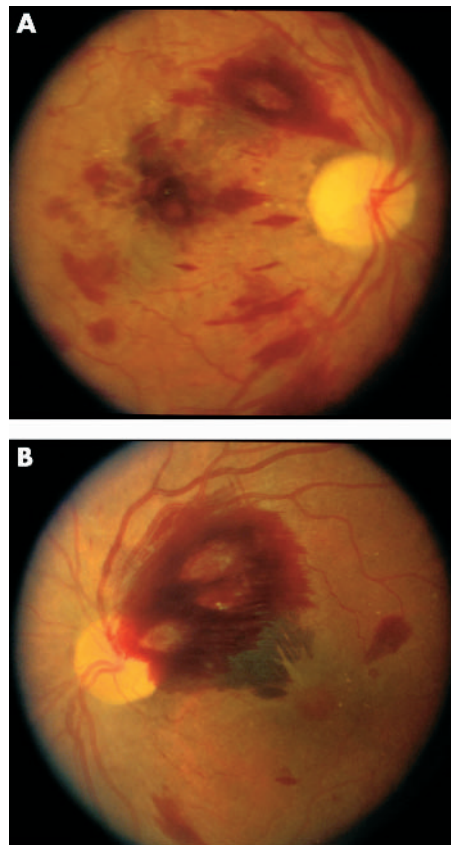


bj11643.f2

**Figure 2** Right eye. (A) Colour photograph demonstrates non-proliferative diabetic retinopathy with retinal hard exudates and central macular thickening. (B) Fluorescein angiogram confirms leaking microaneurysms and clinically significant macular oedema with retinal cysts.

**CASE HISTORY**

A 39 year old man was referred with a 1 year history of gradually progressive blurred vision. He was of Ashkenazi Jewish heritage and had been diagnosed at 1 year of age with Bloom syndrome, confirmed by elevated sister chromatid exchange frequency on chromosomal analysis. He had been diagnosed 1 year earlier with non-insulin dependent diabetes mellitus which was noted to be poorly controlled. His past medical history was otherwise significant for hypercholesterolaemia, chronic rhinitis, and for excision of a squamous cell carcinoma from his right ear several years earlier. On physical examination, he was of short stature (4 feet, 8 inches, 142 cm) and displayed the narrow facies typical of Bloom syndrome (fig 1A). An erythematous facial rash in a malar pattern was present, which the patient reported as chronic. Best corrected visual acuity was 20/60 right eye and 20/25 left eye. Intraocular pressures were normal in both eyes and slit lamp examination revealed narrow angles in both anterior chambers, measured gonioscopically in both eyes as grade I to II in the Shaffer system. Dilated fundus examination revealed scattered punctate yellow lesions in both maculae that resembled hard drusen (fig 1B, C). Intraretinal haemorrhages and microaneurysms present in the posterior pole of both eyes indicated non-proliferative diabetic retinopathy, with retinal thickening and hard exudates in the right macula (fig 2A). Fluorescein angiography confirmed clinically significant macular oedema with a cystoid component right eye (fig 2B). Focal macular laser photocoagulation was performed right eye, but he was seen to have only partial



**Figure 3** Fundus photographs display leukaemic retinopathy with nerve fibre layer haemorrhages as well as deep retinal and subretinal haemorrhages in both eyes (A, B).

resolution of the oedema with visual acuity of 20/80 right eye and 20/25 left eye at 5 months post-laser.

Six months after initial presentation the patient returned on an urgent basis with a 2 day history of subacute bilateral vision loss, associated with malaise, fever, and chills. He also noted a “rash” on his arms and legs over the past week.

On examination he had several focal skin lesions on the cheeks and nose (fig 1A) and purple maculopapular lesions distributed over his arms, legs, and abdomen. He had a fever at 38.4°C, and was tachycardic. Visual acuity had declined to counting fingers right eye and 20/80 left eye. Dilated fundus examination now revealed dense intraretinal and even subretinal haemorrhages in the posterior pole of both eyes (fig 3), some of which were white centred haemorrhages.

He was admitted to the hospital and white blood cell count was found to be 29 600 with greater than 95% blasts and zero neutrophils. Acute lymphoblastic leukaemia was diagnosed by bone marrow biopsy. He underwent 3 weeks of induction chemotherapy with daunorubicin, vincristine, and prednisone and achieved remission, with resolution of his haemorrhagic retinopathy and visual improvement to 20/400 right eye and 20/40 left eye. However, 2 months after discharge he had disease recurrence necessitating re-induction chemotherapy followed by allogeneic stem cell transplantation. During this prolonged admission he died from complications of fungal pneumonia.

**DISCUSSION**

Bloom syndrome is an archetypal “chromosome breakage syndrome.” A recessively inherited mutation in the *BLM* gene leads to an inordinate frequency of chromosomal breaks and rearrangements, possibly via aberrant repair of breaks in

**Table 1** Ophthalmological abnormalities reported in Bloom syndrome

Location	Finding	Reference
Eyelid	Café au lait lesion	14
	Sun sensitive telangiectatic erythema	14
	Madarosis	14
Conjunctiva	Bulbar conjunctival telangiectasia	15, 16
	Conjunctivitis	18
Anterior chamber	Narrow angles	this report
Iris	Sectoral iris pigment alteration	14
Retina	Drusen	11
	Unilateral retinoblastoma	17
	Non-proliferative diabetic retinopathy	this report
Optic nerve	Leukaemic retinopathy	this report
	Bilateral optic nerve hypoplasia	15

double stranded DNA.<sup>7-10</sup> The *BLM* mutation in turn gives rise throughout life to a high number of acquired somatic mutations. Genomic instability can affect virtually all genetic loci, cell types, and tissues in an individual with Bloom syndrome, so it is not surprising that manifold ocular abnormalities have been observed. As described here, a single patient in a short span of time displayed multiple independent retinal pathologies. In addition to early onset retinal drusen, which may be considered characteristic for the syndrome, he developed two different complications secondary to systemic diseases: diabetic retinopathy and leukaemic retinopathy.

Perhaps the most common ocular finding in Bloom syndrome is the presence of retinal drusen at an early age (fig 1); noted in this patient at age 39, drusen may be present even in childhood. In this and in other reported cases the drusen are hard, small, and non-confluent. Landau and colleagues<sup>11</sup> first described bilateral drusen in three children and termed them "colloid body-like spots." They equated these childhood drusen with those more commonly seen as a "senile phenomenon," and indeed there is a clinical resemblance to age related macular degeneration. Of note, no form of exudative macular degeneration has been reported in these patients.

Non-proliferative diabetic retinopathy in this patient had typical features (fig 2), with severe macular oedema recalcitrant to standard laser therapy. Diabetes is a classic feature of Bloom syndrome, usually occurring in its non-insulin dependent form. It is therefore surprising that diabetic retinopathy has not, to our knowledge, previously been described in Bloom syndrome. This absence may result from patient age and diabetes duration being curtailed by early mortality in patients with Bloom syndrome. The patient reported here had reached 40 years of age, one of the longest surviving patients with Bloom syndrome; perhaps his later age and duration of diabetes allowed for retinal expression of his diabetes.

Acute leukaemias are the most frequent malignancies arising in patients with Bloom syndrome, but again leukaemic retinopathy has not to our knowledge been reported previously. In this case, rapid visual loss and haemorrhagic retinopathy were the presenting signs for the diagnosis of acute leukaemia. The retinal findings were those of typical leukaemic retinopathy<sup>12-13</sup> with bilateral haemorrhages in the superficial and deep retina throughout the posterior pole, some white centred haemorrhages, and also subretinal haemorrhage at the central macula in one eye (fig 3). Partial reversal of the retinopathy was seen following chemotherapy and remission of his leukaemia.

A wide variety of other ocular abnormalities have been found in Bloom syndrome (see table 1). A sunlight induced telangiectatic facial rash resembling that of lupus erythema-

tosis is one of the diagnostic features of the disease; telangiectatic lesions can involve the lower eyelids<sup>14</sup> and have even been reported on the conjunctiva.<sup>15 16</sup> In the patient described here, the anterior chamber angles were seen to be narrow bilaterally; he had no evidence of narrow angle glaucoma, and glaucoma has not been reported as a feature of Bloom syndrome.

Abnormalities of the posterior segment have been described sparsely in Bloom syndrome. Although a wide array of systemic diseases and malignancies appear in Bloom syndrome, retinal pathologies secondary to disorders such as diabetes, leukaemia, lymphoma, or tumour metastases have not been reported. Retinoblastoma has been reported in a child<sup>17</sup>; an infant with bilateral optic nerve hypoplasia has also been reported.<sup>15</sup>

In conclusion, the collected observations in Bloom syndrome indicate that a wide variety of ocular abnormalities can arise as a consequence of excessive somatic mutations. While reports of retinal abnormalities have been scant in this disorder, the ophthalmological spectrum of Bloom syndrome can be expanded from the multiple, independent findings in this patient.

#### Authors' affiliations

**R B Bhisitkul, M Rizen**, Department of Ophthalmology, Beckman Vision Center, University of California San Francisco Medical School, San Francisco, CA, USA

Supported by That Man May See Foundation.

The authors have no proprietary or commercial interests related to the manuscript.

Correspondence to: Robert B Bhisitkul, MD, PhD, Department of Ophthalmology, University of California San Francisco, 10 Kirkham Street, K301, San Francisco, CA 94143, USA; [bhisit@itsa.ucsf.edu](mailto:bhisit@itsa.ucsf.edu)

Accepted for publication 19 April 2003

#### REFERENCES

- 1 **Bloom D.** Congenital telangiectatic erythema resembling lupus erythematosus in dwarfs. *Am J Dis Child* 1954;**88**:754-8.
- 2 **German J.** Bloom's syndrome: the first 100 cancers. *Cancer Gen Cytogen* 1997;**93**:100-6.
- 3 **Li L, Eng C, Desnick RJ, et al.** Carrier frequency of the Bloom syndrome *blm*<sup>Ash</sup> mutation in the Ashkenazi Jewish population. *Molec Genet Metab* 1998;**64**:286-90.
- 4 **Roa BB, Savino CV, Richards CS.** Ashkenazi Jewish population frequency of the Bloom syndrome gene 2281 delta 6ins7 mutation. *Genet Testing* 1999;**3**:219-21.
- 5 **Peleg L, Pessio R, Goldman B, et al.** Bloom syndrome and Fanconi's anemia: rate and ethnic origin of mutation carriers in Israel. *Isr Med Assoc* 2002;**4**:95-7.
- 6 **German J, Roe AM, Leppert M, et al.** Bloom syndrome: an analysis of consanguineous families assigns the locus mutated to chromosome band 15q26.1. *Proc Nat Acad Sci* 1994;**91**:6669-73.
- 7 **Ellis NA, Groden J, Ye TZ, et al.** The Bloom syndrome gene product is homologous to RecQ helicases. *Cell* 1995;**83**:655-66.

- 8 **Furuichi Y.** Premature aging and predisposition to cancers caused by mutations in RecQ family helicases. *Ann NY Acad Sci* 2001;**928**:121–31.
- 9 **Kusano K**, Johnson-Schlitz DM, Engels WR. Sterility of *Drosophila* with mutations in the Bloom Syndrome gene—complementation by *Ku70*. *Science* 2001;**291**:2600–2.
- 10 **Gaymes TJ**, North PS, Brady N, *et al.* Increased error-prone non homologous DNA end-joining: a proposed mechanism of chromosomal instability in Bloom's syndrome. *Oncogene* 2002;**21**:2525–32.
- 11 **Landau J**, Katzenellenbogen I, Laron Z. Eye findings in congenital telangiectatic erythema and growth retardation (Bloom's syndrome). *Am J Ophthalmol* 1966;**62**:753–4.
- 12 **Allen AR**, Straatsma BR. Ocular involvement in leukemia and allied disorders. *Arch Ophthalmol* 1961;**66**:68–86.
- 13 **Reddy SC**, Quah SH, Low HC, *et al.* Prognostic significance of retinopathy at presentation in adult acute leukemia. *Ann Hematol* 1998;**76**:15–18.
- 14 **German J.** Bloom's syndrome. *Dermatol Clin* 1995;**13**:7–18.
- 15 **Sahn EE**, Hussey RH, Christmann LM. A case of Bloom syndrome with conjunctival telangiectasia. *Pediat Dermatol* 1997;**14**:120–4.
- 16 **German J.** Bloom's syndrome: Genetic and clinical observations in the first twenty-seven patients. *Am J Hum Genet* 1969;**21**:196–227.
- 17 **Gibbons B**, Scott D, Hungerford JL, *et al.* Retinoblastoma in association with chromosome breakage syndromes Fanconi's anaemia and Bloom's syndrome: clinical and cytogenetic findings. *Clin Genet* 1995;**47**:311–17.
- 18 **Szalay GC.** Dwarfism with skin manifestations. *J Pediatr* 1963;**62**:686–95.



## Bloom syndrome: multiple retinopathies in a chromosome breakage disorder

R B Bhisitkul and M Rizen

*Br J Ophthalmol* 2004 88: 354-357  
doi: 10.1136/bjo.2002.011643

---

Updated information and services can be found at:  
<http://bjo.bmj.com/content/88/3/354.full.html>

---

	<i>These include:</i>
<b>Data Supplement</b>	"Patient Consent" <a href="http://bjo.bmj.com/content/suppl/2004/02/25/88.3.354.DC1.html">http://bjo.bmj.com/content/suppl/2004/02/25/88.3.354.DC1.html</a>
<b>References</b>	This article cites 17 articles, 2 of which can be accessed free at: <a href="http://bjo.bmj.com/content/88/3/354.full.html#ref-list-1">http://bjo.bmj.com/content/88/3/354.full.html#ref-list-1</a>
<b>Email alerting service</b>	Receive free email alerts when new articles cite this article. Sign up in the box at the top right corner of the online article.

---

<b>Topic Collections</b>	Articles on similar topics can be found in the following collections <a href="#">Retina</a> (1217 articles) <a href="#">Eye (globe)</a> (543 articles)
--------------------------	--

---

### Notes

---

To request permissions go to:  
<http://group.bmj.com/group/rights-licensing/permissions>

To order reprints go to:  
<http://journals.bmj.com/cgi/reprintform>

To subscribe to BMJ go to:  
<http://group.bmj.com/subscribe/>