

CONTROVERSY

Debate

Diabetic retinopathy: should this patient receive laser treatment?

E Y Chew, J Dowler, H Flynn

Series editors: Susan Lightman and Peter McCluskey

This 53 year old man has had diabetes for approximately 18 years. He has recently experienced a mild decrease in his right visual acuity 20/30 (6/9). His medications include insulin and oral hypoglycaemic agents and his most recent haemoglobin A_{1C} is 9.4%. At this visit, his blood pressure is 125/90. His fasting serum cholesterol level is 247 mg/dl (6.39 mmol/l) while his low density lipoprotein (LDL) cholesterol is 143 mg/dl (3.67 mmol/l). He has moderate cortical lens opacities in both eyes. The fundus examination revealed more severe changes in his right eye with the presence of marked haemorrhages in the four mid-peripheral quadrants (fig 1) with evidence of intraretinal microvascular abnormalities (IRMA) and venous abnormalities in the infranasal quadrant (fig 2). In the right macula, retinal hard exudate can be detected superotemporal to the centre of the fovea (fig 3). In his left eye, he has similar but fewer changes of retinal haemorrhages in all four mid-peripheral quadrants and no evidence of

IRMA, venous abnormalities, or retinal hard exudate. His left vision is 20/20 (6/6).

What steps should be taken to evaluate and treat this patient?

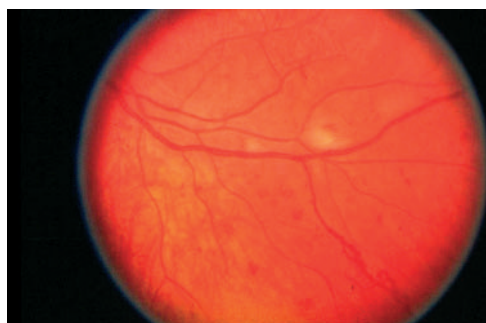


Figure 2 There is evidence of intraretinal microvascular abnormalities (IRMA) and venous abnormalities in the infranasal quadrant.

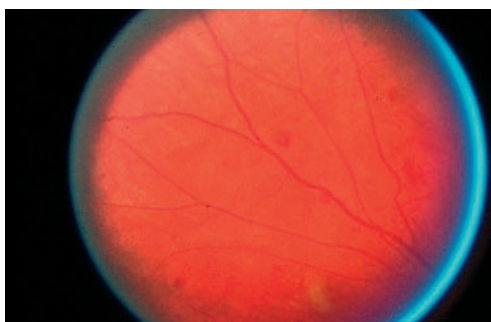


Figure 1 The superotemporal quadrant of the retina showed moderate retinal haemorrhages.

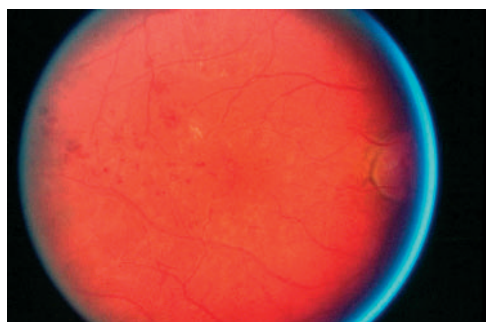


Figure 3 In the right macula, retinal hard exudate can be detected superotemporal to the centre of the fovea.

Correspondence to:
E Y Chew, Building 31,
Room 6A52, 31 Center
Drive, MSC 2510,
Bethesda, MD 20892-
2510, USA; echew@nei.nih.gov

Accepted for publication
12 May 2003

View 1: Should this patient receive laser treatment?

J Dowler

In patients with diabetic retinopathy, laser treatment is directed at the prevention of visual loss rather than at visual improvement. Treatment should therefore be applied before

visual loss occurs, when the risk of visual loss justifies adverse effects of treatment. The risk of visual loss is linked to the likelihood of progression of retinopathy to sight threatening forms,

J Dowler, Moorfields Eye Hospital, City Road, London EC1V 2RD, UK; jonathan.dowler@moorfields.nhs.uk

Debate

Box 1 Factors influencing progression of diabetic retinopathy

- Epidemiological factors (immutable)**
Diabetes type, diabetes duration, ethnicity, sex
- Systemic factors (modifiable)**
Glycaemic control, hypertension, serum lipids, renal dysfunction
- Specific risk factors (timeable)**
Pregnancy, cataract surgery, tightened glycaemic control
- Ophthalmoscopic signs**

which in turn depends on epidemiological factors such as sex, ethnicity, diabetes type, and duration; systemic factors such as hypertension, glycaemic control, and serum lipids; specific risk factors such as pregnancy, cataract surgery, and tightened glycaemic control; and, lastly, ophthalmoscopic signs (box 1).

This patient has type 2 diabetes, and data from the Wisconsin Epidemiological Study of Diabetic Retinopathy (WESDR)^{1,2} (table 1) suggest that retinopathy is likely to progress slower than in type 1 disease, especially if insulin therapy is not required. Glycaemic control, on the other hand, is very poor and this is likely to accelerate retinopathy progression. In the UK Prospective Diabetes Study (UKPDS), patients with type 2 diabetes randomised to intensive glycaemic control had retinopathy progression rates 21% lower than the conventional treatment cohort.³ Mean glycosylated haemoglobin (HbA_{1c}) values were respectively 7.0% and 7.9%, much lower than in this case. UKPDS data indicate that the effect of poor glycaemic control is synergistic with that of poor hypertensive control, but fortunately in this patient hypertensive control is good, and there is no biochemical evidence of renal dysfunction, which might compromise hypertensive control in future. In the UKPDS, patients randomised to intensive control of blood pressure ($\leq 150/85$) had a one third reduction in the rate of retinopathy progression compared to conventionally treated patients.⁴ This patient also has significantly elevated plasma cholesterol levels. Whereas there is no randomised controlled trial demonstrating a beneficial effect on retinopathy with reduction in plasma cholesterol, the ETDRS associated exudate deposition with higher plasma cholesterol values.⁵

In this patient, significant haemorrhage and venous beading are present in four quadrants, and intraretinal microvascular abnormalities

Table 1 Prevalence of diabetic retinopathy in the Wisconsin Epidemiological study of diabetic retinopathy^{1,2}

	Any retinopathy		Proliferative	
	<2 years	>15 years	<4 years	>15 years
IDDM	2%	95%	0%	26%
ITD	23%	85%	4%	20%
NIDDM	10%	58%	3%	4%

Box 2 "4-2-1" rule for clinical grading of severity of non-proliferative retinopathy

Mild

- At least one microaneurysm, criteria not met for moderate

Moderate

- Intraretinal haemorrhages/microaneurysms < standard photograph 2a, and/or cotton wool spots, venous beading, intraretinal microvascular abnormalities, criteria not met for severe

Severe

- At least one of :
 - intraretinal haemorrhages in four quadrants, one of which \geq standard photograph 2a
 - venous beading in two quadrants
 - intraretinal microvascular abnormalities \geq standard photograph 6a in ≥ 1 quadrant
- Criteria not met for very severe

Very severe

- At least two of criteria for severe
- Standard photographs available at: eyephoto.opth.wisc.edu/ResearchAreas/Diabetes/DiabStds.htm*

(IRMA) in at least one. New vessels, fibrous proliferation, retrohyaloid, and intragel haemorrhage are not apparent. Based on the 4-2-1 rule⁶ (box 2), this would be classified as very severe non-proliferative diabetic retinopathy. In the Early Treatment Diabetic Retinopathy Study final retinopathy severity scale, eyes with this level of disease had a 17% probability of developing high risk proliferative retinopathy within a year (table 2).⁷ Exudate approximately one disc diameter temporal to the centre of the macula suggests the possibility of clinically significant macular oedema, albeit eccentric, with little immediate threat to vision.

Table 2 Annual rates of progression to high risk proliferative retinopathy by severity of non-proliferative retinopathy: review schedule giving 4% risk between appointments

Severity NPDR	% PDR/year	Review
Mild	1	48 months*
Moderate	4	12 months
Severe	8	6 months
Very severe	17	3 months

*In our institution, patients with mild NPDR and type 2 diabetes are discharged to annual community review. Patients with type 1 diabetes, who are monocular, or who have other specific risk factors are reviewed annually in the clinic.

This patient has fundus signs consistent with a 17% risk of developing high risk proliferative diabetic retinopathy in a year, possible macular oedema, poor glycaemic control, and elevated serum cholesterol. Improved glycaemic control may be beneficial, though close ophthalmological surveillance during the transition period is desirable. A reduction in serum cholesterol may reduce risks associated with macrovascular disease, even if there is no unequivocal benefit to retinopathy. Careful stereoscopic evaluation of the macula, coupled with fluorescein angiography if indicated, may reveal clinically significant macular oedema, which if present should be treated with macular laser therapy according to ETDRS guidelines. Panretinal laser therapy in the absence of other specific risk factors for retinopathy progression, and in the absence of high risk proliferative disease, confers little potential benefit to offset against side effects such as macular oedema. Provided the patient is a consistent attender, review within 3 months to examine for signs of proliferative disease is appropriate (table 2).

REFERENCES

- 1 Klein R, Klein BEK, Moss SE, *et al.* The Wisconsin Epidemiological Study of Diabetic Retinopathy. II. Prevalence and risk of retinopathy when age at diagnosis is less than 30 years. *Arch Ophthalmol* 1984;**102**:520–6.
- 2 Klein R, Klein BEK, Moss SE, *et al.* The Wisconsin Epidemiological Study of Diabetic Retinopathy. III. Prevalence and risk of retinopathy when age at diagnosis is 30 or more years. *Arch Ophthalmol* 1984;**102**:527–32.
- 3 UK Prospective Diabetes Study Group. Intensive blood glucose control with sulphonylureas or insulin compared with conventional treatment and risk of complications in patients with type 2 diabetes: UKPDS 33. *Lancet* 1998;**352**:837–53.
- 4 UK Prospective Diabetes Study Group. Tight blood pressure control and the risk of macrovascular and microvascular complications in type 2 diabetes: UKPDS 38. *BMJ* 1998;**318**:703–13.
- 5 Chew EY, Klein ML, Ferris FL 3rd, *et al.* Association of elevated serum lipid levels with retinal hard exudates in diabetic retinopathy. Early Treatment Diabetic Retinopathy Study Report 22. *Arch Ophthalmol* 1996;**114**:1079–84.
- 6 American Academy of Ophthalmology. *Preferred practice patterns*. San Francisco: AAO, 1999.
- 7 Early Treatment Diabetic Retinopathy Study Research Group. Fundus photographic risk factors for progression of diabetic retinopathy. *Ophthalmology* 1991;**98**:823–33.

Debate

View 2: Should this patient receive laser treatment?

H W Flynn Jr

I would agree with Mr Dowler's assessment of this patient with type 2 diabetes and very severe non-proliferative diabetic retinopathy in his right eye. Although the macular oedema is difficult to detect in non-stereoscopic fundus photographs of the macula, the presence of retinal hard exudates strongly suggests the presence of macular oedema. It is possible that this patient may have clinically significant macular oedema, although the retinal hard exudate is located a distance from the centre of fovea. His decreased visual acuity would also suggest the involvement of the fovea, either with macular oedema or possibly foveal ischaemia. It would be prudent to conduct a detailed funduscopy with biomicroscopy to view the macula stereoscopically and to perform a fluorescein angiogram. Optical coherence tomography (OCT) of the macula may be helpful. His systemic risk factors include the poor glycaemic control and dyslipidaemia. The management of this patient with diabetic retinopathy consists of both medical treatment of the systemic conditions and local laser therapy for the ocular disease.

Because of the probability of macular oedema, fluorescein angiography is usually performed. Treatment with laser photocoagulation, using the focal and grid techniques advocated in the Early Treatment Diabetic Retinopathy Study (ETDRS), is recommended if clinically significant macular oedema is present. Treatment

should be accomplished in a timely manner as this eye has very severe non-proliferative diabetic retinopathy. The risks, as Dowler has nicely pointed out, of developing proliferative and possibly high risk proliferative retinopathy, are high in such eyes. Scatter (panretinal) photocoagulation given to eyes without prior focal treatment for macular oedema may cause increased macular oedema and visual acuity decrease that may be difficult to recover. If focal areas of fluorescein leakage can be identified, it would be ideal to treat with focal laser photocoagulation first. When the retinal thickening has responded to the focal treatment with nearly complete resolution, scatter photocoagulation should be considered because he has type 2 diabetes. In addition, his left eye has signs of severe non-proliferative retinopathy, which is a stage that may have increased risk of developing proliferative diabetic retinopathy within the year. I would favour treating his right eye which has the more severe level of diabetic retinopathy at least with early scatter photocoagulation. Assuming a favourable response to treatment of the right eye, I would also consider scatter treatment in his fellow eye. I usually do not wait for high risk proliferative retinopathy to develop. Often, a vitreous haemorrhage may be the presenting sign of such disease, making it much more difficult to apply in the scatter laser. Patients with type 2 diabetes in the ETDRS

H W Flynn Jr,
Bascom Palmer
Eye Institute, 900 NW
17th Street, Miami,
FL 33136, USA; hflynn@
med.miami.edu

Debate

clearly had a 50% reduction in severe vision loss when early scatter photocoagulation was given at

the severe non-proliferative diabetic retinopathy stage.

Overview

E Chew

This patient has both medical and ocular conditions that need to be addressed. It is important to emphasise the need to improve his glycaemic control. This information should be communicated to his primary care physician to initiate tighter control of his glycaemia. In the UK Prospective Diabetes Study (UKPDS), the largest and longest randomised study of intensive v conventional glucose control in patients with type 2 diabetes, there was a 25% reduction in the risk of the "any diabetes related microvascular end point," including the need for retinal photocoagulation in the intensive treatment group compared with the conventional treatment group.¹ After 6 years of follow up, a smaller proportion of patients in the intensive treatment group than in the conventional group had a two step progression (worsening) in diabetic retinopathy ($p < 0.01$). Epidemiological analysis of the UKPDS data showed a continuous relation between the risk of microvascular complications and glycaemia, such that for every percentage point decrease in HbA_{1c} (for example, 9% to 8%), there was a 35% reduction in the risk of microvascular complications.

Although the data from the Diabetes Control and Complications Trial (DCCT) are from patients with type 1 diabetes, the results showed the importance as well as the persistent effects of glucose control in preventing the progression of the severity of diabetic retinopathy and the development of macular oedema.² Following the completion of the controlled clinical trial of glycaemic control, the DCCT study was then extended as a follow up study, the Epidemiologic Study of Diabetes Intervention and Complications (EDIC).^{3,4} Patients enrolled into both arms of the study were informed of the beneficial results of tight glycaemic control and the patients in the conventional treatment group were offered intensive therapy. The care of all the patients was then transferred to their own physicians. At 4 years and again at 6 years of follow up, the difference of the HbA_{1c} values narrowed. The proportion of patients who had worsening of retinopathy, including proliferative diabetic retinopathy, macular oedema, and the need for laser therapy, was still statistically significantly reduced in the intensive treatment group compared with the conventional treatment group. It appears that a period of good glycaemic control results in the decrease in the progression of both diabetic retinopathy and nephropathy, despite increasing hyperglycaemia.

The blood pressure in this patient, fortunately, is good. It is important to note that a controlled clinical trial of blood pressure lowering in the

UKPDS patients with hypertension also showed a clinically important effect on the progression of retinopathy and the development of moderate vision loss.⁵

Although clinical trials are crucial in assessing the effects of treatments, secondary analyses of risk factors such as elevated serum cholesterol levels provide important information. In the ETDRS, the observational data showed that the risk of developing retinal hard exudate and the severity of retinal hard exudate were associated with elevated serum cholesterol levels.⁶ The risk of moderate vision loss at 5 years (decrease of three or more lines of vision compared to the baseline vision on the logarithmic visual acuity chart) was also doubled with elevated serum cholesterol levels. Although these are observational data, the results are compelling for recommending the reduction of elevated serum cholesterol levels in such patients. Furthermore, a similar association of increasing retinal hard exudate with elevated serum cholesterol levels was found in the Wisconsin Epidemiologic Study of Diabetic Retinopathy (WESDR), a population based study.⁷ This patient should be treated medically to reduce these elevated levels of cholesterol. Patients with diabetes have a threefold to fourfold increased risk of cardiovascular disease and one of the major associated risk factor is elevated level of serum cholesterol. This indication alone may be sufficient to recommend the treatment of elevated serum cholesterol levels but the risk of potential losing vision may motivate such patients to be compliant with their medical treatment.

In addition to the intensive medical treatment, it would be reasonable to recommend that this patient be considered for focal laser photocoagulation for diabetic macular oedema, which may be present, to be followed by scatter (panretinal) photocoagulation. This patient with type 2 diabetes has the ocular features of very severe non-proliferative diabetic retinopathy, as defined by the so called "4-2-1 rule" which is dependent on the following ocular features found in the four peripheral quadrants, as indicated by Dowler. In 1 year, 50% of these patients will develop any proliferative disease and 17% will develop high risk proliferative retinopathy.⁸ The main ETDRS data showed that early laser photocoagulation results in a statistically significant benefit of early photocoagulation in preventing severe vision loss. Other secondary analyses in the ETDRS also suggest that there is an interaction of diabetes type with scatter photocoagulation. It appears that the risk of severe vision loss can be reduced by 50% if early scatter photocoagulation is administered in

: **E Y Chew**, *Lead clinician*,
: Building 31,
: Room 6A52, 31 Center
: Drive, MSC 2510,
: Bethesda, MD 20892-
: 2510, USA; [echew@](mailto:echew@nei.nih.gov)
: nei.nih.gov

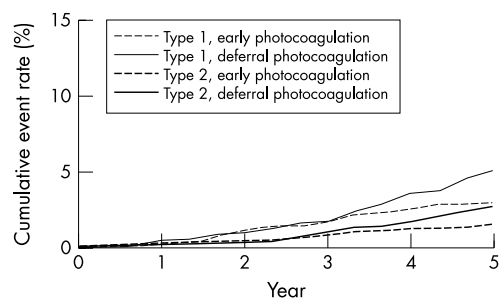


Figure 1 The rates of severe vision loss or vitrectomy in types 1 and 2 diabetes were not statistically different in patients with mild to moderate non-proliferative diabetic retinopathy (NPDR).

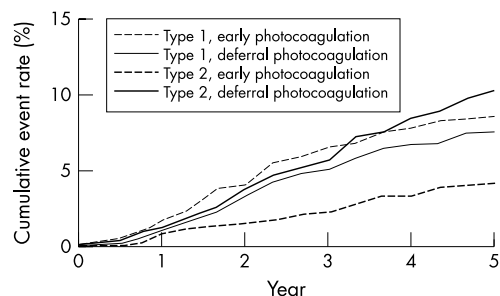


Figure 2 The rates of severe vision loss or vitrectomy were reduced in patients with type 2 diabetes and severe non-proliferative diabetic retinopathy (SNPDR) or worse by as much as 50% at 5 years ($p < 0.01$). There were no statistically significant differences among the patients with type 1 diabetes.

patients with type 2 diabetes and severe non-proliferative diabetic retinopathy or worse (figs 1 and 2).⁹ Such a treatment effect was not found in patients with type 1 diabetes. This interaction was also seen in the Diabetic Retinopathy Study, adding further evidence that this is not a chance finding. Often patients with type 2 diabetes and this level of severity of diabetic retinopathy may present with vitreous haemorrhage, thus making it difficult to administer scatter photocoagulation in a timely fashion. Based on the ETDRS data and personal experience, I would recommend that focal laser photocoagulation be followed by the administration of the scatter photocoagulation.

In summary, patients with severe non-proliferative diabetic retinopathy (SNPDR) should have their macular oedema treatment performed as soon as possible. A scatter (panretinal)

photocoagulation will be considered in patients with type 2 diabetes and severe NPDR because of the likelihood of reducing severe vision loss is greater with early laser photocoagulation. Although vigilant follow up is a potential option there is a high risk that the patient may present at the next visit with a preretinal or vitreous haemorrhage, which may make the treatment difficult.

Laser photocoagulation should also be considered in those patients with pending cataract extraction, pregnancy, and renal disease. These are all guidelines which obviously have to be evaluated in the context of each patient with his or her set of risk factors. The medical management is also an important part of the treatment. We need to communicate with our medical colleagues on this need. Together, we can hope to bring effective therapy to our patients with diabetic retinopathy.

REFERENCES

- 1 **UK Prospective Diabetes Study Group.** Intensive blood-glucose control with sulphonylureas or insulin compared with conventional treatment and risk of complications in patients with type 2 diabetes (UKPDS 33). *Lancet* 1998;**352**:837–53.
- 2 **The Diabetes Control and Complications Trial Research Group.** The effect of intensive treatment of diabetes on the development and progression of long-term complications in insulin-dependent diabetes mellitus. *N Engl J Med* 1993;**329**:977–86.
- 3 **The Diabetes Control and Complications Trial/Epidemiology of Diabetes Intervention and Complications Research Group.** Retinopathy and nephropathy in patients with type 1 diabetes four years after a trial of intensive therapy. *N Engl J Med* 2000;**342**:381–9.
- 4 **The Diabetes Control and Complications Trial/Epidemiology of Diabetes Interventions and Complications Research Group.** Effect of intensive therapy on the microvascular complications of type 1 diabetes mellitus. *JAMA* 2002;**287**:2563–9.
- 5 **UK Prospective Diabetes Study Group.** Tight blood pressure control and risk of macrovascular and microvascular complications in type 2 diabetes: UKPDS 38. *BMJ* 1998;**317**:703–13.
- 6 **Chew EY, Klein ML, Ferris FL III, et al, for the ETDRS Research Group.** Association of elevated serum lipid levels with retinal hard exudate in diabetic retinopathy. *Arch Ophthalmol* 1996;**114**:1079.
- 7 **Klein BEK, Moss SE, Klein R, et al.** The Wisconsin Epidemiologic Study of Diabetic Retinopathy: X. Relationship of serum cholesterol to retinopathy and hard exudate. *Ophthalmology* 1991;**98**:1261.
- 8 **Early Treatment Diabetic Retinopathy Study (ETDRS) Research Group.** Early photocoagulation for diabetic retinopathy: ETDRS report number 9. *Ophthalmology* 1991;**98**(Suppl):767.
- 9 **Ferris FL III.** Early photocoagulation in patients with either type I or type II diabetes. *Trans Am Ophthalmol Soc* 1996;**94**:505–37.

Debate



Overview

E Chew

Br J Ophthalmol 2004 88: 436-437
doi: 10.1136/bjo.2003.024760

Updated information and services can be found at:
<http://bjo.bmj.com/content/88/3/436.full.html>

These include:

References

This article cites 9 articles, 3 of which can be accessed free at:
<http://bjo.bmj.com/content/88/3/436.full.html#ref-list-1>

Email alerting service

Receive free email alerts when new articles cite this article. Sign up in the box at the top right corner of the online article.

Topic Collections

Articles on similar topics can be found in the following collections

[Retina](#) (1207 articles)
[Epidemiology](#) (756 articles)
[Ophthalmologic surgical procedures](#) (962 articles)
[Public health](#) (377 articles)

Notes

To request permissions go to:
<http://group.bmj.com/group/rights-licensing/permissions>

To order reprints go to:
<http://journals.bmj.com/cgi/reprintform>

To subscribe to BMJ go to:
<http://group.bmj.com/subscribe/>