

PostScript

LETTERS

If you have a burning desire to respond to a paper published in *BJO*, why not make use of our "rapid response" option?

Log on to our web site (www.bjophthalmol.com), find the paper that interests you, and send your response via email by clicking on the "eLetters" option in the box at the top right hand corner.

Providing it isn't libellous or obscene, it will be posted within seven days. You can retrieve it by clicking on "read eLetters" on our homepage.

The editors will decide as before whether to also publish it in a future paper issue.

Penetrating ocular injuries in previously injured blind eyes: should we consider primary enucleation?

We read with great interest the paper by Kilmartin *et al*¹ in which the authors noted that most of the newly diagnosed cases of sympathetic ophthalmia (SO) in their prospective study occurred in eyes that had sustained multiple injuries, either via trauma or intraocular surgery, and that enucleation following the onset of SO in these eyes was not related to a better visual outcome in the fellow eye. We have recently encountered two cases of ocular trauma in which, with the aforementioned two points in mind, we found it reasonable to consider and offer primary enucleation in an attempt to decrease the risk of SO.

The first case was a 46 year old man who had suffered a previous penetrating injury to his left eye as a child and now presented with a ruptured pre-phthisical globe after striking his left eye with his hand. The patient had previously undergone cataract extraction and trabeculectomy but had no light perception in that eye before the second injury, because of advanced glaucoma. The second patient was a 49 year old man who presented with a large scleral rupture in the left eye after being struck with a metal wrench. Seven years earlier, the patient had sustained a similar injury that had left him with no light perception in that eye. Given that both patients had no light perception in these previously injured eyes, we considered primary enucleation as a way to minimise the risk of SO. Both patients declined primary enucleation and have not developed any signs of ocular inflammation more than 6 months following repair of their second penetrating ocular injuries.

Sympathetic ophthalmia, a rare bilateral granulomatous panuveitis, presumably arises following penetrating ocular injury and surgery as a result of lymphatic exposure to a previously sequestered antigen.² The risk of SO following a penetrating ocular injury ranges from 0.1% to 0.3%.³⁻⁵ Although the risk of SO with multiple penetrating injuries has not been defined, increased antigen release with repeat uveal exposure probably carries an additive risk. This is supported by

the finding that most of the newly diagnosed cases of SO in the study by Kilmartin *et al*¹ had experienced multiple penetrating ocular events.

In addition, as Kilmartin *et al*¹ have shown, once SO develops, secondary enucleation of the exciting eye to reduce inflammation in the sympathising eye does not necessarily lead to a better visual outcome or to a reduced need for anti-inflammatory treatment. Secondary enucleation is often performed within 14 days of injury as protection against SO for repaired ruptured globes that demonstrate no potential for functional vision.⁶ Unfortunately, the time frame necessary to perform prophylactic secondary enucleation remains uncertain, as SO has been reported with secondary enucleation performed as early as 5 days following a penetrating ocular injury.⁷ The pre-existing lack of vision in previously injured eyes, however, changes the context in which a subsequent penetrating ocular injury is managed. In this setting, repairing the injury in order to assess for visual potential is futile, and primary enucleation may offer the best prophylaxis against SO.

In many instances, individuals who sustain multiple episodes of trauma either have poor access to health care or are non-compliant with prescribed drugs. Should SO develop in such patients, delayed presentation to an ophthalmologist may lead to an unfavourable outcome, as improved results have been shown with prompt and aggressive anti-inflammatory therapy.¹⁻⁸ Even patients who present early in the course of the disease may be committed to a lifetime of immunosuppressive therapy in order to salvage vision in their only seeing eye.

While primary enucleation is not typically recommended in open globe injuries, it may have a role in select cases of penetrating ocular injuries, such as those involving previously injured blind eyes. In these situations, the ophthalmologist and the patient must carefully assess and discuss the potentially increased risk of SO associated with preserving a disorganised, possibly painful, sightless eye.

Acknowledgement

Heed Ophthalmic Fellowship Foundation, Cleveland, Ohio (BHJ).

D A Hollander, B H Jeng, J M Stewart

Department of Ophthalmology, Francis I Proctor Foundation, University of California San Francisco, San Francisco, CA, USA

Correspondence to: Jay M Stewart, Doheny Retina Institute, University of Southern California, 1450 San Pablo Street, Suite 3600, Los Angeles, CA 90030, USA; ne62@yahoo.com

Accepted for publication 12 June 2003

References

- 1 Kilmartin DJ, Dick AD, Forrester JV. Prospective surveillance of sympathetic ophthalmia in the UK and Republic of Ireland. *Br J Ophthalmol* 2000;**84**:259-63.
- 2 Rao NA, Wong VG. Aetiology of sympathetic ophthalmitis. *Trans Ophthalmol Soc UK* 1981;**101**:357-60.
- 3 Allen JC. Sympathetic ophthalmia: a disappearing disease. *JAMA* 1969;**209**:1090.
- 4 Liddy BSTL, Stuart J. Sympathetic ophthalmia in Canada. *Can J Ophthalmol* 1972;**7**:157-9.
- 5 Kraus-Mackiw E, Muller-Ruchholtz W. Sympathetic eye disease: diagnosis and therapy. *Klin Monatsbl Augenheilkd* 1980;**176**:131-9.
- 6 Albert DM, Diaz-Rohena R. A historical review of sympathetic ophthalmia and its epidemiology. *Surv Ophthalmol* 1989;**34**:1-14.
- 7 Bellan L. Sympathetic ophthalmia: a case report and review of the need for prophylactic enucleation. *Can J Ophthalmol* 1999;**34**:95-8.
- 8 Chan CC, Roberge FG, Whitcup SM, *et al*. Thirty-two cases of sympathetic ophthalmia: a retrospective study at the National Eye Institute, Bethesda, MD, from 1982 to 1992. *Arch Ophthalmol* 1995;**113**:597-600.

Can antiseptic scrubs between cataract surgeries reduce bacterial load on surgical gloves to safe levels?

Although previous studies have reported on aspirate cultures after cataract surgery,¹⁻³ the minimum strength of inoculum causing endophthalmitis or the route through which the pathogen enters the eye remains unclear. A recent study reported the use of operative face masks to have a significant effect on the bacterial load falling on the operative site.⁴ Although cataract extraction and lens implant is a procedure of relatively short duration, airborne bacterial contamination of surgical gloves is still possible from the environment in the operating theatre. We designed a study to determine if antiseptic scrubs of surgical gloves between cataract surgeries will reduce bacterial load to levels equivalent to a new pair of sterile gloves.

We obtained approval of the ethics committee of the institute before initiating the study, and obtained necessary consent from participating subjects. Cataract surgery with intraocular lens implants was carried out through a self sealing scleral tunnel incision and manual expression of the lens. We randomly selected operating surgeons for the study. Each operating surgeon underwent a preoperative hand scrub repeated twice using chlorhexidine 0.5% solution for 5 minutes. Each operating surgeon wore a face mask, and donned a sterile surgical gown before gloving. Surgeons used commercially available pre-packed sterile powdered latex surgical gloves in the operating room. Each surgeon used 70% isopropyl alcohol solution applied for 30 seconds to scrub gloves between surgeries. None of the surgeons left the operating area in between surgeries. We used sterile cotton moistened with saline to take swabs from the gloves. Swabs were taken from the pre-packed sterile gloves after opening the pack in the operating room, and streaked across a blood agar plate. Swabs were collected from the fingertips and webs of fingers of both hands at random intervals after the first surgery, and streaked across independent blood agar plates. The surgeons also streaked separate blood agar plates with a random fingertip of both hands at the conclusion of their operating list before removal and disposal of the gloves. Surgical gloves once removed were not used again. Additional swabs were collected from the surgical gown over the elbows and abdominal

area of the surgeon at random intervals and streaked across blood agar plates. Swabs were also collected from the handles of operating microscopes at random intervals. The swabs, after inoculation into blood agar plates, were placed in brain-heart infusion broth.

The plates were incubated for 5 days at 37°C in a 5% carbon dioxide incubator. The plates were read by a microbiologist and declared culture negative if there was no evidence for growth at the end of 5 days. We defined culture positive as the presence of bacterial colonies on the streaked areas, or where the finger impressions were placed. Any species of bacteria were considered significant. The presence of turbidity in the brain-heart infusion broth, if any, was noted.

Surgeons included for the study performed 850 cataract surgeries with intraocular implants in a 5 day period. The mean number of cataract surgeries performed in a day by surgeons included for the study was 16.7 (SD 10.0) (range 4–30, median 15). The duration of surgery ranged from 1–5 hours (mean 6.0 (2.4) cases per hour). None of the culture plates showed any positive growth after 5 days for swabs taken from the sterile gloves, from the gloves in between cataract surgeries, and from the gowns and handles of operating microscopes.

There are, however, several issues to be considered. None of our surgeons had left the operating area in between cataract surgeries; we are not clear if we would have obtained the same results if surgeons reused the same gloves after leaving the operating area. Previous studies have reported the possibility of microscopic punctures to the gloves.^{5–7} Although modern cataract surgery is a “no ocular touch” technique, the possibility of microscopic droplet inoculation of the gloves with ocular fluid or other fluids cannot be ruled out.⁸ A previous study has reported that catheter contamination rates could be reduced without additional risk or cost by rinsing gloved hands in a solution of 0.5% chlorhexidine in 70% alcohol before handling the catheter.⁹ We do not however recommend antiseptic scrubs as an alternative to change of gloves because a sterile prepacked glove can reduce even a theoretical risk of contamination leading to endophthalmitis. However, in resource poor situations, antiseptic scrubs of gloves can be an alternative to change of gloves in between cataract surgeries.

Acknowledgement

Aravind Medical Research Foundation, Madurai, supported this study.

P K Nirmalan, P Lalitha, V N Prajna
Aravind Eye Care System, Madurai, India

Correspondence to: Praveen K Nirmalan, LAICO, Aravind Eye Care System, 72, Kuruvikaran Salai, Gandhi Nagar, Madurai-625020, Tamil Nadu, India; praveen@aravind.org

Accepted for publication 13 May 2003

Financial interest: none.

References

- 1 **Misilberger A**, Ruckhofer J, Raiithel E, *et al*. Anterior chamber contamination during cataract surgery with intraocular lens implantation. *J Cataract Refract Surg* 1997;**23**:1064–9.

- 2 **Prajna NV**, Sathish S, Rajalakshmi PC, *et al*. Microbiological profile of anterior chamber aspirates following uncomplicated cataract surgery. *Indian J Ophthalmol* 1998;**46**:229–32.
- 3 **Dickey JB**, Thompson KD, Jay WM. Anterior chamber aspirate cultures after uncomplicated cataract surgery. *Am J Ophthalmol* 1991;**112**:278–82.
- 4 **Alwitary A**, Jackson E, Chen R, *et al*. The use of surgical facemasks during cataract surgery: is it necessary? *Br J Ophthalmol* 2002;**86**:975–7.
- 5 **Miller KM**, Apt L. Unsuspected glove perforation during ophthalmic surgery. *Arch Ophthalmol* 1993;**111**:186–93.
- 6 **Nakazawa M**, Sato K, Mizuno K. Incidence of perforations in rubber gloves during ophthalmic surgery. *Ophthalmic Surg* 1984;**15**:236–40.
- 7 **Gunasekera PC**, Fernando RJ, de Silva KK. Glove failure: an occupational hazard of surgeons in a developing country. *J R Coll Surg Edinb* 1997;**42**:95–7.
- 8 **Heal JS**, Blom AW, Titcomb D, *et al*. Bacterial contamination of surgical gloves by water droplets spilled after scrubbing. *J Hosp Infect* 2003;**53**:136–9.
- 9 **Kocent H**, Corke C, Alajeel A, *et al*. Washing of gloved hands in antiseptic solution prior to central venous line insertion reduces contamination. *Anaesth Intensive Care* 2002;**30**:338–40.

Practical solutions to service shortcomings in the care of older people: the case for professional collaboration

Recent studies have reported shortcomings in the ways in which ophthalmic teams respond to the emotional and information needs of people who have age related macular degeneration (AMD). Research that I and colleagues have recently completed found similar concerns but also identified potential solutions.

Case report

Mitchell *et al*'s study¹ of the quality of health care in macular degeneration revealed that nearly half of the 2000 surveyed patients were critical of their eye specialist's attitude (variously described as unfeeling, uninterested, or dismissive) as well as lack of information and advice in eye clinics (about the sight condition, low vision aids, and support services). Howe² reminds us that these problems are not new, and that there is routine failure in ophthalmic units to provide adequate information and support. Improvements may be slow, partly because, as Stein *et al*³ discovered, ophthalmologists tend to underestimate the impact AMD has on quality of life.

Our recently completed research,⁴ which focused primarily on the housing and community support needs of blind and partially sighted post-retirees (most but not all suffering AMD), did not specifically solicit views on ophthalmic care per se. However, a strong theme arising out of the quantitative and qualitative interviews with our random sample of 400 people was that ophthalmic teams could have done more to prepare individuals for the emotional and practical consequences of late onset sight loss. Additionally, our data indicate a number of ways in which ophthalmic teams, through closer collaboration with social care professionals, can help address these criticisms of quality of care within eye clinics.

Comment

If people generally find it difficult to present emotional needs within consultations with their family doctor, the case in regard to 64%

of patients interviewed by Cape and McCullagh,⁵ raising worrying feelings within a specialist hospital setting is likely to be even more problematic. It follows that when patients cannot confidently articulate troublesome feelings then their emotional needs may be overlooked. The recognition of patients' emotional needs, by doctors, nurses, and allied specialist staff, is clearly important and yet, according to Barrick,⁶ awareness training initiatives do not appear to be reaching sufficient numbers of ophthalmic nurses. Our research suggests that eye clinics should have on site, or on call, appropriately trained staff, such as specialist sensory impairment social workers, occupational therapists, or rehabilitation workers. These professionals would be available to raise staff awareness of non-clinical needs, listen to patients and provide advice about possible sources of further help, such as counsellors.

Good patient care after diagnosis of AMD, or any other serious sight impairment, also includes the provision of timely and accessible information. Although it was the case that respondents in our research had often developed personal strategies to adapt to and cope with newly acquired impaired vision, they would have been greatly assisted in this process if they had been informed, at an early stage, about local blind associations, eligibility for financial benefits, and the availability and efficacy of low vision equipment. Again, close working between relevant professionals can make it more likely that relevant information is routinely made available. To this end, specialist workers from local social services sensory impairment teams and relevant voluntary sector agencies could usefully join forces to provide an “outreach” information/advice service within eye clinics.

In parallel with these initiatives, and to further bolster a more proactive approach to meeting the “social care” needs associated with late onset sight loss, ophthalmic units may additionally benefit from the regular input of relevant case study material and outcomes, presented at clinical meetings by practice and district nurses, rehabilitation workers, and specialist social services staff. Such an exchange of professional experience and knowledge offers the opportunity for developing a more holistic and integrated approach to improving the services available within eye clinics.

J Percival

Bartlett School of Graduate Studies, University College London, Gower Street, London WC1E 6BT, UK; john.percival@ucl.ac.uk

Accepted for publication 25 June 2003

References

- 1 **Mitchell J**, Bradley P, Anderson SJ, *et al*. Perceived quality of health care in macular disease: a survey of members of the Macular Disease Society. *Br J Ophthalmology* 2002;**86**:777–81.
- 2 **Howe LJ**. Management of age related macular degeneration: still room for improvement. *Br J Ophthalmology* 2003;**87**:375.
- 3 **Stein JD**, Brown MM, Brown GC, *et al*. Quality of life with macular degeneration: perceptions of patients, clinicians, and community members. *Br J Ophthalmology* 2003;**87**:8–12.
- 4 **Hanson J**, Johnson M, Percival J, *et al*. *The Housing and Support Needs of Older People with Visual Impairment*. London: Thomas Pocklington Trust, 2002.
- 5 **Cape J**, McCullagh Y. Patients' reasons for not presenting emotional problems in general

practice consultations. *Br J Gen Pract* 1999;49:875-9.

- 6 **Barrick A.** *Informing and Supporting: A review of support in UK eye clinics.* London: Royal National Institute for the Blind, 2000.

Sorsby fundus dystrophy presenting with choroidal neovascularisation showing good response to steroid treatment

Sorsby fundus dystrophy (SFD) is a dominantly inherited macular dystrophy in which bilateral central visual loss occurs in the fifth decade of life.¹ Duke-Elder and Perkins described it as pseudo-inflammatory macular dystrophy.² It is now known to be caused by mutations in exon 5 of the gene for *TIMP3*,³ tissue inhibitor of metalloproteinases-3. The disorder has variable expressivity and signs vary depending on age at review, but common fundus characteristics include diffuse fine yellow-white deposits, macular choroidal neovascularisation (CNV), and delayed choroidal filling and retinal pigment epithelial (RPE) mottling on fluorescein angiography (FFA). Later stages include atrophy of the macula and periphery.^{1,2}

Punctate inner choroidopathy (PIC) is characterised by multiple yellow opacities at the level of the inner choroid of the posterior pole and mid periphery without other evidence of inflammation. CNV is a frequent complication which responds to steroid treatment.⁴

We describe a patient who presented with clinical signs consistent with PIC complicated by bilateral CNV. The CNV was treated over a period of six years using either oral or sub-Tenon steroids with improvement in vision. She was subsequently found to have SFD.

CASE REPORT

A 36 year old woman presented with a two month history of difficulty reading with the left eye. Past ocular and medical history were unremarkable except for mild myopia (-2.00 dioptres).

On examination, visual acuities (VAs) were 6/5 in the right and 6/18 in the left eye with contact lenses. Fundoscopy revealed a retinal haemorrhage encroaching on the centre of the left fovea and a small chorioretinal scar temporal to the right fovea, which did not appear treatable on fluorescein angiography (FFA). Four months later, she became symptomatic in the right eye with distortion

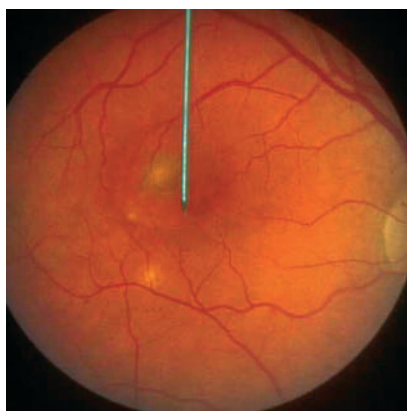


Figure 1 Colour photograph of the right fundus showing macular lesions.

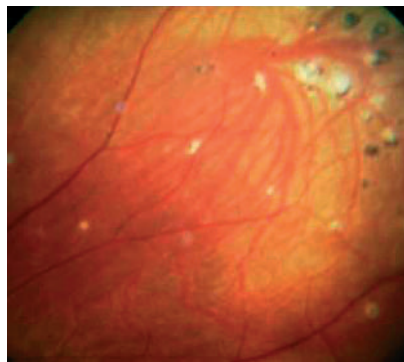


Figure 2 Colour photograph of the left fundus showing mid peripheral chorioretinal scars.

and blurring of vision (fig 1). The RVA was 6/24 and the LVA had stabilised at 6/12 with an old chorioretinal scar in the inferotemporal macula and a small white lesion superior to the fovea. There were several mid-peripheral chorio-retinal scars in both eyes (fig 2). Repeat FFA demonstrated right subfoveal CNV that was not amenable to laser treatment.

Investigations including full blood count, erythrocyte sedimentation rate, electrolytes, renal function, glucose, and chest x ray were all normal. Toxoplasma serology was negative. Serum angiotensin converting enzyme was mildly elevated at 65 U/l (20-54 U/l).

A diagnosis of punctate inner choroidopathy was made based on the clinical signs and the patient was started on 60 mg of daily oral prednisolone, reducing to 5 mg daily by six weeks. This was increased to 30 mg after her RVA deteriorated to 6/60. She remained on a low dose for another three months, by which time her vision returned to a RVA of 6/9 and LVA of 6/6 with glasses.

Three weeks later, she reported a large central scotoma affecting the right eye. RVA was 6/12 and LVA was 6/6. Fundoscopy revealed a small right foveal haemorrhage associated with subretinal oedema. Following a subTenon injection of 20 mg depomedrone, the RVA improved with a subjective reduction in the size of the central scotoma. For the next two years, her vision remained stable.

Four years after initial presentation, her left vision deteriorated again. Fundoscopy revealed areas of CNV superior and adjacent to the old scar in the left eye and FFA confirmed active CNV. She was started on a reducing course of 30 mg oral steroids daily. However, three more episodes of recurrent CNV occurred during oral steroid dose reduction, and were treated by a transient increase in oral steroid dose followed by two subTenon injections of 40 mg triamcinolone. Her LVA improved to 6/9 and remained at 6/12 in the right with resolution of the oedema and scarring. She eventually stopped her steroids for 18 months.

Five years after presentation, a paternal cousin was diagnosed with SFD. Although her family history at presentation was unremarkable, subsequent enquiries revealed that her paternal aunt had been diagnosed with age related macular degeneration (AMD) in her forties. Her father died at the age of 39. She was consequently screened for mutations in the *TIMP3* gene which confirmed that she had the same Ser181Cys mutation as her cousin.

Currently, her RVA is 6/12 and her LVA is 6/9 after a recent recurrence was treated with

subTenon triamcinolone injection. Six years following presentation, she has developed the characteristic yellow-white deposits originally described by Sorsby in both eyes.

COMMENT

This case highlights two main points. Firstly, the fundus features at presentation mimicked those of PIC, and the characteristic yellow-white deposits of SFD were not obvious until six years later. Although it is possible that this patient may have had a combination of PIC and SFD, she may just illustrate the phenotypic variability of SFD.

Secondly, a clear objective improvement in vision was demonstrated after systemic and peri-ocular steroid treatment. There is now experimental and clinical evidence for using steroids in the treatment of choroidal neovascularisation and thus potentially for SFD. Angiostatic steroids inhibit experimental neovascularisation of the choroid⁵ and have been used successfully in patients with CNV secondary to ocular histoplasmosis⁶ and AMD.⁷

In SFD, mutations in the *TIMP3* gene result in the characteristic accumulation of extracellular deposits in Bruch's membrane which are rich in TIMP-3 protein.⁸ The TIMP family of proteins regulate extracellular matrix (ECM) degradation by matrix metalloproteinases (MMPs) and therefore play a key role in a range of physiological processes that include angiogenesis. In the homozygous *Timp3*-null mouse, absent TIMP-3 inhibitory activity leads to the unscheduled activation of MMPs.⁹ The resultant breakdown of the ECM would allow endothelial cells to initiate the process of sprouting or release sequestered angiogenic factors such as vascular endothelial growth factor and/or basic fibroblast growth factor, which promote endothelial cell proliferation and migration. A third possibility is the exposure of an angiogenic cryptic site upon proteolytic cleavage of ECM molecules such as collagen type IV.¹⁰ This may account for the reported inhibitory effect of TIMP-3 on angiogenesis¹¹ although mutant TIMP-3 may not have this property.

Interestingly, MMP expression is significantly attenuated by high concentrations of corticosteroids in the eye¹² which have also been shown to stimulate TIMP-3 expression.¹³ Both actions would have the predicted effect of reducing ECM breakdown and inhibiting angiogenesis. It is therefore not unexpected that steroid treatment in our patient had the effect of improving or stabilising vision with suppression of growth of CNV.

It has been noted that laser treatment in SFD is generally unhelpful,¹⁴ although the role of photodynamic therapy has yet to be fully evaluated. Therefore, early intervention with steroids, whether orally, peri-ocularly, or even by intravitreal injection, may be a useful treatment in this condition with a notoriously poor natural history.

D Atan

Bristol Eye Hospital, Bristol, UK

C Y Gregory Evans

Faculty of Medicine, Imperial College London, UK

D Louis, S M Downes

Oxford Eye Hospital, Oxford, UK

Correspondence to: Miss S M Downes, Oxford Eye Hospital, Radcliffe Infirmary, Woodstock Road, Oxford OX2 6HE, UK; susan.downes@orh.nhs.uk

Accepted for publication 15 May 2003

References

- 1 **Sorsby A**, Mason M. A fundus dystrophy with unusual features. *Br J Ophthalmol* 1949;**33**:67-97.
- 2 **Diseases of the Uveal Tract**. In: Duke-Elder S, ed. *System of Ophthalmology*. London: Kimpton, 1966:715-19.
- 3 **Weber BH**, Vogt G, Pruett RC, et al. Mutations in the tissue inhibitor of metalloproteinases-3 (TIMP3) in patients with Sorsby's fundus dystrophy. *Nat Genet* 1994;**8**:352-6.
- 4 **Flaxel CJ**, Owens SL, Mulholland B, et al. The use of corticosteroids for choroidal neovascularisation in young patients. *Eye* 1998;**12**:266-72.
- 5 **Ishibashi T**, Miki K, Sorgente N, et al. Effects of intravitreal administration of steroids on experimental subretinal neovascularization in the subhuman primate. *Arch Ophthalmol* 1985;**103**:708-11.
- 6 **Martidis A**, Miller DG, Ciulla TA, et al. Corticosteroids as an antiangiogenic agent for histoplasmosis-related subfoveal choroidal neovascularization. *J Ocul Pharmacol Ther* 1999;**15**:425-8.
- 7 **Danis RP**, Ciulla TA, Pratt LM, et al. Intravitreal triamcinolone acetonide in exudative age-related macular degeneration. *Retina* 2000;**20**:244-50.
- 8 **Fariss RN**, Apte SS, Luthert PJ, et al. Accumulation of tissue inhibitor of metalloproteinases-3 in human eyes with Sorsby's fundus dystrophy or retinitis pigmentosa. *Br J Ophthalmol* 1998;**82**:1329-34.
- 9 **Leco KJ**, Waterhouse P, Sanchez OH, et al. Spontaneous air space enlargement in the lungs of mice lacking tissue inhibitor of metalloproteinases-3 (TIMP-3). *J Clin Invest* 2001;**108**:817-29.
- 10 **Xu J**, Rodriguez D, Petitclerc E, et al. Proteolytic exposure of a cryptic site within collagen type IV is required for angiogenesis and tumor growth in vivo. *J Cell Biol* 2001;**154**:1069-79.
- 11 **Anand-Apte B**, Pepper MS, Voest E, et al. Inhibition of angiogenesis by tissue inhibitor of metalloproteinase-3. *Invest Ophthalmol Vis Sci* 1997;**38**:817-23.
- 12 **el-Shabrawi Y**, Eckhardt M, Berghold A, et al. Synthesis pattern of matrix metalloproteinases (MMPs) and inhibitors (TIMPs) in human explant organ cultures after treatment with latanoprost and dexamethasone. *Eye* 2000;**14**:375-83.
- 13 **Leco KJ**, Khokha R, Pavloff N, et al. Tissue inhibitor of metalloproteinases-3 (TIMP-3) is an extracellular matrix-associated protein with a distinctive pattern of expression in mouse cells and tissues. *J Biol Chem* 1994;**269**:9352-60.
- 14 **Holz FG**, Haimovici R, Wagner DG, et al. Recurrent choroidal neovascularization after laser photocoagulation in Sorsby's fundus dystrophy. *Retina* 1994;**14**:329-34.

subscription (4 issues) UK£28/US\$45. Free to developing country applicants.

Elimination of avoidable blindness

The 56th World Health Assembly (WHA) considered the report on the elimination of avoidable blindness (doc A56/26) and urged Member States to: (1) Commit themselves to supporting the Global Initiative for the Elimination of Avoidable Blindness by setting up a national Vision 2020 plan by 2005; (2) Establish a national coordinating committee for Vision 2020, or a national blindness prevention committee to help implement the plan; (3) Implement the plan by 2007; (4) Include effective monitoring and evaluation of the plan with the aim of showing a reduction in the magnitude of avoidable blindness by 2010; (5) To support the mobilisation of resources for eliminating avoidable blindness. The WHA also urged the Director-General to maintain and strengthen WHO's collaboration with Member States and the partners of the Global Initiative for the Elimination of Avoidable Blindness as well as aid in the coordination and support of national capability.

5th International Symposium on Ocular Pharmacology and Therapeutics (ISOPT)

The 5th International Symposium on Ocular Pharmacology and Therapeutics (ISOPT) will take place 11-14 March 2004, in Monte Carlo, Monaco. Please visit our website for details of the scientific programme, registration, and accommodation. To receive a copy of the Call for Abstracts and registration brochure, please submit your full mailing details to <http://www.kenes.com/isopt/interest.htm>. Further details: ISOPT Secretariat (website: www.kenes.com/isopt).

XVth Meeting of the International Neuro-Ophthalmology Society

The XVth Meeting of the International Neuro-Ophthalmology Society will take place 18-22 July 2004, in Geneva, Switzerland. Further details: Prof. A Safran, University Hospital Geneva, c/o SYMPORG SA, Geneva (fax: +4122 839 8484; email: info@symporg.ch; website: www.symporg.ch).

4th International Congress on Autoimmunity

The 4th International Congress on Autoimmunity will take place 3-7 November 2004 in Budapest, Hungary. The deadline for the receipt of abstracts is 20 June 2004. Further details: Kenes International Global Congress Organisers and Association Management Services, 17 Rue du Cendrier, PO Box 1726, CH-1211 Geneva 1, Switzerland (tel: +41 22 908 0488; fax: +41 22 732 2850; email: autoim04@kenes.com; website: www.kenes.com/autoim2004).

4th Meeting of the British Oculoplastic Surgery Society (BOPSS)

The British Oculoplastic Surgery Society (BOPSS) will be holding a meeting in

Manchester on 9 & 10 May 2004 (immediately before the College Congress). The organisers are: Saj Ataullah, Brian Leatherbarrow, Claire Inkster and Mark Halliwell. The social programme begins on the evening of Saturday 8 May. The meeting dinner will be held on Sunday 9 May. The key note invited speaker is Alan McNab, Melbourne. The deadline for abstracts is 27 February 2004. Further information is available from www.bopss.org or by telephone voice mail, on 07092 104 769.

14th Meeting of the EASD Eye Complication study group

The 14th Meeting of the EASD Eye Complication (EASDEC) study group will take place on the 21-23 May 2004. There will be key lecture notes on the following topics: Peter Gaede (Denmark)-Results of the Steno 2 study, Hans Peter Hammes (Germany)-Animal models of diabetic retinopathy, Massimo Porta (Italy)-Screening with the London protocols: 12 years after, and Anselm Kampik (Germany)-Surgical options in diabetic retinopathy. There will also be case presentations and oral and poster presentations. The EASDEC board comprises F Bandello (President), PJ Guillausseau (Vice President), C-D Agardh (Past President), P Massin (Secretary), M Porta (Treasurer). The Scientific and Organizing Committee includes: F Bandello, PJ Guillausseau, P Massin, C-D Agardh, M Porta, A Kampik, M Ulbig, and G Lang. There are three travel grants available, at 1000 Euro each, for young scientists (less than 35 years at the time of the meeting). Application for the grant should be made together with the submission of the abstract. For further information, contact: Department of Ophthalmology, Ingrid Mannl, Ludwig-Maximilians-University, Mathildenstr. 8, 80336 MUNICH, Germany (tel: +49-89-5160-3800; fax: +49-89-5160-4778; e-mail: easdec@ak-i.med.uni-muenchen.de). The deadline for abstracts is 2 March 2004.

International Strabismological Association (ISA) Fellowship

The International Strabismological Association (ISA) has established one fellowship for either basic or advanced training in strabismus/paediatric ophthalmology supported by the amount of US \$10,000. Applications may be obtained from the Secretary/Treasurer or the ISA, Derek T. Sprunger, MD, at Indiana University School of Medicine, 702 Rotary Circle, Indianapolis, Indiana 46202 or by e-mail at isa.lms@juno.com. The last day for this application is 15 March 2004.

20th Asia Pacific Academy of Ophthalmology (APAO) Congress

The 20th Asia Pacific Academy of Ophthalmology (APAO) Congress will be taking place on 27-31 March 2005. It will be held in Kuala Lumpur, Malaysia. For further information, please contact the organisers (e-mail: secretariat@apao2005.com.my; tel: +603 7956 3113; fax: +603 7960 8297; website: www.apao2005.com.my).

NOTICES

HIV/AIDS and the eye

The latest issue of *Community Eye Health* (No 47) discusses the impact of the HIV/AIDS epidemic on prevention of blindness programmes. For further information please contact: Journal of Community Eye Health, International Resource Centre, International Centre for Eye Health, Department of Infectious and Tropical Diseases, London School of Hygiene and Tropical Medicine, Keppel Street, London WC1E 7HT, UK (tel: +44 (0)20 7612 7964; email: Anita.Shah@lshtm.ac.uk; website: www.jceh.co.uk). Annual



Practical solutions to service shortcomings in the care of older people: the case for professional collaboration

J Percival

Br J Ophthalmol 2004 88: 439-440
doi: 10.1136/bjo.2003.027953

Updated information and services can be found at:
<http://bjo.bmj.com/content/88/3/439.full.html>

These include:

References

This article cites 4 articles, 3 of which can be accessed free at:
<http://bjo.bmj.com/content/88/3/439.full.html#ref-list-1>

Email alerting service

Receive free email alerts when new articles cite this article. Sign up in the box at the top right corner of the online article.

Notes

To request permissions go to:
<http://group.bmj.com/group/rights-licensing/permissions>

To order reprints go to:
<http://journals.bmj.com/cgi/reprintform>

To subscribe to BMJ go to:
<http://group.bmj.com/subscribe/>