

Postscript

LETTERS

If you have a burning desire to respond to a paper published in *BJO*, why not make use of our "rapid response" option?

Log onto our website (www.bjophthalmol.com), find the paper that interests you, and send your response via email by clicking on the "eLetters" option in the box at the top right hand corner.

Providing it isn't libellous or obscene, it will be posted within seven days. You can retrieve it by clicking on "read eLetters" on our homepage.

The editors will decide as before whether to also publish it in a future paper issue.

Tears and conjunctival scrapings for coronavirus in patients with SARS

Severe acute respiratory syndrome (SARS) was first recognised in Guangdong Province in China and later in Hong Kong in March 2003.¹ Within a matter of weeks, the outbreak has evolved to become a global health threat and almost 30 countries have been afflicted with the novel coronavirus strain (SARS-CoV).² SARS is a highly contagious potentially lethal disease. The main route of transmission is by respiratory droplets, though the virus has also been isolated in stool and in urine. Tears, being one of the body fluids, may potentially harbour the coronavirus. The presence of viruses in these body fluids may affect our precaution practices and sites of sampling for diagnostic tests.

Case series

A prospective interventional case series study was conducted on the identification of the SARS-CoV virus in tear secretions and conjunctival cells of patients with confirmed SARS. Approval was obtained from the ethics committee of the Chinese University of Hong Kong. Consecutive patients with probable SARS in the Prince of Wales Hospital, Hong Kong, during the epidemic period from April to May 2003 were recruited. Other than the routine samples of nasopharyngeal, mouthwash and stool, tear swab and conjunctival

scraping were taken randomly from one eye of all recruited patients.

The tear swab was taken by putting a sterile cottonwool stick into the deep lower fornix of each patient's eye after a single drop of topical anaesthetic agent (1% amethocaine eye drops) was applied. Conjunctival scraping was performed at the lower palpebral conjunctiva with a bent tip of a sterile 23 gauge needle. All ocular samples were collected by a single ophthalmologist with personal protective equipment recommended by the infection control unit of the hospital. Particular care was taken not to contaminate the samples.

The samples were analysed by virus culture and RT-PCR. The SARS-CoV specific primers COR-1 (sense) 5' CAC CGT TTC TAC AGG TTA GCT AAC GA 3' and COR-2 (antisense) 5' AAA TGT TTA CGC AGG TAA GCG TAA AA 3' were used to detect the presence of SARS-CoV RNA.³ All the patients were further categorised as confirmed SARS with a seroconversion or fourfold increase in antibody titre. The antibody against coronavirus was detected by indirect immunofluorescent technique based on Vero cells infected with SARS-CoV isolated from a patient with SARS.³

A total of 20 probable SARS patients were recruited and 17 were later confirmed with paired convalescent sera. Among the confirmed cases, the mean age was 40.5 (SD 8.8) years and 12 (70.6%) were female. They were recruited during the first (n=6, 35.3%), second (n=8, 47.1%), and third (n=3, 17.6%) weeks of their diseases. Five (29.4%) of the 17 patients were positive for SARS-CoV by PCR with the samples from nasopharynx or stool (table 1). In all tear and conjunctival scraping samples, no SARS-CoV virus could be detected by RT-PCR or isolated by viral culture. Apart from two patients having mild and self limiting conjunctival bleeding after scrapings, no other ophthalmic complication was reported.

Comment

The routes of transmission of SARS other than respiratory droplets and stool are still enigmatic. In fact, tears have been reported by the World Health Organization to be one of the body fluids that might convey the novel SARS coronavirus, though the infectivity or clinical significance is not known.⁴

The negative findings of SARS-CoV viral genetic material or viable virus in the tear

secretion or conjunctival cells of patients with serologically confirmed SARS may have several interpretations. Firstly, RT-PCR testing or viral culture is known to be very specific but lacks sensitivity. Peiris and colleagues reported that only 22 of 44 (50.0%) nasopharyngeal aspirate samples and 10 of 18 (55.6%) faecal samples from patients confirmed with SARS had coronavirus genetic material detected by RT-PCR.³ So negative test results can be false negative and do not exclude the presence of the virus. Sensitivity can be increased if multiple specimens are tested. Secondly, it is possible that the virus and its genetic material were only present for a brief period of the disease, and the samples were not collected at the right time. Thirdly, the virus might not be present in tears at all.

The limitations of this study are the relatively small sample size and only the fact that one sample of tear swab and conjunctival scraping were taken from each patient. We cannot totally exclude the presence of virus in the tear secretion, but it is clear that conjunctival swabs and conjunctival scrapings are not useful samples for confirming or excluding the diagnosis.

W M Chan, K S C Yuen, D S P Fan, D S C Lam
Department of Ophthalmology and Visual Sciences,
The Chinese University of Hong Kong, Hong Kong

P K S Chan
Department of Microbiology, The Chinese University
of Hong Kong, Hong Kong

J J Y Sung
Department of Medicine and Therapeutics,
The Chinese University of Hong Kong, Hong Kong

Correspondence to: Professor D S C Lam, Department
of Ophthalmology and Visual Sciences, The Chinese
University of Hong Kong, 3/F, Hong Kong Eye
Hospital, 147K Argyle Street, Kowloon, Hong Kong;
dennislam@cuhk.edu.hk

doi: 10.1136/bjo.2003.039461

Accepted for publication 4 December 2003

Financial and proprietary interest: Nil.

Financial support: Supported by the Action for Vision
Eye Foundation, Hong Kong.

Conflict of interest: Nil.

References

- 1 Peiris JS, Chu CM, Cheng VC, *et al*. Clinical progression and viral load in a community outbreak of coronavirus-associated SARS pneumonia: a prospective study. *Lancet* 2003;361:1767-72.
- 2 World Health Organization. Cumulative number of reported probable cases of severe acute respiratory syndrome (SARS). (www.who.int/csr/sars/country/table2003_09_23/en/) Accessed 15 October 2003.
- 3 World Health Organization. Use of laboratory methods for SARS diagnosis. (www.who.int/csr/sars/labmethods/en/) Accessed 2 November 2003.
- 4 World Health Organization. Update 27—One month into the global SARS outbreak: status of the outbreak and lessons for the immediate future. (www.who.int/csr/sarsarchive/2003_04_11/en/) Accessed 2 November 2003.

Table 1 Samples for RT-PCR in probable and confirmed SARS

	Probable SARS (n=20)	
	Positive convalescent antibody, confirmed case (n=17)	Negative convalescent antibody, excluded cases (n=3)
	No of patient with positive RT-PCR (%)	No of patient with positive RT-PCR (%)
Nasopharyngeal aspirate and stool	5 (29.4)	0 (0)
Tear swab	0 (0) *p=0.0444	0 (0)
Conjunctival scraping	0 (0) *p=0.0444	0 (0)

*Fisher's exact test, two tail.

- 5 Peiris JS, Lai ST, Poon LL, *et al.* Coronavirus as a possible cause of severe acute respiratory syndrome. *Lancet* 2003;**361**:1319–25.

Congenital third nerve palsy in septo-optic dysplasia

Paediatric oculomotor nerve palsies are rare lesions. The most frequently cited mechanism is perinatal injury to the peripheral third nerve,¹ although they may be due to congenital absence of the nerve and/or nucleus and be accompanied by neurological deficits.^{2–4} Septo-optic dysplasia consists of optic hypoplasia, mid-brain malformations, and hypothalamohypophysial dysfunction. We present three children with congenital third nerve palsy and septo-optic dysplasia.

Case reports

We report on three children with bilateral optic nerve hypoplasia, with visual function from light projection to 0.05 and nystagmus. Magnetic resonance imaging revealed absent septum pellucidum, thinning of corpus callosum, and posterior pituitary ectopia in two cases and infundibular hypoplasia in the third case. They had anterior pituitary hormone deficiency—growth hormone, adrenocorticotropic hormone, and hypothyroidism in case one and two, with additional diabetes insipidus in the third case. There were no other associated brain or ocular anomalies. These children had no positive history of perinatal trauma, drugs, or toxic agents. There was no history of parental consanguinity.

Case 1: unilateral, left, pupil sparing third nerve palsy, with fixed exodeviation of 45 prism dioptres and hypotropia of 30 prism dioptres, no aberrant regeneration, no ptosis.

Case 2: fixing with the paretic left eye (visual acuity 0.05 both eyes) demonstrated an elevation deficit of –3, adduction deficit of –2 on this side but good depression. There was no ptosis, anisocoria, or aberrant regeneration of the oculomotor nerve.

The third case was brought to our attention immediately after birth with bilateral third nerve palsy and pupil involvement on the left side (figs 1 and 2). Orthoptic examination revealed bilateral defective medial gaze and elevation and defective depression on the left side. In course of the first year of life pupillary reaction recovered without aberrant regeneration. At the age of 12 years the child died during febrile illness.

Comment

Our three children with septo-optic dysplasia had unilateral congenital third nerve palsy in two cases and bilateral palsy in one case.



Figure 1 Bilateral third nerve palsy with pupillary involvement left side, age 3 months.

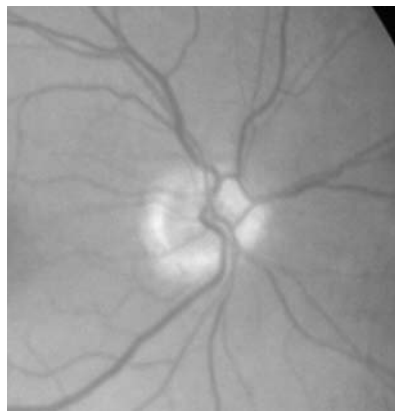


Figure 2 Optic hypoplasia.

There was no ptosis and no involvement of the contralateral superior rectus muscle in the two patients with unilateral nerve disturbance, indicative perhaps of peripheral nerve defect. A possible explanation for the lack of aberrant regeneration may be due to extreme atrophy or even absence of the third nerve.⁵ The child with bilateral third nerve palsy (case 3) had postnatal pupillary involvement in one eye, with regeneration within 1 year. Peripheral nerve damage as well as nuclear defects may have been responsible. Previous reports in the literature showed that several kinds of brain damage could result in congenital oculomotor palsies, such as brainstem infarction, cerebellar and midbrain hypoplasia, absence of basal ganglia, etc.^{5–6}

Two theories have been proposed regarding the pathogenesis of septo-optic dysplasia. As all affected components arise from different tissues and processes at different times developmental anomaly or dysplasia makes little embryological sense. Genetic causes are exceptional.⁷ A vascular disruptive sequence similar to porencephaly, possibly involving the proximal trunk of the anterior cerebral artery is discussed by Lubinsky.⁸ Our findings of congenital third nerve palsy in de Morsier syndrome do not support this hypothesis, as the third cranial nerve and its nuclei are not within the territorial distribution of the anterior cerebral artery and there were no additional defects in the median and paramedian areas of the frontal lobes. The partial palsy in case two, with some amount of adduction, elevation, and depression and the recovery of the pupillary involvement in case three implicate probably prenatal traumatic, infectious or toxic insults, thus supporting the theory of secondary degeneration.

A Langmann, S Lindner

Department of Ophthalmology, University Graz, Austria

Correspondence to: A Langmann, MD, Department of Ophthalmology, Medical University, Auenbruggerplatz 4, University Graz, Austria; andrea.langmann@uni-graz.at

doi: 10.1136/bjo.2003.034405

Accepted for publication 28 October 2003

References

- 1 **Hamed LM.** Associated neurologic and ophthalmologic findings in congenital oculomotor nerve palsy. *Ophthalmology* 1991;**98**:708–14.

- 2 **Balkan R, Hoyt CS.** Associated neurological abnormalities in congenital third nerve palsies. *A J Ophthalmol* 1984;**97**:315–19.
- 3 **Brodsky M, Conte F, Taylor D, et al.** Sudden death in septo-optic dysplasia. *Arch Ophthalmol* 1997;**115**:66–7.
- 4 **Sun Ch.Ch., Kao L-Y.** Unilateral congenital third nerve palsy. *Chan Gung Med J* 2000;**23**:776–80.
- 5 **Norman MG.** Unilateral encephalomalacia in cranial nerve nuclei in neonates: report of two cases. *Neurology* 1976;**24**:424.
- 6 **Schulz E, Jung H.** Unilateral congenital oculomotor nerve palsy, optic nerve hypoplasia and pituitary malformation. A preliminary report. *Strabismus* 2001;**9**:33–5.
- 7 **Tajima T, Hattori T, Nakajima T, et al.** Sporadic heterozygous frameshift mutation of HESX1 causing pituitary and optic nerve hypoplasia and combined hormone deficiency in a Japanese patient. *J Clin Endocrinol Metab* 2003;**8**:45–5.
- 8 **Lubinsky M.** Hypothesis: septo-optic dysplasia is a vascular disruption sequence. *Am J Med Genet* 1997;**69**:235–6.

Penetrating eye injury from rear view mirrors

Penetrating eye injuries are a common complication of severe motor vehicle accidents. The majority of cases accompany facial laceration when the head of a front seat occupant passes forward, and then back, through the broken windshield. The frequency of such injuries has been greatly reduced since legislation was introduced to make the wearing of seatbelts for all occupants and the use of laminated windshield glass compulsory. Glass entering the car through an open side window from a broken external rear view mirror is an uncommon but potentially preventable cause of severe ocular injury. First reported in 1990 by Keenan¹ there have been two subsequent reports from Australia.^{2,3} We report two further cases and highlight deficiencies in legislation regarding the manufacture of external rear view mirrors.

Case reports

Case 1

A 17 year old man was driving a 1987 registered Fiat Uno when the driver's external rear view mirror struck an oncoming van. The mirror broke and a fragment of glass passed through the open side window and hit his left eye. He sustained a corneal and scleral laceration but the lens and iris were not damaged. Following primary repair he made an uneventful postoperative recovery and retained a corrected visual acuity of 6/9 with spectacles.

Case 2

A 22 year old woman passenger of a 2002 registered Peugeot 206 was struck in the right eye when the side mirror struck the mirror of a parked car. The mirror was broken and a fragment of glass entered her right eye through the open passenger window. She sustained a large corneal and scleral laceration with loss of the majority of the iris and damage to the lens. She underwent primary repair of the laceration with lens aspiration and anterior vitrectomy. She subsequently required a second vitrectomy with gas injection for vitreous gel incarceration and a retinal tear. She regained a visual acuity of 6/24 with a contact lens correction, but further improvement was prevented by corneal scar.

Comment

Broken rear view mirrors have previously been identified as a cause of severe ocular injuries.¹⁻³ The two cases we describe occurred in similar circumstances and both patients sustained penetrating eye injuries caused by glass from the broken external rear view mirror entering the car through an open window. The external rear view mirrors project beyond the body of the car and in both cases the mirror was broken following a collision with another vehicle in which the wing mirrors were clipped. No other vehicle damage occurred.

All exterior rear view mirrors fitted to cars in the United Kingdom have to comply with the European Community Directive 71/127/EEC which was last amended in 1988 (Directive 88/321).⁴ This requires mirrors designed for use in cars to undergo a "pendulum test" using a 7 kg weight on a pendulum of 1 metre length released at a 60 degree angle from the vertical to represent the impact of a head hitting the mirror. The test is performed with the weight hitting both the reflecting surface side and repeated on the opposite surface. If, at the end of this test, the glass of the mirror breaks, any fragments should adhere to the back of the protective housing. However, the directive further specifies that:

- (1) Partial unsticking of the glass is permitted provided that this does not exceed 2.4 mm either side of the cracks. It is acceptable for small shards to detach themselves from the surface of the glass at the point of impact.
- (2) The reflecting surface shall be made of safety glass.

It is therefore permissible for small splinters of glass to become detached from the surface of the glass at the point of impact, which is the case for any automobile safety glass. However, in both our cases the fragments appear to have been released from the mirror by spalling following a relatively high velocity impact on the reverse of the mirror housing. The released glass fragments had sufficient momentum to pass through the open window of the car and penetrate the eye. The test described above simulates an object striking the mirror at a velocity of 3.1 ms^{-1} , compared to a velocity of 13.4 ms^{-1} when the mirror of a car travelling at 30 miles per hour hits a stationary object. This velocity would be considerably higher if the car mirror clipped an oncoming car.

These cases highlight that there is a continuing risk of severe eye injury following an impact on the back surface of an external rear view mirror. Current legislation is based on a test that does not replicate the most probable circumstance of impact or the associated risk to the eye. The test is based on the effect of a low velocity impact, as opposed to the high velocity impact that would result from two cars passing in opposing directions. Replacing the glass with plastic would be an option to reduce the risk, although current plastic surfaces do not have the resistance to abrasion of glass which could result in scratches causing distracting light scatter. Avoiding driving with the side windows down, or repositioning the external mirrors are further options.

C Cole, S Tuft

Moorfields Eye Hospital, 162 City Road, London EC1V 2PD, UK

Correspondence to: Mr Stephen Tuft, Moorfields Eye Hospital, 162 City Road, London EC1V 2PD, UK; s.tuft@ucl.ac.uk

doi: 10.1136/bjo.2003.038653

Accepted for publication 3 December 2003

References

- 1 Keenan JM, Raines MF. Ocular injuries from external rear view mirrors. *Eye* 1990;**4**:649-50.
- 2 Thompson CG, Cottee L, Nardi W, *et al*. Perforating eye injuries from external rear vision mirrors. *Aust N Z J Ophthalmol* 1998;**26**:61.
- 3 Thompson C. Ocular injuries and rear-view mirrors (letter). *Clin Exp Ophthalmol* 2000;**28**:395.
- 4 Office for Official Publications of the European Communities CONSLG:1997L0024-20/09/2002.

Coats' disease in a vegetarian female

Coats' disease is an idiopathic condition characterised by telangiectatic and aneurysmal retinal vessels changes with intraretinal and subretinal exudates.¹⁻³ Here we report one case of a young female with an unusual manifestation of Coats' disease.

Case report

A 14 year old female was referred for loss of vision in the left eye of a few weeks' duration. The referring ophthalmologist thought the patient had a chorioretinal inflammatory process with secondary exudative retinal detachment and had recommended a complete medical examination for chorioretinitis.

Visual acuity was 20/20 right eye and 20/400 left eye. Anterior segment examination was normal in both eyes. There were no cells or flare in the anterior chamber and in the anterior vitreous in either eye. Posterior fundus examination of the right eye was normal. In the left eye there was an exudative, neurosensory macular detachment and intraretinal lipid exudation temporally (fig 1A), leading to an area of microvascular changes in the temporal periphery. A serous, dependent neurosensory detachment with intraretinal lipid exudation was present as well. Fluorescein angiography study of the left eye confirmed the presence of marked

microvascular changes in the peripheral retina (fig 1B). There was capillary non-perfusion, dilation and beading of the larger vessels, aneurysmal and telangiectasia formation. There were also telangiectatic vascular changes and intraretinal leakage of fluorescein dye throughout the peripheral fundus. The patient was diagnosed with Coats' disease, even if the clinical presentation was somewhat unusual for Coats' disease, given the absence of massive intraretinal and subretinal lipid exudation. A complete medical examination inclusive of PPD, chest x ray, lime titre, *Bartonella* titre, FTA-abs, VDRL, ACE level, CBC with differential, was negative. The patient had been an absolute vegetarian from birth; her cholesterol level was 116, and her triglyceride level was 83.

Scatter laser photocoagulation was applied around the area of telangiectatic retinal changes and in the temporal retina. Six months later the vision was improved to 20/100. There was partial resolution of the exudative, neurosensory retinal detachment and more lipid deposition in the macula. There was also new occurrence of preretinal neovascularisation and vitreous haemorrhage (fig 2A, B). Further scatter photocoagulation was applied to the temporal retina. One year after the original presentation the vision in the left eye had improved to 20/40. There was complete resolution of the exudative neurosensory detachment both in the macula and in the inferior periphery. The lipid exudation in the macula had mostly reabsorbed. There was also total regression of the preretinal neovascularisation in the temporal periphery (fig 2C, D). There was also complete resolution of the microvascular telangiectatic changes and intraretinal leakage both in the temporal retina, which had been treated with scattered laser photocoagulation and in the nasal retina, which had received no treatment.

Comment

This is an unusual manifestation of Coats' disease because of the limited intraretinal lipid exudation.⁴ A possibility is that the reduced lipid exudation was related to the fact that the patient was totally vegetarian with very low cholesterol and triglyceride

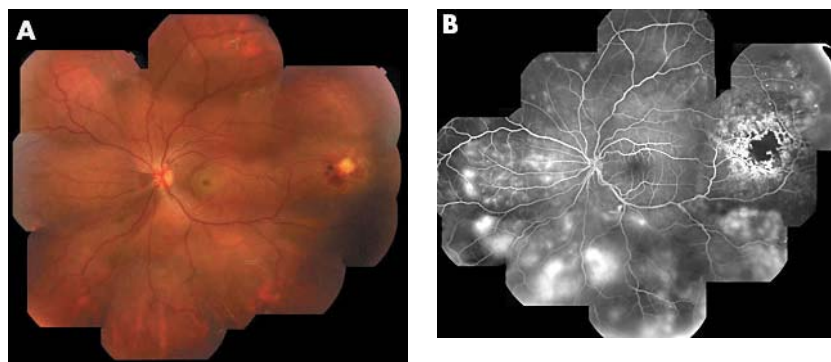


Figure 1 (A) Composite clinical picture of the left eye demonstrated the presence of serous, neurosensory macular detachment, and mild lipid exudation. A well localised area of microvascular retinal changes was present in the temporal periphery. There was also a dependent, exudative, neurosensory detachment and mild lipid exudation throughout the fundus. (B) Composite fluorescein angiography photograph of the same eye confirmed the presence of vascular changes consistent with Coats' disease. There was capillary non-perfusion, microaneurysm and telangiectasia formation, beading and irregularity of the larger vessel walls. Intraretinal vascular leakage was present throughout the fundus.

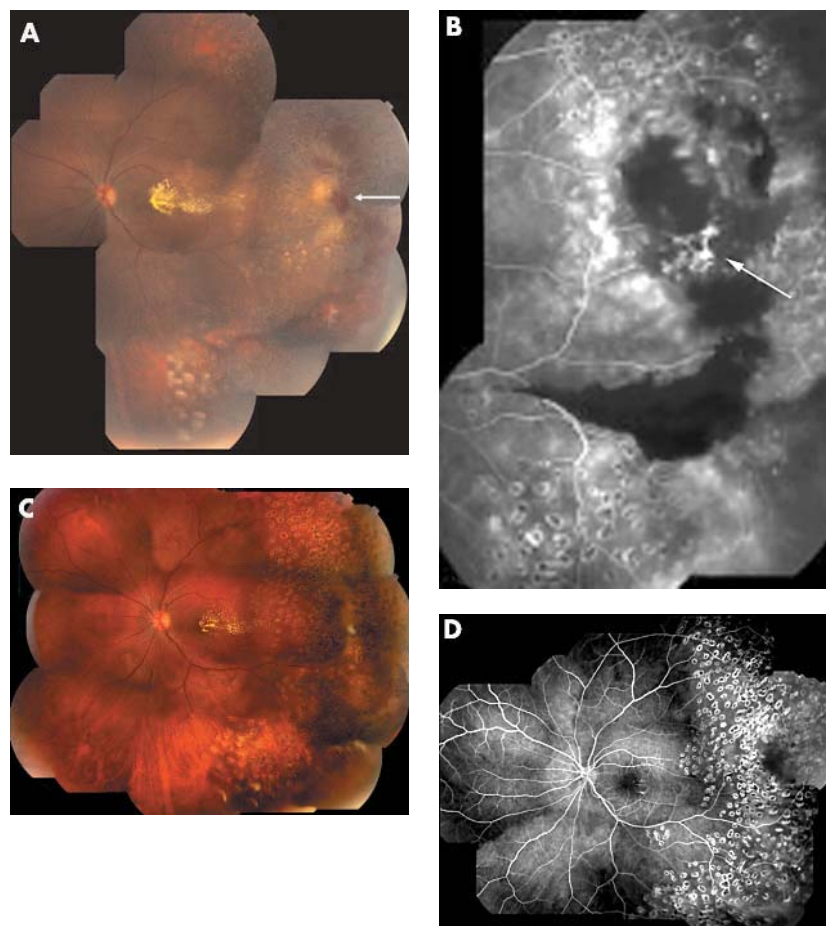


Figure 2 (A) Composite clinical photograph of the same eye 6 months after presentation. There was scatter laser photocoagulation temporally, partial resolution of the serous neurosensory detachment, and more lipid deposition in the macula. There was also new onset of preretinal neovascularisation temporally (arrow) and vitreous haemorrhage. (B) Composite fluorescein angiography photograph at the same time confirmed the presence of preretinal neovascularisation (arrow). (C) Composite clinical photograph of the same eye 1 year after presentation demonstrated total resolution of the exudative neurosensory detachment both in the macula and in the inferior fundus. There was regression of the preretinal neovascularisation and partial resorption of the lipid exudation. (D) Composite fluorescein angiography photograph at the same time confirms the resolution of the preretinal neovascularisation. Note also the disappearance of microvascular retinal changes and intraretinal leakage throughout the fundus.

levels. The development of preretinal neovascularisation in the temporal periphery was also unusual. We thought that it was secondary to retinal ischaemia and not to a break in Bruch's membrane after laser photocoagulation. We also found interesting the fact that the scatter photocoagulation of the temporal periphery resulted in regression of the microvascular telangiectatic changes both in the area that had received laser treatment and in the nasal periphery that had received no treatment. As expected, scatter laser photocoagulation resulted also in reduction of the lipid exudates, similar to what has been described in diabetic retinopathy.³

A P Ciardella

Denver Health Medical Center, University of Colorado, Denver, CO, USA

N Gross, A Angelilli, L Yannuzzi

Manhattan Eye, Ear, and Throat Hospital, New York, NY, USA

Correspondence to: Antonio P Ciardella, MD, Denver Health Medical Center, 777 Bannock Street, Denver, CO 80204, USA; Antonio.ciardella@dhha.org

doi: 10.1136/bjo.2003.038034

Accepted for publication 7 December 2003

References

- 1 Egerer I, Tasman W, Tomer TL. Coats' disease. *Arch Ophthalmol* 1974;**92**:109-12.
- 2 Imre G. Coats' disease and hyperlipemic retinitis. *Am J Ophthalmol* 1967;**64**:726-8.
- 3 Silidor SW, Augsburger JJ, Shields JA, et al. Natural history and management of advanced Coats' disease. *Ophthalmic Surg* 1988;**19**:89-93.
- 4 Shields JA, Shields CL. Review: Coats' disease: the 2001 LuEsther T Mertz lecture. *Retina* 2002;**22**:80-91.
- 5 Early Treatment Diabetic Retinopathy Study Research Group. Photocoagulation for diabetic macular edema, ETDRS Report no 1. *Arch Ophthalmol* 1985;**103**:1796-806.

Churg-Strauss syndrome in a child: retina and optic nerve findings

Allergic granulomatosis and angiitis, also known as Churg-Strauss syndrome (CSS) is

predominantly a disease of adults.¹ Ocular involvement is rare.² We describe a case of CSS in a child that resulted in bilateral optic neuropathy with vasculitis and multiple branch retinal artery occlusions affecting the macula.

Case report

A 10 year old African-American girl developed sudden painless loss of vision in both eyes over 2 days. The child was an inpatient admitted for examination of a multisystem disorder, affecting her pulmonary, gastrointestinal, muscular, and renal systems. On examination the best corrected vision was hand movement in both eyes. Confrontation visual fields were full bilaterally. Pupils were normal, without an afferent papillary defect. Anterior segment examination was completely normal. Posterior segment examination revealed massive retinal opacities in the papillomacular bundle extending into the peripapillary region bilaterally (fig 1). There was pronounced macular oedema and sludging in the venous system. There were extensive scattered intraretinal haemorrhages bilaterally.

Fluorescein angiogram demonstrated bilateral blocking defect caused by retinal opacification and haemorrhages and non-perfusion in the macular region (fig 2). There was also pruning and non-perfusion of both small retinal capillaries and choroidal vessels. The retinal and arterioles venules demonstrated staining and leakage. Both optic discs stained with fluorescein.

The patient had patchy pneumonitis and asthma, hypertension, acute renal failure, elevated liver enzymes, and eosinophilia of 40%. Renal biopsy showed non-specific glomerular inflammation, but no eosinophilic infiltration or granulomata. A magnetic resonance image of the liver showed no

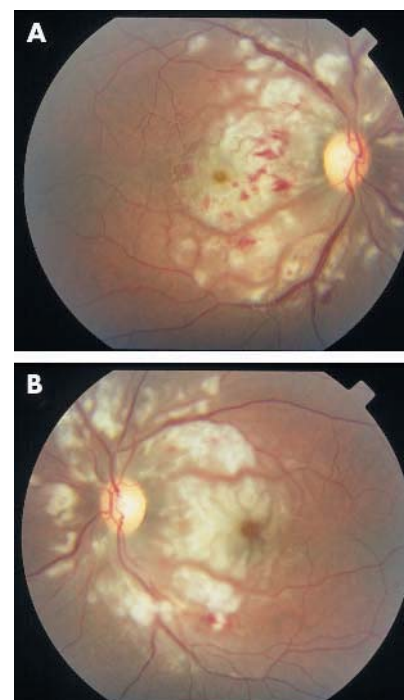


Figure 1 Colour fundus photographs of the right (A) and left (B) eyes, showing retinal opacification and intraretinal haemorrhages in the macular and peripapillary regions.

parenchymal damage. An infectious examination was negative for tuberculosis, Lyme, cat scratch disease, syphilis, HIV, cytomegalovirus, Epstein-Barr virus, toxoplasmosis, or toxocariasis. An oncological examination was negative. ANA, anti-dsDNA, ANCA, complement levels C3, C4, and CH50 were all normal. The diagnosis of Churg-Strauss syndrome was made based on three of six criteria advanced by the American College of Rheumatology,³ which include asthma, hyper eosinophilia of >10%, non-fixed pulmonary infiltrates.

The patient was started on high dose intravenous steroids (2 mg/kg/day) and cyclophosphamide. Intravitreal triamcinolone acetamide injection was performed in the right eye with improvement of macular oedema. However, the vision remained no better than 20/400 in both eyes at 1 month.

Comment

CSS is a systemic granulomatous necrotising vasculitis affecting small to medium-sized vessels. Takanashi *et al*² classified ocular manifestations into two groups: pseudotumour-type and ischaemic vasculitis-type.^{4,5} Pure ischaemic vasculitis-type manifestations were associated with a sudden onset loss of vision, a quiet looking eye, lack of computed tomography (CT) abnormalities, and a positive ANCA.² In contrast, pseudotumour-like manifestations involved a chronic onset, a red eye, orbital abnormalities on CT, and a negative ANCA.¹ Takanashi *et al* advised that

patients with positive ANCA CSS, who are visually asymptomatic, be carefully examined and treated prophylactically with high dose steroids in order to prevent potentially irreversible visual loss from the ischaemic-type ocular manifestations.² The devastating loss of vision in this child with ANCA negative CSS suggests that all patients with CSS should be considered for prophylactic high dose corticosteroids, regardless of their ANCA status.

A Partal, D M Moshfeghi, D Alcorn

Department of Ophthalmology, Stanford University School of Medicine, Stanford, CA, USA

Correspondence to: D M Moshfeghi, MD, Pediatric Vitreoretinal Surgery, Department of Ophthalmology, Stanford University School of Medicine, 1225 Crane Street, Menlo Park, CA 94025, USA; dariusm@stanford.edu

Data accumulation is in conformity with all US federal and state laws and is in adherence to the tenets of the Declaration of Helsinki.

doi: 10.1136/bjo.2003.039859

Accepted for publication 8 December 2003

Financial support: None.

References

- 1 **Watts RA**, Scott DG, Lane SE. Epidemiology of Wegener's granulomatosis, microscopic polyangiitis, and Churg-Strauss syndrome. *Cleve Clin J Med* 2002;**69**(Suppl 2):S1184-6.
- 2 **Takanashi T**, Uchida S, Arita M, *et al*. Orbital inflammatory pseudotumor and ischemic vasculitis in Churg-Strauss syndrome: report of two cases and review of the literature. *Ophthalmology* 2001;**108**:1129-33.
- 3 **Masi AT**, Hunder GG, Lie JT, *et al*. The American College of Rheumatology 1990 criteria for the classification of Churg-Strauss syndrome (allergic granulomatosis and angiitis). *Arthritis Rheum* 1990;**33**:1094-100.
- 4 **Weinstein JM**, Chui H, Lane S, *et al*. Churg-Strauss syndrome (allergic granulomatous angiitis): neuro-ophthalmic manifestations. *Arch Ophthalmol* 1983;**101**:1217-20.
- 5 **Dagi LR**, Currie J. Branch retinal artery occlusion in the Churg-Strauss syndrome. *J Clin Neuroophthalmol* 1985;**5**:229-37.

Metastatic oesophageal carcinoma presenting as a lacrimal gland tumour

A 64 year old man was referred to the Department of Ophthalmology (Southern General Hospital) with 4 month history of painless swelling of the left side of the left orbit. There was no diplopia. His general health appeared reasonably good. Examination showed fullness in the region of the lacrimal gland associated with ecchymosis (fig 1). Visual acuity was 20/20 in each eye. Direct coronal computerised tomography scan of the orbits (fig 2) showed the presence of an extensive ill defined mass lying in the anterior third of the orbit and displacing the globe medially and slightly downwards. The superior and lateral rectus muscles could not be seen separate from the mass anteriorly although they were defined posteriorly. There was no evidence of perineural spread. The radiologist concluded that the appearance is consistent with perilacrimal gland tumour but lymphoma and a secondary tumour should also be considered.

Biopsy of the orbital mass was initially considered to be a poorly differentiated

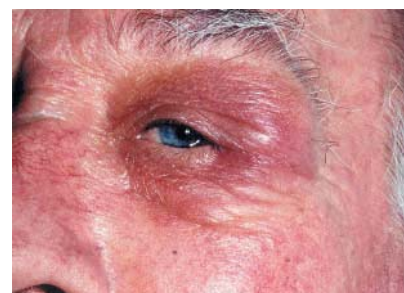


Figure 1 The appearance of the patient at the time of presentation.

adenocarcinoma of the lacrimal gland (reported by Professor W R Lee, Western Infirmary, Glasgow).

On further questioning (systemic review) the patient subsequently volunteered a history of dysphagia. In view of this history, barium meal examination was performed and a 4 cm shouldered stricture with associated mucosal irregularity was identified (fig 3).

An endoscopic biopsy of the oesophageal tumour revealed an infiltrating poorly differentiated squamous cell carcinoma with a histological pattern almost identical to that of the orbital tumour (fig 4, reported by Dr Richard Morton, Southern General Hospital).

In light of this development, the tumour obtained from the orbital biopsy was reviewed and the diagnosis of secondary deposits of a poorly differentiated metastatic squamous cell carcinoma of the oesophagus was made (fig 5, reported by Professor W R Lee, Western Infirmary, Glasgow).

The oesophageal stenosis was dilated and a stent inserted. He was treated with palliative radiotherapy to the oesophagus and the left orbit, but he died 3 months later of generalised metastatic disease.

Comment

At the time of initial examination, there was very little to indicate that the patient had metastatic disease. The most likely diagnosis in this patient therefore was a primary malignant tumour of the lacrimal gland with

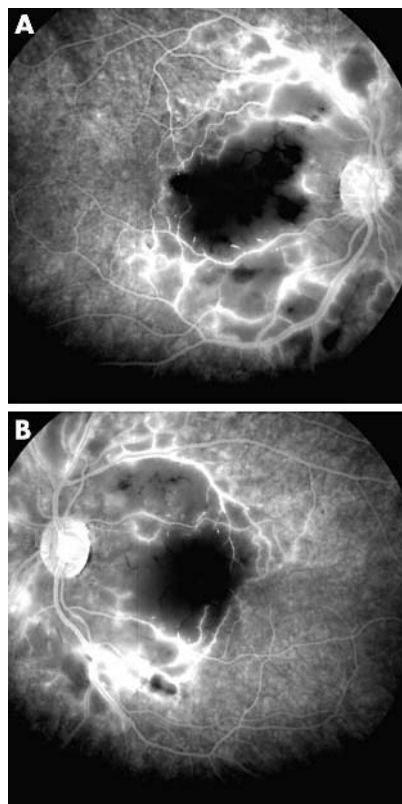


Figure 2 Fluorescein angiogram (recirculation phase) showing extensive macular non-perfusion and blocking defect from retinal opacification and haemorrhage. There is vasculitis-type leakage from the posterior pole retinal vessels (both arteries and veins). Both optic discs stain with fluorescein.

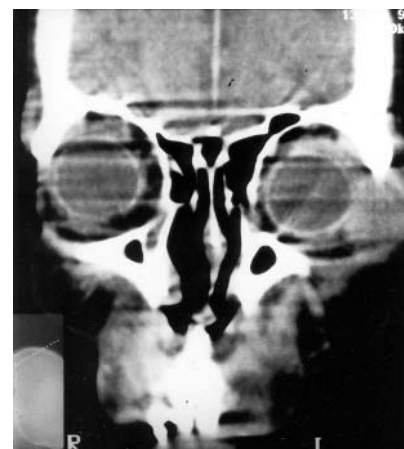

Figure 2 The computed tomography scan shows an irregular tumour mass in the lacrimal fossa and in the superior part of the orbit. Note the erosion of the orbital bone.

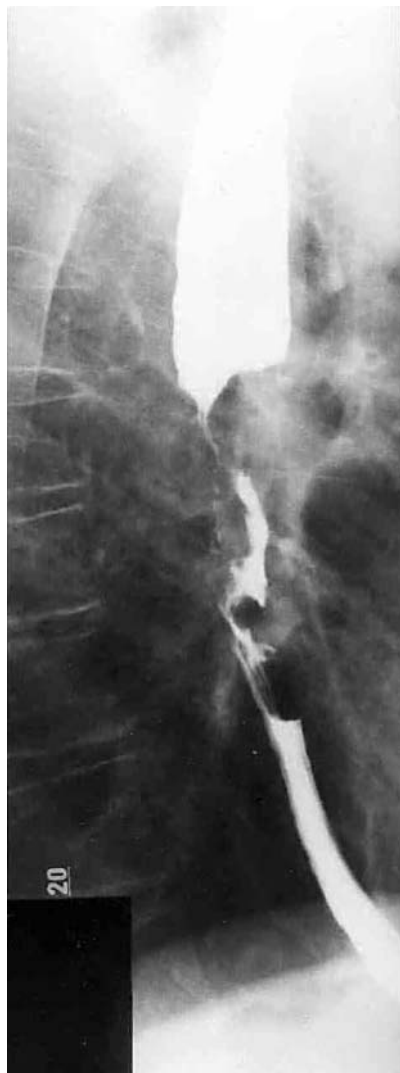

Figure 3 The barium meal reveals an oesophageal stricture.

orbital extension. He was admitted for investigations and treatment

After the findings of the CT scan, it was deemed unlikely that the tumour could be excised. Accordingly the appropriate management was to perform a biopsy initially. This was done 2 weeks following his initial presentation. After the pathological report of a poorly differentiated tumour was made and

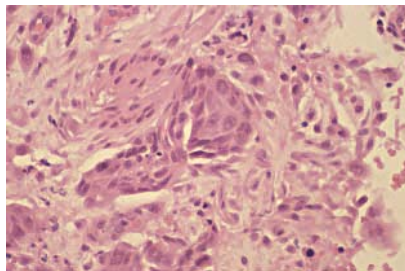


Figure 4 The histological appearance of the squamous carcinoma in the oesophageal biopsy.

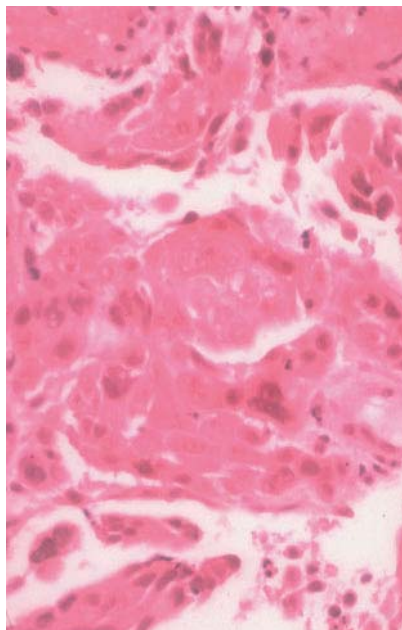


Figure 5 The histological appearance of the poorly differentiated squamous carcinoma within dense fibrous tissue in the orbital biopsy (magnification $\times 400$, haematoxylin and eosin).

the presence of metastasis suspected, the symptoms of dysphagia led to further investigation and demonstration of an oesophageal primary carcinoma. (The oesophageal biopsy was done 10 days after the orbital biopsy).

The most likely neoplasms to metastasise to the orbit include carcinoma of the lung,¹⁻³ breast, and prostate

The orbital tumours may be located anywhere in the orbit but presentation as a lacrimal gland tumour is unusual.

Gastrointestinal carcinoma with metastasis to the orbit represents approximately 6%–7% of reported cases.²⁻⁴ These include carcinoma from stomach, ileum, and colon.

Only one report describes a metastatic oesophageal carcinoma to the intraconal orbit,⁴ but in this case, the clinicians were aware of the oesophageal disease before the occurrence of the orbital tumour.

As far as we know, our case is the first report of a silent carcinoma of the middle third of the oesophagus presenting as a lacrimal gland neoplasm and the case reiterates the importance of careful history taking and thorough preoperative assessment.

O Oworu, P Kyle, R Morton

Southern General Hospital, Glasgow, UK

O Oworu

Huddersfield Royal Infirmary, Huddersfield, UK

Correspondence to: Olugbemisola Oworu, Eye Department, Huddersfield Royal Infirmary, Lindley, Huddersfield HD3 3EA, UK; gbemsol@aol.com

doi: 10.1136/bjo.2003.034322

Accepted for publication 8 December 2003

References

1 **Ferry AP, Font RL.** Carcinoma metastatic to the eye and orbit. I: A clinicopathologic study of 227 cases. *Arch Ophthalmol* 1974;**92**:276–86.

2 **Font RL, Ferry AP.** Carcinoma metastatic to the eye and orbit. III: A clinicopathologic study of 28 cases metastatic to the orbit. *Cancer* 1976;**38**:1326–35.
 3 **Shields CL, Shields JA, Peggs M.** Tumors metastatic to the orbit. *Ophthal Plast Reconstr Surg* 1988;**4**:73–80.
 4 **Collins MJ, Wojno TH, Grossniklaus HE.** Metastatic esophageal carcinoma to the orbit. *Am J Ophthalmol* 1999;**127**:228–9.

Vitreoretinal abnormalities in the Conradi-Hunermann form of chondrodysplasia punctata

Autosomal dominant chondrodysplasia punctata or Conradi-Hunermann disease¹ is a rare disorder with variable expressivity. It is characterised by dysplastic skeletal changes with premature punctate epiphyseal and paravertebral calcification, associated with moderate growth deficiency, scoliosis, limb asymmetry, flexion contractures of the hips, knees and elbows, talipes equinovarus, short neck, frontal bossing, nasal bone hypoplasia with characteristic “koala” facies and dystrophic changes in hair and skin.^{2,3} Among the ocular features reported, cataracts are by far the most common, occurring in about 20% of cases of Conradi-Hunermann disease compared with a much higher incidence (>66%) in the more severe (and usually lethal) autosomal recessive and X linked dominant forms the disease.^{2,4,5} In addition, optic atrophy, microphthalmos, iris hypoplasia, and Axenfeld-Rieger syndrome have been described.^{6,7}

Case report

We describe unusual vitreoretinal abnormalities in a 28 year old woman with Conradi-Hunermann disease. Her original diagnosis had been made in childhood based on clinical and radiological grounds, and she had undergone numerous cosmetic and reconstructive procedures on her nose, jaw, and lower limbs, as well as right cataract surgery at the age of 18 years for cortical lens opacity. Refraction showed low hyperopia and her left eye, also affected by cataract, had been considered amblyopic. She presented to us with a short history of photopsia and floaters in the left eye, but with no change to her corrected Snellen visual acuities of 6/12 right and 6/36 left.

Anterior segment examination revealed lower lid distichiasis and quiet pseudophakia on the right, and peripheral cortical lens opacities and a small pupil on the left. Her intraocular pressures were normal. Funduscopy showed healthy discs and maculae, with temporal dragging of vessels on the right (as had been noted many years previously). No posterior vitreous detachment was evident in either eye, but a number of unusual vitreoretinal tractional complexes were present, more marked on the left, with underlying retinal pigment epithelium disturbance (fig 1). The fundal view on the left was impaired by the cortical cataract and small pupil.

Strands of condensed vitreous emanated from each complex, pulling partial and full thickness operculae. The right eye showed flatter complexes, which appeared more stable, with less traction. In the left eye the precise nature of some of the tractional complexes was difficult to ascertain because of the cortical cataract and small pupil: it was uncertain whether they represented tractional schisis or full thickness combined tractional and rhegmatogenous lesions. A

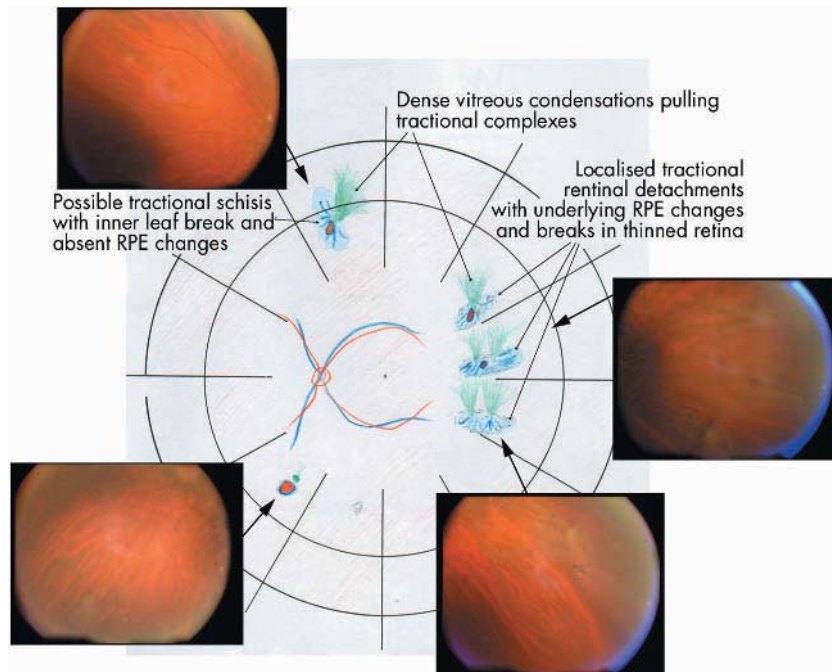


Figure 1 Vitreoretinal abnormalities in chondrodysplasia punctata. Retinal drawing with photographic insets of the left fundus, illustrating the nature and distribution of the vitreoretinal tractional complexes described. Vitreous condensations emanating from each complex can be seen, but the partial and full thickness operculae are difficult to appreciate in the photographs because of cortical cataract and small pupil. The right fundus is not shown here but had similar lesions, only less florid.

group of three such lesions was located just temporal to the macula in the left eye.

Given the unstable appearance and symptomatic nature of the left eye, the tractional lesions associated with retinal breaks were treated by argon laser retinopexy. One of the three temporal tractional complexes was untreatable with laser because of the cortical lens opacity.

Two weeks later the patient noticed a nasal visual field disturbance associated with photopsia in the left eye. She had developed a partial posterior vitreous detachment with a temporal rhegmatogenous retinal detachment transecting the macula, secondary to breaks associated with the temporal tractional complexes.

She subsequently underwent left phacemulsification, intraocular lens implantation, pars plana vitrectomy, encirclement, endolaser, cryotherapy, and C₃F₈ gas injection. During the surgery the condensed vitreous was found to be very adherent to the tractional complexes; multiple retinal breaks opened up within the complexes and also in a few areas of apparently "normal" retina. Postoperatively the retina was flat, but she developed raised intraocular pressure associated with a fibrinous anterior uveitis and iris bombé—this settled with topical therapy and Nd:YAG laser peripheral iridotomy. Six weeks later an inferotemporal redetachment secondary to proliferative vitreoretinopathy occurred. This was treated successfully by membrane peel, endolaser, and gas tamponade. Her retina has remained flat since, with a Snellen visual acuity of 6/36 in this left amblyopic eye.

Comment

We describe previously unreported vitreoretinal abnormalities in a patient with

Conradi-Hunermann disease. The pathogenesis of these lesions is not understood, but it may not be surprising that yet another skeletal dysplasia is associated with vitreoretinal changes.⁸ Identification of the underlying genetic defect in this particular variant of chondrodysplasia punctata may provide insight into the development of both bone and vitreous. We hope that better reporting of vitreoretinal features in Conradi-Hunermann syndrome will help improve understanding and management of this condition.

Y D Ramkissoon, E J Mayer, C Gibbon, R J Haynes
Bristol Eye Hospital, Lower Maudlin Street, Bristol BS1 2LX, UK

Correspondence to: Mr R J Haynes, Bristol Eye Hospital, Lower Maudlin Street, Bristol BS1 2LX, UK; Richard.Haynes@ubht.swest.nhs.uk

doi: 10.1136/bjo.2003.038638

Accepted for publication 8 December 2003

References

- 1 **Online Mendelian Inheritance in Man, OMIM (TM)**. Baltimore, MD: Johns Hopkins University (MIM Number *118650) [date last edited 30 June 2003] (www.ncbi.nlm.nih.gov/omim/).
- 2 **Spranger JW, Opitz JM, Bidder U**. Heterogeneity of chondrodysplasia punctata. *Humangenetik* 1971;11:190–212.
- 3 **Sheffield LJ, Danks DM, Mayne V, et al**. Chondrodysplasia punctata: 23 cases of a mild and relatively common variety. *J Pediatr* 1976;89:916–23.
- 4 **Silengo MC, Luzzatti L, Silverman FN**. Clinical and genetic aspects of Conradi-Hunermann disease. A report of three familial cases and review of the literature. *J Pediatr* 1980;97:911–17.

- 5 **Happle R**. Cataracts as a marker of genetic heterogeneity in chondrodysplasia punctata. *Clin Genet* 1981;19:64–6.
- 6 **Massey FY, Roy JH**. Ocular manifestations of Conradi disease. *Arch Ophthalmol* 1974;92:524–6.
- 7 **Tanaka Y, Saitoh A, Taniguchi H, et al**. Conradi-Hunermann syndrome with ocular abnormalities. *Ophthalmic Genet* 1999;20:271–4.
- 8 **Richards AJ, Scott JD, Snead M**. Molecular genetics of rhegmatogenous retinal detachment. *Eye* 2002;16:388–92.

“Imploding antrum” or silent sinus syndrome following naso-tracheal intubation

Silent sinus syndrome is a condition in which chronic asymptomatic maxillary sinus disease presents with spontaneous unilateral enophthalmos and hypoglobus.¹ Patients have inferior displacement of the orbit due to a downward bowing of the orbital floor and atelectasis of the maxillary antrum. Although the underlying maxillary sinus pathology is “silent” it has been suggested recently that “imploding antrum” more closely describes the acute nature of maxillary sinus collapse that occurs in the majority of cases.² We present a typical case that appears to have been related to previous nasotracheal intubation.

Case report

A 27 year old woman was referred to ophthalmology outpatients complaining that her left eye was lower than the right and that when she looked down, she could see more of her left cheek than on the other side. She had started to notice this following an admission to hospital 6 months previously with viral meningitis. Since then, she had also experienced a “heavy blocked” feeling in the left side of her face together with some left nasal congestion. There was no history of acute sinusitis or chronic rhinosinusitis and, in particular, no history of trauma or surgery to the face—although she had had a nasotracheal intubation for a routine general anaesthetic 1 year earlier.

On examination, she had normal visual acuity and extraocular movements, but was found to have 2 mm of enophthalmos and 2 mm of hypoglobus. On subsequent review in the ENT clinic, nasendoscopy revealed a left deviated nasal septum with obstruction

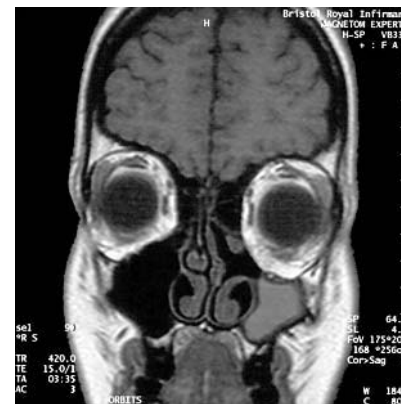

Figure 1 Coronal magnetic resonance image showing opacification and marked reduction in volume of the left maxillary sinus.

of the middle meatus, while the middle turbinate could not be visualised.

Magnetic resonance imaging clearly showed depression of the left orbit with thinning of the orbital floor and a marked reduction in maxillary sinus volume (fig 1). The maxillary antrum was opacified and the middle turbinate severely lateralised. The ethmoid, frontal, and sphenoid sinuses were clear.

She underwent septoplasty and functional endoscopic sinus surgery (FESS) during which a left middle meatal anastomy was performed. Biopsies from the antrum demonstrated polypoid fibrinous and mucoid material with no viable cellular tissue. Bacterial and fungal cultures were negative.

At follow up she had reduced hypoglobus of the left eye, an improvement in the left nasal airway and resolution of facial pressure. Orbital floor reconstruction was not required.

Comment

Silent sinus syndrome generally occurs in the third to fifth decade, shows equal sex distribution, and presents with anything from 2–12 months history of enophthalmos. Other symptoms can include transient vertical diplopia, upper lid retraction, lagophthalmos, malar depression, and facial pressure.³ By definition, there is no history of acute or chronic sinusitis and no previous facial surgery or trauma.¹ The amount of enophthalmos varies from 2–5 mm¹ and visual acuity and extraocular movements are usually normal.⁴

Much speculation exists about the cause of silent sinus syndrome. The most popular theory of pathogenesis is that ostiomeatal obstruction results in reduced aeration of the antrum, causing negative sinus pressure and atelectasis.^{1–6} In the most recent review, Rose *et al* found that, as well as the orbital floor being drawn downwards, there was abnormal concavities in the medial and posterolateral walls of all the maxilla that could be assessed on CT scanning.² They also describe an iatrogenic version of the disease occurring after orbital decompression.⁷ These relatively acute changes have led them to use the term “implosion antrum syndrome.”^{7,2}

It is possible in our case that the patient’s previous nasotracheal intubation caused sufficient local damage as to occlude the ostiomeatal complex and create the conditions necessary for development of the syndrome. This supports the hypoventilation theory and also highlights the importance of careful history taking in establishing risk factors for this increasingly recognised condition.

C G L Hobbs, M W Saunders

Department of Otolaryngology/Head and Neck Surgery, St Michael’s Hospital, Bristol, UK

M J Potts

Department of Ophthalmology, Bristol Eye Hospital, Bristol, UK

Correspondence to: Mr C G L Hobbs, Department of Otolaryngology/Head and Neck Surgery, St Michael’s Hospital, Southwell Street, Bristol BS2 8EG, UK; chris.hobbs@bristol.ac.uk

doi: 10.1136/bjo.2003.035386

Accepted for publication 10 December 2003

References

1 Soparkar CN, Patrinely JR, Cuaycong MJ, *et al*. The silent sinus syndrome. A cause of

spontaneous enophthalmos. *Ophthalmology* 1994;**101**:772–8.
 2 Rose GE, Sandy C, Hallberg L, *et al*. Clinical and radiologic characteristics of the imploding antrum, or “silent sinus,” syndrome. *Ophthalmology* 2003;**110**:811–18.
 3 Wan MK, Francis IC, Carter PR, *et al*. The spectrum of presentation of silent sinus syndrome. *J Neuro-ophthalmol* 2000;**20**:207–12.
 4 Gillman GS, Schaitkin BM, May M. Asymptomatic enophthalmos: the silent sinus syndrome. *Am J Rhinol* 1999;**13**:459–62.
 5 Davidson JK, Soparkar CN, Williams JB, *et al*. Negative sinus pressure and normal predispose imaging in silent sinus syndrome. *Arch Ophthalmol* 1999;**117**:1653–4.
 6 Kass ES, Salman S, Rubin PA, *et al*. Chronic maxillary atelectasis. *Ann Otol Rhinol Laryngol* 1997;**106**:109–16.
 7 Rose GE, Lund VJ. Clinical features and treatment of late enophthalmos after orbital decompression: a condition suggesting cause for idiopathic “implosion antrum” (silent sinus) syndrome. *Ophthalmology* 2003;**110**:819–26.

No association of p53 codon 72 and p21 codon 31 polymorphisms in Taiwan Chinese patients with pterygium

After abnormal expression of the p53 gene being found in epithelium, pterygium is now considered to be a result of uncontrolled cell proliferation, like a tumour.^{1 2}

The p53 gene is a tumour suppressor gene, whose function is mediated by stimulation of p21 (Waf-1) gene, another tumour suppressor gene, to control cell cycle and prevent tumour formation.³ Mutations in either p53 or p21 are detected in many tumour cells,^{3 4} and polymorphisms of p53 codon 72 or p21 codon 31 were found to be associated with many tumours.^{5 6}

Because of the abnormal expression of the p53 gene in pterygium epithelium^{1 2} and there is evidence that hereditary factors may have a role in the development of pterygium,^{7 8} it is logical to suspect the correlation between pterygium formation and p53 and p21 polymorphisms.

In this study, p53 codon 72 and p21 codon 31 polymorphisms were evaluated in order to understand whether these two polymorphisms are associated with increased susceptibility for pterygium.

Patients and methods

A total of 128 pterygium patients (71 men and 57 women) were enrolled in the study with ages ranging from 35 to 90 years (mean 64.6 years). One hundred and three volunteers aged 55 years or more without pterygium were enrolled as the control group. There were 64 men and 39 women in the

control group (age range from 50 to 83 years with an average of 64.2 years).

The genomic DNA was prepared from peripheral blood. For p53, the primer Pro 72 was designed for p53 codon 72 in proline form and Arg 72 for arginine form, according to the procedure described by Storey *et al*.⁵ For p21, the primer for codon 31 was designed from codon 1 start (5’-GTCAGAACC GGCTGGGGATG-3’) to codon 91 (5’-CTCCT CCAACTCATCCC GG-3’), according to the procedure described by Li *et al*.⁶ The PCR products from the same individual were mixed together and 10 µl of this solution were loaded into 3% agarose gel containing ethidium bromide for electrophoresis.

Results

There were no significant differences between both groups in age and sex.

The frequency of the genotype of p53 codon 72 and p21 codon 31 polymorphisms in the pterygium group and control group is shown in table 1. There were no significant differences between both groups.

The frequency of the alleles for the p53 codon 72 and p21 codon 31 between pterygium and control groups was not statistically different (table 2).

Analysis of combination p53 codon 72 and p21 codon 31 polymorphisms, there was also no significant difference between both groups (table 3).

Comment

Weinstein *et al* suggest the cause of p53 mutation in pterygium may be ultraviolet radiation or be hereditary.² Detorakis *et al* proposed a “two hit” model for DNA abnormalities in pterygium.⁹ The first hit could be either inherited or incurred by ultraviolet radiation, and the second hit could be caused either by solar light or by viral infection. Though the hereditary factor was proposed to have a role in pterygium formation, there were few studies to clarify this proposition. In this study, we try to investigate the hereditary factor of pterygium by single nucleotide polymorphism (SNP) marker. Single nucleotide polymorphisms are the most abundant types of DNA sequence variation in the human genome, and the SNP marker has provided a new method for identification of complex gene associated diseases such as tumour.¹⁰

The p53 codon 72 and p21 codon 31 polymorphisms are two of the most important SNP markers for tumour susceptibility. However, there are no significant differences between the pterygium and control group in our study. We suggest the p53 codon 72 and p21 codon 31 polymorphisms maybe cannot

Table 1 Distribution of p53 codon 72 and p21 codon 31 polymorphisms in the pterygium and control group

Genotype	Pterygium (n = 128) (%)	Control (n = 103) (%)	p Value
p53			0.65
GG	42(32.8)	32(31.1)	
GC	60(46.9)	54(52.4)	
CC	26(20.3)	17(16.5)	
p21			0.50
AA	24 (18.8)	14 (13.6)	
AC	76 (59.4)	68 (66.0)	
CC	28 (21.9)	21 (20.4)	

Table 2 Allelic frequencies for p53 codon 72 and p21 codon 31 polymorphisms in the pterygium and control group

Allele	Pterygium (n = 128) (%)	Control (n = 103) (%)	p Value
p53			0.82
Allele G (arginine)	144 (56.3)	118 (57.3)	
Allele C (proline)	112 (43.8)	88 (42.7)	
p21			0.69
Allele A (arginine)	124 (48.4)	96 (46.6%)	
Allele C (serine)	132 (51.6)	110 (53.4%)	

Table 3 Distribution of combination p53 codon 72 and p21 codon 31 polymorphisms in the pterygium and control group

Genotype	Pterygium (n = 128) (%)	Control (n = 103) (%)	p Value
p53/p21			0.84
GG/AA	9 (7.0)	3 (2.9)	
GG/AC	29 (22.7)	25 (24.3)	
GG/CC	4 (3.1)	4 (3.9)	
GC/AA	10 (7.8)	9 (8.7)	
GC/AC	31 (24.2)	32 (31.1)	
GC/CC	19 (14.8)	13 (12.6)	
CC/AA	5 (3.9)	2 (1.9)	
CC/AC	16 (12.5)	11 (10.7)	
CC/CC	5 (3.9)	4 (3.9)	

become useful genetic markers for pterygium susceptibility. This could be the basis of future surveys.

Y Y Tsai

Department of Ophthalmology, China Medical University Hospital, Taichung, Taiwan

Y Y Tsai, Y W Cheng

Institute of Medicine, Chung Shan Medical University, Taichung, Taiwan

H Lee

Institute of Toxicology, Chung Shan Medical University, Taichung, Taiwan

S H Tseng

Department of Ophthalmology, National Cheng Kung University Hospital, Tainan, Taiwan

C H Tsai

Taichung Healthcare and Management University, Taichung, Taiwan

F J Tsai

College of Chinese Medicine, China Medical University, Taichung, Taiwan

Correspondence to: F J Tsai, MD, PhD, College of Chinese Medicine, China Medical University, No 2, Yue Der Road, Taichung, Taiwan; d0704@www.cmu.edu.tw

doi: 10.1136/bjo.2003.040428

Accepted for publication 15 December 2003

The authors have no proprietary or financial interest in any material or device mentioned.

References

- Tam DT**, Lim AS, Goh HS, *et al*. Abnormal expression of the p53 tumor suppressor gene in the conjunctiva of patients with pterygium. *Am J Ophthalmol* 1997;**123**:404–5.
- Weinstein O**, Rosenthal G, Zirkin H, *et al*. Overexpression of p53 tumor suppressor gene in pterygia. *Eye* 2002;**16**:619–21.

- Greenblatt MS**, Bennett WP, Hollstein M, *et al*. Mutation in the p53 tumor suppressor gene: clues to cancer etiology and molecular pathogenesis. *Cancer Res* 1994;**54**:4855–78.
- Hollstein M**, Rice K, Greenblatt MS, *et al*. Database of p53 gene somatic mutations in human tumors and cell lines. *Nucleic Acids Res* 1994;**22**:3551–5.
- Storey A**, Thomas M, Kalita A, *et al*. Role of a p53 polymorphism in the development of human papilloma virus-associated cancer. *Nature* 1998;**393**:229–34.
- Li YJ**, Laurent-Puig P, Salmon RJ, *et al*. Polymorphisms and probable lack of mutation in the WAF1-CIP1 gene in colorectal cancer. *Oncogene* 1995;**10**:599–601.
- Zhang JD**. An investigation of aetiology and heredity of pterygium. Report of 11 cases in a family. *Acta Ophthalmol* 1987;**65**:413–16.
- Hilgers JHCh**. Pterygium: its incidence, heredity and etiology. *Am J Ophthalmol* 1960;**63**:5–44.
- Detorakis ET**, Drakonaki EE, Spandidos DA. Molecular genetic alterations and viral presence in ophthalmic pterygium (Review). *Int J Mol Med* 2000;**6**:35–41.
- Kwok PY**, Gu Z. Single nucleotide polymorphism libraries: why and how are we building them? *Mol Med Today* 1999;**5**:538–43.

BOOK REVIEWS

The Ophthalmology Examinations Review

By TienYin Wong. Pp 448; \$84. Singapore: World Scientific Publishing, 2001. ISBN 9810243995.

Preparing for postgraduate examinations is now a nearly universal event for ophthalmologists in training. In many countries it will become a part of a practising ophthalmologist's professional life as well. Preparation

books for these types of examination are increasingly being published. Dr Tien Yin Wong has written a book to prepare ophthalmologists for postgraduate examinations. Granted this book is addressed primarily to those who take the British style examinations but it could be easily used by trainees in countries where exams are slightly different. This book is organised in a clear fashion with specific topics being outlined in a bullet point fashion. Important information is highlighted in bold print and the table of contents and index are both well organised and detailed enough that information can be found quickly and almost flawlessly. The topics covered include all of the classic subspecialty areas of ophthalmology and some additional miscellaneous areas including lasers in ophthalmology and epidemiology, public health, and research methods. The author also attempts to prioritise examination material with a system of stars that are meant to rate the likelihood that the material under review is commonly used in testing circumstances. This prioritisation attempt is perhaps the least successful part of the book. Overall, however, Dr Wong includes an enormous amount of information in just over 400 pages, and has done so in an attractive way. The book is easy to read with outline forms and lots of highlighted information in box or table presentations. While there has been an obvious attempt to make this book concise and to the point this reader still finds it slightly unnerving that no references are included. However, this is a book that is meant to prepare one for tests and not to provide detailed reference information. It easily and successfully fulfils this role.

C S Hoyt

University of California, San Francisco, CA, USA; dfrase@mcn.org

How to Write a Paper. 3rd ed.

Ed George M Hall. Pp 175; £16.95. London: BMJ Books, 2003. ISBN 0727917285.

This multiauthored book is a must for both aspiring authors and those who think they can already write. The book is very easy to read, informative, and amusing. Why all should read it is because it informs of the processes involved in publication, the role of editors and assessors and, of course, publishers; thus, the book increases the understanding of what happens behind the scenes. Other chapters are equally important, presenting a common theme—how to captivate the reader. The book assists in helping authors write abstracts, introductions, best ways to present results, and how to generate informative discussion. In all chapters the approach emphasises brevity and how to get the audience interested from the very beginning. There is even a chapter on titles! Remember, as the book also says, most readers do not read the whole paper, if you are lucky they may read just the title. If you want your work to be read make it short and interesting from the very beginning. This book will help authors achieve their desired result.

A D Dick

University of Bristol, Bristol BS1 2LX, UK; adick@bristol.ac.uk

Pediatric ophthalmology and strabismus. 2nd ed

Eds K W Wright, P H Spiegel. Pp 1084; £174.50. Berlin: Springer, 2003. 0-387-95478-3.

Paediatric ophthalmology is a large and developing subject and a new comprehensive, up to date text is much to be welcomed. In this revised edition of a major textbook, the editors and contributing authors have made great efforts to include many recent and important pieces of research. Despite this, there is a very practical flavour to most of the chapters; a nice touch is the inclusion of several practically useful tables (guidelines for planning strabismus surgery) and graphs of normal adnexal dimensions just within the covers.

Three new chapters were added since the first edition; "Visual electrophysiology in children," "Strabismus surgery," and "Ocular disorders with systemic manifestations." The first is a masterly and highly readable summary of the usefulness of electrophysiology in children and is a fitting tribute to one of the authors, Dr Tony Kriss, who sadly died soon after its completion. The chapter on strabismus surgery by Kenneth Wright contains elegant descriptions, beautifully illustrated, of a range of surgical techniques used in strabismus surgery. Finally, there is a unique account by Dr Maya Eibschitz-Tsimhoni, of the ocular manifestations of inherited disease. She includes a glossary of terms used to describe dysmorphic features, an alphabetical thesaurus of syndromes with prominent ocular features and their many alternative names and a clear description of the general and ocular findings in each, together with the genetic locus where known, or inheritance pattern. Generally, the neuro-ophthalmological and systemic or developmental problems are dealt with particularly well, but all of the chapters are comprehensive and well illustrated with clinical pictures and clear diagrams where appropriate.

I have rarely enjoyed reading a textbook as much as this one. My only complaint is of its bulk and the fact that apparently there is no CD version. This textbook is certainly useful enough for one to take it to clinics regularly but it is difficult to do this if attending outreach clinics, especially if carrying a laptop computer, an indirect ophthalmoscope, and a retinoscope as well. I would therefore warmly recommend this book to all ophthalmologists who see children but I would also beseech the publishers to think about a more portable medium for this potentially extremely useful text.

C Williams

Bristol, UK; cathy.williams@bris.ac.uk

NOTICES

Low vision care

The latest issue of *Community Eye Health* (No 49) deals with the problems and management of low vision. For further information

please contact: Journal of Community Eye Health, International Resource Centre, International Centre for Eye Health, Department of Infectious and Tropical Diseases, London School of Hygiene and Tropical Medicine, Keppel Street, London WC1E 7HT, UK (tel: +44 (0)20 7612 7964; email: Anita.Shah@lshtm.ac.uk; online edition: www.jceh.co.uk). Annual subscription (4 issues) UK £28/US\$45. Free to developing country applicants.

Elimination of avoidable blindness

The 56th World Health Assembly (WHA) considered the report on the elimination of avoidable blindness (doc A56/26) and urged Member States to: (1) Commit themselves to supporting the Global Initiative for the Elimination of Avoidable Blindness by setting up a national Vision 2020 plan by 2005; (2) Establish a national coordinating committee for Vision 2020, or a national blindness prevention committee to help implement the plan; (3) Implement the plan by 2007; (4) Include effective monitoring and evaluation of the plan with the aim of showing a reduction in the magnitude of avoidable blindness by 2010; (5) To support the mobilisation of resources for eliminating avoidable blindness. The WHA also urged the Director-General to maintain and strengthen WHO's collaboration with Member States and the partners of the Global Initiative for the Elimination of Avoidable Blindness as well as aid in the coordination and support of national capability.

XVth Meeting of the International Neuro-Ophthalmology Society

The XVth Meeting of the International Neuro-Ophthalmology Society will take place 18-22 July 2004, in Geneva, Switzerland. Further details: Prof. A Safran, University Hospital Geneva, c/o SYMPORG SA, Geneva (fax: +4122 839 8484; email: info@symporg.ch; website: www.symporg.ch).

4th International Congress on Autoimmunity

The 4th International Congress on Autoimmunity will take place 3-7 November 2004 in Budapest, Hungary. The deadline for the receipt of abstracts is 20 June 2004. Further details: Kenes International Global Congress Organisers and Association Management Services, 17 Rue du Cendrier, PO Box 1726, CH-1211 Geneva I, Switzerland (tel: +41 22 908 0488; fax: +41 22 732 2850; email: autoim04@kenes.com; website: www.kenes.com/autoim2004).

XVI International Congress for Eye Research

The XVI International Congress for Eye Research will be held on 29 August-3 September 2004 in Sydney, Australia. For further information, please contact: icer2004@tourhosts.com.au (website: www.tourhosts.com.au/icer2004).

Optometry giving sight launches new website

Optometry Giving Sight (OGS) is delighted to announce the launch of its official website www.givingsight.org which will go live on Friday 21 May 2004. Further to VISION 2020's recent announcement that HRH The Countess of Wessex will be showing her support for the ground-breaking campaign OGS at a luncheon she will be attending at the Mansion House on Monday 17 May, the launch of the website is another step forward in the progress of this exciting new project.

OGS is a unique collaboration of the International Agency for the Prevention of Blindness (IAPB), World Optometry Foundation (WOF) and the International Centre for Eyecare Education (ICEE). The purpose of the OGS project is to generate new income primarily from the Optometrists, Optical Dispensers, Optometric Practices, Opticians and optical outlets throughout the world, for the purposes of VISION 2020: The Right to Sight, including the delivery of eye and vision care; the development of human resources; and the improvement of infrastructure needed to improve eye care services around the world. Attached is the web launch press release, OGS poster and a photograph with caption. For further information, please contact: Isabel Gander (tel: +44 7879 424 400; e-mail: igander@v2020.org; website: www.givingsight.org) and for further information on 'VISION 2020: The Right to Sight' please visit www.v2020.org.

CORRECTION

In the letter by Shortt *et al* (*Br J Ophthalmol* 2003;**87**:1302), the image presented in fig 3 was the incorrect figure. The correct figure is shown below. The journal apologises for the error.

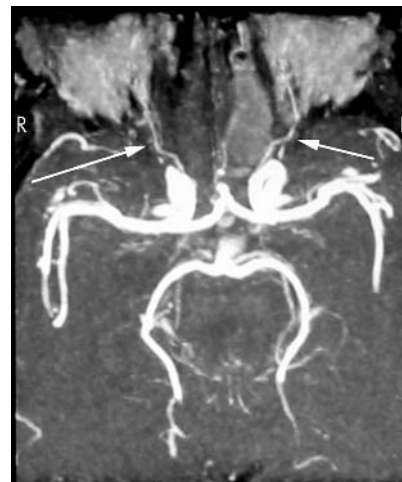

Figure 3 Postoperative MRA. Normal blood flow is present in both ophthalmic arteries (arrows).



Churg-Strauss syndrome in a child: retina and optic nerve findings

A Partal, D M Moshfeghi and D Alcorn

Br J Ophthalmol 2004 88: 971-972
doi: 10.1136/bjo.2003.039859

Updated information and services can be found at:
<http://bjo.bmj.com/content/88/7/971.full.html>

References

These include:

This article cites 5 articles, 1 of which can be accessed free at:
<http://bjo.bmj.com/content/88/7/971.full.html#ref-list-1>

Article cited in:
<http://bjo.bmj.com/content/88/7/971.full.html#related-urls>

Email alerting service

Receive free email alerts when new articles cite this article. Sign up in the box at the top right corner of the online article.

Notes

To request permissions go to:
<http://group.bmj.com/group/rights-licensing/permissions>

To order reprints go to:
<http://journals.bmj.com/cgi/reprintform>

To subscribe to BMJ go to:
<http://group.bmj.com/subscribe/>