

## SCIENTIFIC REPORT

## Penetrating keratoplasty: indications over a 10 year period

N Al-Yousuf, I Mavrikakis, E Mavrikakis, S M Daya

*Br J Ophthalmol* 2004;88:998–1001. doi: 10.1136/bjo.2003.031948

**Aims:** To determine the indications for penetrating keratoplasty (PK) at the Corneoplastic Unit and Eye Bank, UK, a tertiary referral centre, over a 10 year period.

**Methods:** Records of all patients who underwent PK at our institution between 1990 and 1999 were reviewed retrospectively. Of the 1096 procedures performed in this period, 784 records were available for evaluation (72%).

**Results:** Re-grafting was the most common indication, accounting for 40.9% of all cases. Keratoconus was the second most common indication (15%), followed by Fuchs' endothelial dystrophy (9.3%), pseudophakic bullous keratopathy (7.6%), and viral keratitis (5.9%), which included both herpes simplex and herpes zoster and showed a statistically significant decreasing trend using regression analysis ( $p < 0.005$ ). Among the re-graft subgroup, viral keratitis accounted for 21.2% as the underlying primary diagnosis. The most common cause for graft failure in the re-graft subgroup was endothelial failure (41.8%).

**Conclusion:** Re-grafting is the leading indication for PK; viral disease—although declining—is the leading primary diagnosis.

Penetrating keratoplasty (PK) is the most common tissue transplant performed in Europe and the United States.

Advances in the medical management of certain diagnoses and the adoption of a conservative approach have changed patterns in the indications of PK. Moreover, the decline of certain disorders due to changes in surgical practice, and the emergence of new surgical techniques have largely influenced the changing trend. The indications for PK have continued to change since 1940,<sup>1–3</sup> and investigators have studied the changing trends over the past few decades.<sup>1–19</sup> To update these trends we report the indications for PK from 1990 to 1999, and compare these with indications during an earlier time period at the same institution<sup>4</sup> and to those of other series.

## PATIENTS AND METHODS

A retrospective analysis of records of all cases of PK performed between January 1990 and December 1999 was undertaken. All cases were performed at the Corneoplastic Unit and Eye Bank, UK, a tertiary referral centre for corneal and anterior segment disorders. Of the 1097 PKs performed in this period, only 784 medical records were available for review. Records were not accessible or had been destroyed as patients had not been followed up—either because they lived abroad, transferred to another institution, or had died. Although the indications for PK for the remaining 313 cases could be retrieved from the booking register, we elected not to include these as there was little correlation between the data recorded in the operative note and the register. Information obtained was analysed with respect to age, sex, eye grafted, and preoperative clinical diagnosis. The indications for PK were divided into seven diagnostic categories

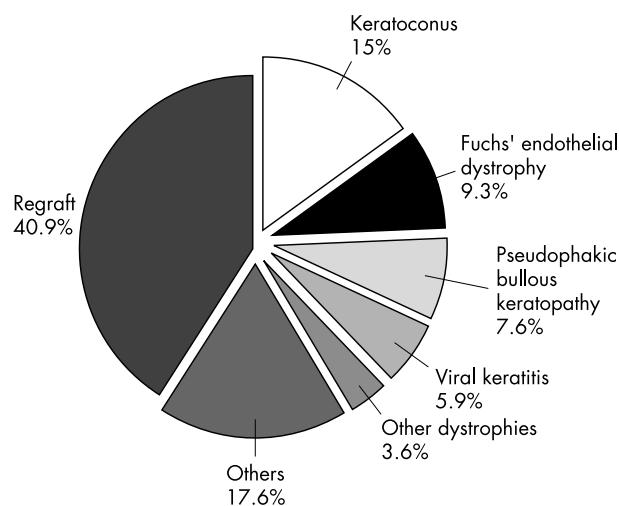
(fig 1). Re-grafts were further analysed for the aetiology of failure of the previous graft and original diagnosis.

Statistical significance was determined using  $\chi^2$  analysis. A combination of linear regression and *t* test were used to establish linear trends and to determine the statistical significance of the trend.

## RESULTS

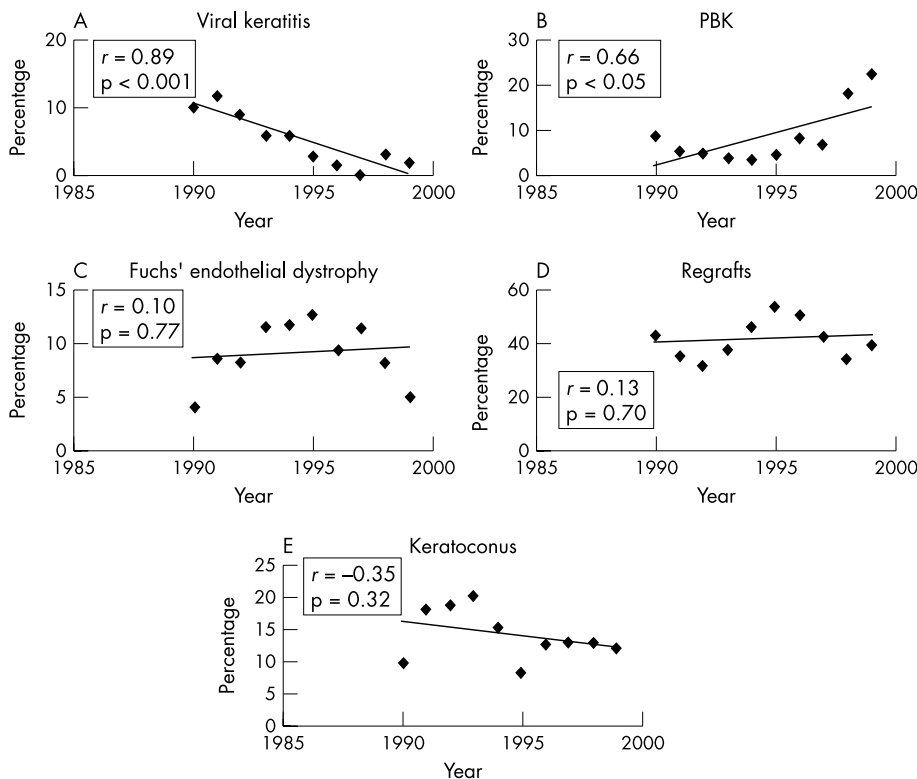
Of the 784 cases performed, 714 (91%) had the graft performed for visual reasons. Sixty five (8.3%) were for therapeutic reasons such as unresponsive infection ( $n = 13$ , 1.7%), threatened perforation ( $n = 9$ , 1.1%), and actual perforation ( $n = 43$ , 5.5%). Only five cases (0.6%) were performed for cosmetic reasons. Of 13 eyes which had a PK for infection, seven cases were bacterial, one *Acanthamoeba*, and in the five remaining cases the infectious agent was unknown.

The mean patient age was 54.21 years with a standard deviation (SD) of 21.46 and a median of 56.5 years. The mean ages for the main diagnoses were re-grafts 54.4 (SD 19.66) years, keratoconus 32.5 (SD 11.70) years, herpes infection 55.5 (SD 20.87) years, Fuchs' endothelial dystrophy 70 (SD 10.37) years, and pseudophakic bullous keratopathy (PBK) 75 (SD 9.74) years.



**Figure 1** Indications for penetrating keratoplasty (PK), 1990–1999. Re-graft ( $n = 321$ , 40.9%) was the most common indication for PK. Keratoconus was the second most common diagnosis ( $n = 118$ , 15%), followed by Fuchs' endothelial dystrophy ( $n = 73$ , 9.3%), pseudophakic bullous keratopathy ( $n = 60$ , 7.6%), viral keratitis ( $n = 46$ , 5.9%), and other dystrophies ( $n = 28$ , 3.6%). These six indications account for 82.3% of indications for PK. Aphakic bullous keratopathy, injuries, interstitial keratitis, and ulcerative keratitis accounted for most of the remaining cases ( $n = 138$ , 17.6%).

**Abbreviations:** HSV, herpes simplex virus; PBK, pseudophakic bullous keratopathy; PK, penetrating keratoplasty.



**Figure 2** Trends of the leading indications for penetrating keratoplasty (PK). Viral keratitis, which included both herpes simplex and herpes zoster, as an indication for PK, showed a statistically significant decreasing trend using regression analysis (A,  $p < 0.001$ ). Pseudophakic bullous keratopathy (PBK) increased, reaching a peak in 1999 (B,  $p < 0.05$ ). Fuchs' endothelial dystrophy, regrafts, and keratoconus fluctuated over this 10 year period and did not show a statistically significant trend (C-E). The correlation coefficient  $r$  measures the closeness of fit of the data to the regression line.

Overall, sex distribution showed slight male predominance with 54.7% males and 45.3% females. Using  $\chi^2$  analysis for sex differences by diagnostic categories there was a statistically significant predominance among males with keratoconus (79 males, 39 females;  $p < 0.001$ ). No significant sex difference was found for the other diagnostic categories. The trends of the main indications for PK are illustrated in figure 2.

The underlying primary diagnosis and the reason for graft failure in the regraft subgroup were evaluated (table 1). Surgical procedures associated with PK are illustrated in table 2.

Figure 3 illustrates the comparison of the current indications for PK with those studied in the previous two decades.<sup>4</sup>

**DISCUSSION**

The Corneoplastic Unit and Eye Bank is a tertiary referral centre that deals primarily with corneal and anterior segment disorders. The indications for PK are not representative of those nationwide and clearly reflect the specialty nature of the institution (table 3). The category "other" in the table provided by UK Transplant accounted for 28% of indications. This is erroneous and reflects the operating surgeons' unwillingness to categorise indications according to the list provided in the Transplant Record Form.

Regrafting accounted for 40.9% of all PKs over 10 years, a figure that has essentially not changed from the last series spanning two decades (40.8%).<sup>4</sup> It was also one of the leading indications at a number of institutions in Europe and North America.<sup>2 3 5-8 20 21</sup> Regrafting can be expected to remain a leading indication for PK with the expanding pool of PK recipients and endothelial failure as a leading cause of graft failure. However with the growing interest in lamellar

**Table 1** Analysis of regrafts: original diagnosis and cause of failure

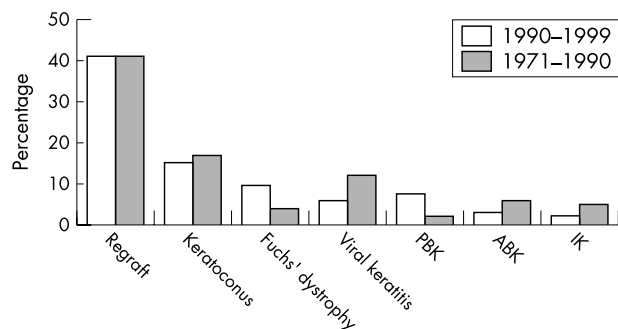
Original diagnosis	Causes of failure
Viral keratitis 68 (21.2%)	Endothelial failure* 134 (41.8%)
Dystrophies 49 (15.2%)	Endothelial rejection† 53 (16.5%)
Bullous keratopathy 47 (14.6%)	Astigmatism 20 (6.2%)
Trauma 44 (13.7%)	Recurrence of dystrophy 15 (4.7%)
Keratoconus 41 (12.8%)	Perforation 15 (4.7%)
Ulcerative keratitis 10 (3.1%)	Bacterial infection 13 (4%)
Corneal opacities 10 (3.1%)	Scarring 12 (3.7%)
Others 40 (12.5%)	Primary donor failure 7 (2.2%)
Unknown 12 (3.7%)	Recurrent HSV keratitis 7 (2.2%)
	Impending perforation 6 (1.9%)
	Bacterial infection with perforation 5 (1.5%)
	Glaucoma 5 (1.5%)
	Trauma 3 (0.9%)
	Others 14 (4.4%)
	Unknown 12 (3.7%)
<b>Total 321 (100%)</b>	<b>Total 321 (100%)</b>

\*Endothelial failure unrelated to endothelial rejection.  
 †Endothelial rejection leading to endothelial failure.  
 HSV, herpes simplex virus.

**Table 2** Surgical procedures associated with penetrating keratoplasty. All cases that had an anterior chamber lens implanted, underwent surgery from 1990-93

	PK+ECCE+IOL	Secondary IOL (aphakic)	IOL exchange primary implant	At exchange
ACIOL	5 (3.4%)	8 (12%)	35 (67.3%)	12 (23%)
PCIOL	140 (94.6%)	10 (15%)	2 (3.8%)	6 (11.5%)
Transsclerally sutured IOL	3 (2%)	48 (73%)	1 (1.9%)	34 (65.5%)
Iris fixated IOL	0	0	8 (15.4%)	0
Unknown	0	0	6 (11.5%)	0
<b>Total</b>	<b>148</b>	<b>66</b>	<b>52</b>	<b>52</b>

PK, penetrating keratoplasty; ECCE, extracapsular cataract extraction; IOL, intraocular lens implant; ACIOL, anterior chamber IOL; PCIOL, posterior chamber IOL.



**Figure 3** Comparison of distribution of indications for penetrating keratoplasty at the Corneoplastic Unit and Eye Bank between 1990–99 and 1971–90. Regrafting was the most common indication in both series (40.9% and 40.8%, respectively). Keratoconus was the second most common indication and similar in both series (15% and 16.8%, respectively). Viral keratitis, which comprised 11.7% of the previous series, had a statistically significant decrease to 5.9% ( $p < 0.005$ ) in the present series. The frequency of both aphakic bullous keratopathy and interstitial keratitis were significantly higher in the previous series ( $p < 0.005$ ). Both pseudophakic bullous keratopathy and Fuchs' endothelial dystrophy had a statistically significant increase in the present series ( $p < 0.005$ ).

techniques, both deep and automated, the number of regrafts may in time decrease.

Viral keratitis comprising both herpes simplex and herpes zoster was the most common primary diagnosis in regrafts in our series, accounting for 21.2% of cases. The majority of these had a PK performed at another institution. Prophylactic antiviral treatment following PK has been used as standard practice at this institution since 1994. Acyclovir has been shown to significantly improve graft survival, and more common use of this modality may decrease the number of failed grafts from herpes simplex in the future.<sup>22–24</sup> Viral keratitis was also the most common primary diagnosis in regrafts in previous reports from the UK, constituting 22–27%.<sup>5, 25</sup> Additionally, this study shows a statistically

significant decline in viral keratitis as an indication for primary PK. This is consistent with national UK data (table 3) and probably reflects better medical management of Herpetic keratitis through use of topical and systemic antivirals, increased appreciation of the higher risk of graft failure in this disease and a consequent reluctance to perform PK. Viral keratitis accounted only for 2.3% in the Doheny Eye Institute and also demonstrated a decreasing trend compared with earlier reports from the same institution.<sup>8</sup> Brady *et al* also showed viral disease declining progressively.<sup>12</sup> This decline, along with the use of systemic acyclovir, may in time reduce viral keratitis as a primary diagnosis for regrafts.

The most common cause for graft failure in regrafts was endothelial failure (41.8%) followed by endothelial rejection (16.5%). Primary failure accounted for 2.2% of regrafts. Sharif *et al*<sup>4</sup> (1971–1990) reported a rate of 4.5% and Moorfields Eye Hospital (1985–1987) 5.8%.<sup>5</sup> This decrease in primary failure as a cause, reflects the improvement in eye banking over the last decade. Endothelial decompensation was also described at Moorfields Eye Hospital as the leading cause for graft failure.<sup>5</sup> MacEwen *et al*,<sup>25</sup> in their study of regrafts, similarly demonstrated that allograft rejection and endothelial failure accounted for most graft failure causes.

Although keratoconus is the leading indication for PK nationally (23.5%) (table 3), it was the second most common indication in this series (15%) as it was previously between 1975 and 1990 (16.8%).<sup>4</sup> Keratoconus was more common in males in our series and similar preponderance has been reported previously,<sup>20, 26</sup> although female predominance has also been described.<sup>27–28</sup> Keratoconus has and continues to be a leading indication for PK elsewhere<sup>1, 3, 5, 9, 21, 29–30</sup>; however, with the resurgence of interest in lamellar techniques<sup>31–34</sup> as well as the introduction of intracorneal rings,<sup>35</sup> this may decrease in time.

Fuchs' endothelial dystrophy was the third most common indication at 9.3%. The reported rates of Fuchs' endothelial dystrophy are highly variable<sup>3, 8, 10–12, 36–37</sup> and probably due to different demographic pools and referral patterns. Although Fuchs' endothelial dystrophy is known to be more common

**Table 3** Comparison of indications for penetrating keratoplasty nationally (yearly intervals)\* and at the Corneoplastic Unit and Eye Bank (CUEB), 1990–99

	Primary disease nationally (%)										Primary disease at CUEB, 1990–99 (%)			
	1990	1991	1992	1993	1994	1995	1996	1997	1998	1999	Total	Total		
Regraft†	0.1	0.1	0.1	0.2	0.1	0.4	0.4	0.6	0.8	0.8	0.36	40.9	Regraft†	
Keratoconus	19	20	20	23	26	24	27	26	25	25	23.5	15	Keratoconus	
Fuchs' dystrophy	8	8	10	11	10	11	11	13	13	13	10.8	9.3	Fuchs' dystrophy	
Endothelial failure: pseudophakic bullous keratopathy	7	10	9	7	7	7	8	7	7	–	7.6	7.6	Pseudophakic bullous keratopathy	
Endothelial failure: aphakic bullous keratopathy	13	7	4	3	3	2	2	2	2	–	4.2	–	–	
Endothelial failure: other	6	4	2	2	2	1	2	2	2	–	2.5	–	–	
Chronic inflammation: viral keratitis	6	5	3	4	3	3	3	3	2	–	3.5	5.9	Viral keratitis	
Chronic inflammation: other	6	5	4	3	3	3	3	2	1	3.2	–	–	–	
Aetiology uncertain	3	4	6	5	5	4	3	3	3	–	4	–	–	
Trauma: mechanical	2	2	2	1	1	1	1	1	1	–	1.3	–	–	
Other	17	14	10	12	12	37	40	39	42	57	28	17.6	Other	
Ocular disease unknown	13	22	29	30	27	7	1	1	1	3	13.4	–	–	
													3.6	Other dystrophies

\* National data provided by UK Transplant.

† Includes endothelial failure, rejection, primary failure, and other causes of failure.

among females,<sup>20 37 38</sup> our study showed no statistically significant sex difference.

Although bullous keratopathy (aphakic and pseudophakic) has significantly declined nationally from 20% in 1990 to 9% in 1998 (table 3), this has not changed significantly as an indication for PK at our institution. However, as expected with increased use of intraocular lenses in cataract surgery in the mid 1980s, aphakic bullous keratopathy declined and PBK increased in our series (fig 3).

The incidence of PBK in the UK has been markedly lower than North America. Sharif *et al*<sup>4</sup> reported 2% between 1975 and 1990. Between 1990 and 1999, PBK accounted for 7.6% in the UK (table 3) and the figure was identical in our series. In North America PBK became a leading indicator for PK in some series (Wills Eye Hospital 22.9%,<sup>12</sup> Doheny Eye Institute 24.8%<sup>8</sup>) and was a result of the initial enthusiasm for lens implantation in cataract surgery, particularly with anterior chamber closed loop implants and iris clip lenses. The UK, in its highly conservative approach and slower acceptance of intraocular lenses, avoided this epidemic. Interestingly, although the national rate of PBK remained the same over the 10 year period (table 3), at our institution the rate of PBK increased (fig 2B)—possibly reflecting an increase in referral of postcataract extraction complications requiring anterior segment reconstruction.

With changes in medical and surgical management, one expects a change in indications for corneal transplantation, and indeed this has been reflected nationally in the UK. However it is interesting to note that the overall indications for PK at a referral centre have not essentially changed over a period of 30 years. Re-grafts have continued to be a leading indication at an identical rate in two series at the same institution with viral disease, which although declining, being the lead primary diagnosis. Through further improvements in medical management and the advent of better surgical techniques for lamellar grafting and newer techniques of posterior lamellar and endothelial transplantation, the indications for PK and the role of a referral corneal institution may well change over the next 30 years.

## ACKNOWLEDGEMENTS

The authors gratefully acknowledge the assistance of Andrea Rowe, Eye Bank Coordinator, Dot Helme and Caroline Langridge, Department of Clinical Audit and Research, Queen Victoria Hospital, East Grinstead, and Phil Pocock, Senior Biostatistician, UK Transplant.

## Authors' affiliations

**N Al-Yousuf, I Mavrikakis, E Mavrikakis, S M Daya**, Corneoplastic Unit and Eye Bank, Queen Victoria Hospital, East Grinstead, UK

Presented in part at "CORNEA 2002 - celebrating 50 years of Eye Banking", Gatwick, UK, 14 November 2002.

Correspondence to: Mr S M Daya, Director and Consultant Ophthalmic Surgeon, Corneoplastic Unit and Eye Bank, Queen Victoria Hospital, East Grinstead, West Sussex RH19 3DZ, UK; [sdaya@compuserve.com](mailto:sdaya@compuserve.com)

Accepted 5 January 2004

## REFERENCES

- Smith RE, McDonald HR, Nesburn AB, *et al*. Penetrating keratoplasty, Changing indications, 1947 to 1978. *Arch Ophthalmol* 1980;**98**:1226-9.
- Lemp MA. Indications for penetrating keratoplasty. *Med Ann DC* 1972;**41**:346-50.
- Arentsen JJ, Morgan B, Green WR. Changing indications for keratoplasty. *Am J Ophthalmol* 1976;**81**:313-18.
- Sharif KW, Casey TA. Changing indications for penetrating keratoplasty, 1971-1990. *Eye* 1993;**7**:485-8.
- Morris RJ, Bates AK. Changing indications for keratoplasty. *Eye* 1989;**3**:455-9.
- Robin JB, Gindi JJ, Koh K, *et al*. An update of the indications for penetrating keratoplasty, 1979 through 1983. *Arch Ophthalmol* 1986;**104**:87-9.
- Mohamadi P, McDonnell JM, Irvine JA, *et al*. Changing indications for penetrating keratoplasty, 1984-1988. *Am J Ophthalmol* 1989;**107**:550-2.
- Flowers CW, Chang KY, McLeod SD, *et al*. Changing indications for penetrating keratoplasty, 1989-1993. *Cornea* 1995;**14**:583-8.
- Damji KF, Rootman J, White VA, *et al*. Changing indications for penetrating keratoplasty in Vancouver, 1978-1987. *Can J Ophthalmol* 1990;**25**:243-8.
- Lindquist TD, McGlothlan JS, Rotkis WM, *et al*. Indications for penetrating keratoplasty: 1980-1988. *Cornea* 1991;**10**:210-16.
- Hyman L, Wittmann J, Yang C. Indications and techniques of penetrating keratoplasties, 1985-1988. *Cornea* 1992;**11**:573-6.
- Brady SE, Rapuano CJ, Arentsen JJ, *et al*. Clinical indications for and procedures associated with penetrating keratoplasty, 1983-1988. *Am J Ophthalmology* 1989;**108**:118-22.
- Chandler JW. Indications for penetrating keratoplasty and management of cases. *Trans Pacific Coast Oto-ophthalmol Soc* 1976;**57**:97-104.
- Robinson CH. Indications, complications and prognosis for repeat penetrating keratoplasty. *Ophthalmic Surg* 1979;**10**:27-34.
- Ramsay AS, Lee WR, Mohammed A. Changing indications for penetrating keratoplasty in the West of Scotland from 1970 to 1995. *Eye* 1997;**11**:357-60.
- Haamann P, Jensen OM, Schmidt P. Changing indications for penetrating keratoplasty. *Acta Ophthalmol* 1994;**72**:443-6.
- Rapuano CJ, Cohen EJ, Brady SE, *et al*. Indications for and outcomes of repeat penetrating keratoplasty. *Am J Ophthalmol* 1990;**109**:689-95.
- Brooks AMV, Weiner JM. Indications for penetrating keratoplasty: A clinicopathological review of 511 corneal specimens. *Aust N Z J Ophthalmol* 1987;**15**:277-81.
- Kervick GN, Shepherd WFL. Changing indications for penetrating keratoplasty. *Ophthalmic Surg* 1990;**21**:227.
- Maeno A, Naor J, Lee HM, *et al*. Three decades of corneal transplantation: indications and patient characteristics. *Cornea* 2000;**19**:7-11.
- Cursiefen C, Kuchle M, Naumann GOH. Changing indications for penetrating keratoplasty: Histopathology of 1,250 corneal buttons. *Cornea* 1998;**17**:468-70.
- Cobo LM, Coster DJ, Rice NSC, *et al*. Diagnosis and management of corneal transplantation for herpetic keratitis. *Arch Ophthalmol* 1980;**98**:1755-9.
- Barney NP, Foster CS. A prospective randomised trial of oral acyclovir after penetrating keratoplasty for herpes simplex viral keratitis. *Cornea* 1994;**13**:232-6.
- Tambasco FP, Cohen EJ, Nguyen LH, *et al*. Oral acyclovir after penetrating keratoplasty for herpes simplex keratitis. *Arch Ophthalmol* 1999;**117**:445-9.
- MacEwen CJ, Khan ZUH, Anderson E, *et al*. Corneal re-graft: indications and outcome. *Ophthalmic Surgery* 1988;**19**:706-12.
- Liu E, Slomovic AR. Indications for penetrating keratoplasty in Canada, 1986-1995. *Cornea* 1997;**16**:414-19.
- Pouliquen Y. Doane lecture keratoconus. *Eye* 1987;**1**:1-14.
- Kaufman H, Barron B, McDonald M. *The cornea*, 2nd ed. Butterworth-Heinemann, 1998:369.
- Mamalis N, Anderson CW, Kreisler KR, *et al*. Changing trends in the indications for penetrating keratoplasty. *Arch Ophthalmol* 1992;**110**:1409-11.
- The Australian Corneal Graft registry, 1990-1992 report. *Aust N Z J Ophthalmol* 1993;**21**(suppl 2):1-48.
- Anwar M, Teichman KD. Big-bubble technique to bare Descemet's membrane in anterior lamellar keratoplasty. *J Cataract Refract Surg* 2002;**28**:398-403.
- Coombes AG, Kirwan JF, Rostron CK. Deep lamellar keratoplasty with lyophilised tissue in the management of keratoconus. *Br J Ophthalmol* 2001;**85**:788-91.
- Melles GR, Remeijer L, Geerards AJ. A quick surgical technique for deep, anterior lamellar keratoplasty using visco-dissection. *Cornea* 2000;**19**:427-32.
- Balestrazzi E, Balestrazzi A, Mosca L, *et al*. Deep lamellar keratoplasty with trypan blue intrastromal staining. *J Cataract Refract Surg* 2002;**28**:929-31.
- Colin J, Cochener B, Savary G, *et al*. Correcting keratoconus with intracorneal rings. *J Cataract Refract Surg* 2000;**26**:1117-22.
- Legeais J, Parc C, D'Hermies F. Nineteen years of penetrating keratoplasty in the Hotel-Dieu Hospital in Paris. *Cornea* 2001;**20**:603-6.
- Dobbins KRB, Price FW, Whitson WE. Trends in the indications for penetrating keratoplasty in the Midwestern United States. *Cornea* 2000;**19**:813-16.
- Kracher JH, Palay DA. *Cornea*. St Louis, USA: Mosby, 1995.



## Penetrating keratoplasty: indications over a 10 year period

N Al-Yousuf, I Mavrikakis, E Mavrikakis, et al.

*Br J Ophthalmol* 2004 88: 998-1001

doi: 10.1136/bjo.2003.031948

---

Updated information and services can be found at:

<http://bjo.bmj.com/content/88/8/998.full.html>

---

### References

*These include:*

This article cites 31 articles, 6 of which can be accessed free at:

<http://bjo.bmj.com/content/88/8/998.full.html#ref-list-1>

Article cited in:

<http://bjo.bmj.com/content/88/8/998.full.html#related-urls>

### Email alerting service

Receive free email alerts when new articles cite this article. Sign up in the box at the top right corner of the online article.

---

### Topic Collections

Articles on similar topics can be found in the following collections

[Ophthalmologic surgical procedures](#) (962 articles)

[Cornea](#) (380 articles)

[Ocular surface](#) (452 articles)

[Eye \(globe\)](#) (538 articles)

---

### Notes

---

To request permissions go to:

<http://group.bmj.com/group/rights-licensing/permissions>

To order reprints go to:

<http://journals.bmj.com/cgi/reprintform>

To subscribe to BMJ go to:

<http://group.bmj.com/subscribe/>