

SCIENTIFIC REPORT

An intravitreal biodegradable sustained release naproxen and 5-fluorouracil system for the treatment of experimental post-traumatic proliferative vitreoretinopathy

J A Cardillo, M E Farah, J Mitre, P H Morales, R A Costa, L A S Melo, B Kuppermann, R Jorge, P Ashton

Br J Ophthalmol 2004;88:1201–1205. doi: 10.1136/bjo.2003.039917

Background/aims: To determine the potential of an intravitreal sustained release naproxen and 5-fluorouracil (NA/5-FU) codrug for the treatment of experimental proliferative vitreoretinopathy (PVR) in a model for trauma associated tractional retinal detachment (TRD).

Methods: Sustained release pellets were prepared by covalently linking naproxen to 5-fluorouracil. Drug release was tested *in vitro* and toxic effects were evaluated by electroretinography and light microscopy. Traumatic PVR was induced in pigmented rabbits by performing a scleral laceration, followed by repair and intravitreal injection of 0.4 ml of autologous blood. Thirty six eyes were treated with a sustained release implant containing 1.5 mg NA/5-FU as a codrug and 36 control eyes were submitted to surgery alone. Eyes were evaluated for TRD by serial indirect ophthalmoscope examination at different time points followed by postmortem fundus evaluation of the enucleated eye

Results: The NA/5-FU pellets were found to provide linear release of 5-FU and naproxen over the 30 day duration of the *in vitro* release test. Both the severity of PVR grade and the percentage of eyes with moderate or worse tractional detachment were significantly lower in eyes treated with the codrug pellet. There were no drug related toxic effects evident on histopathological or electroretinograph examination of eyes containing the NA/5-FU pellet.

Conclusions: The results suggest that this NA/5-FU codrug device effectively inhibits the progression of PVR in a rabbit trauma model that closely resembles PVR in humans. Additional studies to add knowledge to these initial findings and to clarify the potential of the codrug device for the treatment of human PVR are warranted.

Penetrating ocular trauma is a cause of severe visual loss and disability in the United States.¹ Vision can be lost not only as a result of the initial mechanical damage but also because of secondary complications.² Although wound healing is a natural aspect of recovery following penetrating injury, excessive scar tissue development in the eye may lead to the development of tractional retinal detachment,^{2–6} and therefore treatments directed at prevention of proliferative vitreoretinopathy (PVR) are a logical principle of management.²

Various pharmacological agents have been evaluated in animals and humans for their utility in decreasing the incidence of tractional retinal detachment due to PVR

following retinal detachment^{7–12} but very few following ocular trauma.^{13–14} However, eyes with an open globe injury should be considered at additional risk for PVR because the 11%–43% frequency of PVR found in these patients is significantly higher than the 7%–11% rate following retinal detachment surgery alone.^{2–15–17} Antiproliferative agents, such as daunomycin and 5-fluorouracil (5-FU), have been suggested as therapy for PVR.^{7–13} Other investigators have documented the efficacy of intravitreal steroids in the prevention of PVR.^{18–19} We have previously shown the efficacy of a corticosteroid and 5-fluorouracil conjugate in the treatment of experimental PVR.^{11–12} The use of intraocular steroids, however, has attendant risks and preparations of non-steroidal anti-inflammatory drugs (NSAIDs) provide the ocular surgeon with an alternative approach to the control of inflammation that may have distinct advantages over corticosteroid use.

In the ocular trauma field, however, further studies are still mandatory to obtain additional information and to clarify the potential usefulness of such systems for the pharmacological treatment of PVR. In addition, in the setting of trauma, where a stronger and more prolonged stimulus for proliferation is present, a sustained release drug with prolonged effects is likely to be more effective than the transient nature of its free form. Therefore, this system is a logical and rational addition to the pharmacological approach of preventing PVR following ocular trauma.

An encouraging previous experience with a codrug for the treatment of experimental PVR prompted us to investigate the potential of an improved NSAIDs/5-FU conjugated system also for the prevention of an experimental trauma model of PVR.

METHODS

An established rabbit model of post-traumatic PVR, previously described by Ryan and Cleary,²⁰ was used to investigate the effects of a controlled NA/5-FU delivery system on the intraocular scarring process following an experimental posterior penetrating eye injury in the rabbit. All animal procedures were performed in accordance with the ARVO Statement for the Use of Animals in Ophthalmic and Vision Research. Seventy two pigmented rabbits of either sex weighting approximately 1.5–2 kg were used for this study.

Preparation of NA/5-FU pellets for implantation

Fully bioerodible implantable sustained release pellets containing 1.5 mg of the NA/5-FU codrug were prepared by

Abbreviations: ERG, electroretinography; NA/5-FU, naproxen and 5-fluorouracil; NSAIDs, non-steroidal anti-inflammatory drugs; PVR, proliferative vitreoretinopathy; TRD, tractional retinal detachment.

direct compression of the powered codrug into a 1.5 mm disk with a customised press (Parr Instrument, Moline, IL, USA).

In vitro pharmacokinetic study

The release rate of the parent drugs (5-FU and naproxen) and the intact codrug were determined in vitro by immersing the pellets in 1 ml of a 1:1 phosphate buffer/bovine serum mixture at 37°C. The buffer was replaced daily and, after deproteination, assayed by high performance liquid chromatography. The release rate was determined by plotting the cumulative amount of drug released versus time.

Assessment of toxic effects

Scotopic electroretinography (ERG) was performed in both eyes of 10 rabbits before implantation of a 1.5 mg NA/5-FU pellet in the right eye. Postimplantation ERG was performed at 14, 18, and 60 days. Electroretinography examinations were recorded with the use of contact lens electrodes (ERG-Jet, Universo SA, La Chaux-de-fonds, Switzerland) with a two channel clinical signal averager (No. 5200, Cadwell, Kennewick, WA, USA) and a Ganzfeld flash unit (VPA-10, Cadwell). Scotopic ERGs, obtained after at least 30 minutes of dark adaptation, were elicited at 0.34 Hz. For each ERG, 20 stimulus presentations were averaged. To minimise the effect of individual and daily variation on the ERG, the ratio of the b-wave amplitude of the experimental (right) eye to the b-wave amplitude of the control (left) eye was determined. When the amplitude of the experimental and control eyes are equal, the ratio equals 1. A decrease in the ratio reflects a relative decrease in the b-wave amplitude of the experimental eye.

The rabbits used for ERG analysis were killed at 65 days for histopathological analysis. The pellet injected eyes were immediately enucleated and a 3 o'clock hour circumferential incision was created 1.0 mm posterior to the limbus. The globes were fixed by immersion in 2% glutaraldehyde in 0.1 mol/l sodium cacodylate buffer (pH 7.4) and processed in paraffin. Sections were stained with haematoxylin-eosin and examined by light microscopy.

Animal model for trauma associated PVR

A previously developed model for traumatic PVR was used.²⁰ Briefly, 72 pigmented rabbits each weighing 1.5–2 kg were used. The animals were anaesthetised with a 4:1 mixture of ketamine hydrochloride (24 mg/kg) and xylazine hydrochloride (6 mg/kg), and their pupils were dilated with 1% tropicamide and 2.5% phenylephrine hydrochloride eye drops. Using an operating microscope, rabbit eyes were injured by a standard 8 mm circumferential scleral incision through the pars plana 2.5 mm from the limbus, followed by repair of the wound with 8–0 silk sutures. At the end of the surgery, all eyes received 0.4 ml of autologous blood injected through a 25 gauge needle inserted through the wound and into the mid vitreous. Thirty six treated eyes were randomly implanted with 1.5 mg of the NA/5-FU codrug pellet into the vitreous base through the area of laceration, and 36 control rabbits were submitted to PVR inducing operation alone with no pellet implantation.

PVR grading

As a reliable clinical observation is precluded by vitreal blood, we sought to mitigate this problem by combining a detailed fundus evaluation of the enucleated eye under a dissecting microscope, in addition to a clinical indirect microscopic examination at day 3, day 7, day 14, day 21, day 28, and day 60. A total of six eyes per group were analysed at each time point. All animals were sacrificed under deep anaesthesia by an intracardiac injection of pentobarbital sodium. The following grading scale was used to classify each eye:

Stage 0: Attached without evidence of fibrous ingrowth.

Stage 1: Attached with minimal traction elevation confined to the medullary ray. Mild fibrous ingrowth was present upon scleral depression. Occasionally a "clothesline" type of fold was evident within the posterior ray, but the retina surrounding the ray remained attached.

Stage 2: Up to 50% of the retina was detached (moderate tractional elevation), usually directly surrounding the ray. Prominent A–P traction involving the disc and medullary ray was evident. Prominent fibrous ingrowth was present, with faint bands connecting the peripheral ray fibrous mass to the disc or ray. The retinal vessels were dilated without overt neovascularisation.

Stage 3: Between 50%–100% of the retina was detached (severe retinal detachment), usually associated with an open funnel configuration. Fibrous ingrowth from the wound was severe, and the peripheral retina and ray were drawn towards the fibrous mass.

Stage 4: 100% of the retina was detached associated with a closed funnel configuration. Fibrous ingrowth was severe, with obvious dragging of the retina causing prominent retinal folds.

Statistical analysis

Statistical analysis was performed using the Statistica 6.0 software (Statsoft Inc, Tulsa, OK, USA). The Mann-Whitney non-parametric test was used to compare the difference in median clinical grade of PVR between treated and untreated groups. The χ^2 test was used to compare the difference in the number of eyes with retinal detachment between experimental and control animals. For all the tests, the level of significance was set at $\alpha = 0.05$, two tailed. A paired two tailed *t* test was used to compare the ERG b-wave amplitude ratio before and after pellet implantation.

RESULTS

The NA/5-FU pellets were found to provide linear release of 5-FU and naproxen over the 30 day duration of the in vitro release test. Over this time the release rate of 5-FU was approximately 6 ug/day and the release rate of NA was approximately 10 ug/day (fig 1) Interestingly, because of the extremely short half life of the conjugate once dissolved, only trace amounts of the intact codrug were detected in the release medium. We evaluated the capacity of the NA/5-FU codrug pellet to prevent TRD in an experimental posterior penetrating eye injury in the rabbit. As expected, a scleral

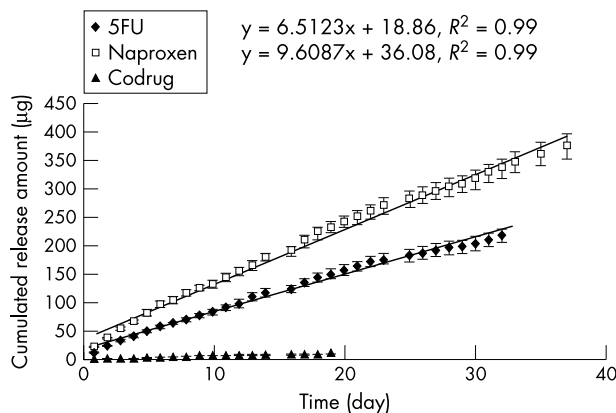


Figure 1 In vitro release of naproxen and 5-fluorouracil from NA/5-FU codrug pellets placed in 50% human plasma and 50% phosphate buffer, pH 7.4. Data represent mean (SD); n=3 at each time point.

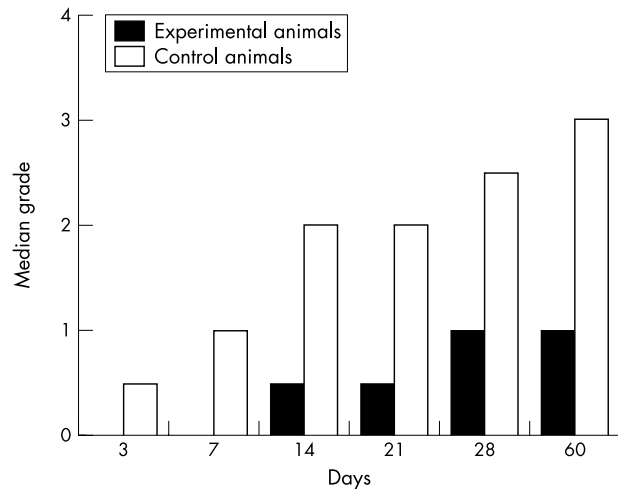


Figure 2 Median clinical grade of proliferative vitreoretinopathy as a function of time. Median grade was 0 at time points that do not show a data bar.

incision followed by an intravitreal blood injection induced TRD (stages 3 or 4) in 100% of the untreated eyes not receiving a codrug pellet 14 days after the triggering injury. In striking contrast, no eyes in the treated group showed evidence of severe retinal detachment (stage 3) at 60 days. Overall, the NA/FU codrug pellet treated rabbits showed a statistically significant decrease in the retinal detachment rate compared with the control group at all time points, except for day 3 when the configuration of the retina resembled that of the normal eyes and did not suggest the presence of vitreous traction in either group ($p < 0.003$, Mann-Whitney U test). These data are summarised in figure 2. The percentage of eyes with moderate tractional retinal detachment (up to 50% of retina detachment) or worse was higher in the control group than in the treated group after the second week ($p < 0.02$, χ^2 test) (fig 3).

A clinical feature that correlated with ultimate TRD in all untreated eyes was the early and persistent development of fibrous ingrowth from the incision which ultimately pro-

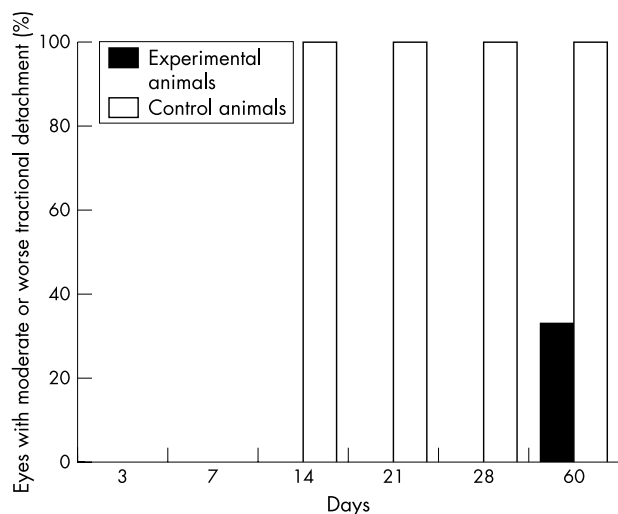


Figure 3 Percentage of eyes with moderate or worse tractional detachment as a function of time. The percentage of eyes with moderate tractional detachment was 0 at time points that do not show a data bar.

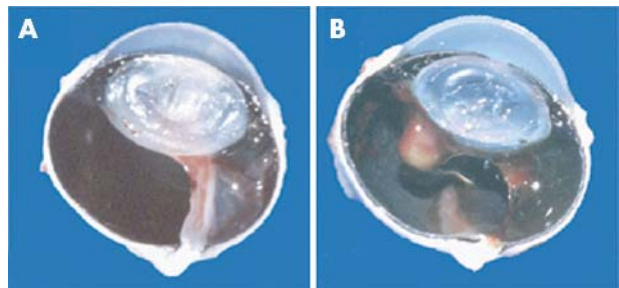


Figure 4 Fundus evaluation of a radial section of the enucleated eye, 30 days after the triggering event. (A) The finding in the control eye where typically 50%–100% of the retina was detached (severe retinal detachment), usually associated with an open funnel configuration. Fibrous ingrowth from the wound and the peripheral retina and ray drawn towards the fibrous mass can be observed. (B) A treated eye with the retina attached with minimal traction elevation confined to the posterior pole. Note that at day 30 the NA/5-FU pellet showed only partial absorption.

gressed in most severe cases to cause transverse traction, ciliary body detachment, and cyclitic membrane formation within 21 days. Within 14 days, anteroposterior traction was observed between the disc and the fibrous mass. Ultimately, epiretinal proliferation developed in association with progressive TRD of the medullary rays and closed funnel configuration. In the treated group a prominent but restricted anteroposterior traction involving the disc and medullary ray was evident up to the 60th day of follow up. Prominent fibrous ingrowth was present, with faint bands connecting the peripheral fibrous mass to the disc or ray. Clinically, a complete dissolution of the conjugate drug-polymer could be only observed at day 60. At day 30, the NA/5-FU pellet demonstrated only partial absorption (fig 4).

NA/5-FU pellet toxicity

Electroretinograms showed no evidence of NA/5-FU toxic effects. The b-wave amplitudes remained normal throughout the study. Ratios of the ERG b-wave amplitudes of the injected eye to the b-wave of the contralateral (control) eye were not statistically different when preimplantation values were compared with postimplantation values ($p = 0.27$ at day 63, paired t test) (fig 5).

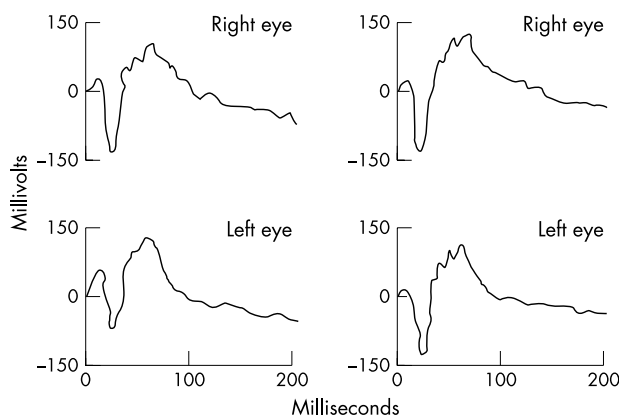


Figure 5 Representative scotopic electroretinography in eye receiving a 1.5 mg NA/5-FU codrug pellet. The ratios of the electroretinographic b-wave amplitude of the implanted (right) to the left eye (control) were not statistically different when preinjection values (left) were compared with postimplantation values (right) at day 60 ($p = 0.27$).

On histopathologic analysis, the ciliary body and retina were normal by light microscopy examination (data not shown). No sign of retinal necrosis, photoreceptor cell loss, cystic degeneration, inflammatory cell infiltration, or hypocellularity of nuclear layers was observed.

DISCUSSION

The results of our study show that an implantable NA/5-FU codrug effectively inhibits the progression of PVR in a rabbit model. Both the severity of PVR grade and percentage of eyes with moderated tractional detachment or worse were significantly lower in experimental eyes than control eyes. Previous studies have shown the effectiveness of sustained release TA/5-FU in decreasing the incidence of PVR in an animal model not involving penetrating trauma.^{11 12} We hypothesised that a device that contained both an anti-inflammatory drug and 5-fluorouracil in combination might be more effective than treatment with either agent alone and might simultaneously downregulate the inflammatory and proliferative components of the wound healing response. Historically, corticosteroids have been the drug of choice for the prevention or treatment of intraocular inflammation. Although effective, these drugs may interfere more severely with wound healing, aggravate infection, or cause an increase in intraocular pressure. The advent of ophthalmic preparations of non-steroidal anti-inflammatory drugs provides the ocular surgeon with an alternative approach that may have distinct advantages over corticosteroid use. Furthermore, the severe nature of PVR in this model coupled with its long lasting proliferation stimulus provides the rationale for a slow delivery drug therapy. Single intravitreal injections of either agent have a relatively short half life (further shortened by vitrectomy, aphakia, and postoperative inflammation),²¹ which is unlikely to be sufficient for an adequate therapeutic effect in this severe model of experimental PVR. In the human eye the time interval between the primary trauma and the occurrence of PVR varies according to the type of trauma involved. A shorter interval between injury and PVR onset is observed for perforated globes (1.3 months), but may be as long as 3.2 months for penetrating injury.² A similar association between types of injury and time to development of PVR is also seen in animal models. In accordance with our experiment, in the rabbit, PVR occurred 8–16 days following an 8 mm incision in conjunction with an injection of blood in the vitreous cavity,²⁰ whereas a transvitreal perforation resulted in fibrous proliferation and retinal detachment beginning 4 days after injury.²² Adjunctive therapy for post-traumatic PVR is likely to be most effective early, when the disease is in its subclinical stages, and should ideally be sustained over a period that corresponds with the duration of the stimulus. According to our study, the NA/5-FU pellets were found to provide linear release of 5-FU and naproxen over the 30 day duration of the in vitro release test, when cellular proliferation has generally ceased. Taken together, these data suggest that the naproxen-5-fluorouracil slow delivery device would be a rational designed pharmacological adjunct to the surgical management of post-traumatic PVR, a disease that typically runs its course over a 2–5 week period in experimental models²⁰ or longer in the human eye.²

A rapidly acting, prolonged effect drug delivery system is a logical necessity for the pharmacological treatment of PVR, as the clearance of drugs from the vitreous cavity may be affected by factors including vitreous liquefaction, vitrectomy, or inflammation, such as is seen in injured eyes. In the clinical arena, the codrug might be placed in the eye at the conclusion of vitrectomy to repair the primary injury in the presence or absence of PVR. In this situation, gas or silicone oil is often used as a vitreous substitute to provide an extended retinal tamponade. The pharmacokinetics and

efficacy of the codrug pellet in this situation are unknown and are beyond the scope of this initial report. An additional important concern is that blocking the proliferative features of PVR may also block the therapeutic response that leads to a chorioretinal scar closing the retinal breaks, and even the wound healing process. Papers describing clinical experience with the use of daunomycin and 5-fluorouracil in PVR surgery have not reported any evidence of this complication.^{7 9 10 13} However, regarding ocular trauma, additional work is needed to validate this evidence and forms the groundwork for future investigations.

The NA/5-FU codrug pellet used in this study did not result in a toxic effect on the retina when examined electrophysiologically or histologically. Because vitrectomy is the primary procedure of choice in injured eyes at high risk to develop PVR, a major concern would be the possibility of an enhanced toxicity of this NA/5-FU codrug pellet in vitrectomised eyes and this system should be further evaluated in this respect.

Under the conditions of this study, this NA/5-FU codrug device inhibited the frequency and severity of PVR in a rabbit trauma model that closely resembles PVR in humans. Assuming a lack of toxic effects, this device may be characterised as an optimised plan for prophylaxis in the clinical field and merits further investigation.

Authors' affiliations

J A Cardillo*, R A Costa, R Jorge, Department of Ophthalmology, Hospital de Olhos de Araraquara, Araraquara, São Paulo, Brazil
J A Cardillo, M E Farah, J Mitre, P H Morales, L A S Melo, Department of Ophthalmology, Paulista School of Medicine, UNIFESP-EPM, Sao Paulo, Brazil

B Kuppermann, Department of Ophthalmology, University of California Irvine, Irvine, California, USA

P Ashton, Department of Ophthalmology, Tufts New England Medical Center, Boston, Massachusetts, USA

The authors have no financial interest in any of the products mentioned in this paper.

Correspondence to: Dr J A Cardillo, Hospital de Olhos de Araraquara, Rua Henrique Dall'Acqua 45, Araraquara-SP, Brazil 14802-530; jacardillo@horizon.com.br

Accepted 1 February 2004

REFERENCES

- 1 Parver LM. Eye trauma: the neglected disorder. *Arch Ophthalmol* 1986;**104**:1452–3.
- 2 Cardillo JA, Stout T, LaBree L, et al. Post-traumatic proliferative vitreoretinopathy. The epidemiologic profile, onset, risk factors, and visual outcome. *Ophthalmology* 1997;**104**:1166–73.
- 3 Eagling EM. Perforating injuries involving the posterior segment. *Trans Ophthalmol Soc UK* 1975;**95**:335–9.
- 4 Cox MS, Freeman HM. Retinal detachment due to ocular penetration I. Clinical characteristics and surgical results. *Arch Ophthalmol* 1978;**96**:1354–61.
- 5 Ryan SJ, Allen AW. Pars plana vitrectomy in ocular trauma. *Am J Ophthalmol* 1979;**88**:483–91.
- 6 Brinton GS, Aaberg TM, Reeser FH, et al. Surgical results in ocular trauma. *Am J Ophthalmol* 1982;**93**:271–8.
- 7 Blumenkranz M, Hernandez E, Ophir A, et al. 5-fluorouracil: New applications in complicated retinal detachment from an established antimetabolite. *Ophthalmology* 1984;**91**:122–30.
- 8 Rubsamen PE, Davis PA, Hernandez E, et al. Prevention of experimental proliferative vitreoretinopathy with a biodegradable intravitreal implant for the sustained release of fluorouracil. *Arch Ophthalmol* 1994;**112**:407–13.
- 9 Asaria RH, Kon CH, Bruce C, et al. Adjunct 5-fluorouracil and heparin prevents proliferative vitreoretinopathy: Results from a randomized, double-blind, controlled clinical trial. *Ophthalmology* 2001;**108**:1179–83.
- 10 Wiedemann P, Hilgers RD, Bauer P, et al. Adjunctive daunorubicin in the treatment of proliferative vitreoretinopathy: results of a multicenter clinical trial. Daunomycin Study Group. *Am J Ophthalmol* 1998;**126**:550–9.
- 11 Yang CS, Khawly JA, Hainsworth DP, et al. An intravitreal sustained-release triamcinolone and 5-fluorouracil codrug in the treatment of experimental proliferative vitreoretinopathy. *Arch Ophthalmol* 1998;**116**:69–77.

- 12 **Berger AS**, Cheng CK, Pearson PA, *et al.* Intravitreal sustained release corticosteroid-5-fluorouracil conjugate in the treatment of experimental proliferative vitreoretinopathy. *Invest Ophthalmol Vis Sci* 1996;**37**:2318–25.
- 13 **Wiedemann P**, Leummen K, Schmiedl R, *et al.* Intraocular daunorubicin for the treatment and prophylaxis of traumatic proliferative vitreoretinopathy. *Am J Ophthalmol* 1987;**104**:10–14.
- 14 **Ozderdem U**, Mach-Hoacre B, Keef K, *et al.* The effect of prinomast (AG3340), a synthetic inhibitor of matrix metalloproteinases, on posttraumatic proliferative vitreoretinopathy. *Ophthalmic Res* 2001;**33**:20–3.
- 15 **Rachal WF**, Burton TC. Changing concepts of failures after retinal detachment surgery. *Arch Ophthalmol* 1979;**97**:480–3.
- 16 **Bonnet M**. Clinical factors predisposing to massive proliferative vitreoretinopathy in rhegmatogenous retinal detachment. *Ophthalmologica* 1984;**188**:148–52.
- 17 **Cowley M**, Conway BP, Campochiaro PA, *et al.* Clinical risk factors for proliferative vitreoretinopathy. *Arch Ophthalmol* 1989;**107**:1147–51.
- 18 **Tano Y**, Chandler D, Machemer R. Treatment of intraocular proliferations with intravitreal injection of triamcinolone acetonide. *Am J Ophthalmol* 1980;**90**:810–16.
- 19 **Chandler DB**, Rozakis G, Dejuan E, *et al.* The effect of triamcinolone acetonide on a refined experimental model of proliferative vitreoretinopathy. *Am J Ophthalmol* 1980;**90**:810–16.
- 20 **Ryan SJ**, Cleary PE. Experimental model of posterior penetrating injury. *Trans New Orleans Acad Ophthalmol* 1983;**31**:122–8.
- 21 **Algere P**, Bill A. Effects of vitrectomy and phakectomy on the drainage of the vitreous compartment. *Albrecht von Graefes Arch Klin Exp Ophthalmol* 1981;**216**:253–60.
- 22 **Topping TM**, Abrams GW, Machemer R. Experimental double-perforating injury of the posterior segment in rabbit eyes: the natural history of intraocular proliferation. *Arch Ophthalmol* 1979;**97**:735–42.

Video reports

To view the video reports in full visit our website www.bjophthalmol.com and click on the link to the video reports.

Video Suite: Triamcinolone-assisted vitrectomy

- Triamcinolone-assisted removal of the posterior hyaloid to repair retinal detachment due to macular hole in high myopia. *A Ueno, H Enaida, Y Hata, T Nakamura, T Hisatomi, K Fujisawa, T Kubota, T Sakamoto, T Ishibashi*
- Triamcinolone acetonide-assisted Epiretinal Membrane Peeling. *S D M Chen, C K Patel*
- A suture technique to manage a case of severe early flap displacement after laser in situ keratomileusis. *L Spadea, P Pantaleoni, G Bianco*
- Reconstruction of the Ocular Surface in LOGIC Syndrome. *E Moore, V Kumar, J R Ainsworth, S Shah*
- Laser Photocoagulation for Posterior Segment Intraocular Parasites. *T Prabripataloong, S Asawaphureekorn*
- Feeder Vessel Treatment with High Speed ICG Angiography. *D Stanescu-Segall, G Coscas, F Coscas, G Soubrane*
- Endoscopy to aid anterior segment surgery. *J E Moore, A Sharm*
- Penetrating ocular injury due to a fish hook: Surgical removal. *S D M Chen, D Chiu, C K Patel*
- Retinal Ganglion Cell Axon Response to Guidance Molecules. *S F Oster and DW Sretavan*
- Marin-Amat Syndrome. *A Jogiya, C Sandy*
- Excision of subcutaneous Dirofilaria of the eyelid. *D Mallick, TP Ittyerah*
- Thixotropy: a novel explanation for the cause of lagophthalmos after peripheral facial nerve palsy. *M Aramideh, J H T M Koelman, P P Devriese, F VanderWerf, J D Speelman*
- Surgical revision of leaking filtering blebs with an autologous conjunctival graft. *K Taherian, A Azuara-Blanco*
- Dipetalonema Reconditum in the human eye. *T Huynh, J Thean, R Maini*



An intravitreal biodegradable sustained release naproxen and 5-fluorouracil system for the treatment of experimental post-traumatic proliferative vitreoretinopathy

J A Cardillo, M E Farah, J Mitre, et al.

Br J Ophthalmol 2004 88: 1201-1205
doi: 10.1136/bjo.2003.039917

Updated information and services can be found at:

<http://bjo.bmj.com/content/88/9/1201.full.html>

These include:

References

This article cites 21 articles, 8 of which can be accessed free at:

<http://bjo.bmj.com/content/88/9/1201.full.html#ref-list-1>

Article cited in:

<http://bjo.bmj.com/content/88/9/1201.full.html#related-urls>

Email alerting service

Receive free email alerts when new articles cite this article. Sign up in the box at the top right corner of the online article.

Topic Collections

Articles on similar topics can be found in the following collections

[Retina](#) (1207 articles)

[Vitreous](#) (124 articles)

Notes

To request permissions go to:

<http://group.bmj.com/group/rights-licensing/permissions>

To order reprints go to:

<http://journals.bmj.com/cgi/reprintform>

To subscribe to BMJ go to:

<http://group.bmj.com/subscribe/>