

SCIENTIFIC REPORT

PET/CT imaging: detection of choroidal melanoma

S Reddy, M Kurli, L B Tena, P T Finger

Br J Ophthalmol 2005;89:1265–1269. doi: 10.1136/bjo.2005.066399

Aim: To determine the size of untreated choroidal melanomas resolved by whole body positron emission tomography fused with computed tomography (PET/CT).

Methods: 50 consecutive patients with untreated choroidal melanomas underwent whole body PET/CT. A functionally fused helical CT scan and 18-fluoro-2-deoxyglucose (FDG) PET scans were employed. The tumours were identified (both quantitatively and qualitatively) and compared with clinical measurements derived from ophthalmoscopic, angiographic, and ultrasonographic imaging. Standardised uptake values (SUV) of more than 2.5 were considered positive.

Results: Among the 50 patients with choroidal melanoma, PET/CT scan SUVs of more than 2.5 were noted in 14 (28%) tumours. No AJCC T1 class tumours, 33.3% of T2 melanomas, and 75% of T3 melanomas were physiologically identifiable on PET/CT. With respect to COMS group classifications, no small choroidal tumours, 33% of medium, and 75% of large melanomas were physiologically identifiable. The sole ring melanoma was identifiable on PET/CT imaging. The smallest tumour physiologically identifiable by PET/CT had basal dimensions of 3×5.9 and an apical height of 2.9 mm.

Conclusion: Though PET/CT was found to be capable of physiologically identifying certain medium (T2) and most large sized (T3) choroidal melanomas, physiological imaging was not completely dependent upon tumour size. Functionally fused PET/CT localised the tumours within the eye and assessed their physiological activity.

Cancer cells require a great deal of sugar (glucose) for metabolism and growth. Positron emission tomography/computed tomography (PET/CT) scanning utilises a radioactive form of glucose, called 18-fluoro-2-deoxyglucose (FDG) that accumulates within malignant cells because of their high rate of metabolism. The FDG injected patient is imaged on the whole body PET scanner in an effort to reveal tumours that may have been overlooked or difficult to characterise (as benign or malignant) by conventional computed tomography (CT), x ray, or magnetic resonance imaging (MRI).

The CT portion of a PET/CT provides detailed information about the location, size, and shape of tumours but offers less information that can be used to differentiate between cancerous and normal structures (compared to PET). The dual modality, PET/CT scanner fuses an image that puts form and function on the same diagnostic page.

Choroidal melanomas are the most common primary intraocular cancer in adults.¹ The Collaborative Ocular Melanoma Study (COMS) group and others have concluded that indirect ophthalmoscopy, combined with ophthalmic ultrasonography and fluorescein angiography, can yield a diagnostic accuracy rate greater than 99%.² However, strict selection criteria (patient and tumour specific) for COMS

eligibility were based on size and, secondly, on appearance, shape, location, internal ultrasonic reflectivity, and angiographic evidence of tumour leakage.² Though exhaustive, the diagnostic criteria employed by COMS did not include physiological imaging.²

The importance of early detection of malignant melanoma cannot be understated.^{3–7} Mathematical studies of tumour doubling time and the COMS small tumour trial suggest that metastasis from choroidal melanomas can occur while a small tumour is being observed as a “suspicious choroidal naevus.”^{4–5} Since COMS found that largest tumour dimension is significantly correlated with the risk of metastasis, it is reasonable to assume that a physiological assessment of tumour metabolism could help differentiate between suspicious choroidal naevi and small choroidal melanomas before growth.^{2–3}

In the last few years PET/CT has emerged as a new imaging modality for the detection and staging of cancer.⁸ Our study evaluates the efficacy of FDG-PET/CT imaging for the detection of primary choroidal melanomas, to assess their physiological activity and its relationship to tumour size.

METHODS AND MATERIALS

Patients

Since August of 2003, 50 consecutive patients with choroidal melanomas were evaluated by PET/CT before treatment (table 1). All patients had a clinical diagnosis confirmed by ophthalmoscopy, fluorescein angiography, and ophthalmic ultrasonography. Their initial metastatic investigation included liver function tests (γ -glutamyl transpeptidase, aspartate aminotransferase, alanine aminotransferase, alkaline phosphatase, bilirubin), a chest x ray and whole body FDG-PET/CT imaging. Informed consent and health insurance portability and accountability act (HIPAA) forms were obtained before treatment.

PET/CT protocol

PET/CT imaging required that patients refrain from eating a carbohydrate based dinner the previous night and to fast 4–6 hours before injection of 18-FDG. This diminished physiological glucose utilisation and reduced insulin serum levels to baseline. The normal fasting glucose level was optimally less than 110 mg/dl, but the acceptable range was 80 mg/dl to 160 mg/dl. The full body PET/CT scan began at the top of the head and ended at the bottom of the feet. The CT portion (General Electric Discovery ST, Piscataway, NJ, USA) with BGO (bismuth germanate) crystal consisted of a multi-detector helical CT scanner. The imaging parameters were 80–140 kV, 40–80 mA, 0.8 s per CT rotation, and a table speed of 33.75 mm/rotation. The CT slice thickness was 3.75 mm with an image interval of 3.27 mm. The CT

Abbreviations: AJCC, American Joint Cancer Committee; BGO, bismuth germanate; COMS, Collaborative Ocular Melanoma Study; CT, computed tomography; FDG, 18-fluoro-2-deoxyglucose; MRI, magnetic resonance imaging; PET, positron emission tomography; SUV, standardised uptake values

Table 1 Patients with uveal melanomas

Patient No	Age	Sex	Eye	Location	Tumour size (mm)			AJCC	COMS	PET/CT detection
					Width	Length	Height			
1	74	M	RE	4I	5.9	3	2.9	T2	medium	positive
2	69	F	LE	11P	13	11.5	3	T2	medium	positive
3	70	M	LE	9EP	14.9	9.9	3.2	T2	medium	positive
4	69	M	RE	12PE	13.5	11.5	4.5	T2	medium	positive
5	54	F	RE	6P	15.8	15.1	6	T2	medium	positive
6	65	F	RE	1E	14	13.8	7.3	T2	medium	positive
7	69	M	LE	9EA	16	14	8.2	T2	medium	positive
8	83	F	LE	12EA	14.9	14.1	8.6	T2	medium	positive
9	57	M	LE	6EP	16	14	11.5	T3	large	positive
10	88	F	LE	2EA	16.2	15.3	11.9	T3	large	positive
11	60	F	LE	230CB	15.5	14.5	12.2	T3	large	positive
12	65	M	LE	730EA	16.9	19.1	12.3	T3	large	positive
13	67	F	RE	9E	19	15.2	14	T3	large	positive
14	95	M	LE	ring melanoma				T3	large	positive
15	53	F	RE	430EP	8.8	8.2	1.6	T1	small	no
16	60	F	RE	CB	8.5	6.6	1.7	T1	small	no
17	66	M	LE	1PE	6.4	5.4	1.7	T1	small	no
18	46	F	RE	430E	7.9	7.4	1.8	T1	small	no
19	72	M	RE	5PE	5.7	4.3	1.8	T1	small	no
20	55	F	RE	2PE	9.5	9.1	2	T1	small	no
21	59	F	RE	7PE	6.1	7.9	2	T1	small	no
22	67	F	RE	2EP	8	6.8	2	T1	small	no
23	90	F	LE	5PE	5	4	2.1	T1	small	no
24	59	F	LE	PE	7.9	7.6	2.1	T1	small	no
25	53	F	RE	12EP	7.7	7	2.1	T1	small	no
26	70	F	RE	9EP	9.6	6.4	2.1	T1	small	no
27	60	F	LE	9PE	8	7.5	2.1	T1	small	no
28	65	M	RE	9EP	8.7	8.9	2.2	T1	small	no
29	57	F	LE	3PE	5	6	2.3	T1	small	no
30	54	F	RE	11EP	7.7	6.8	2.4	T1	small	no
31	87	F	RE	2EA	9	7.8	2.5	T1	small	no
32	56	F	LE	3EP	8.5	6.2	2.5	T1	small	no
33	43	M	LE	5CB	7	6.2	2.6	T2	medium	no
34	69	M	LE	6EP	16	13.4	2.7	T2	medium	no
35	75	F	LE	3EP	12	10.8	2.8	T2	medium	no
36	48	M	RE	6EP	8	8	2.9	T2	medium	no
37	76	M	LE	2EP	10	9.4	2.9	T2	medium	no
38	72	M	RE	11PE	7.1	6.4	3	T2	medium	no
39	73	M	RE	9EA	11	7	3	T2	medium	no
40	66	F	RE	7EP	9.3	8.1	3.4	T2	medium	no
41	67	M	LE	2EP	13.8	12.4	3.7	T2	medium	no
42	82	M	RE	6EP	11.8	11	4.1	T2	medium	no
43	76	F	LE	3EP	14.1	14	4.2	T2	medium	no
44	48	M	LE	3E	13.8	11.2	4.3	T2	medium	no
45	51	M	LE	430EP	11.8	8.3	4.8	T2	medium	no
46	48	M	LE	6E	13.7	11.3	6.3	T2	medium	no
47	39	F	LE	2EP	15.4	14.8	7.7	T2	medium	no
48	46	M	LE	11PE	12.1	10.1	8.3	T2	medium	no
49	46	F	RE	5CB	16	14	11.1	T3	large	no
50	48	F	LE	11E	14.5	12.2	13.7	T3	large	no

E, equator; P, posterior; A, anterior; I, iris; CB, ciliary body; AJCC, American Joint Cancer Committee; COMS, Collaborative Ocular Melanoma Study.

acquisition came before the PET emission acquisition, and the acquisition time was dependent on the dose of FDG and ranged from 19 seconds to 27 seconds. FDG was injected with a target dose of a 5 mCi (range 10 mCi to 20 mCi). The dose was calculated by (weight in kilograms × target dose in mCi)/70 kg. The FDG was injected via an intravenous line, followed by 10 ml of normal saline. Imaging began within 45 minutes of injection and ended no later than 1.5 hours after injection.

The resolution of the PET scan was 4 mm. The transmission time at each bed position was 2–3 minutes. Eight to nine bed positions were used. After each bed position, a 512 cm × 512 cm CT matrix was converted to a 128 cm × 128 cm matrix that was fed into the PET scan. The PET scan reconstructed the images on the fly and utilised the CT scan to correct for attenuation. Then, Xeleris (General Electric software, Piscataway, NJ, USA), a computer software, was used to fuse and display the PET and CT images to produce the final image. The images were graded positive when tracer uptake of 2.5 SUV (standardised maximum uptake value) or

more was observed in comparison with the surrounding structures. The SUV_{MAX} was calculated for each site using the conventional formula using body weight normalisation:

$$SUV = \frac{\text{Tissue activity } (\mu\text{Ci/ml})}{\text{Injected dose (mCi) / Body weight (kg)}}$$

RESULTS

Fifty patients (22 males and 28 females) with a mean age of 64 years (range 39–95) and a clinical diagnosis of choroidal melanoma underwent full body PET/CT scans (table 1). Our study included 27 melanomas of the left eye and 23 melanomas of the right. One of the melanomas was classified as a ring melanoma, and of the 49 remaining, the mean width, length, and height of the uveal melanomas were 11.16 mm (range 5–19), 9.87 mm (range 3–19.1), and 4.78 mm (range 1.6–14), respectively.

Table 2 PET/CT detection of uveal melanoma (AJCC/COMS classification)

Tumour size (AJCC/COMS)	Total number of patients	Number of patients detected (AJCC)	Number of patients detected (COMS)
T1/small	18	0 (0%)	0 (0%)
T2/medium	24	8 (33%)	8 (33%)
T3/large	8	6 (75%)	6 (75%)

The analysis of PET/CT scans showed tumour uptake in 14 (28%) patients. There were seven males, seven females, and their mean age was 70 years (range 54–95). The mean width of the lesions identified by PET/CT, excluding the ring melanoma, was 14.7 mm (range 5.9–19), the mean length was 13.2 mm (range 3–19.1), and the mean height was 8.1 mm (range 2.9–14). The PET/CT detected none of the American Joint Committee on Cancer (AJCC) T1 staged melanomas (table 2). The PET/CT detected 33% of the AJCC T2 tumours and 75% of the AJCC T3 tumours. No small choroidal tumours (fig 1) as classified by COMS were detected by PET/CT (table 2). Thirty three per cent of medium sized melanomas (fig 2) and 75% of large tumour (fig 3) PET/CT scans showed tumour uptake (figs 4 and 5). The smallest tumour detected by PET/CT imaging was 3×5.9 mm in base and 2.9 mm in height.

DISCUSSION

With the introduction of positron emission tomography in the 1960s, and its growing importance in clinical practice within the past decade, various studies addressed the question whether PET imaging can be used to diagnose and

stage malignant choroidal melanomas. A prospective study by Spraul *et al* concluded that FDG-PET alone was not a sensitive procedure for the diagnosis of choroidal melanomas since only two out of their four cases were visualised.⁹ Similarly, PET alone detected three of 12 uveal melanomas in one study and another reported only seven of 20.^{10 11} However, in the past few years, the PET/CT fusion scanners are helping bring molecular imaging to the forefront of cancer diagnosis.¹² A modern PET/CT scanner combines the metabolic/physiological findings of PET with the anatomic localisation/characterisation of CT.

PET/CT increases the accuracy and confidence in judging whether a tumour is malignant.¹³ This has been shown for colorectal cancer as well as primary head and neck malignancies.^{14 15} In addition, PET/CT has eliminated the need for a full dose diagnostic CT to correlate inconclusive findings demonstrated by PET alone.¹⁵ In addition, examination times have been reduced by 30% (compared to conventional PET imaging) because PET attenuation correction can now be based on the CT data. This eliminates the need for separate transmission scanning.¹⁵ Compared with PET alone, PET/CT is also superior because it anatomically

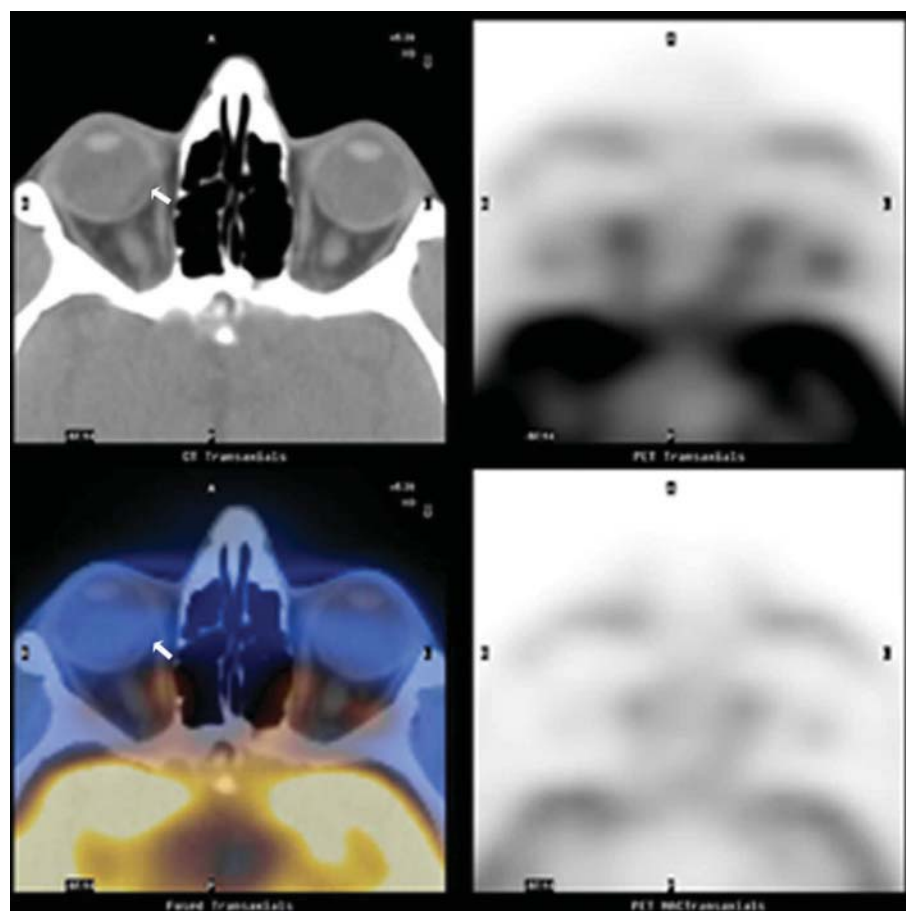


Figure 1 Patient 20. PET/CT image of a patient with an AJCC-T1 (COMS small) 9.1×9.5×2 mm choroidal melanoma (arrow at tumour location). No FDG uptake was detected on PET and CT could not visualise the small tumour in the right eye.

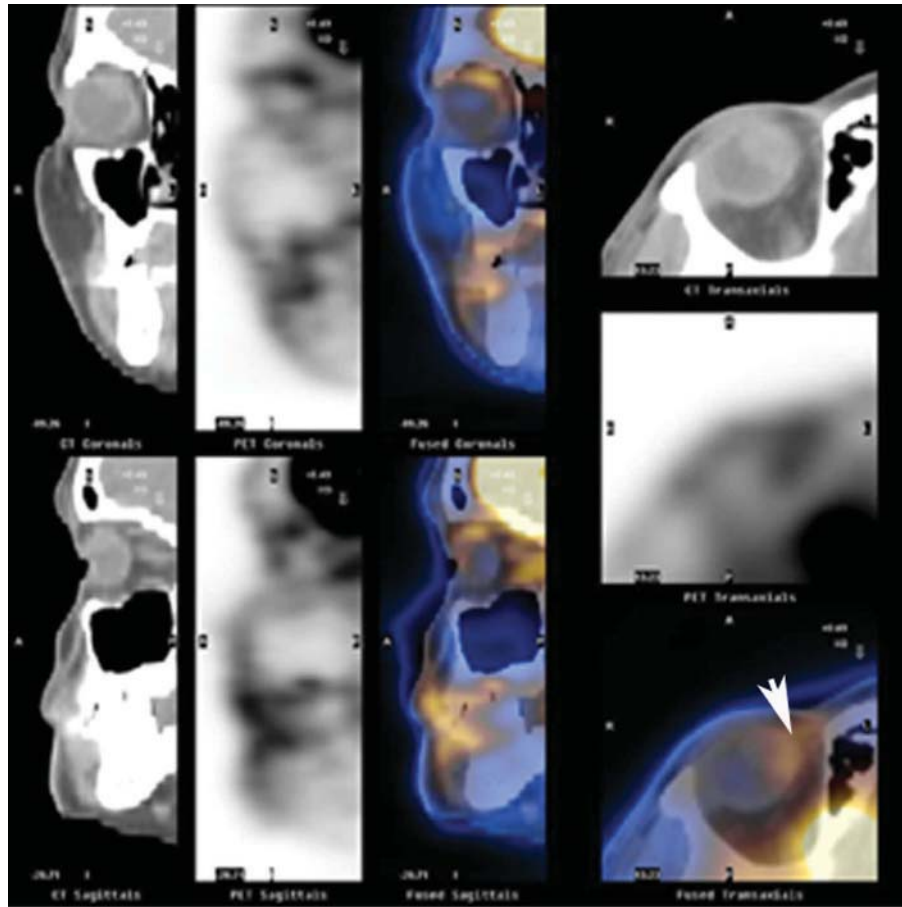


Figure 2 Patient 6. An AJCC-T2 (COMS medium) 13.8×14×7.3 mm choroidal melanoma was detected on PET/CT imaging in the right eye (arrow). There was increased FDG uptake and CT localised the uveal tumour.

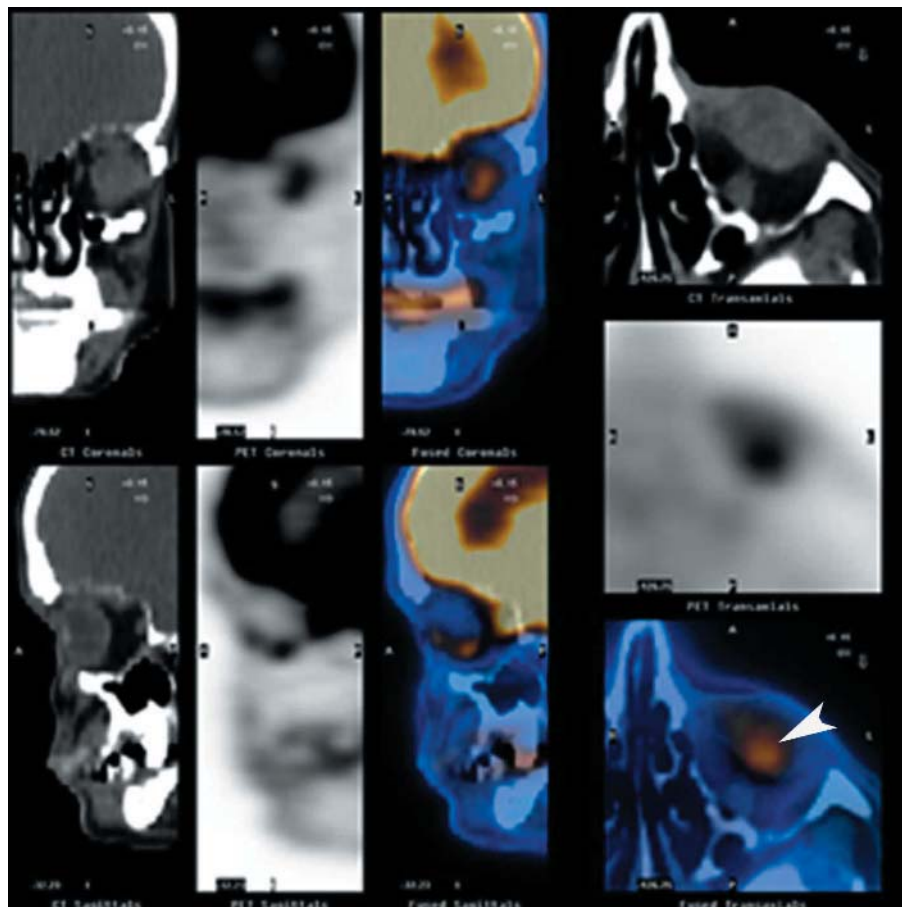


Figure 3 Patient 9. PET/CT imaging detected an AJCC-T3 (COMS large) 14×16×11.5 mm choroidal melanoma (COMS/AJCC) in the left eye (arrow).

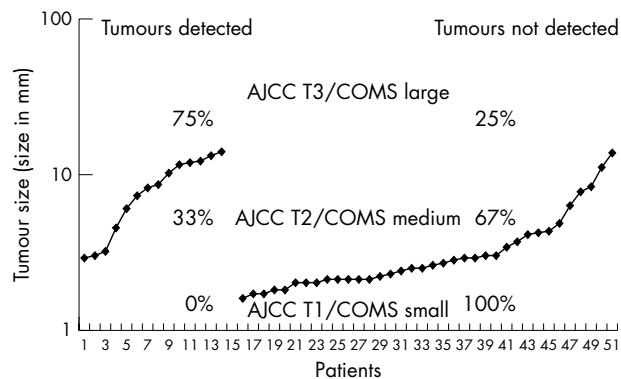


Figure 4 PET/CT detection of ocular melanoma.

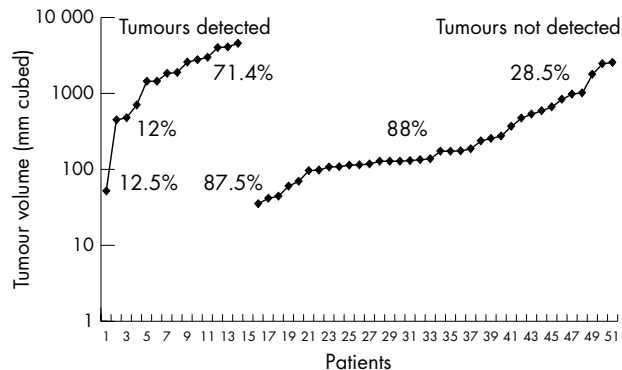


Figure 5 PET/CT detection of ocular melanoma.

locates the melanoma and thereby increases the confidence that it is the tumour that is being characterised by FDG uptake.

In our study, neither AJCC-T1 uveal tumours nor small COMS choroidal melanomas were identified by PET/CT. Therefore, it is unlikely that PET/CT can be used to differentiate between small choroidal melanomas and suspicious choroidal naevi (at this time). Furthermore, 63% of T2 tumours and 69% of small choroidal tumours (that went undetected) were larger than the 4 mm resolution of our scanner. This suggests that high metabolic activity was integral to making a tumour identifiable. PET/CT was most effective in detecting the physiological activity of AJCC-T3 and large choroidal melanomas. Age, sex, or tumour location did not appear to affect SUV value.

This study did not examine if the metabolic activity revealed by PET/CT correlated with tumour metastasis. This study did not find PET/CT to be a more accurate method to diagnose intraocular choroidal melanoma (compared to standard clinical evaluations). This study clearly demonstrated that current FDG-PET/CT technology can reveal metabolic activity of choroidal melanomas, that there appears to be significant variability among melanomas of different sizes, and that further research will define the role of PET/CT in ophthalmic oncology.

Authors' affiliations

S Reddy, M Kurli, L B Tena, P T Finger, The New York Eye Cancer Center, New York, NY, USA
M Kurli, L B Tena, P T Finger, The New York Eye and Ear Infirmary, New York, NY, USA
S Reddy, P T Finger, New York University School of Medicine, New York, NY, USA
L B Tena, P T Finger, The Saint Vincent's Comprehensive Cancer Center, New York, NY, USA
L B Tena, New York Medical College, New York, NY, USA

This research was supported by The EyeCare Foundation, Inc, and Research to Prevent Blindness, New York, NY, USA

Competing interests: none declared

Correspondence to: Paul T Finger, MD, FACS, The New York Eye Cancer Center, 115 East 61st Street, New York City, NY 10021, USA; pfinger@eyecancer.com

Accepted for publication 1 March 2005

REFERENCES

- Egan KM, Seddon JM, Glynn RJ, *et al*. Epidemiological aspects of uveal melanoma. *Surv Ophthalmol* 1988;**32**:239-51.
- Collaborative Ocular Melanoma Study Group. Accuracy of diagnosis of choroidal melanomas in the Collaborative Ocular Melanoma study. *Arch Ophthalmol* 1990;**108**:1268-73.
- Diener West M, Reynolds SM, Agugliaro DJ, *et al*. Screening for metastasis from choroidal melanoma: the Collaborative Ocular Melanoma Study Group Report 23. *J Clin Oncol* 2004;**22**:2438-44.
- Ehner VM, Flint A, Vine AK. Histopathology of documented growth in small melanocytic choroidal tumors. *Arch Ophthalmol* 2004;**122**:1876-8.
- Eskelin S, Pyrhonen S, Summanen P, *et al*. Tumor doubling times in metastatic malignant melanoma of the uvea. Tumor progression before and after treatment. *Ophthalmology* 2000;**107**:1443-9.
- Eskelin S, Kivela T. Uveal melanoma: implications of tumor doubling time. *Ophthalmology* 2001;**108**:830-1.
- Finger PT. Radiation therapy for choroidal melanoma. *Surv Ophthalmol* 1997;**42**:215-232.
- Townsend D, Carney J, Yap J, *et al*. PET/CT today and tomorrow. *J Nucl Med* 2004;**45**(Suppl 1):4S1-14S.
- Spraul CW, Lang GE, Lang GK. Value of positron emission tomography in the diagnosis of malignant ocular tumors. *Ophthalmologica* 2001;**215**:163-8.
- Lucignani G, Paganelli G, Madorati G, *et al*. MRI, antibody-guided scintigraphy, and glucose metabolism in uveal melanoma. *J Comp Ass Tomogr* 1992;**16**:77-83.
- Madorati G, Lucignani G, Landoni C. Glucose metabolism and pathological findings in uveal melanoma: preliminary results. *Nucl Med Comm* 1996;**17**:1052-6.
- Beyer T, Townsend DW, Brun T, *et al*. A combined PET/CT scanner for clinical oncology. *J Nucl Med* 2000;**41**:1369-79.
- Cohade C, Osman M, Leal J, *et al*. Direct comparison of 18F-FDG PET and PET/CT in patients with colorectal carcinoma. *J Nucl Med* 2003;**44**:1797-803.
- Goerres G, Schulthess G, Steinert H. Why most PET of lung and head-and-neck cancer will be PET/CT. *J Nucl Med* 2004;**45**(Suppl 1):66S-71S.
- Von Schilthess GK. Cost consideration regarding an integrated CT-PET system. *Eur Radial* 2000;**10**(suppl 3):S377-S380.



PET/CT imaging: detection of choroidal melanoma

S Reddy, M Kurli, L B Tena, et al.

Br J Ophthalmol 2005 89: 1265-1269

doi: 10.1136/bjo.2005.066399

Updated information and services can be found at:

<http://bjo.bmj.com/content/89/10/1265.full.html>

References

These include:

This article cites 12 articles, 5 of which can be accessed free at:

<http://bjo.bmj.com/content/89/10/1265.full.html#ref-list-1>

Article cited in:

<http://bjo.bmj.com/content/89/10/1265.full.html#related-urls>

Email alerting service

Receive free email alerts when new articles cite this article. Sign up in the box at the top right corner of the online article.

Notes

To request permissions go to:

<http://group.bmj.com/group/rights-licensing/permissions>

To order reprints go to:

<http://journals.bmj.com/cgi/reprintform>

To subscribe to BMJ go to:

<http://group.bmj.com/subscribe/>