

# PostScript

## LETTERS

### Bevacizumab suppresses choroidal neovascularisation caused by pathological myopia

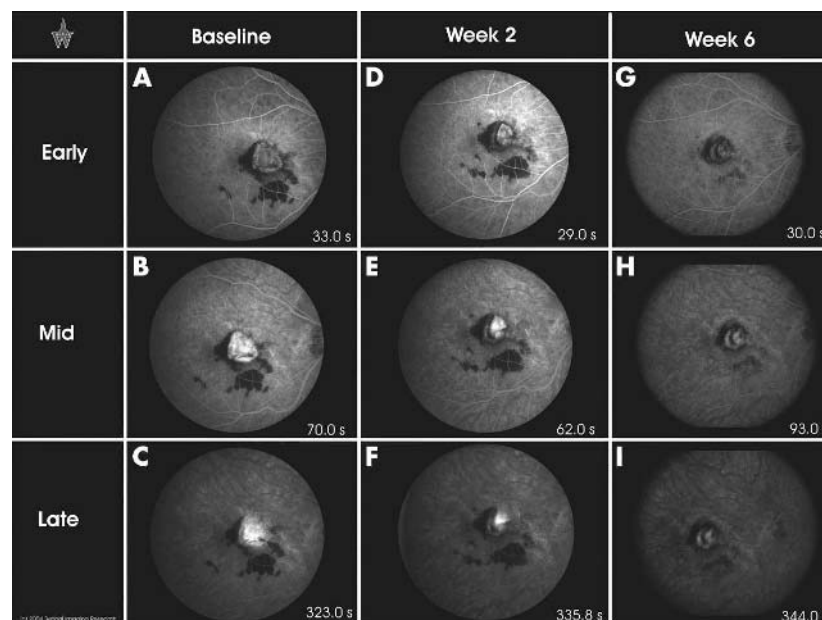
Bevacizumab (Avastin, Genentech) is a recombinant humanised, full length, anti-VEGF monoclonal antibody that binds all isoforms of VEGF-A. It has been shown to prolong survival of patients with advanced colon cancer when combined with 5-fluorouracil.<sup>1</sup> In this report, we describe the effect of bevacizumab in two patients with choroidal neovascularisation (CNV) secondary to pathological myopia, which was refractory to other treatment.

#### Case reports

##### Patient 1

AM is a 36 year old white man who was diagnosed with subfoveal CNV caused by pathological myopia (right eye = -11.50 D, left eye = -11.50 D) in his left eye in September 2002 for which he received three photodynamic therapy (PDT) treatments. He developed subfoveal CNV in his right eye in June 2003 and received one PDT treatment combined with an intravitreal injection of 4 mg of triamcinolone acetonide. In May 2004, he presented with recurrent subfoveal CNV in his right eye and refused PDT. Off-label use of bevacizumab was discussed and after informed consent, the patient decided to proceed.

Just before treatment in July 2004, best corrected visual acuity (VA) was 20/40 in the right eye and 20/25 in the left eye. There was a ring of hyperpigmentation centred on the fovea with a surrounding ring of subretinal blood and substantial subretinal fluid in the right eye (fig 1A). An optical coherence tomography (OCT) scan through the centre of the fovea confirmed the presence of

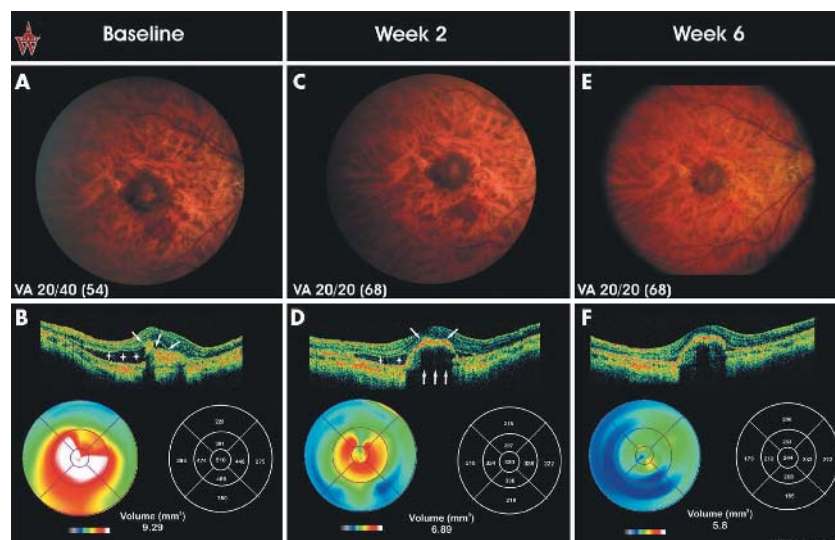


**Figure 2** Fluorescein angiography of patient 1 at baseline and after starting infusions of bevacizumab.

extensive subretinal fluid (fig 1B, asterisks) with subretinal tissue in the centre of the fovea (arrowheads). An OCT map showed severe thickening and subretinal fluid throughout the centre of the macula (foveal thickness 510  $\mu\text{m}$ , macular volume 9.29  $\text{mm}^3$ ). In the left eye, there were pigmentary changes and no subretinal blood or fluid (foveal thickness, 201  $\mu\text{m}$ ). In the right eye, the early phase of a fluorescein angiography (FA) scan showed a central area of hyperfluorescence surrounded by blocked fluorescence from subretinal blood (fig 2A). Central fluorescence increased in the mid

phase (fig 2B) and in the late phase the area of hyperfluorescence was larger with indistinct borders indicating leakage of dye into surrounding tissue (fig 2C).

The patient received an intravenous infusion of 5 mg/kg of bevacizumab, which he tolerated well. He noted subjective improvement in vision in both eyes within 7 days and 2 weeks after the infusion, VA was 20/20 in both eyes and biomicroscopy showed less subretinal fluid (fig 1C), confirmed by OCT (fig 1D, asterisk). Compared to the pre-infusion OCT, the retinal thickness map showed substantial improvement with a decrease in foveal thickness (330  $\mu\text{m}$  from 510  $\mu\text{m}$ ) and macular volume (6.89  $\text{mm}^3$  from 9.29  $\text{mm}^3$ ). In the early phase of a FA in the right eye (fig 2D), the hyperfluorescent area was reduced compared to a corresponding frame of the baseline FA (fig 2A). The intensity of hyperfluorescence increased between the early and mid phase (fig 2E) and there was evidence of dye leakage from the CNV during the late phase (fig 2F). The patient received second and third infusions of 5 mg/kg of bevacizumab without any difficulty. Six weeks after the first infusion, VA was 20/20 in each eye and biomicroscopy showed no identifiable subretinal fluid in the right eye and resorption of almost all of the subretinal blood (fig 1E). OCT confirmed that there was no subretinal fluid (fig 1F) and the retinal thickness map showed further improvement compared to the map after the first infusion. Foveal thickness measured 244  $\mu\text{m}$  and macular volume was 5.80  $\text{mm}^3$ . Early phase of the FA showed further reduction in the area of hyperfluorescence (fig 2G) compared to a corresponding frame of the FA done after the first infusion (fig 2D). There was only a mild increase in brightness of the hyperfluorescent area in the mid phase of the FA



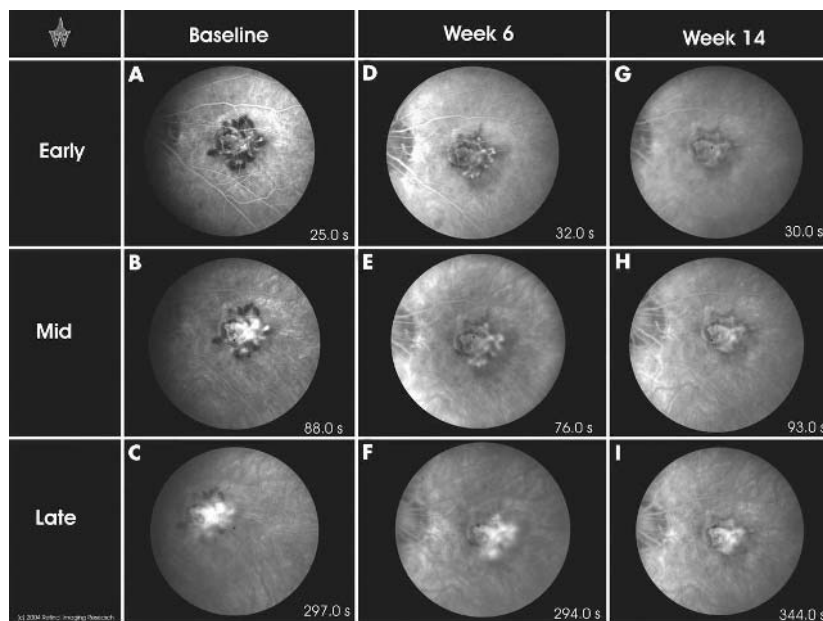
**Figure 1** Fundus appearance and optical coherence tomogram of patient 1 at baseline and after starting infusions of bevacizumab.

(fig 2H) and sharp borders with no further increase in brightness in the late phase (fig 2I). This indicates that there was little collection of dye within the CNV and no leakage into surrounding tissue—two favourable signs. Nine months after the fourth infusion, the patient was asymptomatic and visual acuity was 20/20 in each eye. FA showed no evidence of leakage in either eye.

**Patient 2**

LL is a 52 year old white woman with pathological myopia (refractive error  $-17.75$  sphere and  $-18.75 + 0.75 \times 165$ ). The left eye developed subfoveal CNV in February 2002 and the patient had six PDT treatments with the last in January 2004. The right eye developed juxtafoveal CNV and was treated with photocoagulation in April 2002. Recurrent CNV occurred beneath the fovea and was treated with PDT on two occasions, the most recent in January 2004.

The patient presented in July of 2004 complaining of progressive loss of vision in both eyes. Visual acuity was 20/100 in the right eye and 20/200 in the left eye. In the right eye, there was a laser scar between the disc and the nasal border of the fovea. There were flecks of subretinal haemorrhage and mild subretinal fluid. In the left eye there was hypopigmentation surrounded by a ring of hyperpigmentation with subretinal fluid, blood, and thickening in the macula (fig 3A). OCT in the left eye showed prominent retinal thickening surrounding a small central area of retinal atrophy (fig 3B, arrow). The retinal thickness map showed the thickest region of the retina to be located on the inferotemporal side of the fovea. Foveal thickness was  $311 \mu\text{m}$  and macular volume was  $7.30 \text{ mm}^3$ . In the right eye, OCT showed retinal thinning in the region of the laser scar inferonasal to the fovea (fig 3C, arrows), and thickening superotemporal to the fovea with a pocket of subretinal fluid (asterisk). Foveal thickness was  $296 \mu\text{m}$  and macular volume was  $5.91 \text{ mm}^3$ . There was subfoveal CNV in both eyes, and it was decided to treat the left eye because there



**Figure 4** Fluorescein angiography of patient 2 at baseline and after starting infusions of bevacizumab.

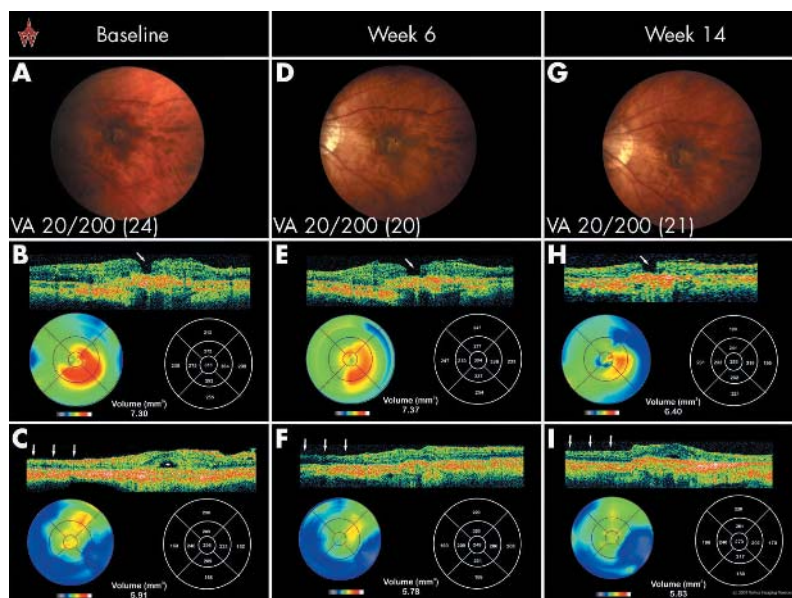
was more retinal thickening in the left eye. The early phase of the FA showed a central area of hyperfluorescence and surrounding blocked fluorescence from subretinal blood (fig 4A). The hyperfluorescence became much brighter during the mid phase of the FA (fig 4B) and leaked during the late phase (fig 4C). The patient refused additional PDT and after careful consideration of potential risks and benefits and signing a consent form, the patient was given four intravenous infusions of 5 mg/kg of bevacizumab at intervals of 2 weeks, which she tolerated well.

Examination before the fourth infusion showed a VA of 20/64 in the right eye and 20/

200 in the left eye. Biomicroscopy in the left eye showed reduced subretinal blood compared to the baseline examination, but persistent macular thickening (fig 3D) confirmed by OCT, which showed a foveal thickness of  $304 \mu\text{m}$  and a macular volume of  $7.37 \text{ mm}^3$ . In the right eye, there was mild residual subretinal fluid and a few flecks of subretinal blood temporal to the laser scar. OCT in the right eye showed reduced retinal thickening and minimal subretinal fluid with foveal thickness of  $249 \mu\text{m}$  and a macular volume of  $5.78 \text{ mm}^3$  (fig 3F). In the left eye, early phase of a FA (fig 4D) showed a similar area of hyperfluorescence as that seen in the early phase of the baseline FA (fig 4A), but substantially less fluorescence during the mid (fig 4E) and late (fig 4F) phases than the corresponding phases of the baseline FA, indicating less filling of the CNV with dye. There was still substantial leakage of dye into surrounding tissue in the late phase (fig 4F). The patient returned 2 months after the fourth infusion noting subjective visual improvement that had allowed her to resume many activities that she had previously stopped. VA was 20/64 in the right eye and 20/200 in the left. Contact lens biomicroscopy in the left eye showed no identifiable subretinal blood or fluid, and macular thickness appeared reduced (fig 3G). This was confirmed by OCT (fig 3H; foveal thickness  $253 \mu\text{m}$ , macular volume  $6.40 \text{ mm}^3$ ). In the right eye, there was no identifiable subretinal blood or fluid and OCT showed no changes from the scan at week 6. FA in the left eye showed reduced hyperfluorescence compared to previous FAs at all phases, early (fig 4G), mid (fig 4H), and late (fig 4I), and no leakage.

**Comment**

In two patients, intravenous infusions of bevacizumab resulted in reduced fluorescein angiographic evidence of leakage from CNV and decreased retinal thickening and subretinal fluid. This anatomical evidence of



**Figure 3** Fundus appearance and optical coherence tomogram of patient 2 at baseline and after starting infusions of bevacizumab.

improvement was accompanied by visual improvement in two of the three eyes in which there was active subfoveal CNV at baseline. The one eye that did not show objective evidence of visual improvement had prominent subretinal fibrosis and a central area of retinal atrophy at baseline. Although spontaneous improvement cannot be ruled out with certainty, the course of these two patients suggests that antagonism of VEGF with bevacizumab provided benefit. No ocular or systemic side effects were observed.

Recent studies have suggested that VEGF may be an important stimulus for neovascular age related macular degeneration (AMD).<sup>2,3</sup> Despite differences in pathogenesis among the disease processes, the effect of bevacizumab in the two patients reported here suggests that VEGF may be an important stimulus for CNV in pathological myopia as well as AMD. While uncontrolled observations in two patients do not justify widespread use of bevacizumab in patients with CNV, additional studies are warranted. A controlled clinical trial is needed to determine if bevacizumab is safe and effective in patients with subfoveal CNV caused by pathological myopia and, if so, to determine the appropriate frequency of administration.

**Q D Nguyen, S Shah, S Tatlipinar, D V Do, E V Anden, P A Campochiaro**

Department of Ophthalmology, Johns Hopkins University School of Medicine, 600 North Wolfe Street, Baltimore, MD, USA

Correspondence to: Peter A Campochiaro, MD, Maumenee 719, Wilmer Eye Institute, Johns Hopkins University School of Medicine, 600 North Wolfe Street, Baltimore, MD 21287-9277, USA; [pcampo@jhmi.edu](mailto:pcampo@jhmi.edu)

doi: 10.1136/bjo.2005.066431

Accepted for publication 14 January 2005

## References

- Hurwitz H, Fehrenbacher L, Novotny W, et al.** Bevacizumab plus irinotecan, fluorouracil, and leucovorin for metastatic colorectal cancer. *N Engl J Med* 2004;**350**:2335–42.
- Gragoudas ES, Adamis AP, Cunningham ET Jr, et al.** Pegaptanib for neovascular age-related macular degeneration. *N Engl J Med* 2004;**351**:2805–16.
- Schwartz SD, Blumenkranz M, Rosenfeld PJ, et al.** Safety of rhuFab V2, an anti-VEGF antibody fragment, as a single intravitreal injection in subjects with neovascular age-related macular degeneration. *Invest Ophthalmol Vis Sci (suppl)* 2001;**42**:S522.

## Compliance: clear communication's critical

Non-compliance can be subdivided into voluntary and involuntary types. Voluntary non-compliance is patients deciding not to use their medication. Involuntary non-compliance refers to situations where medications are used incorrectly, such as eye drops missing the conjunctival sac, using incorrect medication, or following an incorrect regime. The impact of non-compliance is particularly important for patients with chronic diseases such as glaucoma.<sup>1</sup>

We collected data from patients in our clinic to try to ascertain the frequency and nature of any discrepancies between the drop regimes patients were using and what their notes said their current regimes should be.

## Methods

One hundred consecutive patients using topical medication to lower intraocular pressure attending a UK teaching hospital's glaucoma service clinics were asked which drops they were using and how often they put them in. Each patient was only entered into the study once. If any deviation from the drop regime described in their notes was identified then further questioning was used to identify the cause of that discrepancy.

## Results

In total, 30 of the 100 patients were not using the antiglaucoma medication as described in their notes. Eighteen cases were caused by ophthalmologists either changing a regime without informing the general practitioner or not giving clear instructions to the patient. Examples include transcription errors by the ophthalmologist when dictating the letter to the general practitioner (four cases), patients stopping treatments because of side effects without contacting clinic (four cases), patients stopping their glaucoma drops after cataract surgery (three cases), and ambiguity between Xalatan and Xalacom (one case).

Patient error can be attributed to nine cases. Examples include patient using drops less frequently than prescribed (three cases), patient using drops in the wrong eye or one eye only (two cases), patients changing the dose frequency of their own accord (one case), and using drops too frequently (one case).

The other three cases were the result of "unreliable" nursing home staff (two cases), and failure to prescribe eye drops on admission to a general medical ward.

## Comment

Ophthalmologists communicating poorly with patients or with general practitioners caused nearly one in five patients to use the wrong regime. The responsibility for ensuring that all communication between the ophthalmologist and patients or general practitioners is intelligible and unambiguous lies with the ophthalmologist.

One frequent cause of non-compliance is newly diagnosed patients thinking that the initially prescribed bottle is the full course of treatment, and ceasing treatment when this bottle expires. This is a well recognised phenomenon on the literature on persistency with treatment for glaucoma.<sup>2</sup>

We were alarmed that 30% of the sample were using an incorrect drop regime. Involuntary non-compliance merits further research and poses a considerable threat to the control of patients' disease. Furthermore, failure to identify compliance as the cause of a patient's apparent lack of response to treatment may result in prescription of more toxic medication, and increasingly complex drop regimes, which can lead to further compliance problems.<sup>3</sup>

**A J Buller, B Connell, A F Spencer**

Manchester Royal Eye Hospital, Manchester, UK

Correspondence to: A J Buller, Manchester Royal Eye Hospital, Oxford Road, Manchester M13 9WH, UK; [alexbuller@mac.com](mailto:alexbuller@mac.com)

doi: 10.1136/bjo.2005.066175

Accepted for publication 9 January 2005

## References

- Schwartz GF.** Persistency and tolerability of ocular hypotensive agents: population-based evidence in the management of glaucoma. *Am J Ophthalmol* 2004;**137**(Suppl):S1–S2.
- Reardon G, Schwartz GF, Mozaffari E.** Patient persistency with topical ocular hypotensive therapy in a managed care population. *Am J Ophthalmol* 2004;**137**(Suppl):S3–S12.
- MacKean JM, Elkington AR.** Compliance with treatment of patients with chronic open-angle glaucoma. *Br J Ophthalmol* 1983;**67**:46–9.

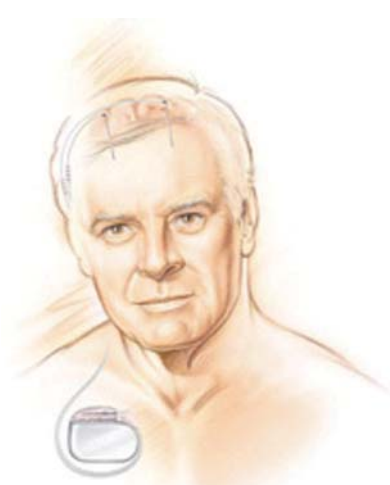
## Safety of phacoemulsification in a patient with an implanted deep brain neurostimulation device

A 69 year old woman with nuclear sclerotic cataracts was examined. She was awaiting neurosurgery for treatment of drug refractory titubation (head tremor). Before cataract surgery, she underwent successful neurosurgery. The implanted Medtronic deep brain stimulation device rendered her asymptomatic of tremors. At the cataract preoperative clinic she showed the device identification card that stated "ultrasound diathermy ... anywhere on your body ... can result in severe injury or death."<sup>1</sup> Following confirmation from Medtronic that it was safe to proceed, the patient had an uneventful left phacoemulsification performed under general anaesthesia with the neurostimulator turned "off." Seven months later she underwent a similar successful right phacoemulsification.

## Comment

Deep brain neurostimulation of the thalamus is the treatment of choice for drug refractory essential tremor.<sup>2</sup> Indications for its use are widening and include use in multiple sclerosis, advanced Parkinson's disease, and movement disorders such as dystonia.<sup>3</sup> The deep brain neurostimulator has three implanted components. The electrodes are implanted into the subthalamic nucleus or the globus pallidus interna,<sup>1,2,4</sup> then an insulated lead is placed subcutaneously from the burr hole to a sealed neurostimulator device beneath the clavicle. The neurostimulator electrical stimulation pulses can be adjusted from external devices.<sup>4</sup>

There are two recorded fatalities in patients with implanted deep brain neurostimulation



**Figure 1** Implanted deep brain neurostimulation device.

devices who had received short wave diathermy "as used by physiotherapists."<sup>3</sup> Medtronic also report two similar patients who were still comatose.<sup>1</sup> Another report described permanent, severe central nervous system injury following stimulation of a spinal cord neurostimulator by a radiofrequency antitheft device.<sup>6</sup>

Brain damage results from heating of the implanted electrodes.<sup>7</sup> Heat energy released directly to the body from an external source can be conducted via the insulated lead of an implanted neurostimulation device, raising the temperature at the electrode. Furthermore, if an external source generates an electric current in the insulated lead, this will result in a rise in the temperature at the electrode. Ultrasound diathermy transfers heat directly to the body where short wave diathermy results in an induced electrical current.<sup>8</sup> One study calculated a potential rise of 9.76°C at the deep brain neurostimulator electrode when short wave diathermy was used.<sup>9</sup> For phacoemulsification to be safe in patients with deep brain neurostimulators, it must not produce significant heat or generate an electric current.

The phacoemulsification hand piece uses the piezoelectric effect to drive the phacoemulsification needle tip in a linear jackhammer-like movement, physically cutting the lens.<sup>9</sup> Acoustic cavitation results from an explosive collapse of vacuoles formed in fluid around the swiftly moving phacoemulsification needle tip.<sup>9</sup> A study showed a maximum temperature rise of 3.5°C in the anterior chamber during routine phacoemulsification.<sup>10</sup> The risk of this generated heat spreading to the implanted electrodes must be low. The phacoemulsification tip does not generate an oscillating magnetic field that might induce an electrical current. Theoretically, this should render ultrasound phacoemulsification safe in the presence of implanted deep brain neurostimulators.

With expanding technology, there will naturally be situations with the potential for interactions between equipment from different specialties. Consent should include the possibility of heat conduction to the implanted neurostimulation device. The use of local anaesthesia may allow early detection of discomfort or neurological sequelae. The surgeon should make use of all techniques to reduce the heat generated during phacoemulsification. Medtronic advise turning the neurostimulator off and not placing any cables over the patient's chest and neck (R Coffey, 3 February 2005, personal communication). There are various neurostimulators, including cortical devices, that may have increased sensitivity to localised temperature increases. Heat formation at the phacoemulsification needle tip has been analysed; however, further research on the extent of heat dissipation is required.

**C F Parsloe, J M Twomey**  
Musgrove Park Hospital, Taunton, Somerset

Correspondence to: Mr J M Twomey, Musgrove Park Hospital, Taunton TA1 5DA, Somerset, UK; john.twomey@tst.nhs.uk

doi: 10.1136/bjo.2005.066209

Accepted for publication 21 February 2005

## References

- 1 **Medtronic.** Important safety information. [www.medtronic.co.uk/UK/patients/neuro/safety\\_information.html](http://www.medtronic.co.uk/UK/patients/neuro/safety_information.html), accessed 4 January, 2005.
- 2 **Gross RE, Lozano AM.** Advances in neurostimulation for movement disorders. *Neurol Res* 2000;**22**:247–58.
- 3 **Joshua A, Bryant B, et al.** The impact of thalamic stimulation on activities of daily living for essential tremor. *Surg Neurol* 2003;**59**:479–85.
- 4 **Medtronic.** What is deep brain stimulation? [www.medtronic.co.uk/UK/patients/neuro/brain\\_stimulation.html](http://www.medtronic.co.uk/UK/patients/neuro/brain_stimulation.html), accessed 4 January, 2005.
- 5 **Medicines and Healthcare Products Regulatory Agency.** Patients with active/powered implants: risk of serious injury from therapeutic diathermy treatment. [www.medical-devices.gov.uk/mda/mdawebsitev2.nsf/webvwIndex/3FE48E06AB1F64F200256AB6003F1C6D?OPEN](http://www.medical-devices.gov.uk/mda/mdawebsitev2.nsf/webvwIndex/3FE48E06AB1F64F200256AB6003F1C6D?OPEN), accessed 4 January, 2005.
- 6 **Eisenberg E, Waisbrod H.** Spinal cord stimulator activation by an antitheft device. *J Neurosurg* 1997;**87**:961–2.
- 7 **Ruggera PS, Witters DM, et al.** In vitro assessment of tissue heating near metallic medical implants by exposure to pulsed radio frequency diathermy. *Phys Med Biol* 2003;**48**:2919–28.
- 8 **Anderson DM, ed.** *Dorland's illustrated medical dictionary*. Philadelphia: WB Saunders, 2000.
- 9 **Dondrea CL, ed.** *Surgery for cataract*. In: *Basic and clinical science course*. San Francisco: American Academy of Ophthalmology, 2004:89–162.
- 10 **Heisler JM, Barmbek AK, et al.** In vivo measurement of the temperature changes during phacoemulsification. *Ophthalmology* 2002;**99**:448–56.

## Vertical deviation exacerbated by convergence and accommodation

We report a patient with hypertropia causing diplopia exacerbated by convergence and accommodation.

## Case report

A 36 year old man presented with 8 year history of worsening intermittent double vision. Visual acuities were 6/5 in each eye. For near there was manifest left hypertropia and left hyperphoria at distance (fig 1A, table 1). Extraocular movements were full with no overactions. No significant difference in vertical deviation in different gaze positions or cyclotropia was found, the deviation increased on head tilt to the left (table 2). There was no dissociated vertical deviation.<sup>1</sup> The angle of deviation varied between 2 and 7 prism dioptres at distance and 24 and 45 prism dioptres at near on repeated examinations. Stereovision was 55 seconds of arc when deviation was prism corrected. The AC/A ratio was normal using gradient method. The vertical fusion range was 13 prism dioptres at distance (9 prism dioptres base-down and 4 prism dioptres base-up).

The vertical deviation increased on accommodation with concave lenses and the deviation decreased with 10 dioptre base-in prisms at near (table 1). Eye movement recordings are shown in figure 1C. Pupil reactions and funduscopy were unremarkable. Thyroid functions, thyroid peroxidase and acetylcholine receptor antibodies were normal. Tensilon test was negative. Orbicularis oculi muscle single fibre electromyogram was unremarkable. Neurological examination and magnetic resonance imaging of the brain and orbits were normal.

## Comment

Klein-Scharff and Kommerell<sup>2</sup> first reported three patients with hypotropia and two with

**Table 1** Angle of deviation on fixation at distance and near measured with the alternating prism cover test

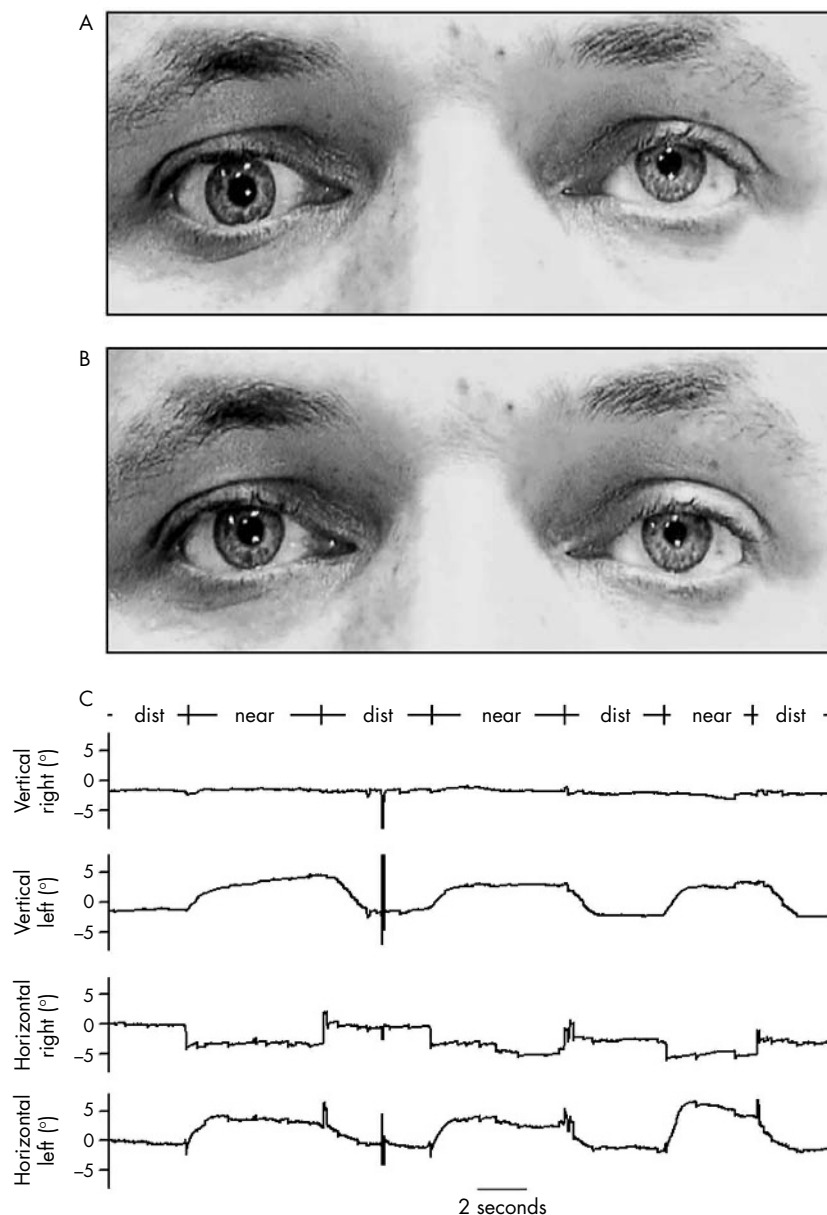
At 6 metres	5 prism dioptres L/R*
At 6 metres with -1D lens	8 prism dioptres L/R
At 6 metres with -2D lens	14 prism dioptres L/R
At 6 metres with -3D lens	25 prism dioptres L/R
At 33 cm	30 prism dioptres L/R
At 33 cm with +3D lens	30 prism dioptres L/R
At 33 cm with 10 prism dioptres base in	15 prism dioptres L/R

\*Left over right

**Table 2** Harms Wall measurements in nine directions of gaze (upper panel) and head tilt to the right and left in primary position (lower panel) with left fixation

Left fixation (red filter over left eye)						
		Elevation				
	+2 0	14 L/R	+1 0	12 L/R	+4 0	17 L/R
Left	+2 2 Ex	17 L/R	+4 0	15 L/R	+4 2 int	15 L/R
	+3 2 Ex	15 L/R	+5 0	14 L/R	+5 0	14 L/R
		Depression				
Left fixation						
		R tilt	L tilt			
	+14 0	9 L/R	-7 0	20 L/R		

For each direction of gaze the first number indicated the horizontal deviation (ie, +2 = 2 degrees esotropia), the second measurement indicates the vertical deviation (ie, 14 L/R = 14 degrees left over right) and the number under the horizontal and vertical measurements indicated the cyclodeviation (ie, 0 = no cyclodeviation, 2 int = 2 degrees incycloptropia, 2 ex = 2 degrees excycloptropia).



**Figure 1** Patient fixating at near with large left over right squint (A) and at distance with no manifest vertical deviation (B). Eye movement recordings of patient during near and distance fixation demonstrating a slow upward drifting of the left eye, which occurred simultaneously with the convergence movement (C).

hypertropia modulated by accommodation and/or convergence. In contrast with our patient, +3 dioptre lenses reduced the vertical deviation at near in at least one case. They concluded that the patient had vertical accommodative vergence. Four of five of their cases had additional forms of strabismus.

Gräf and Weinand<sup>3</sup> described a case of left hyperphoria increasing on convergence. Use of convex lenses and concave lenses did not change the vertical deviation. Similar to our patient, this child had an increase in vertical deviation when the head was tilted to the side of the hyperphoria/tropia. Gräf has recently attributed this to the unidirectional fusional vertical vergence tonus that develops to compensate for the vertical deviation.<sup>4</sup> Gräf<sup>5</sup> described three additional cases with vertical accommodative vergence with

hypotropia. As in our patients concave lenses at distant fixation increased the vertical deviation. Subsequently, a series of 19 patients with differences in the vertical deviation between near and distance were reviewed.<sup>6</sup> Most cases were combined with strabismus sursoadductorius and strabismus deorsoadductorius. In 15 of the 19 patients the vertical deviation increased and in four patients it decreased at near fixation. We agree that supranuclear or internuclear misinnervation most likely explains the connection between elevation and accommodation and convergence.<sup>2,3</sup> A more peripheral innervational abnormality can be excluded because there is no elevation of the left eye when the patient is looking to the right (no aberrant innervation between the fibres to the medial rectus and superior rectus).

In our patient it is unclear whether the abnormality was congenital and decompensation of hyperphoria increased symptoms, or whether it was acquired. Increased vertical fusion range argues for a longstanding squint. The history of most patients in the literature<sup>1,2</sup> was similar, with slow increase of diplopia and vertical deviation at near over several years. In several patients, combined amblyopia or other strabismus forms—such as dissociated vertical deviation—argue for an early onset of the eye motility problem.<sup>2,3</sup> Interestingly, one patient<sup>2</sup> seemed to have developed the vertical deviation in combination with convergence after trauma. It is possible that the aberrant re-innervation can be either congenital or acquired. It would be interesting to investigate systematically the influence on near and distance fixation in patients with vertical squint.

**S Thomas, S J Farooq, F A Proudlock, I Gottlob**

University of Leicester, Robert Kilpatrick Clinical Sciences Building, Leicester Royal Infirmary, PO Box 65, Leicester LE2 7LX, UK

Correspondence to: Professor Irene Gottlob, Department of Ophthalmology, PO Box 65, RKCSB, University of Leicester, Leicester LE2 7LX, UK; [ig15@le.ac.uk](mailto:ig15@le.ac.uk)

doi: 10.1136/bjo.2005.069351

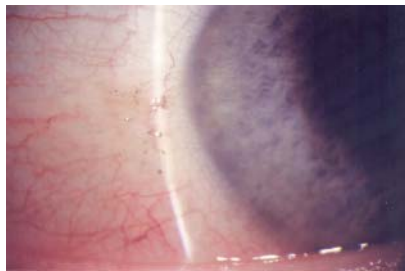
Accepted for publication 13 March 2005

## References

- 1 Bielschowsky A. Disturbance of the vertical motor muscles of the eye. *Arch Ophthalmol* 1938;**20**:175–200.
- 2 Klein-Scharff U, Kommerell G. Vertical accommodative vergence. *Klin Monatsbl Augenheilkd* 1991;**199**:344–5.
- 3 Gräf M, Weinand K. Vertical deviation coupled to convergence. *Klin Monatsbl Augenheilkd* 2000;**216**:51–3.
- 4 Graf M, Krzizok T, Kaufmann H. Head-tilt test in unilateral and symmetric bilateral acquired trochlear nerve palsy. *Klin Monatsbl Augenheilkd* 2005;**222**:142–9.
- 5 Gräf M. Drei Fälle von vertikaler accommodativer Vergenz. *Klin Monatsbl Augenheilkd* 1993;**202**:136–7.
- 6 Gräf MH, Rost D, Becker R. Influence of viewing distance on vertical strabismus. *Graefes Arch Clin Exp Ophthalmol* 2004;**242**:571–5.

## Tetracycline induced green conjunctival pigment deposits

There have been no reports, to our knowledge, of a clinical presentation of ocular pigmentation secondary to the use of oral tetracycline only. Tetracycline hydrochloride is not a well recognised cause of ocular pigmentary changes, but has been reported to cause pigmentation of teeth and nails.<sup>1</sup> Of all the tetracyclines, minocycline (a second generation drug) is most often associated with the adverse effect of pigmentation.<sup>1</sup> There have been several case reports of minocycline induced scleral pigmentation.<sup>2–6</sup> Ocular pigmentary changes reportedly caused by tetracycline have been noted in association with use of minocycline.<sup>7,8</sup> Both patients in these case reports had had tetracycline/minocycline therapy for more than 10 years for acne vulgaris and had their deposition localised within the tarsal conjunctiva.<sup>7</sup> It is believed that most of the cysts are found at the inferior border of the lower tarsus because of the frequency of pre-existing invaginations of conjunctival epithelium in



**Figure 1** Clinical photograph of the conjunctival pigmentary deposits.

this location.<sup>7</sup> The question was raised that long term tetracycline has an effect on the lipid layer of the tear film; noting that the pigmentary deposits were only seen in the conjunctival cysts over the tarsal conjunctiva.<sup>8</sup> Recently, there has been a case report of a patient with a 5 year history of minocycline use for rheumatoid arthritis who developed focal palpebral conjunctival pigment deposits. This patient did not have a reported use of tetracycline.<sup>2</sup>

Our patient was taking only tetracycline without concomitant or previous minocycline use and had bulbar conjunctival lesions. Our patient had also been on tetracycline for 2½ years.

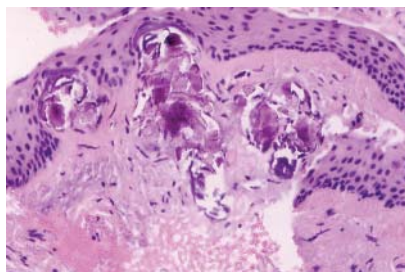
### Case report

A 48 year old healthy white asymptomatic man presented for evaluation of "green crystals" on the conjunctiva of both eyes (fig 1). The patient had noted the onset of this pigmentation over the previous several months. The patient was treated for acne vulgaris with tetracycline 500 mg a day for the past 2½ years. He denied the use of any topical ophthalmic drops. He took Lotensin for the treatment of hypertension. Past medical history was otherwise unremarkable.

On examination the patient was noted to have several dark green granular deposits on the temporal bulbar conjunctiva of both eyes. The granules appeared discrete, crystalline, and varied in size. Otherwise, the examination was unremarkable. Pigmentation was not noted in any other region.

### Pathology

Pathology confirmed the presence of tetracycline. The specimen was positive for a non-polarisable foreign material in a submucosal and intraepithelial distribution (fig 2). This material was calcified and had a faint



**Figure 2** Light microscopy of the pathology specimen of the conjunctival biopsy showing a non-polarisable foreign material in a submucosal and intraepithelial distribution.

brown-yellow tinge. There was no appreciable inflammatory reaction or giant cell reaction to the material. Pathology was consistent with that of previously described reports of tetracycline.<sup>7</sup>

### Comment

Tetracyclines of the first generation (tetracycline, oxytetracycline, and tetracycline chloride) are the most commonly prescribed oral antibiotics for acne.<sup>9</sup> Tetracycline has also been shown to result in improvement of the ocular manifestations of rosacea.<sup>10 11</sup> Both conditions are frequent; thus, the ophthalmologist will encounter many patients being treated with tetracycline. Tetracycline fluorescence has been detected in the conjunctiva of all patients who have taken tetracycline orally.<sup>12</sup> Fluorescence was not generalised but was restricted to a thin film-like layer on the surface and to small areas in the surface layer of cells.<sup>12</sup>

This is the first case report, to our knowledge, of clinically visible conjunctival bulbar deposits caused by the use of tetracycline without a history of minocycline use. Pigmentary changes may initially be noted by the ophthalmologist, as in our case report.

It is important to recognise signs of tetracycline pigmentation as it is a commonly used medication, and cessation of the medication may help avoid further pigmentary changes.

V L Morrison, D O Kikkawa

UCSD Department of Ophthalmology, UCSD School of Medicine, La Jolla, CA 92093-0946, USA

B G Herndier

UCSD Department of Pathology, UCSD School of Medicine, La Jolla, CA 92093-0946, USA

D O Kikkawa

Division of Ophthalmic Plastic and Reconstructive Surgery, UCSD Department of Ophthalmology, UCSD School of Medicine, La Jolla, CA 92093-0946, USA

Correspondence to: Don O Kikkawa, MD, UCSD Department of Ophthalmology, Shiley Eye Center, 9415 Campus Point Drive, La Jolla, CA 92093-0946, USA; [dkikkawa@ucsd.edu](mailto:dkikkawa@ucsd.edu)

doi: 10.1136/bjo.2005.069526

Accepted for publication 15 March 2005

### References

- Eisen D, Hakim MD. Minocycline-induced pigmentation; incidence, prevention and management. *Drug Safety* 1998;**18**:431–40.
- Bradfield YS, Robertson DM, Salomao DR, et al. Minocycline-induced ocular pigmentation. *Arch Ophthalmol* 2003;**121**:144–5.
- Morrow GL, Abbott RL. Minocycline-induced scleral, dental, and dermal pigmentation. *Am J Ophthalmol* 1998;**125**:396–7.
- Fraunfelder FT, Randall JA. Minocycline-induced scleral pigmentation. *Ophthalmology* 1997;**104**:936–8.
- Sabroe RA, Archer CB, Harlow D, et al. Minocycline-induced discolouration of the sclerae. *Br J Dermatol* 1996;**135**:314–16.
- Angeloni VL, Salasche SJ. Nail, skin, and scleral pigmentation. *Cutis* 1987;**40**:229–33.
- Messmer E, Font RL, Sheldon G, et al. Pigmented conjunctival cysts following tetracycline/minocycline therapy. histochemical and electron microscopic observations. *Ophthalmology* 1983;**90**:1462–8.
- Brothers DM, Hidayat AA. Conjunctival pigmentation associated with tetracycline medication. *Ophthalmology* 1981;**88**:1212–15.
- Zouboulis CC, Piquero-Martin J. Update and future of systemic acne treatment. *Dermatology* 2003;**206**:37–53.
- Del Rosso JQ. A status report on the medical management of rosacea: focus on topical therapies. *Cutis* 2002;**70**:271–5.
- Brown SJ, Shahinian L. Diagnosis and treatment of ocular rosacea. *Ophthalmology* 1978;**85**:779–86.
- Dilly PN, Mackie IA. Distribution of tetracycline in the conjunctiva of patients on long term systemic doses. *Br J Ophthalmol* 1985;**69**:25–8.

### Corneal epithelial defects related to high postoperative astigmatism

High and sometimes irregular astigmatism is not an infrequent complication following anterior segment surgery such as suturing of large wounds and corneal transplants. Abnormal corneal topography may affect tear film stability adversely. We present the case of two patients who had persistent postoperative epithelial defects in the lower third of the cornea, in the presence of high corneal astigmatism despite aggressive lubrication. Upon addressing their high corneal astigmatism their epithelial defects resolved.

### Case 1

An 84 year old man underwent a repeat, HLA matched, penetrating keratoplasty following a failed graft for pseudophakic bullous keratopathy. He had had dry eye symptoms with his primary graft with signs of punctate keratitis treated with non-preserved lubrication. His repeat graft was uneventful. He was treated with tacrolimus postoperatively to minimise risk of rejection.

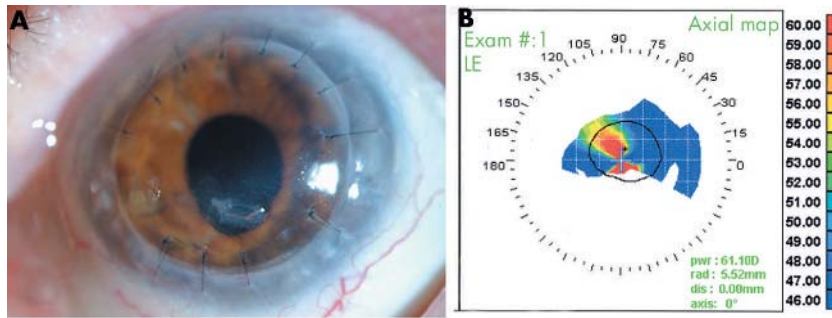
Postoperatively, he had persistent dry eye symptoms for which he was prescribed non-preserved topical lubricants. Six months postoperatively sutures in the horizontal meridian were removed to address "against the rule" astigmatism. He presented a month later with an epithelial defect in the lower third of his graft with an underlying superficial stromal melt (fig 1A). Corneal topography at this time revealed significant "with the rule" corneal astigmatism of 13 dioptres (fig 1B). Tight sutures were cut and non-preserved lubrication, dexamethasone 0.1% and chloramphenicol 0.5%, was continued. Resolution of the epithelial defect followed rapidly with no further progression of stromal melting.

### Case 2

A 72 year old woman with progressive cataract underwent uncomplicated extracapsular cataract surgery. She had been diagnosed with keratoconjunctivitis sicca 15 years previously, which at times required aggressive topical lubrication to control. Postoperatively, she developed a large central corneal defect in the lower third of the cornea. Despite aggressive lubrication the epithelial defect persisted for weeks. She had tight superior wound sutures causing 11.0 dioptres of astigmatism. It was suspected that this could be impeding normal corneal wetting. Upon their release and continued topical lubrication the epithelial defect resolved.

### Comment

It is possible that an irregular corneal surface interferes with normal maintenance of the ocular surface tear film. This abnormal tear distribution is likely to be exacerbated by an



**Figure 1** (A) Diffuse slit lamp photograph of the corneal graft showing an epithelial defect and superficial stromal melting in the lower third. (B) Corneal topography showing steep with the rule astigmatism.

underlying dry eye state. If tear deficiency and degree of astigmatism are extreme, desiccation of the corneal epithelium is possible, leading to non-healing defects and associated sequelae.

In cases where high or irregular astigmatism is associated with postoperative non-healing corneal defects, addressing the degree of corneal astigmatism may help restore physiological tear dynamics and resolution of the epithelial defect. Corneal sutures may themselves impede epithelial migration,<sup>1</sup> but if this were the only explanation all grafts would be exposed to the same risk. Conversely, not all patients with high astigmatism (non-surgical) have epithelial defects. This would suggest that more than a single factor is at play in such situations. To our knowledge high astigmatism as a contributory factor to development of persistent epithelial defects post operatively, has not been previously considered.

**R Singh, T Umopathy, B B Kulkarni, H S Dua**  
University Hospital, Queens Medical Centre,  
University of Nottingham, Nottingham, UK

Correspondence to: Professor H S Dua, Division of Ophthalmology, University Hospital, Queens Medical Centre, B Floor, Eye ENT Centre, Nottingham NG7 2UH, UK; [harminder.dua@nottingham.ac.uk](mailto:harminder.dua@nottingham.ac.uk)

doi: 10.1136/bjo.2005.069260

Accepted for publication 23 March 2005

## Reference

- 1 **Lemp MA.** The surface of the corneal graft: in vivo colour specular microscopic study in the human. *Trans Am Ophthalmol Soc* 1989;**87**:619–57.

## Non-tuberculous mycobacteria related infectious crystalline keratopathy

Non-tuberculous mycobacteria (NTM) or atypical mycobacterial keratitis is an uncommon condition causing indolent corneal ulceration. The infection mimics herpetic, mycotic, and *Nocardia* keratitis and diagnosis requires a high index of suspicion. We report two cases of NTM infection where the presenting sign was that of crystalline keratopathy. Both cases were diagnosed by microbial culture and successfully treated.

### Case 1

A 44 year old white female contact lens wearer presented with a 3 week history of

an inflamed eye with a 1.5 mm diameter area of corneal stromal infiltration. Vision was 6/6 in each eye. She was being treated with antivirals and later unsuccessfully with antibacterials and steroids. Three active stromal crystalline infiltrates appeared in the mid-stroma 3 weeks later (fig 1). Culture from a corneal biopsy revealed *Mycobacterium chelonae*.

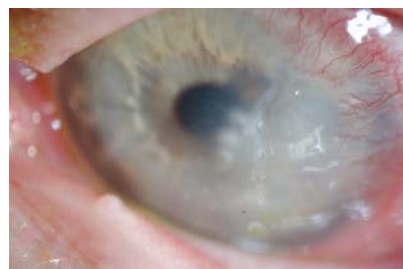The keratitis responded to topical amikacin and amphotericin B, which was started on the suspicion of fungal keratitis, before microbial culture results were available. The keratitis resolved over a 4 week period and vision settled at 6/9.

### Case 2

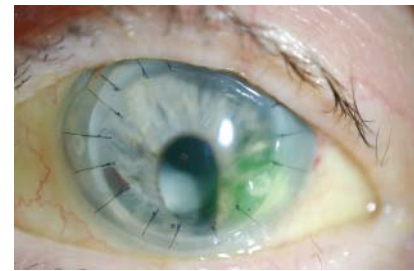
An 80 year old white woman with pseudophakic bullous keratopathy had a penetrating keratoplasty and was given systemic tacrolimus. Three months postoperatively she presented with endothelial dusting and a 1 mm mid-stromal abscess with a crystalline appearance (fig 2). A corneal scrape revealed acid fast bacilli for which she was commenced on topical ciprofloxacin and amikacin 2.5% but was slow to respond. Culture confirmed *Mycobacterium chelonae* resistant to amikacin. Topical moxifloxacin was added and oral clarithromycin commenced. Three months later, the ulcer healed with a clear graft but the vision did not improve (counting fingers) on account of pre-existing macular oedema.

### Comment

Non-tuberculous mycobacteria cause indolent corneal ulceration resembling herpes virus, fungal, or *Nocardia* keratitis. The variable clinical presentations and poor susceptibility to conventional antibacterials usually results in a delay in diagnosis.<sup>1–3</sup> The two common types of NTM causing keratitis are



**Figure 1** Case 1 showing three active stromal crystalline infiltrates central to the edge of the ulcer.



**Figure 2** Case 2 showing a mid-stromal abscess with a crystalline appearance at 5 o'clock region of the graft-host junction.

*M chelonae* and *M fortuitum*. The clinical features of NTM include pseudodendritic epithelial defects, subepithelial white fluffy infiltrates with crystalline satellite lesions and ulcers with an overhanging necrotic edge and a grey sloughed base.<sup>1</sup> Keratic precipitates and endothelial deposits may appear. Early diagnosis is difficult and absence of organisms in smears and cultures does not exclude the diagnosis of NTM. Repeat scrapes or a corneal biopsy should be considered in all indolent corneal ulcers.

Amikacin has been the drug of choice in *Nocardia* and atypical mycobacterial infection.<sup>1,2</sup> However, approximately 60% of patients will not respond to topical amikacin, as with our second case, and use of combination therapy with ciprofloxacin, gatifloxacin, moxifloxacin, and clarithromycin is recommended.<sup>4–7</sup> Penetrating keratoplasty is performed when stromal infiltration is extensive<sup>4</sup> but immunosuppression may predispose to recurrent infection. Both our patients were treated successfully. The first patient had a good visual outcome but the second had poor vision due to pre-existing pathology. Successful treatment requires disease awareness, deferring the use of steroids when no organism has been isolated and use of effective antibiotics.

**T Umopathy, R Singh, H S Dua**

Division of Ophthalmology and Visual Sciences,  
Queens Medical Centre, University Hospital,  
Nottingham, UK

**F Donald**

Department of Microbiology, Queens Medical Centre,  
University Hospital, Nottingham, UK

Correspondence to: H S Dua, Division of Ophthalmology, B Floor, Eye ENT Centre, University Hospital, Queens Medical Centre, Nottingham NG7 2UH, UK; [harminder.dua@nottingham.ac.uk](mailto:harminder.dua@nottingham.ac.uk)

doi: 10.1136/bjo.2005.069856

Accepted for publication 23 March 2005

## References

- 1 **Kinota S, Wong KW, Biswas J, et al.** Changing patterns of infectious keratitis: overview of clinical and histopathologic features of keratitis due to acanthamoeba or atypical mycobacteria, and of infectious crystalline keratopathy. *Indian J Ophthalmol* 1993;**41**:3–14.
- 2 **Hu FR, Huang WJ, Huang SF.** Clinicopathologic study of satellite lesions in nontuberculous mycobacterial keratitis. *Jpn J Ophthalmol* 1998;**42**:115–18.
- 3 **Sridhar MS, Gopinathan U, Garg P, et al.** Ocular nocardia infections with special emphasis on the cornea. *Surv Ophthalmol* 2001;**45**:361–78.
- 4 **Matoba A.** *Mycobacterium chelonae* keratitis of a corneal graft. *Am J Ophthalmol* 1987;**103**:595–96.

- 5 Ford JG, Huang AJW, Pflugfelder SC, *et al*. Nontuberculous mycobacterial keratitis in south Florida. *Ophthalmology* 1998;**105**:1652–58.
- 6 Abshire R, Cockrum P, Crider J, *et al*. Topical antibacterial therapy for mycobacterial keratitis: potential for surgical prophylaxis and treatment. *Clinical Therapeutics* 2004;**26**:191–6.
- 7 Hyon J-Y, Joo M-J, Hose S, *et al*. Comparative efficacy of topical gatifloxacin with ciprofloxacin, amikacin and clarithromycin in the treatment of experimental mycobacterium chelonae keratitis. *Arch Ophthalmol* 2004;**122**:1166–9.

## Xanthogranulomatous disease in the lacrimal gland

We report three cases of adult lacrimal gland xanthogranulomatous disease that demonstrate the spectrum of this disorder and provide insight into immune dysfunction.

### Case 1

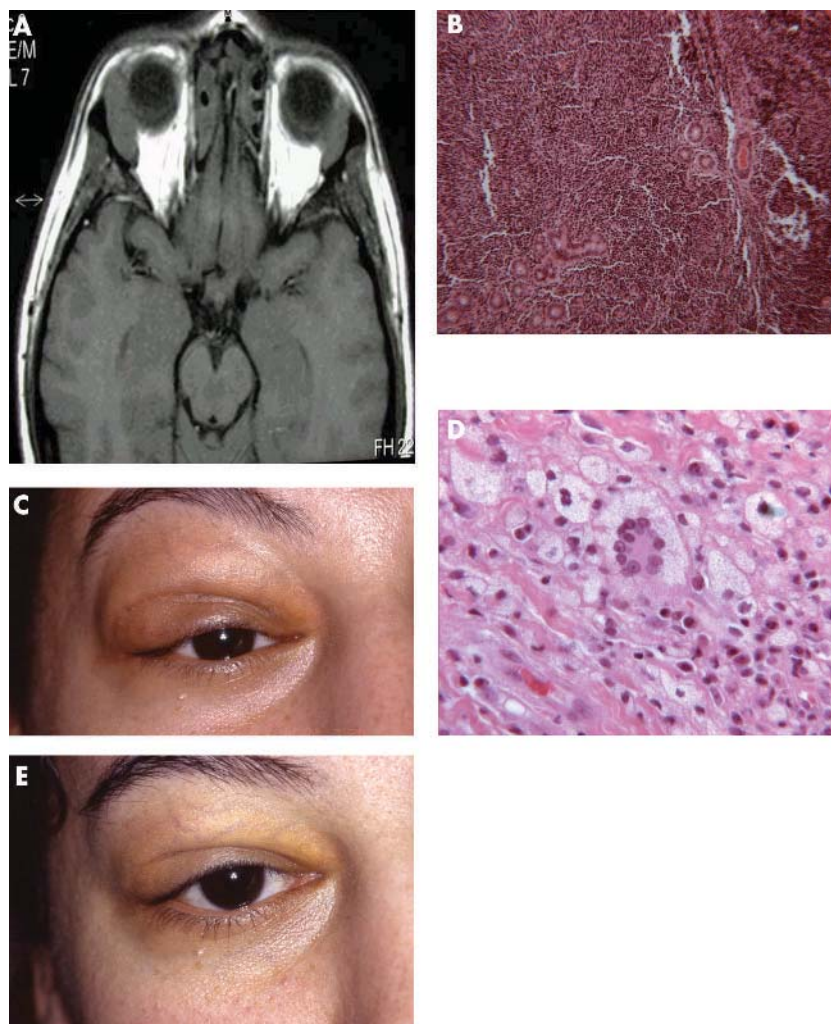
A 23 year old asthmatic female had 1 year of bilateral, painless, lacrimal gland masses from polyclonal B cell (CD 20+) infiltration (fig 1A, B) The patient was asymptomatic for 18 months after external beam radiation (25 Gy in 10 fractions). While 7 months pregnant, painless lacrimal gland enlargement recurred, as firm, yellow, nodular masses (fig 1C). A second biopsy showed foamy histiocytes, Touton giant cells, and lymphoid infiltrate without necrobiosis (fig 1D). The orbital masses have remained stable 2 years after corticosteroids and surgical debulking. Systemic involvement included breast MALT type lymphoma 4 years after presentation.

### Case 2

A 49 year old Brunei male had 10 years of bilateral, yellow, mildly steroid responsive, superolateral orbital masses (fig 2A). Previous biopsy showed benign, polyclonal lymphocytic proliferation in the lacrimal gland and eyelid xanthoma. Second eyelid and lacrimal gland biopsy demonstrated xanthomatous infiltrate involving obicularis and lymphocytes with some germinal centres, s100 negative, KP1 positive foamy histiocytes and Touton giant cells, respectively (fig 2B–D). Orbital findings improved with Solumedrol (3 g over 3 days), ciclosporin, and cyclophosphamide. The patient was lost to follow up after 6 months. Systemic associations included asthma, sinusitis, and polyclonal paraproteinaemia (increased  $\alpha 1$  and  $\alpha 2$ ,  $\beta$  globulin, and IgM).

### Case 3

A 52 year old white female had 2 months of bilateral, yellow, lacrimal gland masses and dry eye (confirmed by Schirmer's testing) (see fig 3A–C). Lacrimal gland biopsy demonstrated foamy histiocytes, Touton giant cells, chronic inflammation, bands of fibrosis, and necrobiosis. The lacrimal gland masses resolved at 2 years after treatment with Solumedrol (3 g over 3 days), methotrexate, pulsed cyclophosphamide, and topical 0.05% ciclosporin (Restasis) (fig 3E–F). She is maintained on prednisone 40 mg per day, methotrexate 17.5 mg per week, and Restasis twice a day. Systemic associations included asthma, cervical, axillary, hilar lymphadenopathy, iliac, sacral, L4 sclerosis, and xanthogranulomatous disease of the breast for which she underwent mastectomy 3 months before presentation (fig 3D).



**Figure 1** (A) T1 weighted axial magnetic resonance imaging (MRI) showing bilateral lacrimal gland enlargement. (B) Initial lacrimal gland biopsy showing a dense lymphocytic infiltrate with preserved ducts (haematoxylin and eosin stain, original magnification 4 $\times$ ). (C) Clinical photograph of yellow, recurrent mass, right orbit, 2 years after radiation treatment. (D) Second lacrimal gland biopsy showing Touton giant cells, foamy histiocytes, lymphocytes, and plasma cells (haematoxylin and eosin stain, original magnification 60 $\times$ ). (E) Clinical photograph of patient showing improvement 1 year after treatment.

### Comment

Adult xanthogranulomatous disease is a class II histiocytic disorder<sup>1</sup> syndromically classified as adult onset xanthogranuloma (AOX), adult onset asthma and periocular xanthogranuloma (AAPOX),<sup>2</sup> necrobiotic xanthogranuloma (NBX),<sup>3</sup> and Erdheim-Chester disease (ECD).<sup>4</sup> AOX is a solitary lesion.<sup>5</sup> AAPOX has B cell mediated findings including adult onset asthma, lymphadenopathy, and paraproteinaemia.<sup>3</sup> Ulcerative skin lesions, paraproteinaemia/myeloma, and silent internal organ disease characterise NBX.<sup>3</sup> ECD is typified by lethal, retroperitoneal and bony sclerosis.<sup>4</sup>

All our cases had asthma. Case 2 had elevated serum protein. Case 3 had lymphadenopathy, salivary gland enlargement, and bony sclerosis. Cases 1 and 3 had breast masses: MALT type lymphoma postdated orbital disease in case 1; xanthogranulomatous disease preceded orbital involvement in case 3. The first two cases could be classified as AAPOX. Case 3 had necrobiosis suggesting NBX, but had clinical features of AAPOX and

lacked skin ulcers. These findings demonstrate the adult xanthogranulomatous syndromes are not mutually exclusive.

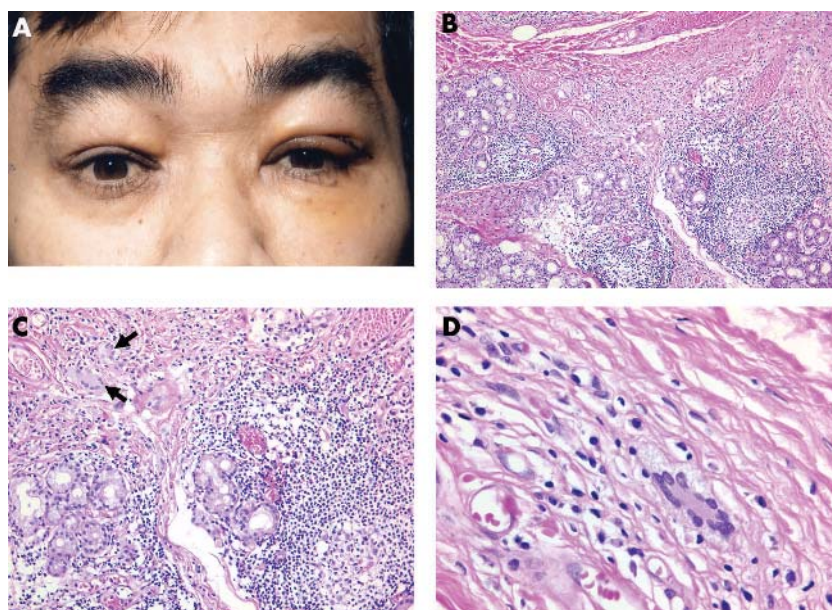
Xanthogranuloma histology consists of non-Langerhans, lipid laden histiocytes, Touton giant cells, and varying degrees of lymphocytic infiltrate, fibrosis, and necrosis (necrobiosis). This infiltration replaced the normal lacrimal gland architecture causing mass effect and loss of tear production. This same process affected the breast in case 3.

The immune cascade leading to this histopathological appearance is unknown. Our previous work found a predominance of CD8 (cytotoxic) T cells in areas of fibrosis and lipophage accumulation. We postulated that CD8 cells activated histiocytes and fibroblasts. Relevant to this hypothesis, it is fascinating that polyclonal B cell (CD20+) infiltration, without gland destruction or foamy histiocytes, preceded the development of xanthogranuloma in cases 1 and 2 and in one case from the literature<sup>6</sup> (fig 1B). An additional report was initially diagnosed as Sjögren's syndrome, but lacked histology.<sup>9</sup>

**Table 1** Xanthogranulomatous disease presenting in the lacrimal gland

Reference	Duration	Pathology first biopsy	Time to 2nd biopsy	Pathology 2nd biopsy	Systemic findings	Treatment/response	Age	Sex	Diagnosis
Rouhianen <sup>6</sup>	1 month	"chronic inflam"	8 months	Xantho	NR	Prednisone, varied course	45	F	AOX
Miszkiel, <sup>10</sup> case 9	1 year	xantho			Asthma, eosinophilia, neutrophilia	Surgery	60	F	AAPOX
Tucker <sup>11</sup>	2–3 months	Xantho			Paraproteinaemia, polyarticular migratory arthritis. Later, conjunctival lesions	Prednisone	43	F	NBX
Karcioglu <sup>9</sup>		Xantho			Initially "diagnosed as Sjögren's"		23	F	Not enough info to classify

Other cases report dry eye, or lacrimal gland involvement, but not specifically presentation in the lacrimal gland.



**Figure 2** (A) Clinical photograph showing bilateral lacrimal gland enlargement and, xanthochromia of the upper eyelids. (B) Second lacrimal gland biopsy demonstrating infiltration and destruction of the lacrimal gland by lymphorrhages with follicular centres (haematoxylin and eosin stain, original magnification 10 $\times$ ). (C) Higher power view of follicular centres and occasional Touton giant cell (arrows) (haematoxylin and eosin stain, original magnification 20 $\times$ ). (D) Touton giant cells with background of foamy histiocytes, lymphocytes, and plasma cells (haematoxylin and eosin stain, original magnification 60 $\times$ ). Photograph reproduced with permission.

Moreover, case 1 developed a monoclonal proliferation of B cells in the breast 1 year after the orbital xanthogranuloma.

Our cases are unusual because the orbital xanthogranuloma were limited to the lacrimal gland, which is devoid of fat. We found four similar reports (table 1). Perhaps immune dysregulation leads to tissue destruction, and the resultant cell membrane fatty acids are scavenged by malfunctioning histiocytes.

The best treatment for xanthogranulomatous disease is unknown. Our patients had some response to steroids, with cases 2 and 3 responding to B cell (cyclophosphamide and methotrexate) and T cell (cyclosporin) suppressors.

These cases raise questions regarding the pathogenesis of non-Langerhans histiocytosis and demonstrate that histopathological and clinical findings must be used for diagnosis in

the spectrum of disorders that is xanthogranulomatous disease.

#### J A Sivak-Callcott

Department of Ophthalmology, West Virginia University, Morgantown, WV, USA

#### W K Lim, L L Seah

Singapore National Eye Centre, Singapore

#### J Oestreicher, D Rossman, N Nijhawan

Department of Ophthalmology, University of Toronto, Toronto, Ontario, Canada

#### J Rootman

Department of Ophthalmology and Visual Sciences, University of British Columbia, Vancouver, BC, Canada

#### J Rootman, V White

Department of Pathology, University of British Columbia, Vancouver, BC, Canada

#### H J Williams, W W L Chang

Department of Pathology, West Virginia University, Morgantown, WV, USA

#### A DiBartolomeo\*

Department of Rheumatology, West Virginia University, Morgantown, WV, USA

#### D Howarth

Department of Pathology, University of Toronto, Toronto, Ontario, Canada

Correspondence to: Jennifer A Sivak-Callcott, MD, West Virginia University Eye Institute, PO Box 9193, Morgantown, WV 26506, USA; [jsivak@hsc.wvu.edu](mailto:jsivak@hsc.wvu.edu)

doi: 10.1136/bjo.2004.063578

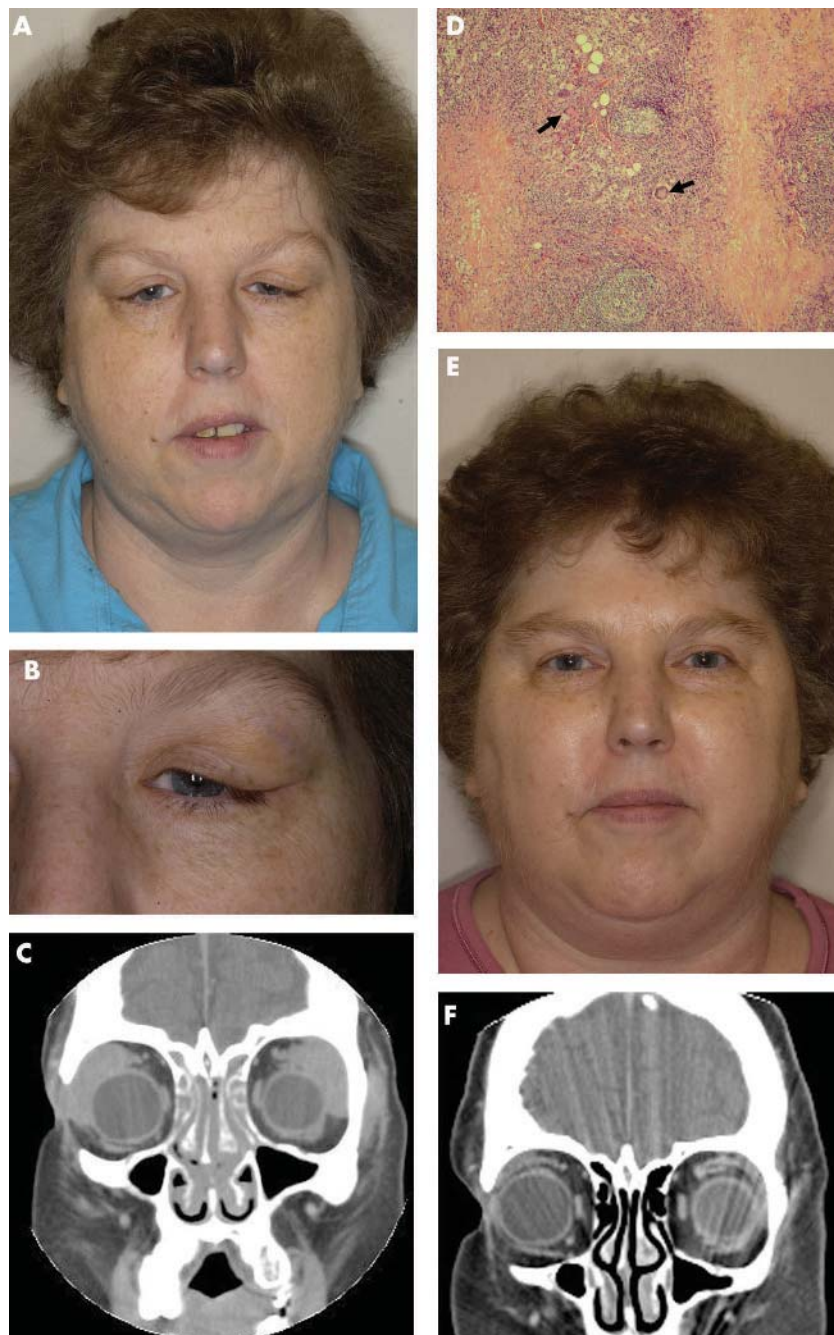Accepted for publication 1 April 2005

None of the authors have any financial interests regarding this paper.

\*Published posthumously.

#### References

- Moschella SL. An update of the benign proliferative monocyte-macrophage and dendritic cell disorders. *J Dermatol* 1996;**23**:805–15.
- Jakobiec F, Mills M, Hidayat A, et al. Periocular xanthogranulomas associated with severe adult-onset asthma. *Trans Am Ophthalmol Soc* 1993;**91**:99–129.
- Kossard S, Winkelmann RK. Necrobiotic xanthogranuloma with paraproteinemia. *J Am Acad Dermatol* 1980;**3**:257–70.
- Veysier-Belot C, Cacoub P, Caparros-Lefebvre D, et al. Erdheim-Chester disease: clinical and radiologic characteristics of 59 cases. *Medicine* 1996;**75**:157–69.
- Mencia-Gutierrez E, Gutierrez-Diaz E, Madero-Garcia S. Juvenile xanthogranuloma of the orbit in an adult. *Ophthalmologica* 2000;**214**:437–40.
- Rouhianen H, Nerdrum K, Puustjarvi T, et al. Xanthogranuloma juveniles—a rare cause of orbital swelling in adulthood. *Ophthalmologica* 1992;**204**:162–5.
- Novak P, Robbins T, Winkelmann R. Necrobiotic xanthogranuloma with myocardial lesions and nodular transformation of the liver. *Hum Pathol* 1992;**23**:195–6.
- Ugurlu S, Bartley GB, Gibson LE. Necrobiotic xanthogranuloma: long term outcome of ocular involvement. *Am J Ophthalmol* 2000;**129**:651–7.
- Karcioglu ZA, Sharara N, Boles TL, et al. Orbital xanthogranuloma: clinical and morphologic features in eight patients. *Ophthalmic Plast Reconstruct Surg* 1993;**9**:372–81.
- Miszkiel KA, Sohaib SAA, Rose GE, et al. Radiological and clinicopathological features of orbital xanthogranuloma. *Br J Ophthalmol* 2000;**84**:251–8.



**Figure 3** (A, B) Clinical photographs showing bilateral lacrimal gland masses with yellow discoloration, parotid/submandibular salivary gland enlargement, and cervical lymphadenopathy. (C) Coronal computed tomography scan showing bilateral lacrimal gland enlargement. (D) Histopathology of mastectomy specimen showing foamy histiocytes, Touton giant cells (arrows), lymphocytes with follicular centres, and necrobiosis (haematoxylin and eosin stain, original magnification 10×). (E) Clinical photograph 24 months after diagnosis, showing improvement. (F) Coronal computed tomography scan showing resolution of lacrimal gland masses. Photograph reproduced with permission.

11 Tucker N, Discepolo M, Blanco G, et al. Necrobiotic xanthogranuloma without dermatologic involvement. *Can J Ophthalmol* 1997;32:396-9.

**Management of phaeniciatic ophthalmomyiasis externa**

Ophthalmomyiasis, maggot or fly larvae infestation of the eye, is a rare condition that can have variable presentation depending on

the type of fly, the ocular structures involved, and the level of larval infiltration.

**Case report**

A 60 year old African-American male presented with a chief complaint of a swollen, moderately painful red right eye since 4 am that day. Ocular history was significant for foreign body lid trauma of unknown aetiology (presumably a rock or insect) 2 days

earlier while riding his motorcycle without protective goggles.

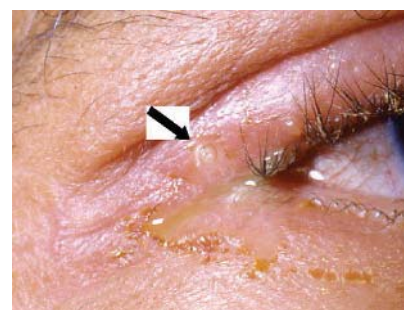Ocular examination revealed 20/20 vision in each eye with correction. Pupils, extra-ocular motilities, and confrontation fields were normal. Slit lamp evaluation revealed upper and lower lid oedema with mild erythema in the right eye. A 1.5 mm round ulcerated lesion was noted on the right outer canthal region that appeared to pulsate as the patient was examined in the slit lamp (fig 1). The left eye and other ocular structures in the right eye were unremarkable.

Upon external digital pressure of the ulcerated lesion, a foreign organism was seen to retreat into the ocular tissue. Manual forceps were used to remove a 1.0 cm long white segmented maggot (fig 2). This specimen was identified by an entomologist under a microscope, as being of the Calliphoridae family, *Phaenicia lucilia*, otherwise known as a screwworm fly.

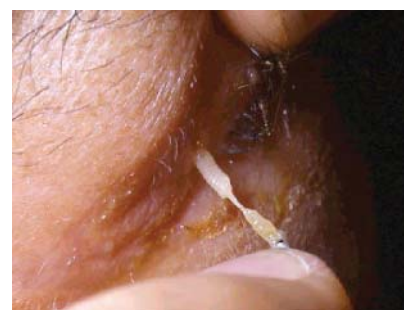The patient was given erythromycin ointment for use twice a day over the lesion. After 3 days, the patient returned with complete resolution of the lid oedema and erythema (fig 3).

**Comment**

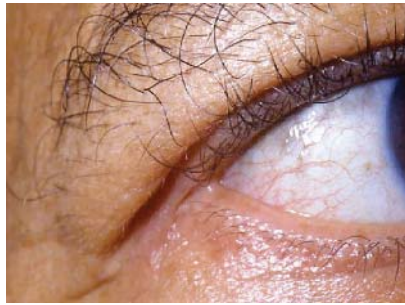Ophthalmomyiasis is generally caused by sheep botflies and flesh flies. The most commonly reported organism in the literature is *Oestrus ovis*, a botfly highly prevalent in sheep herding and farming communities.<sup>1,2</sup> These flies typically lay their eggs on decaying organic material, but are also attracted to open mucopurulent human sores. Within 24 hours, these eggs hatch, producing larvae which then feed on human tissue.<sup>2,3</sup> This case was somewhat unusual in that trauma was the mechanism by which the fly eggs were



**Figure 1** A 1.5 mm ulcerated lesion that appears to pulsate.



**Figure 2** Manual forceps removal produces a 1.0 cm long white segmented maggot.



**Figure 3** Complete resolution of the lid oedema and erythema.

deposited. Clinical features of external ophthalmomyiasis can include conjunctivitis, conjunctival hemorrhage, corneal abrasion, and iritis. Internal ophthalmomyiasis can produce vitreous haemorrhage, tractional retinal detachment, endophthalmitis, and hypopigmented linear and arcuate subretinal tracks. Some of the cases of presumed internal ophthalmomyiasis have been based on hypopigmented subretinal tracks without documentation of an actual maggot.<sup>1</sup>

Treatment strategies depend upon the type of ocular involvement and the level of damage. In cases of external ophthalmomyiasis, manual forceps removal of the larvae is ideal. Ophthalmic ointment can be used to block the larvae's respiratory pore, thereby suffocating the organism to facilitate manual removal. Treatment strategies in cases of internal ophthalmomyiasis are case specific, ranging from iridectomy, vitrectomy, and retinotomy to laser photocoagulation. This is the first reported case of ophthalmomyiasis externa by a screwworm fly, *Calliphoridae Phaenicia* sp successfully treated with manual forceps removal.

### Acknowledgements

Thanks to Kipling Will and David Faulkner for their assistance from the University of California, Berkeley, Entomology Department. Thanks to A Bitanga for the photographs. Thanks also to Thomas Lietman for his help with the manuscript.

**N Huynh, B Dolan**

San Francisco VA Medical Center, CA, USA

**S Lee, J P Whitcher**

Proctor Foundation, CA, USA

**J Stanley, J P Whitcher, S Lee**

UCSF Department of Ophthalmology, CA, USA

Correspondence to: Dr Scott Lee, UCSF Department of Ophthalmology, CA 94122, USA; [selee@itsa.ucsf.edu](mailto:selee@itsa.ucsf.edu)

doi: 10.1136/bjo.2005.071597

Accepted 1 April 2005

### References

- Heyde RR, Seiff SR, Mucia J. Ophthalmomyiasis externa in California. *West J Med* 1987;144:80-1.
- Neva FA, Brown HW. *Basic clinical parasitology*, 6th ed. Norwalk, CT: Appleton and Lange, 1994:292-4.
- Sigauke E, Beebe WE, Gander RM, et al. Case report: ophthalmomyiasis externa in Dallas County, Texas. *Am J Trop Med* 2003;68:46-7.
- Buettner H. Ophthalmomyiasis interna. *Arch Ophthalmol* 2002;120:1598-9.

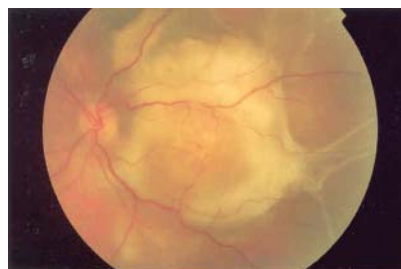## Vitreous haemorrhage associated with *Ginkgo biloba* use in a patient with age related macular disease

*Ginkgo biloba* extract is a widely used herbal extract that is readily available as an "over the counter" product. It is most commonly used for improving mental alertness and memory. One of its components, ginkgolide B is a potent inhibitor of platelet activating factor.<sup>1</sup> Long term use has been associated with increased bleeding time and it can potentiate the anticoagulant effects of aspirin and warfarin.<sup>2</sup>

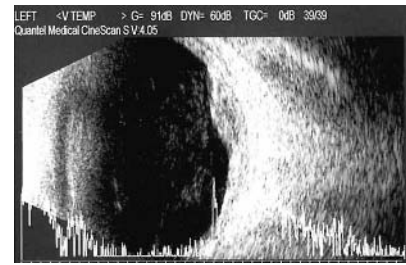
This is a case in which the regular use of *Ginkgo biloba* was associated with a vitreous haemorrhage in a woman with a subretinal neovascular membrane, who had no other risk factors for haemorrhage.

A 78 year old woman, who was otherwise fit and well, first presented in July 2001 to the ophthalmology department in Cheltenham General Hospital with a history of floaters in both eyes. Her visual acuities were 6/6 in the right eye and 6/12 correcting to 6/9 in the left eye. Fluorescein angiography confirmed exudative age related macular disease (ARMD) on the left but no treatable discrete neovascular membrane. She had further loss of vision in the left eye and by October 2002 her left eye vision had deteriorated to 3/60. She experienced a gradual deterioration of vision in the right eye until February 2004, when she presented with rapid visual loss in the right eye to 6/24. An untreatable occult choroidal neovascular membrane was demonstrated on fluorescein angiography. In June 2004 she noted a further sudden drop in central vision in the left eye. On examination she had extensive preretinal and subretinal haemorrhage. Within the next month she developed a dense vitreous haemorrhage reducing her visual acuity to hand movements. A B-scan ultrasound confirmed the vitreous haemorrhage and showed a flat retina with a haemorrhagic elevation at the posterior pole consistent with exudative age related macular disease (fig 1). On further questioning she revealed that she had been taking *Ginkgo biloba* for the past 5 months. She was also taking vitamin C 1 g daily, zinc, lutein, B complex, fish oil, Fossamax, and a steroid inhaler for asthma. She was advised to stop the *Ginkgo biloba* and the vitreous haemorrhage gradually resolved. There has been no further bleeding in the follow up period of 8 months, but she has been left with exuberant macular fibrosis (fig 2).

Another case of vitreous haemorrhage associated with the use of *Ginkgo biloba* has been reported in a patient with no other risk



**Figure 1** Colour fundus photograph of left eye showing extensive macular scar.



**Figure 2** B-scan showing vitreous haemorrhage and haemorrhagic elevation at posterior pole.

factors for haemorrhage. A 59 year old man underwent liver transplant for cirrhosis caused by hepatitis B infection. This was complicated postoperatively by a large subphrenic haematoma. Three weeks later he developed a right vitreous haemorrhage.<sup>3</sup> There are several reports in the literature linking the use of *Ginkgo biloba* with spontaneous haemorrhage. These include the report of a subdural haematoma,<sup>4</sup> hyphaema,<sup>5</sup> subarachnoid haemorrhage,<sup>6</sup> and intracerebral haemorrhage.<sup>7</sup>

### Comment

A study evaluating the causes of 653 cases of spontaneous vitreous haemorrhage found ARMD to be a small yet significant cause.<sup>8</sup> A study by el Baba *et al* showed that in 19% of reported cases of ARMD complicated by massive intraocular haemorrhage, the patients were taking warfarin or aspirin.<sup>9</sup> Vitreous haemorrhage is found to have a significantly higher incidence in patients taking warfarin or aspirin when the bleeding occurred.<sup>10</sup>

This case supplements a series of case reports implicating the use of *Ginkgo biloba* in spontaneous haemorrhage. There is a danger in the widely held belief that herbal remedies are benign. Patients often omit to tell their doctors of these supplemental medicines when being asked about their drug history. Herbal remedies have been exempt from scientific scrutiny and product regulation and, as a result, we are largely unaware of their full adverse effects profile and possible drug interactions. It should be made regular practice to specifically ask patients about the use of any herbal remedies or unconventional medicines.

**O P MacVie, B A Harney**

Gloucestershire Eye Unit, Cheltenham, UK

Correspondence to: Olivia P MacVie, Gloucestershire Eye Unit, Cheltenham General Hospital, Sandford Road, Cheltenham GL53 7AN, UK; [olivmac9@hotmail.com](mailto:olivmac9@hotmail.com)

doi: 10.1136/bjo.2005.072454

Accepted for publication 3 April 2005

### References

- Chung KF, Dent G, McKusker M, et al. Effect of a ginkgolide mixture (BN52063) in antagonising skin and platelet responses to PAF in man. *Lancet* 1987;1:248-51.
- Fugh-Berman A. Herb-drug interactions. *Lancet* 2000;355:134-8.
- Hauser D, Gayowski T, Singh N. Bleeding complications precipitated by unrecognized *Ginkgo biloba* use after liver transplantation. *Transplant Int* 2002;15:377-9.

- 4 **Gilbert GJ**. Gingko biloba. *Neurology* 1997;**48**:1137.
- 5 **Rosenblatt M**, Mindel J. Spontaneous hyphaema associated with ingestion of Gingko biloba extract. *N Engl J Med* 1997;**336**:1108.
- 6 **Vale S**. Subarachnoid haemorrhage associated with Gingko biloba. *Lancet* 1998;**35**:36.
- 7 **Benjamin J**, Muir T, Briggs K, *et al*. A case of cerebral haemorrhage, can Gingko biloba be implicated? *Postgrad Med J* 2001;**77**:112-13.
- 8 **Butner RW**, McPherson AR. Spontaneous vitreous haemorrhage. *Ann Ophthalmol* 1982;**14**:268-70.
- 9 **El Baba F**, Jarrett WH, Harbin TS, *et al*. Massive haemorrhage complicating age-related macular degeneration. Clinicopathologic correlation and role of anticoagulants. *Ophthalmology* 1986;**93**:1581-92.
- 10 **Tilanus MA**, Vaandrager W, Cuyper MH, *et al*. Relationship between anticoagulant medication and massive intraocular haemorrhage in age-related macular degeneration. *Graefes Arch Clin Exp Ophthalmol* 2000;**238**:482-5.

## The legal requirement for driving in the United Kingdom is met following pupil dilatation

Dilatation of the pupil (mydriasis) is a core component of a comprehensive ophthalmic examination and is becoming part of the eye examination routine for optometrists in the United Kingdom.<sup>1</sup> As many patients drive to attend their examinations, concerns have been raised regarding the effects of pupillary dilatation on driving and whether or not the visual standard for driving is met after dilatation.<sup>2-4</sup> Therefore, we investigated the effect of mydriasis on the visual standard for driving a private vehicle in the United Kingdom.

### Report

Twenty adult subjects (mean age 24 years) with normal or corrected to normal visual acuity participated in the study. A selection of six different pairs of number plates (black on white and black on yellow), which conformed to the current UK visual standard for driving (that is, after 1 September 2001),<sup>5</sup> was constructed for the study. Monocular and binocular distance logMAR visual acuity

and binocular number plate readings were made before and after mydriasis (of at least 6 mm diameter) with 0.5% tropicamide. Each subject performed the number plate test under standard Driving Standards Agency conditions (outside) at a fixed test distance of 20 metres.<sup>6</sup> A pass at the number plate test required all numbers and letters to be read correctly. Letter by letter scoring was used to record visual acuity. Data were analysed using paired *t* tests (one tailed) as appropriate. Subjects were also asked for their views on the effects of mydriasis using a questionnaire.<sup>3</sup> The study followed the tenets of the Declaration of Helsinki and approval of the protocol was obtained from the institutional human research ethics committee.

All subjects met the legal requirement for driving both before and after dilatation, irrespective of the number plate used. Visual acuity decreased (average of three letters worse) following dilatation ( $p < 0.05$  for right eye, left eye and binocular visual acuity results) (table 1).<sup>4,7</sup>

Following mydriasis, 13 subjects reported an increase in glare, 15 felt more sensitive to light, 14 reported blurry distance vision, five reported blurry near vision, and one subject reported no effect of the drops. Most subjects reported a slight (nine) or moderate (10) effect of the drops; however, the majority (19) felt confident enough to safely drive home after dilatation.

### Comment

Despite a loss in visual acuity after dilatation, all subjects passed the number plate test both before and after dilatation and irrespective of the background colour of the number plate. Recently, Goel *et al* found a significant number of patients (four of 28) did not pass the number plate test after mydriasis.<sup>8</sup> However, subjects in our study were relatively young, wore the appropriate refraction and were free from signs of ocular disease. Given the small effect of mydriasis on visual acuity,<sup>4,7,9</sup> it is not surprising that, for our subjects, mydriasis did not affect the UK visual standard for driving. Notwithstanding the relatively small loss in visual acuity, most subjects in our study reported a slight or

moderate effect of mydriasis on their vision. Nevertheless, all subjects but one felt confident enough to drive home.

Wood *et al* have shown that mydriasis has a measurable decrease on real life driving performance, specifically on the detection and recognition of low contrast road obstacles and the ability to navigate around them.<sup>9</sup> These findings, together with our results, suggest that satisfying the UK visual standard for driving does not preclude a decrease in driving performance. Therefore, all patients should be advised that although the visual standard for driving may be met following mydriasis, caution is advised when driving after pupillary dilatation.

**J Siderov, D Mehta, R Virk**

Anglia Vision Research, Department of Optometry and Ophthalmic Dispensing, Anglia Polytechnic University, Cambridge CB1 1PT, UK

Correspondence to: Dr John Siderov, Department of Optometry and Ophthalmic Dispensing, Anglia Polytechnic University, Cambridge CB1 1PT, UK; [j.siderov@apu.ac.uk](mailto:j.siderov@apu.ac.uk)

doi: 10.1136/bjo.2005.070722

Accepted for publication 8 April 2005

Competing interests: none declared

### References

- 1 **Siderov J**. Pupillary dilation in primary care optometry. Part 1. *Optician* 2004;**228**(5965):18-19.
- 2 **Keightly S**. Pupil dilation and driving. *Eye* 2000;**14**:261-2.
- 3 **Siderov J**, Bartlett JR, Madigan CJ. Pupillary dilation: the patient's perspective. *Clin Experiment Optom* 1996;**79**:62-6.
- 4 **Watts P**, O'Duffy D, Riddell C, *et al*. Can I drive after those drops, doctor? *Eye* 1998;**12**:963-6.
- 5 **DVLA**. *At a glance guide to the current medical standards of fitness to drive*. Swansea: Drivers Medical Unit, Driver and Vehicle Licensing Authority, 2003.
- 6 **DSA**. Technical Standards Branch, Driving Standards Agency, UK, personal communication. 2005.
- 7 **Montgomery DMI**, Macewan CJ. Pupil dilatation with tropicamide: the effects on acuity, accommodation and refraction. *Eye* 1989;**3**:845-8.

**Table 1** Monocular (RE and LE) and binocular (BE) visual acuity results

Subject	Age (years)	Pre-dilatation			Post-dilatation			Confident to drive?
		RE	LE	BE	RE	LE	BE	
1	23	6/6 <sup>-3</sup>	6/6 <sup>-3</sup>	6/4.8 <sup>-2</sup>	6/6 <sup>-1</sup>	6/6 <sup>-2</sup>	6/6 <sup>-2</sup>	Yes
2	23	6/6	6/6	6/6 <sup>+2</sup>	6/6	6/7.5 <sup>+2</sup>	6/6 <sup>+1</sup>	Yes
3	21	6/6	6/6	6/4.8 <sup>-2</sup>	6/6 <sup>-3</sup>	6/6 <sup>-3</sup>	6/6 <sup>-3</sup>	Yes
4	23	6/6 <sup>+2</sup>	6/6 <sup>+1</sup>	6/6 <sup>+3</sup>	6/7.5 <sup>+2</sup>	6/7.5 <sup>-1</sup>	6/6 <sup>-1</sup>	Yes
5	24	6/6 <sup>-1</sup>	6/6 <sup>+2</sup>	6/6 <sup>-1</sup>	6/6 <sup>-1</sup>	6/6 <sup>-2</sup>	6/6 <sup>-1</sup>	No
6	36	6/7.5 <sup>-1</sup>	6/6 <sup>-2</sup>	6/6 <sup>-1</sup>	6/7.5 <sup>-1</sup>	6/7.5 <sup>-2</sup>	6/7.5	Yes
7	23	6/4.8 <sup>-2</sup>	6/6 <sup>-1</sup>	6/4.8 <sup>-1</sup>	6/6 <sup>-1</sup>	6/7.5 <sup>-1</sup>	6/6 <sup>+2</sup>	Yes
8	27	6/4.8 <sup>+3</sup>	6/4.8 <sup>-1</sup>	6/3.8 <sup>-3</sup>	6/6	6/4.8 <sup>-1</sup>	6/4.8 <sup>+1</sup>	Yes
9	22	6/3.8 <sup>-1</sup>	6/4.8 <sup>-1</sup>	6/4.8 <sup>-1</sup>	6/4.8	6/4.8 <sup>-2</sup>	6/4.8 <sup>-1</sup>	Yes
10	21	6/6 <sup>+1</sup>	6/6 <sup>+2</sup>	6/6 <sup>+3</sup>	6/6 <sup>-1</sup>	6/6	6/6	Yes
11	20	6/6 <sup>-1</sup>	6/6 <sup>-2</sup>	6/4.8 <sup>-1</sup>	6/6 <sup>+2</sup>	6/6 <sup>-1</sup>	6/6 <sup>-2</sup>	Yes
12	23	6/4.8 <sup>-1</sup>	6/6 <sup>-2</sup>	6/4.8 <sup>-1</sup>	6/6 <sup>+2</sup>	6/6 <sup>-1</sup>	6/6 <sup>+3</sup>	Yes
13	23	6/6 <sup>-1</sup>	6/6 <sup>-2</sup>	6/6 <sup>-1</sup>	6/7.5 <sup>+1</sup>	6/7.5 <sup>+2</sup>	6/6	Yes
14	20	6/4.8 <sup>-3</sup>	6/6 <sup>-2</sup>	6/4.8 <sup>-2</sup>	6/4.8 <sup>-2</sup>	6/4.8 <sup>-2</sup>	6/4.8 <sup>-2</sup>	Yes
15	26	6/7.5 <sup>-2</sup>	6/7.5 <sup>+3</sup>	6/6 <sup>-1</sup>	6/9.5 <sup>-1</sup>	6/7.5 <sup>-3</sup>	6/7.5 <sup>-2</sup>	Yes
16	22	6/4.8 <sup>-2</sup>	6/7.5	6/4.8	6/4.8	6/6 <sup>-1</sup>	6/4.8 <sup>-2</sup>	Yes
17	24	6/6 <sup>+3</sup>	6/6 <sup>+2</sup>	6/4.8 <sup>+1</sup>	6/7.5	6/7.5 <sup>+1</sup>	6/6	Yes
18	22	6/4.8 <sup>-3</sup>	6/4.8 <sup>-1</sup>	6/4.8 <sup>+1</sup>	6/6 <sup>-2</sup>	6/6 <sup>-1</sup>	6/6 <sup>+1</sup>	Yes
19	22	6/4.8 <sup>-1</sup>	6/4.8 <sup>+1</sup>	6/4.8 <sup>+1</sup>	6/6 <sup>-2</sup>	6/6 <sup>-1</sup>	6/6	Yes
20	23	6/6 <sup>+2</sup>	6/6 <sup>+3</sup>	6/4.8 <sup>-1</sup>	6/7.5 <sup>-2</sup>	6/7.5 <sup>-3</sup>	6/7.5	Yes

- 8 Goel S, Maharajan P, Chua C, *et al*. Driving ability after pupillary dilatation. *Eye* 2003;17:735–8.
- 9 Wood JM, Garth D, Grounds G, *et al*. Pupil dilatation does affect some aspects of daytime driving performance. *Br J Ophthalmol* 2003;87:1387–90.

### Hydrated scleral buckle: a late complication of MAI explants

Several long term complications have been reported with MAI scleral buckles,<sup>1–3</sup> a synthetic hydrophilic scleral buckling element, first introduced in the 1970s.<sup>1</sup> We present a case of an extruding, hydrated MAI scleral buckle that presented as an orbital lesion. The magnetic resonance imaging (MRI) characteristics of the hydrated MAI buckle are also described.

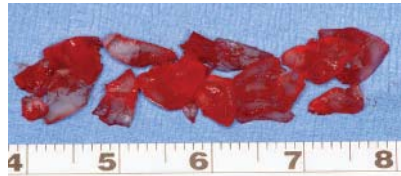#### Case report

An 81 year old woman was referred to the orbital service for evaluation of a freely mobile non-painful subconjunctival lesion in the left eye present for at least a year. The extraocular movement was full but with a small left exotropia in primary gaze. Anterior segment examination revealed a firm, nodular subconjunctival lesion in the superomedial quadrant. The diagnosis of extruding scleral buckle versus a large orbital conjunctival inclusion cyst was entertained. She, however, denied a history of retinal detachment repair.

The patient underwent MRI of the orbits with and without gadolinium infusion which revealed a 2.5×0.7 cm<sup>2</sup> elongated, elliptical mass in the medial intraconal space. The hyperintensity of the mass on T2 weighted images, indicative of high water content, led to the mistaken radiological diagnosis of a cystic, fluid filled lesion (fig 1). Intraoperatively, a swollen intact segmental buckle was encountered that disintegrated into small and large pieces when grasped with a forceps. Complete meticulous removal of these small fragments was performed (fig 2).

#### Comment

MAI hydrogel explant is made of polymethyl acrylate-co-2-hydroxyethyl acrylate crossed linked with ethylene diacrylate with 15% water<sup>2</sup> and was considered an ideal scleral buckling material since it was as effective as solid silicone rubber buckle and sponge but with lower incidence of erosion.<sup>4</sup> However, long term complications are being more frequently recognised with the MAI buckle.<sup>3</sup> Complications include hydration of the



**Figure 2** Hydrated, friable buckle removed in multiple small fragments.

buckle with erosion and extrusion of the explant.<sup>2</sup> Owing to their hydrophilic nature, buckles tend to swell, become bulky, and displace from their intended position. These explants change from an opaque, soft, spongy, whitish appearance to a translucent, gel-like, cream coloured material with hydration.<sup>2</sup> They become extremely friable and fragment easily with slight traction upon removal.<sup>1–3</sup> Scanning electron microscopy of these hydrated buckles has revealed distortion of their micropore architecture.<sup>1,2</sup>

The presentations of hydrated MAI buckles are varied. They can become extremely loose and migrate anteriorly, or enlarge in situ and present as orbital masses. Since complications do not occur until many years after the orbital surgery, the history of a retinal detachment repair may not be elicited. In addition, these loose buckles usually do not indent the globe and may not be recognised as being present on indirect ophthalmoscopy.

Radiological imaging may be helpful. MRI T1 weighted images of a hydrated buckle reveal a well defined, hypointense mass, while T2 weighted images reveal a hyperintense mass as a result of high water content. (In contrast, a silicone element will be black on MRI images.)

Removal of hydrated MAI buckles can be very difficult. Careful sub-Tenon dissection should be carried out since any pressure on the buckle can lead to its fragmentation. The procedure is often complicated because of the extremely friable nature of these buckles. Cryoprobe has been used successfully in some cases for removal of the buckles.<sup>5</sup> Le Rouic *et al* demonstrated that removal of MAI buckles with a cryoprobe is a safe and effective technique with lower fragmentation rate compared to the use of forceps.<sup>5</sup> The cryoprobe allows the water in the swollen explant material to freeze, which helps to reduce fragmentation.

In conclusion, ophthalmologists should be aware of the possible complications of the MAI hydrogel buckles. Knowledge of the MRI characteristics of hydrated MAI buckles may be helpful in identifying them in the event they present as a space occupying orbital mass.

**N Bhagat, A Khanna, P D Langer**

Institute of Ophthalmology and Visual Science, New Jersey Medical School, Newark, NJ 07103, USA

Correspondence to: Paul D Langer, MD, Institute of Ophthalmology and Visual Science, New Jersey Medical School, DOC, Suite 6168, 90 Bergen Street, Newark, NJ 07103, USA; [planger@umdnj.edu](mailto:planger@umdnj.edu)

doi: 10.1136/bjo.2005.072280

Accepted for publication 10 April 2005

Supported by an unrestricted grant from Research to Prevent Blindness.

Competing interests: none declared

#### References

- Oshitari K, Hida T, Okada AA, *et al*. Long-term complications of hydrogel buckles. *Retina* 2003;23:257–61.
- Marin JF, Tolentino FI, Refojo MF, *et al*. Long-term complications of the MAI hydrogel intrascleral buckling implant. *Arch Ophthalmol* 1992;110:86–8.
- Hwang KI, Lim JI. Hydrogel explant fragmentation 10 years after scleral buckling surgery. *Arch Ophthalmol* 1997;115:1205–6.
- Ho PC, Chan IM, Refojo MF, *et al*. The MAI hydrophilic implant for scleral buckling: a review. *Ophthalmic Surg* 1984;15:511–15.
- Le Rouic JF, Bejjani RA, Azan F, *et al*. Cryoextraction of episcleral Miragal buckle elements: a new technique to reduce fragmentation. *Ophthalmic Surg Lasers* 2002;33:237–9.

### Complex I respiratory defect in LHON plus dystonia with no mitochondrial DNA mutation

Leber hereditary optic neuropathy (LHON) sometimes occurs with dystonia<sup>1</sup> in association with mitochondrial DNA (mtDNA) mutations in complex I.<sup>2</sup> We describe a patient with LHON plus dystonia who had a severe complex I respiratory defect with no pathological mtDNA mutation, implying a mitochondrial abnormality of nuclear origin.

#### Case report

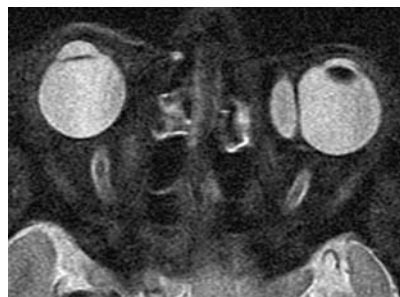The proband was healthy until age 17 years when she developed progressive right sided weakness followed 5 years later by a left hemiparesis with involuntary posturing of the left arm and leg. Intelligence was average, and she finished grade 6 at school. Her parents were unrelated, and she had five healthy siblings.

Neuro-ophthalmological examination at age 23 documented excellent afferent and efferent visual functioning with no Kaiser-Fleischer ring. Optic discs were hyperaemic and slightly elevated with peripapillary telangiectasias in both eyes (fig 1A and B). She had modest right sided weakness, diffuse hyper-reflexia greater on the right, bilateral Babinski signs, and dystonic posturing on the right while walking.

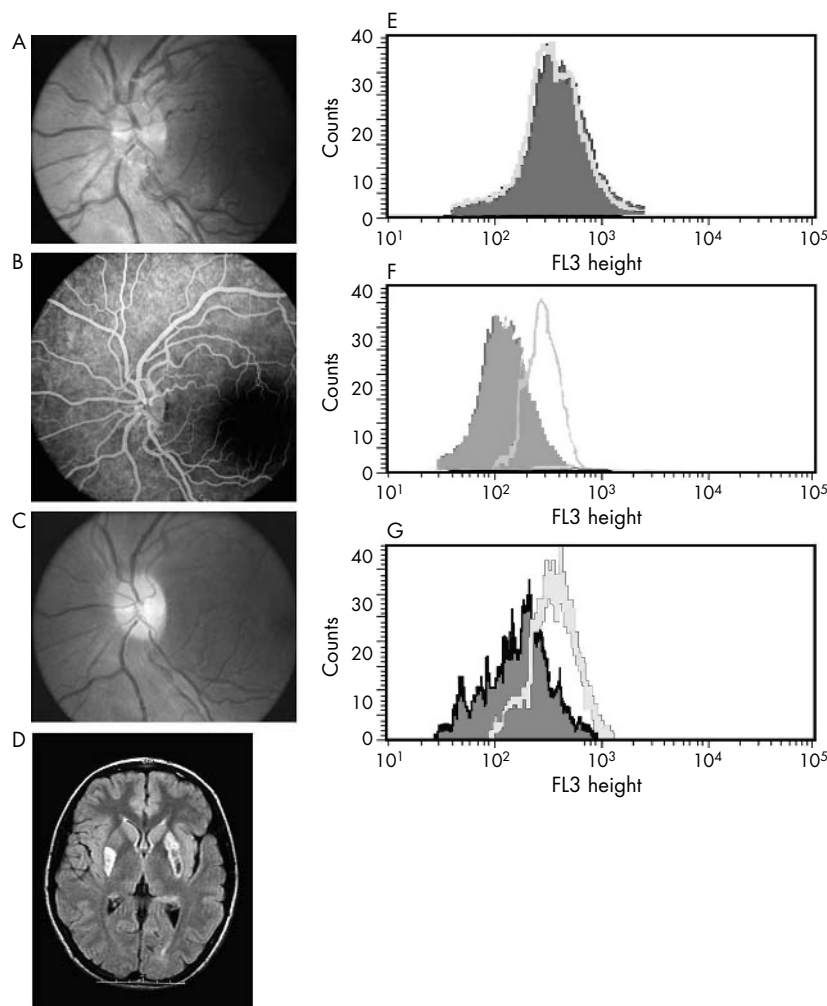
On return 21 months later, she reported that the vision of both eyes had declined 9 months previously. Visual acuity was 20/100 in both eyes with poor colour vision in both eyes, a mild left afferent pupillary defect, and bilateral optic atrophy with no residual hyperaemia or peripapillary telangiectasias (fig 1C). Gait was somewhat worse, and she was modestly dysarthric. Vision did not improve during 18 months of follow up.

Normal laboratory studies included haemogram, liver and renal function, serum lactate, pyruvate, and 24 hour urine copper excretion. Cerebral spinal fluid (CSF) lactic acid was slightly elevated (2.8 mmol with normal range 0.6–2.2 mmol), and brain MRI revealed abnormalities in both basal ganglia (fig 1D).

After signing informed consent, the proband, her mother and father, and four siblings had blood drawn for DNA extraction, polymerase chain reaction amplification, and sequencing of the entire mitochondrial genomic coding region as previously described.<sup>3</sup> Sequence results were compared to Mitomap ([www.mitomap.org/mitomap/mitoseq.html](http://www.mitomap.org/mitomap/mitoseq.html)), the human mitochondrial genome database ([www.genpat.uu.se/mtDB](http://www.genpat.uu.se/mtDB)), GenBank ([www.ncbi.nlm.nih.gov/Genbank/index.html](http://www.ncbi.nlm.nih.gov/Genbank/index.html)), and



**Figure 1** T2 weighted MRI image reveals a hyperintense mass exhibiting a mass effect on the left globe.



**Figure 1** (A) Fundus photograph of left optic disc showing hyperaemia and peripapillary telangiectasias. The right disc had a similar appearance. (B) Intravenous fluorescein angiogram of left optic disc confirming tortuous vessels with no leakage of fluorescein typical of the pseudopapilloedema of LHON. This photograph was taken at 5:45. The right disc had a similar appearance. (C) Fundus photograph of left optic disc taken 9 months after visual loss showing modest diffuse pallor of the disc with resolution of disc elevation and peripapillary telangiectasias. The right disc had a similar appearance. (D) Brain magnetic resonance imaging (MRI, Flair TR 9502 TE 138/EF) showing bilateral basal ganglion lesions affecting predominantly the putamen, left>right, with parenchymal loss and hyperintense signal implying gliosis without mass effect. Small T2 hyperintense signal abnormalities were also present in the diencephalon, the cerebral peduncles, and the periaqueductal region. (E), (F), and (G) Overlain histograms showing fluorescence in uninhibited lymphoblasts (dark grey peaks) and in lymphoblasts inhibited with rotenone (light grey peaks) in the patient (E), unaffected sibling (F), and normal control (G). X axis is a logarithmic scale quantifying pulse of fluorescence detected by the flow cytometer; Y axis is a logarithmic scale of number of cells. Dark grey peaks represent fluorescence of cells incubated with dihydroethidium (DHE) only. Light grey peaks represent fluorescence of cells incubated with DHE and rotenone, which inhibits activity of mitochondrial complex I. Fluorescence increased almost three-fold in control cells (G) and cells of the unaffected sibling (F) after incubation with rotenone (20  $\mu$ M), while the patient's cells showed no increase in fluorescence because of pre-existing inhibition, indicating a complex I respiratory defect. This experiment was repeated four times with similar results.

a normal control group of 119 people with no medical problems, who share similar ethnicity with the proband. Mitochondrial respiratory function in complexes I, III, IV, and V was assessed in the proband and one unaffected sibling using a previously described flow cytometric functional analysis method.<sup>3,4</sup>

The proband, her siblings, and their mother had one mtDNA sequence variant recognised as a polymorphism in the Japanese population,<sup>5</sup> which was not present

in the 119 normal controls of similar ethnicity. Thirteen previously reported homoplasmic mtDNA polymorphisms were detected in the proband, her family, and the control group. The proband, but not her unaffected brother, had a severe respiratory defect in complex I (fig 1E, F, and G).

#### Comment

This young woman's initial examination was significant for normal vision with hyperaemic

optic discs, pseudopapilloedema, and peripapillary telangiectasias. She went on to develop bilateral optic nerve injury typical of LHON. She also had progressive basal ganglion and upper motor neuron disease culminating in bilateral spasticity, a broad based and unsteady gait, dystonia, and dysarthria. Her clinical course, elevated CSF lactate, normal urinary copper excretion, and severe complex I respiratory defect imply a mitochondrial mechanism for optic nerve and brain injury.

Mitochondrial complex I dysfunction in the absence of a pathological mtDNA mutation provides presumptive evidence of a mitochondrial abnormality of nuclear origin. Complex I dysfunction has been identified in patients with sporadic focal dystonia,<sup>6</sup> and at least one familial generalised dystonia syndrome had a defined nuclear mutation affecting a mitochondrial protein.<sup>7</sup> Other patients with LHON plus dystonia have had complex I mtDNA mutation(s), so this patient broadens the genetic circumstance in which the phenotype may be expected.

**K K Abu-Amero**

Genetics Department, King Faisal Specialist Hospital and Research Centre, Riyadh, Saudi Arabia

**T M Bosley, S Bohlega, D McLean**

Neuroscience Department, King Faisal Specialist Hospital and Research Centre, Riyadh, Saudi Arabia

Correspondence to: Dr Khaled K Abu-Amero, Department of Genetics, King Faisal Specialist Hospital and Research Center (MBC No 03), PO Box 3354, Riyadh 11211, Saudi Arabia; [kamero@kfshrc.edu.sa](mailto:kamero@kfshrc.edu.sa)

doi: 10.1136/bjo.2005.072819

Accepted for publication 10 April 2005

#### References

- 1 Nikoskelainen EK, Marttila RJ, Huoponen K, *et al*. Leber's "plus": neurological abnormalities in patients with Leber's hereditary optic neuropathy. *J Neurol Neurosurg Psychiatry* 1995;**59**:160-4.
- 2 Tarnopolsky MA, Baker SK, Myint T, *et al*. Clinical variability in maternally inherited leber hereditary optic neuropathy with the G14459A mutation. *Am J Med Genet A* 2004;**124**:372-6.
- 3 Abu-Amero KK, Bosley TM, Bohlega S, *et al*. Mitochondrial T9957C mutation in association with NAION and seizures but not MELAS. *Ophthalmic Genet* 2005;**26**:31-6.
- 4 Setterfield KWA, Donald J, Thorburn DR, *et al*. Flow cytometry in the study of mitochondrial respiratory chain disorders. *Mitochondrion* 2002;**1**:437-45.
- 5 Tanaka M, Cabrera VM, Gonzalez AM, *et al*. Mitochondrial genome variation in eastern Asia and the peopling of Japan. *Genome Res* 2004;**14**:1832-50.
- 6 Schapira AH, Warner T, Gash MT, *et al*. Complex I function in familial and sporadic dystonia. *Ann Neurol* 1997;**41**:556-9.
- 7 Binder J, Hofmann S, Kreisel S, *et al*. Clinical and molecular findings in a patient with a novel mutation in the deafness-dystonia peptide (DDP1) gene. *Brain* 2003;**126**(Pt 8):1814-20.

#### Retinal haemorrhages in a young patient with homocysteinuria

The most common ocular complication in homocysteinuria is lens subluxation.<sup>1</sup> We present a patient with homocysteinuria who developed subhyaloid haemorrhages during pars plana vitrectomy/lensectomy for a subluxated lens in the right eye. She had also developed preretinal and intraretinal haemorrhages in her fellow eye 6 months earlier,

after phacoemulsification of the subluxated lens. No preoperative or intraoperative anti-coagulation was used for either eye surgeries.

### Case report

A 12 year old girl with homocysteinuria presented with decreased vision in the right eye as a result of an anteriorly luxated lens causing pupillary block glaucoma with an intraocular pressure (IOP) of 50 mmHg. The posterior segment was normal. She had undergone phacoemulsification and anterior vitrectomy for pupillary block glaucoma caused by subluxated lens in the fellow eye 6 months earlier. Retinal examination post-operatively revealed preretinal and intraretinal haemorrhages in the mid-periphery (fig 1), which cleared spontaneously over the next 5 months.

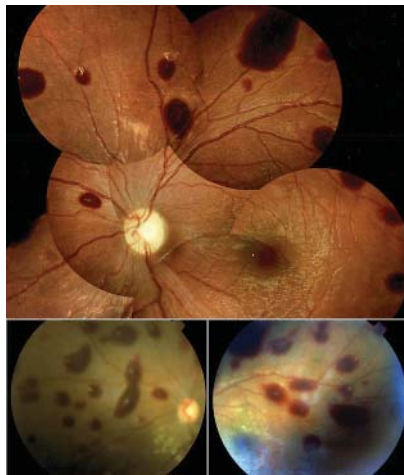Since medical therapy was ineffective in the right eye, she underwent pars plana lensectomy and vitrectomy. As the core vitrectomy was initiated, small subhyaloid haemorrhages were noted to develop in the mid-periphery. The vitrectomy settings were changed to a high cutting speed and low aspiration but the haemorrhages continued to form. Induction of the posterior vitreous detachment was aborted when peripapillary intraretinal haemorrhages were noted to develop.

On the first postoperative day, a 2 disc diameter subhyaloid haemorrhage (not seen at the end of the surgery) was noted in the macula (fig 2). All haemorrhages resolved spontaneously over the next 10 weeks.

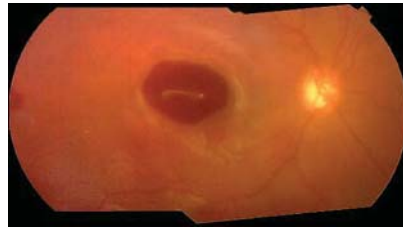
### Comment

The precise mechanism of action of homocysteine on the vascular tree is not well understood. Elevated homocysteine levels can cause endothelial disruption, structural damage by toxic effects on the intima and media, increased oxidation of low density lipoproteins, and alterations of clotting factors leading to a hypercoagulable state.<sup>2</sup>

Histopathological data derived primarily from animal models demonstrate smooth muscle cell hypertrophy and hyperplasia of the arteries.<sup>3</sup> Postmortem studies of



**Figure 1** Fundus photographs of the left eye 3 days after undergoing phacoemulsification and anterior vitrectomy for an anteriorly subluxated lens. Multiple ovoid subhyaloid preretinal and intraretinal haemorrhages are noted in the mid-periphery of the retina.



**Figure 2** Fundus photographs of the right eye 1 day after pars plana vitrectomy and pars plana lensectomy for an anteriorly subluxated lens. A 2 disc diameter subhyaloid haemorrhage is seen in the macula along with one preretinal haemorrhage temporal to the macula. Photographs of other mid-peripheral retinal haemorrhages could not be taken owing to the patient's non-cooperation.

hyperhomocysteinaemic patients have shown intimal and medial thickening with disruption of the internal elastic lamina of small and large vessels.<sup>4</sup> Histopathology of small arteries reveal focal proliferation of connective tissue with increased fibroblasts, collagen, and irregular elastic fibres.<sup>4</sup> These changes may contribute to the fragility of small arteries and capillaries.

Valsalva retinopathy sometimes occurs with general anaesthesia. We do not believe this patient experienced this mainly because Valsalva retinopathy is bilateral. The retinal haemorrhages occurred only in the operated eye and not the fellow eye each time the patient underwent surgery.

The haemorrhages noted postoperatively in the left eye may have occurred because of ocular decompression retinopathy. An acute lowering of IOP can decrease the resistance of the retinal and choroidal circulation, temporarily overwhelming the capacitance of the capillary bed and resulting in multiple endothelial leaks and intraretinal haemorrhages.<sup>5</sup> Hyperhomocysteinaemia can affect the autoregulation of small arteries.<sup>2,3</sup> This may have contributed to the development of retinal haemorrhages in the left eye. The subhyaloid haemorrhages in the right eye, however, were unlikely to be related to ocular decompression retinopathy since no haemorrhages were seen during pars plana lensectomy, but these developed soon after vitrectomy was initiated. Minimal traction transmitted to the internal limiting membrane and nerve fibre layer by the vitrectomy may have caused the extremely friable superficial capillaries to rupture. Indeed, defects in retinal vascular autoregulation due to homocysteinuria, may have contributed to the development of the observed haemorrhages.

We hypothesise that individuals with chronic hyperhomocysteinaemia are at an increased risk for retinal haemorrhages because of homocysteine mediated destructive changes in small vessel walls and an autoregulatory defect that results in extreme capillary fragility.

**R A Shah, M A Zarbin, N Bhagat**

Institute of Ophthalmology and Visual Science, New Jersey Medical School, Newark, NJ 07103, USA

Correspondence to: Neelakshi Bhagat, MD, MPH, Institute of Ophthalmology and Visual Science, New Jersey Medical School, Doctor's Office Center; No 6168, 90 Bergen Street, Newark, NJ 07103, USA; [bhagatne@umdnj.edu](mailto:bhagatne@umdnj.edu)

doi: 10.1136/bjo.2005.072330

Accepted for publication 12 April 2005

This work was supported by Research to Prevent Blindness Inc, the Lions Eye Research Foundation of New Jersey, and the Eye Institute of New Jersey.

### References

- 1 Michalski A, Leonard JV, Taylor DS. The eye and inherited metabolic disease: a review. *J Roy Soc Med* 1988;**81**:286–90.
- 2 Cook JW, Taylor LM, Orloff SL, et al. Homocysteine and arterial disease. Experimental mechanisms. *Vasc Pharmacol* 2002;**38**:293–300.
- 3 Van Guldener C, Stehouwer CD. Hyperhomocysteinemia, vascular pathology, and endothelial dysfunction. *Sem Thrombosis Hemostasis* 2000;**26**:281–9.
- 4 McCully KS. Vascular pathology of homocysteinemia: implications for the pathogenesis of arteriosclerosis. *Am J Pathol* 1969;**56**:111–28.
- 5 Nah G, Aung T, Yip C. Ocular decompression retinopathy after resolution of acute primary angle closure glaucoma. *Clin Experiment Ophthalmol* 2000;**28**:319–20.

### Internet based ophthalmology service: impact assessment

In 2003, the Department of Health, Western Australia, commenced a teleophthalmology service between Carnarvon Regional Hospital (CRH) and Lions Eye Institute (LEI) at City of Perth (at 940 km), pioneering the use of remote, interactive consultations in ophthalmology. This assessment (a) reports the impact of teleophthalmology service on patient diagnosis, management, outcomes, and satisfaction; and (b) estimates the costs of teleophthalmology service.

### Case report

An internet based system ([www.e-icare.com](http://www.e-icare.com)) developed and evaluated at LEI, was used to store and transmit multimedia data to a secure, central database.<sup>1</sup> Practitioners at CRH collected these data, which included patients' demographic details, medical history, and ocular images. A portable slit lamp developed at LEI,<sup>2</sup> tonometer (Keeler Pulsair 3000, Japan), and digital retinal camera (Canon CR4-45NM, Japan) were also used. A questionnaire and interview approach assessed the satisfaction of the patients and practitioners. Estimation of costs analysed additional activity data and associated costs.

During the 12 month study period, there were 118 teleophthalmology consultations (42% men, 58% women, mean age 42 years, range 4–73 years). Most patients (53%) became aware of the service through local media, while health professionals in Carnarvon referred 36% for teleophthalmology consultation. Of the 118 cases, 3% of the patients used teleophthalmology for emergency consultation, 94% for testing for glaucoma and diabetic retinopathy; 3% of the cases were for expert second opinion and postoperative follow up.

Teleophthalmology proved to have impact on all the patients, by improving the eye care facility at CRH itself, instead of the need to travel 940 km to the city. Following teleconsultation, only 3% of patients were referred to a city hospital. While 55% of patients had no abnormalities detected, 3% of patients received treatment at CRH itself. The ophthalmologist recommended regular follow up for 36% of patients seen by telemedicine.

The teleophthalmology consultation cost per patient, at current efficiency level, is \$279.96 including fixed cost. A cost neutral analysis estimated, at optimal efficiency of 352 patients per annum, cost per patient would decrease to \$107.72. In the remote area, without teleophthalmology, the cost to the service provider for a face to face consultation with an ophthalmologist is as high as \$665.44 per patient. The minimum number of patients needed to make a cost effective teleophthalmology consultation is 126 per annum.

The majority of patients (98%) expressed satisfaction with the internet based consultation and observed it as convenient. Lack of physical contact with ophthalmologist was not a major concern to many patients (74%). CRH practitioners spoke favourably of using teleophthalmology, in that they were able to get advice from colleagues and discuss alternative management strategies. Practitioners at LEI found the experience informative and challenging.

### Comment

While acknowledging that face to face consultations with ophthalmologists are unique, its costs are enormous in remote health centres.<sup>3-5</sup> The project is a technical and clinical success and one that led to direct potential benefits for patients in terms of improved outcomes, as well as considerable educational experience for the participating medical practitioners. However, current assessment brought to light the importance of redefining utilisation criteria in order to achieve efficiency. For example, 126 patients per annum are required for a cost effective teleophthalmology service while the current efficiency rate is 118 per annum (2.2 patients per week). Better coordination between the local healthcare workforce and CRH may increase the number of teleophthalmology consultations, which in turn will help to achieve breakeven or even establish net savings. Overall, this assessment indicates that the success of teleophthalmology will be based upon identifying the requirements of the service and using appropriate technology.

### Acknowledgements

Supported by an IPRS Scholarship and UPA(IS) Award from University of Western Australia. The authors thank the Department of Health, Western Australia, Mr Francisco Chaves (health economist), and Ms Beth Hudson for her support and assistance especially in data collection. The authors also thank the patients, clinical staff, and administrative officers in CRH, Carnarvon and at LEI, City of Perth for their assistance.

**S Kumar, M-L Tay-Kearney, I J Constable, K Yogesan**

Lions Eye Institute, University of Western Australia, Nedlands, WA 6009, Australia

Correspondence to: Sajeesh Kumar, Lions Eye Institute, University of Western Australia, 2 Verdun Street, Nedlands, WA 6009, Australia; [sajeesh@cyllene.uwa.edu.au](mailto:sajeesh@cyllene.uwa.edu.au)

Ethical approval was obtained from the University of Western Australia Human Ethics Committee and the Western Australia Aboriginal Health Information Ethics Committee.

doi: 10.1136/bjo.2005.072579

Accepted for publication 12 April 2005

Competing interests: none declared

### References

- 1 **Yogesan K, Constable IJ, et al.** International transmission of tele-ophthalmology images. *J Telemed Telecare* 2000;**5**:41-4.
- 2 **Yogesan K, Cuyppers M, et al.** Tele-ophthalmology screening for retinal and anterior segment diseases. *J Telemed Telecare* 2000;**5**:96-8.
- 3 **Keeffe JE, Weih LM, et al.** Utilisation of eye care services by urban and rural Australians. *Br J Ophthalmol* 2002;**86**:24-7.
- 4 **Whitten PS, Mair FS, et al.** Systematic review of cost effectiveness studies of telemedicine interventions. *BMJ* 2002;**324**:1434-7.
- 5 **Sajeesh KR, Mei-Ling TK, Chaves F, et al.** Remote ophthalmology services: cost comparison of telemedicine and alternate scenarios. *J Telemed Telecare* (in press).

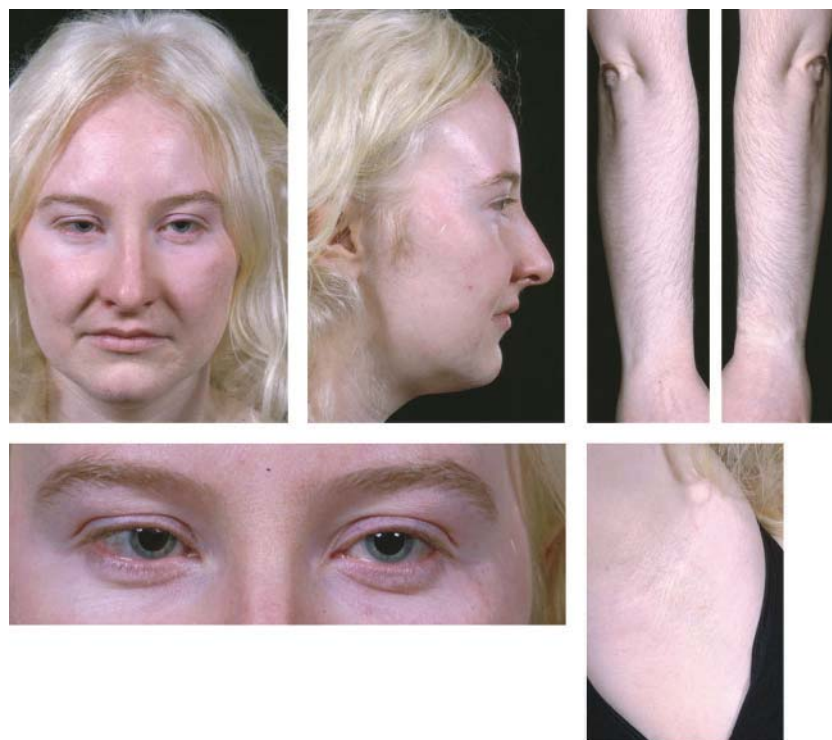### Temperature sensitive oculocutaneous albinism associated with missense changes in the tyrosinase gene

Oculocutaneous albinism (OCA) describes a group of autosomal recessive disorders characterised by reduced or absent pigmentation of the eye, skin, and hair as a result of a congenital reduction in melanin synthesis. Additional findings in the eye include decreased visual acuity, nystagmus, iris transillumination, hypopigmentation of the uveal tract and retinal pigment epithelium, foveal hypoplasia, and abnormal decussation of the optic nerve fibres at the optic chiasm leading to a lack of binocular vision.<sup>1-2</sup> Type I OCA results from mutations in the tyrosinase gene and leads to either total absence of tyrosinase activity (OCA 1a) associated with absence of pigmentation ("tyrosinase negative"), or a marked reduction in tyrosinase activity (OCA 1b) associated with reduced pigmentation

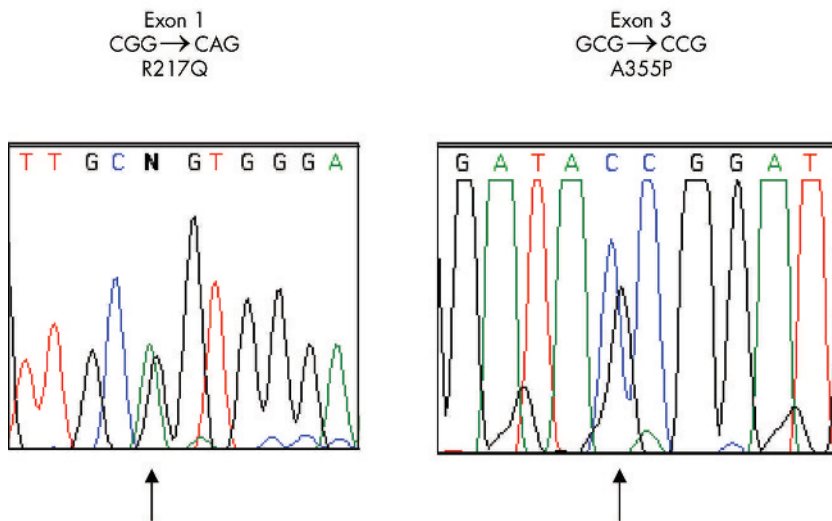
("tyrosinase positive" or "yellow albinism"). We report a new case of the rare variant temperature sensitive albinism and our identification of missense mutations in the tyrosinase gene, not previously found in this form of albinism.

### Case report

The patient, a 31 year old woman, was referred to us for genetic advice. She had originally presented at 6 weeks old with nystagmus and white hair; her parents both have dark hair and olive skin. The diagnosis of oculocutaneous albinism was made at 9 months. As she grew older the hair of her head darkened and, particularly in her teens, the hair on her lower legs and forearms darkened. As an adult she has light blonde hair, darker eye lashes and eyebrows, white axillary and pubic hair, but strongly pigmented hair on forearms and lower legs (fig 1). When examined in the clinic she had reduced visual acuity (6/36 bilaterally), marked iris translucency, and an albinotic retina with foveal hypoplasia bilaterally. Visually evoked potential revealed crossed asymmetry consistent with oculocutaneous albinism. We made a diagnosis of temperature sensitive albinism and searched for mutations in the tyrosinase gene. Blood was taken, with informed consent, from the patient and her parents and DNA extracted using standard techniques. Using polymerase chain reaction we amplified each of her tyrosinase gene exons<sup>3</sup> and sequenced the entire coding region and intron-exon boundaries. Our patient did not have the R422Q mutation previously reported in patients with this phenotype and also did not have two other mutations known to be temperature sensitive.<sup>4</sup> We did identify two missense mutations: R217Q and A355P, in exons 1 and 3 respectively (fig 2). The exon 1 mutation had been inherited from her



**Figure 1** Clinical photographs of patient. Note the yellow blonde hair, dark eyebrows, and strongly pigmented forearm hair. (Photograph reproduced with permission of the patient.)



**Figure 2** Mutations in tyrosinase gene.

mother and the exon 3 mutation from her father. R217Q has been previously reported in OCA1,<sup>5</sup> and A355P in OCA1b in a patient with “little apparent pigmentation” but with no description of the distribution of the pigmentation.<sup>6</sup> Neither has previously been associated with a temperature sensitive phenotype.

### Comment

Temperature sensitive albinism is a rare variant, first described in 1991<sup>1</sup> and subsequently associated with a particular missense mutation in the tyrosinase gene.<sup>1</sup> The mutation, R422Q, results in a temperature sensitive trafficking defect preventing the translocation of the mutant tyrosinase into melanosomes.<sup>4</sup> Thus, at 37°C mutant R422Q tyrosinase is retained in the endoplasmic reticulum and degraded by proteasomes and no pigment is produced. At lower temperatures (31°C) the enzyme can be successfully translocated into the melanosomes and can produce pigment. This leads to a phenotype reminiscent of the Siamese cat with no pigment centrally but pigmentation develops in the peripheries (lower legs and forearms).

Our patient is heterozygous for missense mutations in the tyrosinase gene that have both previously been reported in OCA1 but neither with a temperature sensitive phenotype. We are not aware of other patients with this particular combination of mutations. It has been shown that co-expression of wild type tyrosinase can correct the mutant conformation in temperature sensitive alleles such that exit from the endoplasmic reticulum and complex carbohydrate processing in the Golgi is promoted even at the non-permissive temperature.<sup>7</sup> It may be that one of the mutant alleles identified in our patient modulates the expression of the other, revealing its temperature sensitive nature whereas coexpression with a different allele may give no residual activity. Alternatively, this phenotype may be much commoner than previously thought. To date there have been no studies of function or response to temperature variation of these particular mutant forms of tyrosinase. In light of the phenotype we describe here these studies would be valuable. Furthermore, it is not unusual for

patients with albinism to report development of some pigmentation with age and it would be interesting to review other patients with these mutations. Unless patients with albinism are reviewed later in life this developing phenotype will not be noted.

**T Wang, C T Waters, T Jakins, J R W Yates, D Trump**

Department of Medical Genetics, Cambridge Institute for Medical Research, University of Cambridge, UK

**K Bradshaw**

Department of Ophthalmology, Addenbrooke's Hospital Trust, Cambridge, UK

**A T Moore**

Institute of Ophthalmology and Moorfields Eye Hospital, London, UK

**T Wang, D Trump**

Academic Unit of Medical Genetics, St Mary's Hospital and Centre for Molecular Medicine, Faculty of Medical and Human Sciences, University of Manchester, UK

Correspondence to: Professor Dorothy Trump, Academic Unit of Medical Genetics, St Mary's Hospital, Hathersage Road, Manchester M13 0JH, UK; [dorothy.trump@manchester.ac.uk](mailto:dorothy.trump@manchester.ac.uk)

doi: 10.1136/bjo.2005.070243

Accepted for publication 18 April 2005

### References

- 1 King RA, Jackson IJ, Oetting WS. Human albinism and mouse models. In: Wright AF, Jay B, eds. *Molecular genetics of inherited eye disorders*. New York: Harwood Academic Publishers, 1994;89–122.
- 2 Abrams LS, Traboulsi E. Albinism. In: Traboulsi E, eds. *Genetic diseases of the eye*. New York: Oxford University Press, 1998;697–722.
- 3 Giebel LB, Strunk KM, Spritz RA. Organization and nucleotide sequences of the human tyrosinase gene and a truncated tyrosinase-related segment. *Genomics* 1991;**9**:435–45.
- 4 Toyofuku K, Wada I, Spritz RA, et al. The molecular basis of oculocutaneous albinism type 1 (OCA1): sorting failure and degradation of mutant tyrosinases results in a lack of pigmentation. *Biochem J* 2001;**355**(Pt 2):259–69.
- 5 Oetting WS, King RA. Molecular analysis of type I-A (tyrosinase negative) oculocutaneous albinism. *Hum Genet* 1992;**90**:258–62.
- 6 Spritz RA, Oh J, Fukai K, et al. Novel mutations of the tyrosinase (TYR) gene in type I oculocutaneous albinism (OCA1). *Hum Mutat* 1997;**10**:171–4.
- 7 Halaban R, Cheng E, Hebert DN. Coexpression of wild-type tyrosinase enhances maturation of temperature-sensitive tyrosinase mutants. *J Invest Dermatol* 2002;**119**:481–8.

### Choroidal neovascularisation associated with meningioma

This report documents the occurrence in three patients of subretinal choroidal neovascular membranes (CNVM) ipsilateral to meningiomas involving the optic nerve. We propose that the association might not be coincidental.

#### Case 1

A 31 year old woman developed a central scotoma in the left eye that led to the diagnosis of a left sphenoid wing meningioma involving the optic canal. The tumour was resected and her vision returned to normal. At age 56 a generalised seizure led to recognition of a recurrence. When the recurrent tumour was resected it proved to be a malignant meningioma. She was then treated with photon radiation from a 10 MV source using a three field technique (right lateral, left lateral, and superior). The total dose was 45 Gy administered in 25 fractions. Thereafter, on regular follow up eye examinations she had normal visual function, pupils, and fundi. At the age of 64 she had a single episode in which for several seconds she lost all vision in the left eye except for a nasal island. There were no residua but her ophthalmologist found a new fundus abnormality that prompted referral.

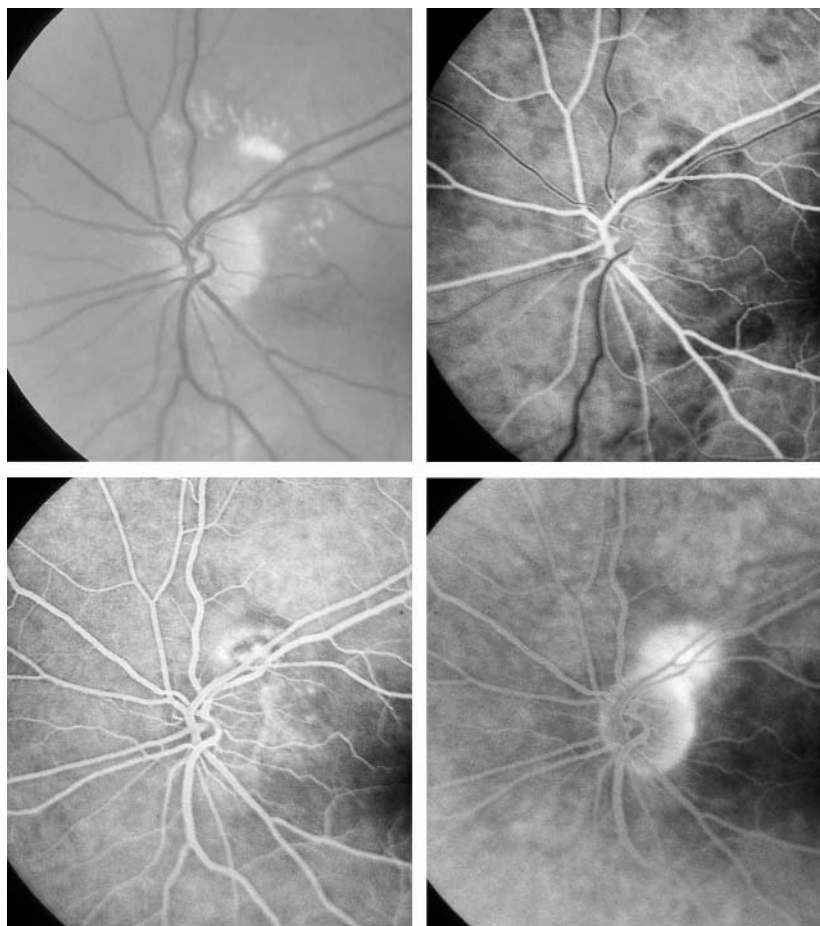
Her medical history included migraine and a cutaneous malignant melanoma. There was no pertinent family history.

The patient's visual acuities were 20/15 in each eye. Her colour vision (Ishihara) and pupils were normal. The Goldmann visual field of her right eye was full but she had a relative inferior altitudinal defect to the I2e white stimulus in the left eye. There was 3 mm of proptosis of the left eye with normal orbital resiliency. Fundus examination of the left eye revealed a peripapillary superotemporal retinal elevation associated with lipid (fig 1, top left). There were no macular drusen. Echography showed 1.1 mm of elevated retina adjacent to the left disc with normal acoustics. The rest of her neuro-ophthalmological examination was normal. There was hyperfluorescence in the area of elevation with late leakage of dye on fluorescein angiography consistent with a peripapillary CNVM (fig 1). At that time magnetic resonance imaging (MRI) scans showed no evidence of recurrent meningioma.

Five years later the vision declined to 20/30 in the left eye. There was neither optic atrophy nor optic disc swelling, but a left afferent pupillary defect and dyschromatopsia were observed. MRI showed that the sphenoid meningioma had recurred and involved the intracanalicular and posterior orbital segments of the left optic nerve. There also was enlargement of the posterior bellies of the left inferior and lateral rectus muscles.

#### Case 2

An 89 year old woman had cataract surgery on her left eye in December 2000 and her right eye in February 2001. She initially saw well following surgery; however, in August



**Figure 1** Patient 1. Retinal elevation and lipid exudation superotemporal to the left optic disc (top left). Venous laminar (top right), arteriovenous transit (bottom left), and late phases (bottom right) of the fluorescein angiogram demonstrates peripapillary hyperfluorescent area growing in size and fluorescence consistent choroidal neovascularisation.

2001 she noted blurring of the vision in her left eye and a peripapillary CNVM was discovered. Despite two laser applications the patient's vision continued to worsen.

Her medical history included rheumatic heart disease, hypertension, and hypercholesterolaemia. In February 2001 she had endocarditis complicated by a left hemiplegia. There was no family history of any pertinent disorder.

Her visual acuities were 20/20 in the right eye and 7/200 in the left. She had dyschromatopsia of the left eye with 2 mm of proptosis and a relative afferent pupil defect. Goldmann perimetry revealed a full visual field in the right eye and only a residual nasal island in the left. The fundus of the right eye was normal without drusen. Her left optic disc was pale and there was nerve fibre layer swelling and haemorrhage adjacent to the nerve. MRI showed a 1.4×1.2×1.2 cm homogeneously enhancing mass along the left planum sphenoidale extending into the left optic canal consistent with a meningioma.

### Case 3

A 47 year old woman noticed that she had a painless visual disturbance of her right eye "like looking through a glass of water." The symptom persisted, and 2 months later she awoke with a blind right eye. An MRI scan was interpreted as normal and her blindness

was ascribed to optic neuritis. She was treated with a course of corticosteroids during which she recovered some vision but her vision failed again after the steroids were discontinued and thereafter she was unable to see light.

She had a history of asthma and obesity. Her father had age related macular degeneration.

At the age of 49 she noticed metamorphopsia in the left eye, and a large, elevated, extrafoveal CNVM was found. Echography revealed 1.3 mm of elevation, which was acoustically normal. Vision was then 20/20. The right optic disc was atrophic and the left was normal. There were no macular drusen. She failed to respond to laser photocoagulation and proton beam radiation. Vision failed to 3/200 and the left disc became oedematous. MRI scanning showed bilateral optic nerve sheath enlargement and gadolinium enhancement of the mid and posterior segments of both optic nerves and extension of the lesion on the right side over the planum towards the chiasm. The lesions were interpreted as primary optic nerve sheath meningiomas.

### Comment

Choroidal neovascularisation has been associated with macular degeneration, histoplasmosis, pathological myopia, angioid streaks,

optic nerve drusen, optic nerve pits, pseudo-tumour cerebri, chronic inflammation, infection, malignant melanoma, choroidal osteomas, choroidal naevi, photocoagulation, and choroidal rupture. A break in Bruch's membrane seems to be a common feature in CNV, but the exact pathogenesis remains a subject of debate.<sup>1,2</sup>

While we cannot eliminate the possibility that the association of CNV with meningiomas and CNV in our patients is merely by chance, several observations suggest otherwise. In each case the fundus of the fellow eye was free of drusen, let alone more substantive evidence of macular degeneration. None of the patients had a disorder known to predispose to CNV. There has been one report of CNV after radiation but in that case the patient also had significant radiation retinopathy.<sup>3</sup> Our irradiated patient (case 1) had no evidence of radiation retinopathy and the radiation portals spared the eye. One of our patients was only 49 years old when the membrane was recognised. In two of our patients the membrane was peripapillary.

Schatz *et al* published the histopathological findings in a patient with a primary optic nerve sheath meningioma in which there was a CNV. However, their patient had chronic disc oedema and venous collaterals and had antecedent age related macular degeneration in both eyes.<sup>4</sup> Shields *et al* described an instance of CNV in a child with an optic nerve glioma. That patient's disc was also oedematous.<sup>5</sup> Peripapillary CNV has been described with chronic disc oedema of other causes as well,<sup>6</sup> but two of our patients never had disc swelling and the third developed disc oedema only after the CNV was recognised.

How might a meningioma cause an ipsilateral CNV? The pathophysiological mechanism by which these two conditions occur together is unclear. It is possible that the tumour tissue could have invaded the eye. CNV has been associated with other tumours involving the choroid.<sup>1,2</sup> Ocular invasion was not evident on ultrasound (cases 1 and 3) or MRI scans but absence of proof is not proof of absence. In the case of Schatz *et al* there were small foci of the meningioma in the peripapillary sclera and retrolaminar optic nerve, which were not seen before enucleation.<sup>4</sup> Dutton reviewed meningiomas involving the optic nerve and primary optic nerve sheath meningiomas. CNV was not mentioned as a presenting sign. None the less, he calculated 3.7% of 477 reported cases described intraocular invasion by meningiomas.<sup>7</sup> Other authors have reported histopathological cases of meningioma invading the optic nerve and disc.<sup>8-10</sup>

We believe that the association of CNV with ipsilateral meningiomas in our patients was not one of chance. The presumed mechanism is invasion of the globe by the tumour sufficient to cause the CNV but below threshold for detection by MRI, ultrasound, or ophthalmoscopy.

**M S Lee**

Cole Eye Institute, The Cleveland Clinic Foundation, Cleveland, OH 44195, USA

**S Lessell**

Neuro-ophthalmology Unit, Massachusetts Eye and Ear Infirmary, Harvard Medical School, Boston, MA 02114, USA

Correspondence to: Michael S Lee, MD, Cole Eye Institute/I-32, The Cleveland Clinic Foundation, 9500

Euclid Avenue, Cleveland, OH 44195, USA;  
leem4@ccf.org

Presented in part at the North American Neuro-ophthalmology Society annual meeting, Snowbird, UT, USA, February 2003.

doi: 10.1136/bjo.2005.071696

Accepted for publication 1 May 2005

Supported by the Heed Foundation, Cleveland, OH, USA (MSL).

Competing interests: none declared

## References

- Green WR, Wilson DJ. Choroidal neovascularization. *Ophthalmology* 1986;**93**:1169-76.
- Lopez FP, Green WR. Peripapillary subretinal neovascularization: a review. *Retina* 1992;**12**:147-71.
- Spaide RF, Borodoker N, Shah V. Atypical choroidal neovascularization in radiation retinopathy. *Am J Ophthalmol* 2002;**133**:709-11.
- Schatz H, Green WR, Talamo JH, et al. Clinicopathologic correlation of retinal to choroidal venous collaterals of the optic nerve head. *Ophthalmology* 1991;**98**:1287-93.
- Shields JA, Shields CL, De Potter P, et al. Choroidal neovascular membrane as a feature of optic nerve glioma. *Retina* 1997;**17**:349-50.
- Jamison RR. Subretinal neovascularization and papilledema associated with pseudotumor cerebri. *Am J Ophthalmol* 1978;**85**:78-81.
- Dutton JJ. Optic nerve sheath meningiomas. *Surv Ophthalmol* 1992;**37**:167-83.
- Rodrigues MM, Savino PJ, Schatz NJ. Sphenoorbital meningioma with opticociliary veins. *Am J Ophthalmol* 1976;**81**:666-70.
- Coston TO. Primary tumor of the optic nerve: with report of a case. *Arch Ophthalmol* 1936;**15**:696-702.
- Dunn SN, Walsh FB. Meningioma (dural endothelioma) of the optic nerve. *Arch Ophthalmol* 1956;**56**:702-7.

## MAILBOX

### Intraoperative visual experiences of cataract patients can be both pleasant and unpleasant

We read with interest Zia *et al's* article, which highlights a professional artist's and a poet's respective renditions of their visual experiences during phacoemulsification and intraocular lens implantation under local anaesthesia.<sup>1</sup> While it is unclear from the report whether the artist's elaborate drawing resembling a "colourful monkey" was associated with a pleasant or frightening visual experience, it appears from the poem that the poet's visual experience was most probably pleasant and delightful.

We have previously reported that the visual experience during cataract surgery under local anaesthesia can be frightening in up to 16.2% of patients.<sup>2-8</sup> The anxiety that may result from the intraoperative visual experience is clinically significant because it may cause patients to become uncooperative during the procedure and trigger a sympathetic stress response. This may result in hypertension, tachycardia, ischaemic strain on the heart, hyperventilation, and acute panic attacks. These stress responses are particularly undesirable in cataract patients who are often elderly, with systemic co-morbidities such as hypertension and ischaemic heart disease.<sup>2-9</sup> The frightening experience may

also lower patients' satisfaction with the surgery.<sup>10-11</sup>

The poet's experience reported by Zia *et al* reminds us that the intraoperative visual experience during cataract surgery can be pleasant for some patients.<sup>1</sup> In fact, our experience has shown that the majority of patients find their visual experiences pleasant and, in some cases, the visual experience actually increases their satisfaction with the surgery. In a recently reported randomised controlled trial conducted in India involving 304 patients who underwent phacoemulsification under either topical anaesthesia (TA) or retrobulbar anaesthesia (RA), the visual experience was reported by 106 out of 154 (68.8%) TA and 102 out of 150 (68%) RA patients to be pleasant and by 47 (30.5%) TA and 46 (30.7%) RA patients to be unpleasant.<sup>12</sup> In a separate unpublished study conducted in Singapore, eight of 98 patients (8.2%) who had phacoemulsification under TA reported that their satisfaction with the surgery increased because of their visual experiences, whereas only two patients (2.0%) experienced a decrease in satisfaction. The remaining 88 patients (89.8%) reported that their visual experience did not affect their satisfaction with the surgery. Some of the patients who found their visual experiences pleasant commented on the "fantastic colours" that they experienced. In another similar study on patients who had cataract surgery under RA, nine of 152 patients (5.9%) experienced an increase in satisfaction, whereas five patients (3.3%) thought that their satisfaction had decreased as a result of the visual experiences and the remaining 138 patients (90.8%) experienced no change in their satisfaction.

An additional observation is from videotaped interviews conducted by one of us (CMK) with several leading ophthalmic anaesthesia providers in the United States who had cataract surgery under local anaesthesia themselves. The video recordings were made during the annual scientific meeting of the Ophthalmic Anaesthesia Society held in Chicago in October 2004. The videos clearly showed they reported seeing pleasant and beautiful images during their surgery.

In summary, patients may experience pleasant or unpleasant visual sensations during cataract surgery under local anaesthesia. Further investigation is warranted to help ascertain how we can reduce the possibility of the experience being unpleasant or frightening.

#### K-G Au Eong

The Eye Institute at Alexandra Hospital, National Healthcare Group, Singapore, The Eye Institute at Tan Tock Seng Hospital, National Healthcare Group, Singapore, Department of Ophthalmology, National University of Singapore, Singapore, Singapore Eye Research Institute, Singapore

#### C S H Tan, C L Ang, S S G Lee

The Eye Institute at Tan Tock Seng Hospital, National Healthcare Group, Singapore

#### R Venkatesh

Aravind Eye Hospitals, Pondicherry, India

#### R Muralikrishnan

Lions Aravind Institute of Community Ophthalmology, Modurai, India

#### G L Fanning

Hauser-Ross Eye Institute, Sycamore, IL, USA

#### C M Kumar

Academic Department of Anaesthesia, The James Cook University Hospital, UK

Correspondence to: Dr Kah-Guan Au Eong, Alexandra Hospital 378 Alexandra Road Singapore, Singapore 159964; kah\_guan\_au\_eong@alexhosp.com.sg

doi: 10.1136/bjo.2005.074823

Accepted for publication 13 May 2005

## References

- Zia R, Schlichtenbrede FC, Greaves B, et al. "Only rarely seen in dreams"—visual experiences during cataract surgery. *Br J Ophthalmol* 2005;**89**:247-8.
- Au Eong KG. 6th Yahya Cohen lecture: visual experience during cataract surgery. *Ann Acad Med Singapore* 2002;**31**:666-74.
- Prasad N, Kumar CM, Patil BB, et al. Subjective visual experience during phacoemulsification cataract surgery under sub-Tenon's block. *Eye* 2003;**17**:407-9.
- Au Eong KG. The Royal College of Ophthalmologists cataract surgery guidelines: what can patients see with their operated eye during cataract surgery? *Eye* 2002;**16**:109-10.
- Au Eong KG, Lim TH, Lee HM, et al. Subjective visual experience during phacoemulsification and intraocular lens implantation using retrobulbar anaesthesia. *J Cataract Refract Surg* 2000;**26**:842-6.
- Au Eong KG, Low CH, Heng WJ, et al. Subjective visual experience during phacoemulsification and intraocular lens implantation under topical anaesthesia. *Ophthalmology* 2000;**107**:248-50.
- Au Eong KG, Lee HM, Lim ATH, et al. Subjective visual experience during extracapsular cataract extraction and intraocular lens implantation under retrobulbar anaesthesia. *Eye* 1999;**13**:325-8.
- Tranos PG, Wickremasinghe SS, Sinclair N, et al. Visual perception during phacoemulsification surgery under topical and regional anaesthesia. *Acta Ophthalmol Scand* 2003;**81**:118-22.
- Tan CSH, Rengaraj V, Au Eong KG. Visual experiences of cataract surgery. *J Cataract Refract Surg* 2003;**29**:1453-4.
- Leo SW, Au Eong KG. Comments on anaesthesia for cataract surgery. *J Cataract Refract Surg* 2003;**29**:633-5.
- Leo SW, Au Eong KG, Rengaraj V, et al. The Misericordia Health Centre cataract comfort study. *Can J Ophthalmol* 2003;**38**:23-4.
- Rengaraj V, Radhakrishnan M, Au Eong KG, et al. Visual experience during phacoemulsification under topical versus retrobulbar anaesthesia: results of a prospective, randomised, controlled, trial. *Am J Ophthalmol* 2004;**138**:641-8.

### Cigarette pack warning: it can send you blind!

The growing research implicating smoking in age related macular degeneration (AMD) prompted us to write an editorial in 1999<sup>1</sup> urging the Australian government to warn smokers of this little appreciated risk.

In 2000, the Australian National Quit campaign ran an advertisement as part of a series titled "Every cigarette is doing you damage," which explicitly addressed AMD. A website describes the campaign here in Australia ([www.quitnow.info.au/script/eye.html](http://www.quitnow.info.au/script/eye.html)) and the television ad may be downloaded ([www.quitnow.info.au/smokescreen/smokescreen.html](http://www.quitnow.info.au/smokescreen/smokescreen.html)).

In 2006 the Australian government will require new mandatory pictorial pack warnings, one of which will be about AMD. This warning was one of the strongest tested among smokers in the research conducted for the government before the announcement. The full report and other related information can be found at [tobacco.health](http://tobacco.health).

usyd.edu.au/site/supersite/resources/docs/gallery\_packwarnings.htm.

Correspondence to: Professor S Chapman, School of Public Health, University of Sydney, Sydney 2006, Australia; [simonchapman@health.usyd.edu.au](mailto:simonchapman@health.usyd.edu.au)

doi: 10.1136/bjo.2005.076562

Accepted for publication 9 June 2005

## Reference

- 1 Mitchell P, Chapman S, Smith W. "Smoking is a major cause of blindness": a new cigarette pack warning? *Med J Aust* 1999;171:173-4.

## BOOK REVIEWS

### Immunology of the lacrimal gland, tear film and ocular surface

Eds Manfred Zierhut, Michael E Stern, David A Sullivan. £75, pp 288. London: Taylor and Francis, 2005, ISBN 184184568X

A short quotation (p 152) summarises the book: "These systems are all part of the multiple and redundant and protective mechanisms...[that] maintain a functioning cornea." Reflecting this complexity, chapters range from the pathogenesis of herpetic keratitis to dry eyes, to mucosal immunity and the use of topical ciclosporin, to tear film and contact lenses and, of course, inflammation. The book includes more unusual chapters on ocular surface: these integrate the eye into the upper aerodigestive tract. Parallels between lacrimal and salivary glands, which are not often conducted, focus attention to the inflammatory and immune processes common to these mucosae and the diagnostic markers they might offer.

Some chapters are dense and scholarly: "Sex, sex steroids and dry eye syndromes" has no fewer than 232 references, and provides a "must read" synthesis of approaches, results and hypotheses of the research undertaken to understand sex related differences in lacrimal and meibomian gland (dys)function. Other chapters have a narrower focus: events leading to *Acanthamoeba* infections and candidates for therapy are presented in an very clearly organised and chapter.

Equally elegantly and authoritatively presented are hypotheses and results showing that constant parasympathetic input is necessary for tear production and thus ocular surface homeostasis.

Though not stated by the editors, this book contains contributions to a meeting with the same title, which provided a wonderful opportunity for discussions. It is rather a pity that these are not part of the book. Putting up with different styles is a small price to pay for this highly informed and expertly abstracted state of knowledge publication.

M Berry

Bristol Eye Hospital, Lower Maudlin Street, Bristol, UK; [mon.berry@bristol.ac.uk](mailto:mon.berry@bristol.ac.uk)

### Glaucoma. 3rd ed.

Eds J Salmon, J Kanski. £46, pp 169. Oxford: Butterworth-Heinemann, 2004, ISBN 0750655283.

This excellent text has been in print since 1989 and its longevity is testament to its high quality. This is the third edition, with a new co-author John Salmon. Since its previous edition over 8 years ago there have been many advances in both the genetics, and the diagnosis, monitoring and treatment of glaucoma. This text successfully updates the previous edition, and provides a concise, systematic, detailed and well balanced representation of modern glaucoma diagnosis and management.

This book is aimed at the trainee ophthalmologist and optometrist, although it is also good basic revision for the practising ophthalmologist. This is a comprehensive text in that each type of glaucoma is described in terms of its main clinical features and management. There are many colour illustrations and photographs, these help the reader to correctly interpret clinical signs and diagnostic tests. It also covers current controversies and new techniques such as non-penetrating glaucoma surgery. The landmark glaucoma studies and their significance are also mentioned. It is perhaps too brief in sections, particularly in the chapters looking at glaucoma diagnosis, perimetry, and imaging; however, adequate and key references are provided to allow further pursuit of these topics in more depth.

The text begins by covering the basic sciences including the physiology of aqueous secretion. Then there is a comprehensive definition and classification of glaucoma. The different types of glaucoma are described at length. Tonometry is covered well, including the range of tonometers, potential errors in tonometry, and calibration. Gonioscopy is discussed including angle structure identification and the different systems of angle classification.

Retinal nerve fibre and optic nerve head assessment is described briefly including the new imaging techniques of scanning laser tomography (Heidelberg retinal tomogram II), ocular coherence tomography (OCT), and scanning laser polarimetry (GDx nerve fibre analyser). The images or readouts produced by each machine are provided in colour along with a very brief description of their interpretation. The various modalities of perimetry are described, their interpretation is given, and new techniques such as the frequency doubling contrast test (FDT) and shortwave automated perimetry (SWAP) are discussed and examples provided.

Glaucoma medications are covered very well. Long standing medication are discussed as well as new treatment options, including combined topical preparations. Neuroprotective agents are covered with the recent research regarding these agents. There is a chapter on laser therapy which covers argon, diode, and selective laser trabeculoplasty, Nd-YAG laser iridotomy, and diode laser cycloablation.

Trabeculectomy surgery with early and late complications are discussed comprehensively. There is an excellent and concise chapter on non-penetrating filtration surgery, covering the two most popular techniques—deep sclerectomy and viscocanalostomy.

The next chapter deals with antimetabolites in filtration surgery; established antimetabolites are covered (5-fluorouracil and mitomycin C), new agents such as antibodies to TGF- $\beta$  are also mentioned. The final chapter is on drainage implants, the Molteno, Baerveldt, and Ahmed implants are discussed. Finally the actual surgical techniques and the complications are well described.

Overall, this is an excellent book, it is concise, with only 163 pages of illustrated text, easy to read, and extremely pertinent to clinical practice. A text I thoroughly recommend for any trainee ophthalmologist or optometrist and anyone wanting a brief, contemporary revision text on the diagnosis and management of glaucoma. Although, fortunately or unfortunately, in the end it may only whet your appetite for information and leave you wanting more.

N Spencer

Bristo Eye Hospital, Lower Maudlin Street, Bristol B S1 2LX UK; [bluegreeniris@hotmail.com](mailto:bluegreeniris@hotmail.com)

## NOTICES

### World Ophthalmology Congress 2006 – Brazil

The World Ophthalmology Congress (which is replacing the International Congress of Ophthalmology) is meeting in February 2006 in Brazil.

For further information on the congress and committees, scientific program and coordinators of different areas are available at the congress website [www.opthalmology2006.com.br](http://www.opthalmology2006.com.br)

### Thoughts on Ophthalmology and Development

The Mathis Eye Foundation is a small, privately financed organisation, established 17 years ago by a former international banker who began his medical studies at age 40, with the specific intention of working in third world surgical ophthalmology. The Foundation's experiences and lessons learned are presented in a 26 page bound summary entitled *Thoughts on Poor World Ophthalmology Development*, an often critical look at eye surgery programs in Latin America, Africa, and Haiti. To obtain this report without cost, please contact [jheatherly@taylormathis.com](mailto:jheatherly@taylormathis.com).

### Vision 2020

The latest issue of *Community Eye Health* (No 54) assesses the progress of Vision 2020 at the district level. For further information please contact: Journal of Community Eye Health, International Resource Centre, International Centre for Eye Health, Department of Infectious and Tropical Diseases, London School of Hygiene and Tropical Medicine, Keppel Street, London WC1E 7HT, UK (tel: +44 (0)20 7612 7964; email: [Anita.Shah@lshtm.ac.uk](mailto:Anita.Shah@lshtm.ac.uk); online edition: [www.jceh.co.uk](http://www.jceh.co.uk)). Annual subscription (4 issues) UK £28/US\$45. Free to developing country applicants.



## Xanthogranulomatous disease in the lacrimal gland

J A Sivak-Callcott, W K Lim, L L Seah, et al.

*Br J Ophthalmol* 2005 89: 1375-1377

doi: 10.1136/bjo.2004.063578

---

Updated information and services can be found at:

<http://bjo.bmj.com/content/89/10/1375.full.html>

---

*These include:*

### References

This article cites 10 articles, 1 of which can be accessed free at:

<http://bjo.bmj.com/content/89/10/1375.full.html#ref-list-1>

### Email alerting service

Receive free email alerts when new articles cite this article. Sign up in the box at the top right corner of the online article.

---

### Notes

---

To request permissions go to:

<http://group.bmj.com/group/rights-licensing/permissions>

To order reprints go to:

<http://journals.bmj.com/cgi/reprintform>

To subscribe to BMJ go to:

<http://group.bmj.com/subscribe/>