

EXTENDED REPORT

Nd:YAG capsulotomy rates after use of the AcrySof acrylic three piece and one piece intraocular lenses

S I Mian, K Fahim, A Marcovitch, H Gada, D C Musch, A Sugar

Br J Ophthalmol 2005;89:1453–1457. doi: 10.1136/bjo.2005.067405

See end of article for authors' affiliations

Correspondence to: Shahzad Mian, MD, Department of Ophthalmology and Visual Sciences, WK Kellogg Eye Center, University of Michigan, 1000 Wall Street, Ann Arbor, MI 48105, USA; smian@umich.edu

Accepted for publication 1 June 2005

Background/aim: Acrylic lens size and shape may influence the rate of posterior capsule opacification (PCO) and need for Nd:YAG capsulotomy. The aim of this study is to compare the Nd:YAG capsulotomy rate of the three piece acrylic/PMMA AcrySof MA series lens with the one piece acrylic AcrySof SA series lens.

Methods: 434 eyes of 329 patients who had cataract extraction and implantation of one of four types of intraocular lenses (IOLs) were evaluated for rate of Nd:YAG capsulotomy. 176 eyes received the acrylic AcrySof MA30AC IOL, 71 eyes the acrylic AcrySof MA60AC IOL, 45 eyes the acrylic AcrySof SA30AL IOL, and 142 eyes the acrylic AcrySof SA60AT IOL.

Results: The rates of Nd:YAG capsulotomy with the three piece IOL (MA30AC/MA60AC) and the one piece IOL (SA30AL/SA60AT) were 1.2% and 2.1% at 6 months, 2.8% and 5.9% at 12 months, and 3.6% and 7.5% at 24 months, respectively. The incidence of Nd:YAG capsulotomy was higher in patients who received the one piece IOL ($p=0.01$, log rank test). There was no difference in Nd:YAG capsulotomy rates when comparing lens optic size, age, sex, history of pars plana vitrectomy, and diabetes mellitus.

Conclusions: This study shows a greater incidence of Nd:YAG capsulotomy in patients who receive one piece acrylic AcrySof lenses when compared to those who receive three piece acrylic AcrySof lenses.

Posterior capsule opacification (PCO) is the most common complication after cataract extraction with intraocular lens (IOL) implantation. Nd:YAG laser capsulotomy is a definitive treatment of PCO; however, there are rare but significant complications of capsulotomy, including cystoid macular oedema, retinal detachment, and increased intraocular pressure.^{1–2} In addition, Nd:YAG capsulotomy to treat PCO results in increased requirements for patient follow up and has a substantial socioeconomic impact.^{3–4}

Acrylic lenses have been shown to be very successful in numerous studies. Since the introduction of the acrylic three piece MA series IOL (AcrySof, Alcon) in 1995 and the one piece SA series IOL (AcrySof, Alcon) in 2000, studies have shown that both have a low incidence of PCO and Nd:YAG capsulotomy rate.^{5–13} Acrylic lenses are very stable; they have a low incidence of complications, including minimal tilt, decentration, and anterior capsule contraction.^{3–4} There may be additional benefits with alterations in lens size and design, including reduction of PCO formation with three piece acrylic IOLs.^{15–18} Other studies have shown that acrylic lenses are the IOL of choice for patients with certain risk factors, such as younger age and diabetes.^{19–20}

Since acrylic lens size and shape may influence the rate of PCO formation and need for Nd:YAG capsulotomy, the aim of this study was to compare the Nd:YAG capsulotomy rates of the three piece acrylic AcrySof IOL (MA30AC/MA60AC) with the one piece acrylic AcrySof IOL (SA30AL/SA60AT).

METHODS

After obtaining institutional review board approval, a retrospective review was performed of eyes that had phacoemulsification with posterior chamber acrylic AcrySof IOL implantation between January 2000 and September 2002. This time interval was chosen because it was a period of transition, when all four IOL types were being utilised. For each surgery, the patient's chart was reviewed for the following data: age at surgery, sex of patient, right or left eye, past ocular history, preoperative and postoperative best

corrected vision, date of cataract extraction, IOL type, date of Nd:YAG capsulotomy (if performed), pre-Nd:YAG and post-Nd:YAG capsulotomy best corrected vision, and date of last examination.

All surgeries were performed by one surgeon. After retrobulbar anaesthesia, a clear corneal temporal incision was made with a 2.75 mm keratome blade. Viscoelastic was used to inflate the anterior chamber and continuous curvilinear capsulorhexis of about 4–5 mm was performed. Hydrodissection and “divide and conquer” phacoemulsification were performed and the cortex was removed with automated irrigation/aspiration. The posterior capsule was vacuumed but no other capsular polishing was performed. Viscoelastic was then inserted into the capsular bag, followed by “in the bag” placement of the posterior chamber IOL. Patients with any of the following conditions were excluded: capsule tear, vitreous loss, incomplete cortical cleanup, IOL not fixated in capsular bag, PCO noted at time of surgery, congenital cataract, history of trauma, history of preoperative uveitis, or postoperative follow up less than 5 months.

Nd:YAG capsulotomy was performed based on subjective patient complaints or measurable decrease in visual acuity compared to best postoperative visual acuity, coupled with the presence of PCO detected on dilated slit lamp examination.

In all, 434 eyes of 329 patients were included and divided into four groups according to the type of IOL implanted: group 1 (176 eyes of 148 patients), three piece acrylic with PMMA haptics and 5.5 mm optic diameter (MA30AC); group 2 (71 eyes of 61 patients), three piece acrylic with PMMA haptics and 6.0 mm optic diameter (MA60AC); group 3 (45 eyes of 40 patients), one piece acrylic and 5.5 mm optic diameter (SA30AL); group 4 (142 eyes of 117 patients), one piece acrylic and 6.0 mm optic diameter (SA60AT). In general, the use of the four IOL types was sequential with

Abbreviations: IOL, intraocular lens; PCO, posterior capsule opacification

the smaller optics implanted before the larger optics and the three piece before the one piece lenses during the study period.

The number of each type of IOL implanted, the number of eyes needing Nd:YAG capsulotomy, and the time from surgery to follow up were determined. Table 1 shows the number of eyes in each group and patient demographic data. Kaplan-Meier survival distribution plots were generated to display the time to Nd:YAG capsulotomy events with adjustment for censoring. Cox proportional hazards regression models that accounted for inter-eye dependency were used to compare incidence rates. SAS 9.0 software was used for the analyses.

RESULTS

Twenty two of 247 (8.9%) eyes that received the three piece IOL (MA30AC/MA60AC) required Nd:YAG capsulotomy, as did 14 of 187 (7.5%) that received the one piece IOL (SA30AL/SA60AT). Table 2 shows the mean follow up time by IOL type. Mean follow up time for those who received a three piece lens was 33.5 months (5.3–91.1) while the mean follow up time until Nd:YAG capsulotomy was 29 months (3.2–76.6). Mean follow up time was 14 months (5.1–37.5) for those who received a one piece IOL while the mean follow up time until Nd:YAG capsulotomy was 9.2 months (1.9–19.3).

The rates of Nd:YAG capsulotomy with the three piece IOL and the one piece IOL were 1.2% and 2.1% at 6 months, 2.8% and 5.9% at 12 months, and 3.6% and 7.5% at 24 months, respectively. Kaplan-Meier survival curve analysis revealed a significant difference between the one piece and three piece IOLs in the incidence of Nd:YAG capsulotomy, upon accounting for censoring ($p = 0.01$). Figure 1 shows a higher incidence of Nd:YAG capsulotomy in the one piece IOL when compared to the three piece IOL groups up to 24 months after cataract surgery.

Fourteen of 221 eyes that received a 5.5 mm IOL (SA30AL/MA30AC) required Nd:YAG capsulotomy, as did 22 of 213 that received a 6.0 mm IOL (SA60AT/MA60AC). There was no difference between rate of Nd:YAG capsulotomy when comparing SA30AL with SA60AT IOLs ($p = 0.13$) and MA30BA with MA60AC IOLs ($p = 0.21$) upon analysis of the survival curves. There was a trend towards an increased rate of Nd:YAG capsulotomy ($p = 0.06$) in eyes of younger patients. Sex ($p = 0.86$), history of diabetes mellitus ($p = 0.90$), and pars plana vitrectomy ($p = 0.14$) were not associated with differences in Nd:YAG capsulotomy rates.

DISCUSSION

Several factors have been shown to influence PCO formation and, concomitantly, the need for Nd:YAG capsulotomy. Variations in surgical technique that can influence PCO formation include cortical clean up, continuous curvilinear

capsulorhexis, posterior capsule polishing, and lens placement in the capsular bag. Patient variables, such as younger age, female sex, diabetes, and uveitis, may increase the incidence of PCO formation. Finally, the IOL shape, biomaterial, and size may contribute to PCO formation.

Peng *et al* found that the most important technique to reduce the incidence of PCO is meticulous cortical clean up.²¹ In our series, all surgeries were performed by one surgeon using the same technique, including thorough cortex removal. In addition, only patients with lens placement in the capsular bag without posterior capsular abnormalities at the time of surgery were included.

The incidence of PCO is also significantly influenced by the type of IOL utilised. Current interest is focused on the effect of biomaterial composition and design of IOLs on incidence of PCO. Studies comparing biomaterial of IOLs have shown that acrylic IOLs have a low incidence of PCO and Nd:YAG capsulotomy (table 3).^{6–13 22–31} Apple *et al* reviewed 5416 eyes and found a 0.9% Nd:YAG capsulotomy rate with AcrySof three piece acrylic lenses while the rate ranged between 12.1% and 33.4% for all other reported lenses: one and three piece designs with polymethyl methacrylate (PMMA) optics, one piece silicone plate IOLs, three piece lenses with silicone optic polyimide haptics, silicone optic proline haptics, and silicone optic PMMA haptics.²² Beltrame *et al* reported a Nd:YAG capsulotomy rate of 2.5% with the AcrySof MA60BM IOL and 43.15% with a hydrogel (H60M) IOL.⁸ Similarly, Missier *et al* noted that only 2.8% of patients who received an AcrySof (MA30/MA60) lens, compared to 23.1% who received a silicone (AA4203VF) lens required Nd:YAG capsulotomy in the first 3 years postoperatively.²³ One proposed explanation for the reduced occurrence of PCO with use of the acrylic lens is the adhesive nature of the biomaterial. Linnola *et al* found that acrylic binds best with fibronectin relative to other biomaterials.³² By binding tightly to the capsular bag, acrylic IOLs help decrease posterior lens epithelial cell proliferation. The high capsular biocompatibility of the AcrySof lens is attributed to its hydrophobic nature; this explains the low PCO rate of this IOL when compared to hydrophilic acrylic IOLs.^{33–35}

Multiple studies comparing PCO incidence when using one piece versus three piece acrylic IOLs have produced conflicting results. Bender and Nejima have reported no significant difference in PCO rates between the one piece and three piece acrylic lenses up to 18 months after surgery.^{22 36} Although Wallin *et al* reported no significant difference in laser capsulotomy rates, there was a twofold increase in PCO formation in the one piece acrylic IOL when compared to the three piece acrylic IOL 2 years after surgery.¹⁷ A randomised, self controlled study of 104 eyes comparing the one piece and three piece acrylic IOLs found a significant decrease in PCO formation in the three piece IOL at 1 year but not at 2 years

Table 1 Patient demographic data

	MA group	SA group
Total patients	209	157
Mean age (months) (range)	66 (17–98)	69 (26–92)
Females	58.9% (123)	61.8% (97)
Males	41.1% (86)	38.2% (60)
Diabetes	9.3% (23)	12.8% (24)
Previous pars plana vitrectomy	6.9% (17)	8.0% (15)
Total eyes	247	187
MA30BA IOL	176	–
MA60BM IOL	71	–
SA30AL IOL	–	45
SA60AT IOL	–	142
Right eye/left eye	119/128	118/69

Table 2 Nd:YAG capsulotomy results and follow up time

	Total MA	MA30AC	MA60AC	Total SA	SA30AL	SA60AT
Eyes	247	176	71	187	45	142
Nd:YAG (%)	22 (8.9)	12 (6.8)	10 (14)	14 (7.5)	2 (4.4)	12 (8.5)
Mean follow up time (months) (range)	33.5 (5.3–91.1)	32.8	35.4	14 (5.1–37.5)	19.4	12.3
Mean time to YAG (months) (range)	29.0 (3.2–76.6)	29.7	28.2	9.2 (1.9–19.3)	17.1	7.86

after lens implantation.³⁷ In our series, patients who received one piece IOLs required Nd:YAG capsulotomy at a significantly higher rate than those who received three piece IOLs, as shown by Kaplan-Meier survival analysis. Studies have documented that Nd:YAG capsulotomy is often performed 2 years after cataract extraction.^{38 39} In our study, the observed differences reflect events that occurred in the first 2 years of follow up after cataract extraction. However, if patients with the one piece acrylic IOL have Nd:YAG capsulotomy performed earlier and further follow up reveals few additional events, the overall event rate in the two IOL groups may be comparable with longer follow up (fig 1).

The shape of the lens is also an important factor in lens epithelial cell proliferation. Much of the success of these IOLs has been attributed to the square edge design. Nishi *et al* have shown that capsular bend formation begins with IOL adhesion with the lens capsule followed by peripheral anterior and posterior capsular adhesion.⁴⁰ As the capsular adhesion progresses centrally, capsular bend formation occurs as a result of wrapping of the posterior capsule around the posterior optic edge.¹⁶ The square edge design of the IOL creates a sharp bend in the posterior capsule, which may physically inhibit cell migration. In fact, acrylic lenses with a round edge design lose their effectiveness in preventing PCO; a sharper lens posterior edge design, regardless of lens material composition, is essential in prevention of PCO formation.^{41–43} A mathematical explanation also suggests that the sharp edge applies high mechanical pressure on the posterior capsule, which forms a physical barrier to cell migration.⁴⁴ The thin haptics of the three piece MA lens allow for better adhesion between the anterior and posterior capsules and bend formation because they are closer together. The one piece SA lens has bulky haptics with loss of truncated edge at the haptic junction, which leads to decreased adhesion between the capsules and posterior lens epithelial cell migration. Nishi's model predicts that the three piece IOLs will have a lower incidence of PCO than one piece IOLs, which is consistent with previous reports and our study.^{16 17}

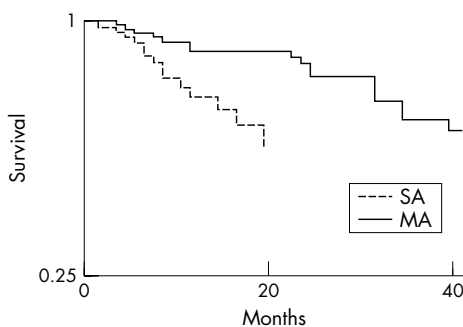


Figure 1 Kaplan-Meier survival curve shows significantly higher incidence of Nd:YAG capsulotomy with the one piece acrylic AcrySof lens (SA30AL/SA60AT) when compared to the three piece acrylic AcrySof lens (MA30AC/MA60AC) (p=0.01).

IOL size may be a significant factor in determining rate of Nd:YAG capsulotomy. Davison reported no significant difference between the rate of Nd:YAG capsulotomy in 5.5 mm and 6.0 mm IOLs.¹³ A conflicting study found that PCO incidence is lower in larger acrylic IOLs.¹⁵ Though not statistically significant, our results also indicate a trend towards a lower incidence of Nd:YAG capsulotomy with the 6.0 mm IOL. There are two proposed explanations for this trend. The first is that the larger optic edge produces a more peripheral barrier to lens epithelial cell migration than the smaller optic. The second is that the larger optic applies greater peripheral pressure against the capsule than the smaller optic, which produces an effective barrier against lens epithelial cell migration.⁴⁴ However, Nishi and Nishi have shown that a 7.0 mm optic may increase the rate of PCO formation as a result of decreased capsular adhesion and bend formation, suggesting the importance of an optimal optic size.¹⁶

Acrylic IOLs have been reported to be preferred, especially in high risk patients.^{19 20} Nd:YAG capsulotomy is more common in younger patients after cataract surgery, and AcrySof acrylic lenses may be the preferred IOL in young patients.^{19 45} Our results indicate a trend towards a greater rate of Nd:YAG capsulotomy in the eyes of younger patients. Some studies have found that women require Nd:YAG capsulotomy following cataract surgery more often than men.^{41 46} However, our study did not identify sex as a risk factor.

A high rate of Nd:YAG capsulotomy with phacoemulsification after pars plana vitrectomy has previously been reported.^{47 48} This has been attributed to use of expandable gas or silicone oil, and intraoperative posterior capsular injury. Our rate of Nd:YAG capsulotomy was not associated with history of pars plana vitrectomy. This may be the result of exclusion of patients who were noted to have intraoperative PCO. Our series may have also had a greater number of patients who had pars plana vitrectomy without use of expandable gas or silicone oil. Nd:YAG capsulotomy has also been found to be more common in diabetic patients as compared to non-diabetics.⁴⁹ Our results did not find diabetes as a significant risk factor for higher rate of Nd:YAG capsulotomy. A difference may have been found if there were a larger number of diabetics in the study.

The limitations of this study include its retrospective design and the use of Nd:YAG capsulotomy as an indirect measure of PCO. This study shares the limitations of any retrospective study in that the patients were not randomised and the end points were not defined in advance. However, the patient demographics are similar among the groups. Criteria for a surgical procedure such as Nd:YAG capsulotomy are subjective and largely based on patient complaints. A patient with PCO may not be symptomatic if poor macular function coexists. This may prevent patients with PCO from being included in the Nd:YAG capsulotomy group. In addition, need for Nd:YAG capsulotomy requires longer patient follow up, and patients without symptoms may be less likely to follow up; therefore, potentially increasing the overall rate of Nd:YAG capsulotomy. Although the dependence on Nd:YAG capsulotomy as a measure of PCO may be

Table 3 Incidence of Nd:YAG in acrylic AcrySof three piece and one piece IOLs

IOL type	Eyes	Nd:YAG (%)	Mean follow up time (months) (range)	Study
MA30	335	9 (2.69)	23.3 (18.7–30.3)	Stordahl ¹²
MA30	176	12 (6.8)	32.8 (5.3–75.2)	Mian
MA30	156	17 (10.9)	35.15	Ernest ²⁵
MA30	94	1 (1.06)	12	Bender ²⁴
MA30	85	4 (4.71)	13.6	Scaramuzza ¹¹
MA30	46	0 (0)	19.35	Halpern ⁹
MA60	485	12 (2.47)	24	Beltrame ⁸
MA60	127	1 (0.79)	12 (11–14)	Mester ⁷
MA60	100	2 (2)	24	Hayashi ⁶
MA60	71	10 (14)	35.4 (5.3–91.1)	Mian
MA60	62	3 (4.84)	19.35	Halpern ⁹
MA60	38	1 (2.63)	18	Prosdocimo ²⁷
MA60	38	3 (7.89)	24	Wejde ¹⁰
MA60	21	0 (0)	36	Küçükümer ²⁹
MA30/MA60	216	2 (0.9)	Postmortem study	Apple ²⁰
MA30/MA60	107	3 (2.8)	37.08	Missier ²¹
MA30/MA60	61	1 (1.64)	48	Ram ²⁸
MA30/MA60	19	0 (0)	36	Hollick ³⁰
SA30	2044	13 (0.64)	9 (2–23)	Davison ¹³
SA30	45	2 (4.4)	19.4 (6.1–37.5)	Mian
SA30	38	0 (0)	12	Bender ²⁴
SA60	586	2 (0.34)	5.5 (5–6)	Davison ¹³
SA60	142	12 (8.5)	12.3 (5.1–26.0)	Mian

an inaccurate estimate of degree of opacification, it provides a functional measure of significance and imposes equal limitations on all groups.

In summary, our results suggest that the three piece acrylic IOLs may be preferred in order to decrease the rate of Nd:YAG capsulotomy after IOL implantation. one piece IOLs were developed more recently and are not as well studied as the three piece IOLs. Further study of the one piece IOLs, with longer follow up, may help identify the lens of choice. This study shows a higher incidence of Nd:YAG capsulotomy in patients who receive the one piece acrylic AcrySof lens compared to patients who receive the three piece acrylic AcrySof lens.

ACKNOWLEDGEMENTS

Supported in part by a departmental grant from Research to Prevent Blindness, Inc, New York, USA.

Authors' affiliations

S I Mian, K Fahim, A Marcovitch, H Gada, D C Musch, A Sugar, Department of Ophthalmology and Visual Sciences, WK Kellogg Eye Center, University of Michigan Medical School, Ann Arbor, MI, USA
D C Musch, Department of Epidemiology, School of Public Health, University of Michigan, Ann Arbor, MI, USA

None of the authors have proprietary or financial interest in this article.

REFERENCES

- Ficker LA, McG Steele AD. Complications of Nd:YAG laser posterior capsulotomy. *Trans Ophthalmol Soc UK* 1985;**104**:529–32.
- Steinert RF, Puliafito CA, Kumar SR, et al. Cystoid macular edema, retinal detachment and glaucoma after Nd:YAG laser posterior capsulotomy. *Am J Ophthalmol* 1991;**112**:373–8.
- Apple DJ, Solomon KD, Tetz, et al. Posterior capsule opacification. *Surv Ophthalmol* 1992;**37**:73–116.
- Steinberg EP, Javitt JC, Sharkey PD, et al. The content and cost of cataract surgery. *Arch Ophthalmol* 1993;**111**:1041–9.
- Nejima R, Miyata K, Honbou M, et al. A prospective, randomized comparison of single and three piece acrylic foldable intraocular lenses. *Br J Ophthalmol* 2004;**88**:746–9.
- Hayashi K, Hayashi H. Posterior capsule opacification after implantation of a hydrogel intraocular lens. *Br J Ophthalmol* 2004;**88**:182–5.
- Mester U, Fabian E, Gerl R, et al. Posterior capsule opacification after implantation of CeeOn Edge 911A, PhacoFlex SI-40NB, and AcrySof MA60BM lenses. *J Cataract Refract Surg* 2004;**30**:978–85.
- Beltrame G, Salvat ML, Chizzolini M, et al. Posterior capsule opacification and Nd:YAG capsulotomy rates after implantation of silicone, hydrogel and soft acrylic intraocular lenses: a two-year follow-up study. *Eur J Ophthalmol* 2002;**12**:388–94.
- Halpern MT, Covert D, Battista C, et al. Relationship of AcrySof acrylic and PhacoFlex silicone intraocular lenses to visual acuity and posterior capsule opacification. *J Cataract Refract Surg* 2002;**28**:662–9.
- Wejde G, Kugelberg M, Zetterström C. Posterior capsule opacification: comparison of 2 intraocular lenses of different materials and design. *J Cataract Refract Surg* 2003;**29**:1556–9.
- Scaramuzza A, Fernando GT, Crayford BB. Posterior capsule opacification and lens epithelial cell layer formation: hydroview hydrogel versus AcrySof acrylic intraocular lenses. *J Cataract Refract Surg* 2001;**27**:1047–54.
- Stordahl PB, Drolsum L. A comparison of Nd:YAG capsulotomy rate in two different intraocular lenses: AcrySof and Stabibag. *Acta Ophthalmol Scand* 2003;**81**:326–30.
- Davison JA. Clinical performance of Alcon SA30AL and SA60AT single-piece acrylic intraocular lenses. *J Cataract Refract Surg* 2002;**28**:1112–23.
- Mengual E, Garcia J, Elvira JC, et al. Clinical results of AcrySof intraocular lens implantation. *J Cataract Refract Surg* 1998;**24**:114–17.
- Meacock WR, Spalton DJ, Boyce JF, et al. Effect of optic size on posterior capsule opacification: 5.5 mm versus 6.0 mm AcrySof intraocular lenses. *J Cataract Refract Surg* 2001;**27**:1194–8.
- Nishi O, Nishi K. Effect of the optic size of a single-piece acrylic intraocular lens on posterior capsule opacification. *J Cataract Refract Surg* 2003;**29**:348–53.
- Wallin T, Hinckley M, Nilson C, et al. A clinical comparison of single-piece and three-piece truncated hydrophobic acrylic intraocular lenses. *Am J Ophthalmol* 2003;**136**:614–19.
- Chang D. Single versus three piece acrylic IOLs. *Br J Ophthalmol* 2004;**88**:727–8.
- Küchle M, Lausen B, Gusek-Schneider GC. Results and complications of hydrophobic acrylic vs PMMA posterior chamber lenses in children under 17 years of age. *Graefes Arch Clin Exp Ophthalmol* 2003;**241**:637–41.
- Kim NJ, Lee JH. Effect of an acrylic posterior chamber intraocular lens on posterior capsule opacification in cataract patients with associated risk factors. *J Cataract Refract Surg* 2003;**29**:1575–8.
- Peng Q, Apple DJ, Visessook N, et al. Surgical prevention of posterior capsule opacification. Part 2: Enhancement of cortical cleanup by focusing on hydrodissection. *J Cataract Refract Surg* 2000;**26**:188–97.
- Apple DJ, Peng Q, Visessook N, et al. Eradication of posterior capsule opacification. Documentation of a marked decrease in Nd:YAG laser posterior capsulotomy rates noted in an analysis of 5416 pseudophakic human eyes obtained postmortem. *Ophthalmology* 2001;**108**:505–18.
- Missier KAA, Nuijts RMMA, Tjia KF. Posterior capsule opacification: silicone plate-haptic versus acrySof intraocular lenses. *J Cataract Refract Surg* 2003;**29**:1569–74.
- Bender LE, Nimsgern C, Jose R, et al. Effect of a 1-piece and 3-piece AcrySof intraocular lenses on the development of posterior capsule opacification after cataract surgery. *J Cataract Refract Surg* 2004;**30**:786–9.
- Ernest P. Posterior capsule opacification and neodymium: YAG capsulotomy rates with AcrySof acrylic and PhacoFlex II silicone intraocular lenses. *J Cataract Refract Surg* 2003;**29**:1546–50.
- Ursell PG, Spalton DJ, Pande MV, et al. Relationship between intraocular lens biomaterials and posterior capsule opacification. *J Cataract Refract Surg* 1998;**24**:352–60.

- 27 **Prosdocimo G**, Tassinari G, Sala M, *et al*. Posterior capsule opacification after phacoemulsification. Silicone CeeOn edge versus acrylate AcrySof intraocular lens. *J Cataract and Refract Surg* 2003;**29**:1551–5.
- 28 **Ram J**, Kaushik S, Brar G, *et al*. Neodymium:YAG capsulotomy rates following phacoemulsification with implantation of PMMA, silicone, and acrylic intraocular lenses. *Ophthalmic Surg Lasers* 2001;**32**:375–82.
- 29 **Küçüksümer Y**, Bayraktar Ş, Yilmaz Ö. Posterior capsule opacification 3 years after implantation of an AcrySof and a MemoryLens in fellow eyes. *J Cataract Refract Surg* 2000;**26**:1176–82.
- 30 **Hollick EJ**, Spalton DJ, Ursell PG, *et al*. The effect of polymethylmethacrylate, silicone, and polyacrylic intraocular lenses on posterior capsular opacification 3 years after cataract surgery. *Ophthalmology* 1999;**106**:54–5.
- 31 **Sundelin K**, Friberg-Riad Y, Östberg A, *et al*. Posterior capsule opacification with AcrySof and poly(methyl methacrylate) intraocular lenses. Comparative study with a 3-year follow-up. *J Cataract Refract Surg* 2001;**27**:1586–90.
- 32 **Linnola RJ**, Sund M, Ylonen R, *et al*. Adhesion of soluble fibronectin, laminin, and collagen type IV to intraocular lens materials. *J Cataract Refract Surg* 1999;**25**:1486–91.
- 33 **Schauersberger J**, Amon M, Kruger A. Lens epithelial cell outgrowth on 3 types of intraocular lenses. *J Cataract Refract Surg* 2001;**27**:850–4.
- 34 **Abela-Formanek C**, Amon M, Schild G, *et al*. Uveal and capsular biocompatibility of hydrophilic acrylic, hydrophobic acrylic, and silicone intraocular lenses. *J Cataract Refract Surg* 2002;**28**:50–61.
- 35 **Abela-Formanek C**, Amon M, Schauersberger J, *et al*. Results of hydrophilic acrylic, hydrophobic acrylic, and silicone intraocular lenses in uveitic eyes with cataract. Comparison to a control group. *J Cataract Refract Surg* 2002;**28**:1141–52.
- 36 **Nejima R**, Miyata K, Honbou M, *et al*. A prospective, randomized comparison of single and three piece acrylic foldable intraocular lenses. *Br J Ophthalmol* 2004;**88**:746–749.
- 37 **Sacu S**, Findl O, Menapace R, *et al*. Comparison of posterior capsule opacification between the 1-piece and 3-piece acrysof intraocular lenses. *Ophthalmology* 2004;**111**:1840–6.
- 38 **Baratz KH**, Cook BE, Hodge DO. Probability of Nd:YAG laser capsulotomy after cataract surgery in Olmsted County, Minnesota. *Am J Ophthalmol* 2001;**131**:161–6.
- 39 **Ando H**, Ando N, Oshika T. Cumulative probability of neodymium:YAG laser posterior capsulotomy after phacoemulsification. *J Cataract Refract Surg* 2003;**29**:2148–54.
- 40 **Nishi O**, Nishi K, Akura J. Speed of capsular bend formation at the optic edge of acrylic, silicone, and poly(methyl methacrylate) lenses. *J Cataract Refract Surg* 2002;**28**:431–7.
- 41 **Nishi O**, Nishi K, Akura J, *et al*. Effect of round-edge acrylic intraocular lenses on preventing posterior capsule opacification. *J Cataract Refract Surg* 2001;**27**:608–13.
- 42 **Nishi O**, Nishi K, Osakabe Y. Effect of intraocular lenses on preventing posterior capsular opacification: design versus material. *J Cataract Refract Surg* 2004;**30**:2170–6.
- 43 **Findl O**, Menapace R, Sacu S, *et al*. Effect of optic material on posterior capsule opacification in intraocular lenses with sharp-edge optics. *Ophthalmology* 2005;**112**:67–72.
- 44 **Boyce JF**, Gurbpreet SB, Spalton DJ, *et al*. Mathematical modeling of the forces between an intraocular lens and the capsule. *J Cataract Refract Surg* 2002;**28**:1853–9.
- 45 **Maltzman BA**, Haupt E, Notis C. Relationship between age at time of cataract extraction and time interval before capsulotomy for opacification. *Ophthalmic Surg* 1989;**20**:321–4.
- 46 **Ninn-Pedersen K**, Bauer B. Cataract patients in a defined Swedish population 1986–1990. *Acta Ophthalmol Scand* 1997;**75**:551–5.
- 47 **Pinter SM**, Sugar A. Phacoemulsification in eyes with pars plana vitrectomy: case-control study. *J Cataract Refract Surg* 1999;**25**:556–61.
- 48 **Grusha YO**, Masket S, Miller KM. Phacoemulsification and lens implantation after pars plana vitrectomy. *Ophthalmology* 1998;**287**–94.
- 49 **Ionides A**, Dowler JGF, Hykin PG, *et al*. Posterior capsule opacification following diabetic extracapsular cataract extraction. *Eye* 1994;**8**:535–7.



Nd:YAG capsulotomy rates after use of the AcrySof acrylic three piece and one piece intraocular lenses

S I Mian, K Fahim, A Marcovitch, et al.

Br J Ophthalmol 2005 89: 1453-1457

doi: 10.1136/bjo.2005.067405

Updated information and services can be found at:

<http://bjo.bmj.com/content/89/11/1453.full.html>

These include:

References

This article cites 45 articles, 4 of which can be accessed free at:

<http://bjo.bmj.com/content/89/11/1453.full.html#ref-list-1>

Article cited in:

<http://bjo.bmj.com/content/89/11/1453.full.html#related-urls>

Email alerting service

Receive free email alerts when new articles cite this article. Sign up in the box at the top right corner of the online article.

Topic Collections

Articles on similar topics can be found in the following collections

[Ophthalmologic surgical procedures](#) (962 articles)

[Lens and zonules](#) (638 articles)

Notes

To request permissions go to:

<http://group.bmj.com/group/rights-licensing/permissions>

To order reprints go to:

<http://journals.bmj.com/cgi/reprintform>

To subscribe to BMJ go to:

<http://group.bmj.com/subscribe/>