

## SCIENTIFIC REPORT

# Comparison of optical coherence tomography models OCT1 and Stratus OCT for macular retinal thickness measurement

V Pierre-Kahn, R Tadayoni, B Haouchine, P Massin, A Gaudric

*Br J Ophthalmol* 2005;89:1581–1585. doi: 10.1136/bjo.2005.069815

**Aims:** To compare the values measured for retinal macular thickness with the first and last generations of the optical coherence tomograph (OCT1 and Stratus OCT, Zeiss, Humphrey Division).

**Methods:** This was a cohort study. 59 eyes were examined: 17 had a normal macula and 42 had a diabetic macular oedema. In each eye, mean retinal thickness (RT) was measured automatically in the nine macular Early Treatment Diabetic Retinopathy Study areas and at the foveal centre, using OCT1 and Stratus OCT. The paired mean RT values for each area and the type and proportion of artefacts were compared.

**Results:** Of the 590 automatic measurements, 505 had no artefact, either with OCT1 or Stratus OCT. The mean difference between the OCT1 and Stratus OCT measurements was 25 (SD 26.2)  $\mu\text{m}$  ( $p < 0.0001$ ). With Stratus OCT, RT values were significantly higher, by 8.1% (7.8%), than with OCT1. Artefacts were only observed in cases of diabetic macular oedema and were significantly more frequent with OCT1 than Stratus OCT (10.5% versus 4.4,  $p < 0.0001$ ).

**Conclusion:** The macular retinal thickness values measured with Stratus OCT were significantly higher than those measured with OCT1. Stratus OCT has the advantage of producing fewer artefacts than OCT1 in pathological cases.

informed consent to participate. For diabetic patients, OCT examination was part of the usual assessment of the fundus.

Diabetic patients with the following characteristics were excluded: opaque media, treated macular oedema, or loss of central fixation.

## Optical coherence tomography

OCT1 and Stratus OCT were performed on each eye on the same day and by the same examiners (BH or VPK). Radial line scan protocol was used for both OCT instruments to map the macular areas. With OCT1, RT was measured automatically using the latest software version (A6.2, Carl Zeiss Meditec, Dublin CA, USA), which enabled us to obtain, in 1 second, cross sectional tomographic images 6 mm long (radial B-scan), comprising 100 axial measurements (A-scans). Axial resolution was about 13  $\mu\text{m}$ . The retinal map was calculated by integrating the results of the six radial scans (fig 1A). Mean macular RT was displayed for the nine Early Treatment Diabetic Retinopathy Study (ETDRS)-type areas,<sup>3</sup> including a central 1000  $\mu\text{m}$  disc and inner and outer rings of 3000  $\mu\text{m}$  and 6000  $\mu\text{m}$ , respectively. Each ring was divided into four quadrants (fig 1B). Average RT was calculated automatically for each of the nine quadrants (A1–A9). Central foveal RT was also calculated at the point of intersection of the six radial lines. A paired comparison was performed of the two sets of 590 values.

With Stratus OCT, the latest software version (2.0, Carl Zeiss Meditec, Dublin, CA, USA) was used for RT measurements. Tomographic images 6 mm long were obtained in 1.2 seconds and integrated 512 A-scans with consequent higher longitudinal resolutions than those of OCT1. Axial resolution was also better, at about 7  $\mu\text{m}$ . Mean macular RT was displayed on the same radial spoke pattern grid as with OCT1 (fig 2).

## Artefacts

The proportion of artefacts on radial B-scans was also compared for OCT 1 and Stratus OCT. Artefacts were defined as the discordance between the automatically detected anterior and posterior retinal boundaries and the boundaries detected by the examiner. Such artefacts can either increase or reduce the RT values measured manually in the quadrants concerned (fig 3).

## Data analysis

Comparison of OCT1 and Stratus OCT macular RT estimations was based on quadrant by quadrant paired comparison. The coefficient of correlation and the mean difference between RT measurements with OCT1 and Stratus OCT were calculated. Results are expressed as means (SD). Fisher's

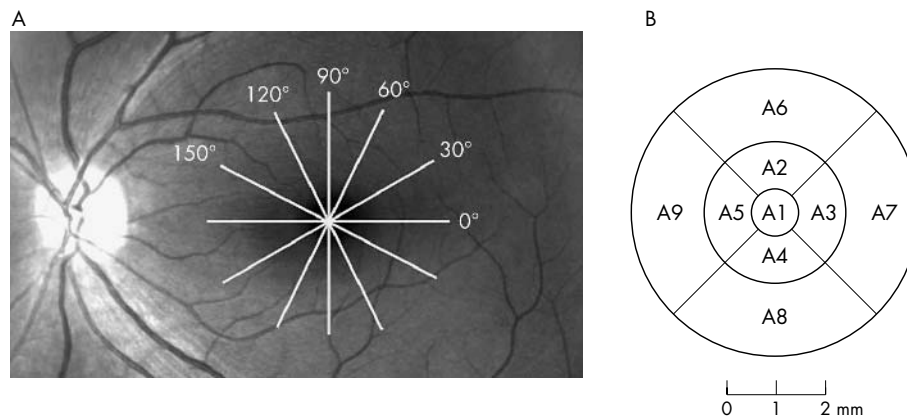
**Abbreviations:** IS, inner segment; OCT, optical coherence tomography; OS, outer segment; RPE, retinal pigment epithelium; RT, retinal thickness

The introduction of optical coherence tomography (OCT) in clinical practice in 1996 made it possible to measure retinal thickness (RT) routinely. The first version, OCT1 (Carl Zeiss Meditec, Humphrey Division, Dublin CA, USA), had an axial resolution of about 15  $\mu\text{m}$ . In 2002, the new Stratus OCT came into use and reduced axial resolution by up to 7  $\mu\text{m}$ . The repeatability and reliability of RT measurements with OCT1 have been demonstrated in several studies.<sup>1,2</sup> It was therefore of interest to test the new Stratus OCT instrument, to see if it gave the same retinal thickness values as the OCT1, and whether artefacts were less frequent with Stratus OCT than with OCT1. We then compared the macular retinal thickness values obtained with OCT1 and Stratus OCT for normal and diabetic patients.

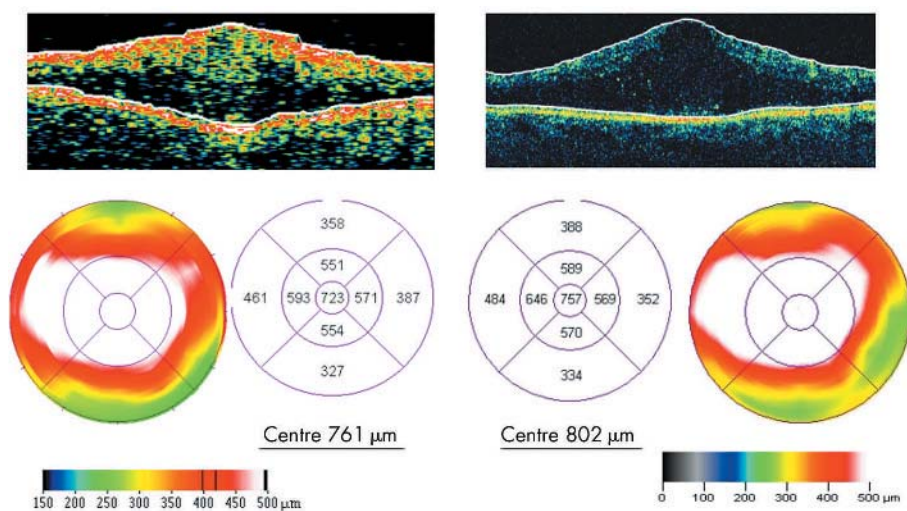
## PATIENTS AND METHODS

### Patients

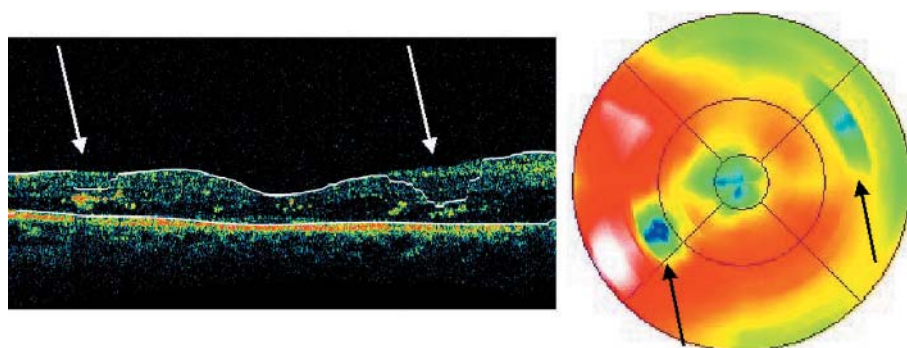
Retinal macular thickness was measured in 59 eyes of 37 patients using OCT1 and Stratus OCT. Seventeen eyes of 13 healthy emmetropic volunteers (six men and seven women, mean age 37.5 (SD 8.6) years) as well as 42 eyes of 24 diabetic patients with untreated focal or diffuse macular oedema (15 men and nine women, mean age 56.5 (11.2) years) were included in the study. The volunteers gave



**Figure 1** Retinal mapping protocol. (A) Radial spoke pattern of six 6 mm long scans centred on the subject's fixation point in a healthy left eye, (B) ETDRS-type areas of the macula in a left eye. A1, central zone 1000 µm in diameter; A2–A5, superior, temporal, inferior and nasal areas of a disc 3000 µm in diameter; and A6–A9 of a disc 6000 µm in diameter.



**Figure 2** (Top) 6 mm long vertical scan line on (left) OCT1 and (right) Stratus OCT, with the automatically positioned anterior and posterior retinal boundaries (white lines). (Bottom) Right eye of a diabetic patient with macular oedema, as seen with (left) OCT1 and (right) Stratus OCT macular mapping with colour coded map and numerical RT.



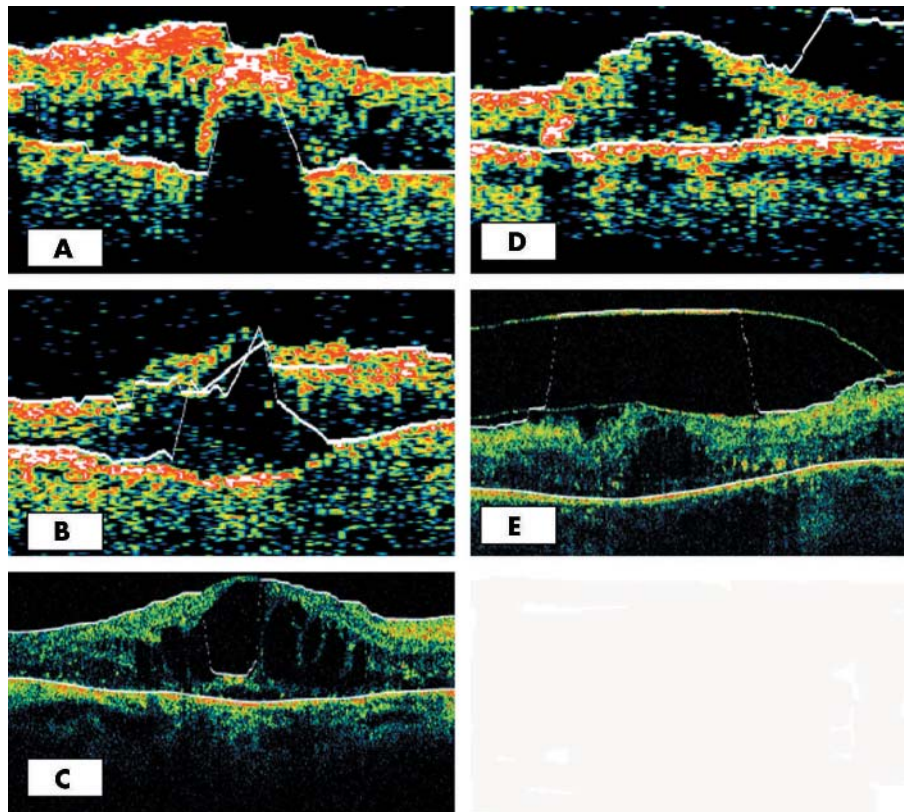
**Figure 3** Stratus OCT scan line 6 mm long centred on the fovea, at an angle of 30° from the horizontal line, in a diabetic right eye with focal temporal macular oedema. Two intraretinal hyper-reflective exudates (white arrows) generate (left) a lower automatically positioned inner retinal boundary with (right) two subsequent artefacts (black arrows) in the retinal thickness mapping (quadrants A7 and A9).

exact test was used for the correlation studies, and paired Student t test, for the comparative studies. Statistical analysis was performed with Apple iMac StatView software (SAS Institute Inc, Version 5.0). All analyses were performed on the two complete sets of 590 values and also on the sets of values that remained after the exclusion of quadrants with artefactual measurements. The type and proportion of the artefacts obtained with OCT1 and Stratus OCT were also compared ( $\chi^2$  test).

**Retinal outer boundary reference line**

Careful examination of the outer boundary reference line, automatically aligned by the mapping software of OCT,

showed that, in Stratus OCT, it was constantly located on the inner segment/outer segment (IS/OS) photoreceptor line rather than on the retinal pigment epithelium (RPE) line. This misalignment was not noted in OCT1, which did not distinguish between these two lines because of its lower axial resolution. To evaluate and quantify this error more accurately, we measured the mean distance between the IS/OS and the RPE lines, at the foveal centre of healthy maculas mapped with Stratus OCT, using the "Scan Profile" protocol of the software. The outer boundary of the retina was characterised by two peaks, the outermost being the signal of the RPE. Callipers easily allowed measurement of the distance between the two peaks. This measurement was



**Figure 4** Examples of artefacts resulting in lower RT values due to (A) the presence of hard exudates with OCT1, (B) erroneous analyses of a cystoid macular oedema with both OCT1 and (C) Stratus OCT. Examples of artefacts resulting in increased RT values due to misinterpretation of a detached posterior hyaloid as the internal limiting membrane by both (D) OCT1, and (E) Stratus OCT.

repeated at the five contiguous pixels on each side. The average of the 11 measurements performed was considered as the distance between the two lines at the foveal centre.

**RESULTS**  
**Artefacts**

Of the two sets of 590 paired values, 85 exhibited artefacts with either OCT1 or Stratus OCT or both. With OCT1, artefacts were present in 19 eyes, and with Stratus OCT, in nine. They were only observed in eyes with diabetic macular oedema (DMO). Of the two sets of 420 values obtained with OCT1 and Stratus OCT in the 42 eyes with DMO, 62 (10.5%) and 26 (4.4%), respectively, exhibited artefacts ( $p < 0.0001$ ). Artefacts resulting in lower RT values than with manual measurement were observed in 44/62 quadrants (71%) in the OCT1 scans, and in 16/26 quadrants (61.5%) in the Stratus OCT scans. These underestimations were mainly the result of the presence of intraretinal hard exudates, or by erroneous analysis of cystoid macular oedema (fig 4A, B, and C). There were a few overestimated artefacts, the result of erroneous positioning of the inner boundary of the retina. The detached

posterior hyaloid was, for example, misinterpreted as the internal limiting membrane (fig 4D and E).

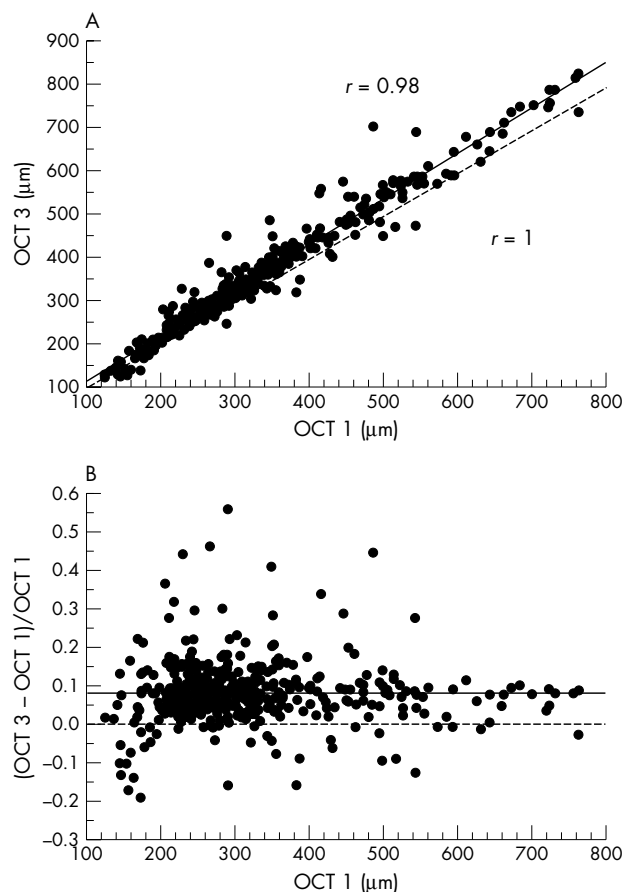
**Retinal thickness values**

On the basis of the two complete series of 590 values—that is, including the artefacts, the mean RT in the 6 mm diameter area was 322.3 (126.3)  $\mu\text{m}$  with OCT1 and 358.9 (156)  $\mu\text{m}$  with Stratus OCT. There was good agreement between the two instruments ( $r = 0.899$ ,  $p < 0.0001$ ). However, the RT values obtained with Stratus OCT were always higher than those obtained with OCT1, by 11.6% (23.1%) (mean difference: 36.6 (70.1)  $\mu\text{m}$   $p < 0.0001$ ); the greater the retinal thickness, the greater the difference.

On the basis of the two series of 505 values—that is, excluding the artefacts, the mean RT in the 6 mm diameter area, was 308.8 (116.8)  $\mu\text{m}$  with OCT1 and 333.8 (126.7)  $\mu\text{m}$  with Stratus OCT. The agreement between the OCT1 and Stratus OCT measurements was better than when the artefactual quadrants were included ( $r = 0.98$ ,  $p < 0.0001$ ). However, these measurements still remained unequal (fig 5A). The mean difference between Stratus OCT and

**Table 1** Distribution of (1) the retinal thickness (RT) measured with OCT1 and with Stratus OCT, (2) the difference between the RT values measured with Stratus OCT and OCT1, and (3) the RT ratio (Stratus OCT – OCT1)/OCT1 based on the 505 non-artefactual RT measurements for 42 eyes with diabetic macular oedema and 17 eyes with healthy maculae

	OCT 1 ( $\mu\text{m}$ )	Stratus OCT ( $\mu\text{m}$ )	Stratus OCT – OCT 1 ( $\mu\text{m}$ )	(Stratus OCT – OCT 1)/OCT 1
Number of values	505	505	505	505
Mean	308.8	333.8	25.0	0.08
SD	116.8	126.7	26.2	0.078
Error of mean	5.2	5.6	1.2	0.003
Minima	124	126	-68	-0.192
Maxima	761	824	+216	+0.557



**Figure 5** Non-artefactual measurements of macular retinal thickness obtained with OCT1 compared to those obtained with Stratus OCT. (A) Graph showing the correlation between RT measurements with OCT1 and Stratus OCT (solid line: observed correlation  $r=0.98$ ; broken line: equal correlation  $r=1$ ). (B) The values for macular retinal thickness measured with Stratus OCT were higher than those measured with OCT1. The excess ranged from 7.5% to 8.7% (mean 8.1) in 95% of the measures.

OCT1 RT values was 25 (26.2)  $\mu\text{m}$  ( $p<0.0001$ ). The RT measurements obtained with Stratus OCT always exceeded those obtained with OCT1, by 8.1% (7.8%) (fig 5B and table 1).

In the 17 healthy eyes, the mean RT in the central area 1 mm in diameter, according to the mapping software, was 178.4 (11.5)  $\mu\text{m}$  with OCT1, and 191.4 (17.6)  $\mu\text{m}$  with Stratus OCT. These measurements were also correlated ( $r=0.76$ ,  $p=0.0002$ ). In this area, mean difference between Stratus OCT and OCT1 RT measurements was 13 (11.8)  $\mu\text{m}$ , ( $p=0.0004$ ).

#### Distance between the two outer hyper-reflective lines on stratus OCT

The distance between these two outer lines, measured at the foveal centre on Stratus OCT A-Scan as the mean value of 11 contiguous measurements, was 46.6 (9)  $\mu\text{m}$ .

#### DISCUSSION

Axial resolution is twice as good with Stratus OCT as with OCT1 (about 7  $\mu\text{m}$  with 1000 pixels for each A-scan versus 13  $\mu\text{m}$  with 500 pixels for OCT1). Longitudinal resolution is also better with Stratus OCT (512 axial profiles per tomographic line, instead of 100 with OCT1). In the present study, RT was therefore measured in each 6 mm diameter area at a total of 600 points using OCT1 and 3072 points

using Stratus OCT. In both OCT instruments, computer image processors measure RT from retinal tomograms as the distance between the highly reflective inner and outer boundaries of the retina, which are located by a thresholding algorithm.<sup>5</sup>

The mapping software of OCT1 has been shown to have good reproducibility for RT measurements in healthy subjects, and in patients with DMO.<sup>1,2</sup> It also appeared to be a sensitive tool for detecting early retinal thickening in diabetic patients.<sup>6,7</sup> We therefore compared the RT measurements obtained with OCT1 (software A6.2) and Stratus OCT (software 2.0) and showed that both give measurements that are highly correlated but nevertheless slightly different. We do not know which OCT gives RT values closest to the in vivo reality, and can only compare the macular RT measured with both instruments. Stratus OCT tended to overestimate the RT measured with OCT1, by 25 (26.2)  $\mu\text{m}$  ( $p<0.0001$ ). As stated in Results, the greater the RT, the greater the difference between OCT1 and Stratus OCT values. The equation:  $\text{RT}(\text{Stratus OCT}) = 1.064 \text{ RT}(\text{OCT1}) + 5.43$  was extrapolated from the regression graph “ $\text{RT}(\text{Stratus OCT}) = f(\text{RT}(\text{OCT1}))$ ” (fig 5A) obtained with StatView software. The mean percentage by which Stratus OCT exceeded OCT1 was 8.1% (7.8%) (fig 5B). Despite the wide range observed for this ratio (−19% to +56%), the standard error of the mean was only 0.3%—that is, in 95% of the RT measures, Stratus OCT exceeded OCT1 by 7.5% to 8.7%. This means that by adding 8% to our OCT1 values, we can estimate the Stratus OCT values with an error of less than 0.6% in 95% of cases. Conversely, by reducing the Stratus OCT values by 7%, the OCT1 values can be estimated with an error of less than 0.6% in 95% of cases.

Because of its better axial resolution, Stratus OCT displays two different outer hyper-reflective lines. The innermost is generated by the IS/OS junction, as shown by Drexler *et al*<sup>8</sup> with an ultra high resolution OCT prototype, and the outermost, by the RPE. Stratus OCT takes the IS/OS line as the outer boundary of the retina, thus underestimating RT. The difference between the RT measurements obtained with the two OCT instruments would have been greater if the outer boundary line of the Stratus OCT had been correctly located at the RPE level.

The significantly lower artefact rate with Stratus OCT than with OCT1 for DMO (4.4% v 10.5%) may be the result of the better definition of A-scans with the former instrument. Artefact locations were also different. Most of the artefacts encountered in OCT1 were not seen in Stratus OCT and vice versa. Maculopathies with hard exudates are the most likely to generate artefacts. However, even in these eyes, artefacts were fewer with Stratus OCT than with OCT 1.

In conclusion, retinal thickness measured with Stratus OCT (version 2.0) was significantly greater than with OCT1 (version A6.2). Therefore, extrapolation of retinal thickness measurements from OCT1 to Stratus OCT should take into account a correcting value. This value would be even higher, by up to 46  $\mu\text{m}$ , if the outer reference line for macular thickness measurement were correctly located on the RPE and not on the IS/OS line. Although Stratus OCT has the advantage of being more accurate and producing fewer artefacts than OCT1 in pathological cases, the retinal thickness values provided by its mapping software should be carefully reappraised.

#### Authors' affiliations

V Pierre-Kahn, R Tadayoni, B Haouchine, P Massin, A Gaudric, Department of Ophthalmology, Hospital Lariboisiere, Assistance Publique-Hôpitaux de Paris, Université Paris 7, Paris, France

Correspondence to: Ramin Tadayoni, MD, Service d'Ophtalmologie, Hôpital Lariboisière 2, rue Ambroise Paré, 75475 Paris Cedex 10, France; [ramin.tadayoni@lrb.ap-hop-paris.fr](mailto:ramin.tadayoni@lrb.ap-hop-paris.fr)

Accepted for publication 1 August 2005

## REFERENCES

- 1 **Massin P**, Vicaut E, Haouchine B, *et al*. Reproducibility of retinal thickness measurements in healthy and diabetic subjects using optical coherence tomography. *Arch Ophthalmol* 2001;**119**:1135–42.
- 2 **Baumann M**, Gentile R, Liebmann J, *et al*. Reproducibility of retinal thickness measurements in normal eyes using optical coherence tomography. *Ophthalmic Surg Lasers* 1998;**29**:280–85.
- 3 **Early Treatment Diabetic Retinopathy Study Research Group**. Photocoagulation for diabetic macular edema. ETRRS report number 1. *Arch Ophthalmol* 1985;**103**:1796–806.
- 4 **Drexler W**, Sattmann H, Hermann B, *et al*. Enhanced visualization of macular pathology with the use of ultrahigh-resolution optical coherence tomography. *Arch Ophthalmol* 2003;**121**:695–706.
- 5 **Hee MR**, Puliafito CA, Duker JS, *et al*. Topography of diabetic macular edema with optical coherence tomography. *Ophthalmology* 1998;**105**:360–70.
- 6 **Massin**, Erginay A, Haouchine B, *et al*. Retinal thickness in healthy and diabetic subjects measured using optical coherence tomography mapping software. *Eur J Ophthalmol* 2002;**12**:102–8.
- 7 **Otani T**, Kishi Sh, Maruyama Y. Patterns of diabetic macular edema with optical coherence tomography. *Am J Ophthalmol* 1999;**127**:688–93.

## Video reports

To view the video reports in full visit our website [www.bjophthalmol.com](http://www.bjophthalmol.com) and click on the link to the video reports.

Video Suite: Subconjunctival dirofilariasis

- Removal of Dirofilarial worm from the subconjunctival space. *D Malik, S Alexander*
- Subconjunctival Dirofilariasis. *G Singh, K Myint, P Sathyain, S Mon, R Manikandan, B Dhillon*
- Magnet-assisted pars plana vitrectomy for giant metallic intraocular foreign body. *R Jorge, RA Costa, JC Castro, RC Siqueira*
- Suture of a Subluxated Posterior Chamber Lens within the Capsular Bag. *LE Fernández de Castro, KD Solomon*
- Ocular Onchocerciasis: Anterior Chamber Microfilariae. *WJ Flynn, HD Dillon*
- Zero Phaco Microincision Cataract Surgery: The Hacc Technique. *K Vaitheeswaran, S Gars, R Grover, M Nadar, S Sharma*
- The presenting features of multiple sclerosis. *VJM Barrett, J Walker, JS Elton*
- Removal of INTACS: Stepped surgical complexity demonstrated with three cases. *L Ilari, J C McAlister, D S Gartry*
- The Nuclear Slide: A novel approach for unleashing the potential of the hydrodissection wave. *A Naseri*
- Giant pleomorphic adenoma of the lacrimal gland: pre- and post-operative function. *A Jain, V I Nehru, U N Saikia, C E E Reddy*
- Limbal-sparing lamellar keratoplasty. *S L Watson, S Rauz, J Dart*



## Comparison of optical coherence tomography models OCT1 and Stratus OCT for macular retinal thickness measurement

V Pierre-Kahn, R Tadayoni, B Haouchine, et al.

*Br J Ophthalmol* 2005 89: 1581-1585

doi: 10.1136/bjo.2005.069815

---

Updated information and services can be found at:

<http://bjo.bmj.com/content/89/12/1581.full.html>

---

*These include:*

### References

This article cites 7 articles, 3 of which can be accessed free at:

<http://bjo.bmj.com/content/89/12/1581.full.html#ref-list-1>

Article cited in:

<http://bjo.bmj.com/content/89/12/1581.full.html#related-urls>

### Email alerting service

Receive free email alerts when new articles cite this article. Sign up in the box at the top right corner of the online article.

---

### Topic Collections

Articles on similar topics can be found in the following collections

[Epidemiology](#) (756 articles)

[Retina](#) (1207 articles)

---

### Notes

---

To request permissions go to:

<http://group.bmj.com/group/rights-licensing/permissions>

To order reprints go to:

<http://journals.bmj.com/cgi/reprintform>

To subscribe to BMJ go to:

<http://group.bmj.com/subscribe/>