

EXTENDED REPORT

Further evidence of genetic heterogeneity in familial exudative vitreoretinopathy; exclusion of *EVR1*, *EVR3*, and *EVR4* in a large autosomal dominant pedigree

C Toomes, L M Downey, H M Bottomley, H A Mintz-Hittner, C F Inglehearn

Br J Ophthalmol 2005;89:194-197. doi: 10.1136/bjo.2004.042507

See end of article for authors' affiliations

Correspondence to:
Dr Carmel Toomes,
Molecular Medicine Unit,
Clinical Sciences Building,
St James's University
Hospital, Leeds LS9 7TF,
UK; c.toomes@leeds.ac.ukAccepted for publication
22 July 2004**Background/aims:** Familial exudative vitreoretinopathy (FEVR) is an inherited blinding condition characterised by abnormal development of the retinal vasculature. The aim of this study was to perform linkage analysis in a large family affected with FEVR to determine whether the mutation involved was in one of the three known autosomal dominant FEVR loci or in another as yet unidentified gene.**Methods:** Genomic DNA samples from family members were polymerase chain reaction (PCR) amplified with fluorescently tagged microsatellite markers spanning the *EVR1/EVR4* locus (11q13-14) and the *EVR3* locus (11p12-13). The resulting PCR products were resolved using an automated DNA sequencer and the alleles sized. These data were used to construct haplotypes across each locus and linkage analysis was performed to prove or exclude linkage.**Results:** The clinical evaluation in this family suggested features typical of FEVR, with deficient peripheral retinal vascularisation being the common phenotype in all affected individuals. However, linkage analysis proved that this family has a form of FEVR genetically distinct from the *EVR1*, *EVR3* and *EVR4* loci.**Conclusion:** The exclusion of linkage in this family to any of the known FEVR loci proves the existence of a fourth locus for autosomal dominant FEVR and shows that this rare disorder is far more heterogeneous than previously thought.

Familial exudative vitreoretinopathy (FEVR) is a rare but well defined inherited disorder of retinal vessel development.¹ The primary pathological process in FEVR is believed to be a premature arrest of retinal vasculogenesis/angiogenesis or retinal vascular differentiation, leading to incomplete vascularisation of the peripheral retina.² All affected individuals have an avascular peripheral retina, so when this is used as the diagnostic criterion, FEVR has a penetrance of 100%. However, this feature alone usually causes no clinical symptoms and can often be diagnosed only by molecular testing or fluorescein angiography.³ Therefore, it is not uncommon for affected individuals to be unaware that they have the disorder until other more severely affected family members are diagnosed, prompting them to seek a diagnosis. The visual problems and variable phenotype present in FEVR are thought to be the result of secondary complications caused by the resulting retinal ischaemia. Neovascularisation around the region of demarcation near the avascular retina is thought to produce a fibrotic response with patients frequently demonstrating peripheral vitreoretinal opacities suggestive of fibrosis. As a consequence, retinal traction may be manifest as macular ectopia or peripheral retinal folds and a proportion of individuals develop a falciform retinal fold. Vascular exudation is a variable feature and occasionally is severe enough to produce a non-rhegmatogenous retinal detachment. Rhegmatogenous retinal detachment is more frequently seen and is often thought to be a consequence of traction although inherent abnormalities of the peripheral retina such as atrophic retinal holes may play a part. These features cause a reduction in visual acuity and in 20% of FEVR cases lead to partial or total blindness.²

FEVR is genetically heterogeneous and can be inherited as an autosomal dominant,⁴⁻⁵ autosomal recessive,⁶⁻⁷ or X linked trait.⁸⁻⁹ To date four loci have been mapped, one X linked (*EVR2* on chromosome Xp)¹⁰ and three autosomal dominant

(*EVR1*¹¹ and *EVR4*¹² on chromosome 11q and *EVR3*¹³ on chromosome 11p). No recessive locus has yet been identified.

The first FEVR locus, *EVR1*, was localised to chromosome 11q13-q23, between D11S527/D11S533 and D11S35, by genetic mapping in two large autosomal dominant pedigrees.¹¹ Subsequent analysis in further families confirmed linkage to this interval,¹⁴⁻¹⁷ and in 2002 the *EVR1* gene was identified when FEVR patients were found to have mutations in the gene *FZD4*, which encodes the Wnt receptor Frizzled-4.¹⁸

The second FEVR locus, *EVR2*, was mapped in X linked pedigrees to chromosome Xp11.4.¹⁰ The mutated gene within this locus was almost immediately identified and shown to be the same as that mutated in Norrie disease, *NDP*.¹⁹⁻²⁰ Norrie disease is a rare X linked recessive neurodevelopmental disorder characterised by congenital blindness, with a proportion of patients (30%) also having sensorineural deafness and mental disturbances.²¹ *NDP* encodes a secreted protein containing a cystine knot motif²² which has recently been shown to function as a high affinity ligand for Frizzled-4.²³

The third locus for FEVR, *EVR3*, was identified on chromosome 11p12-p13 in a large Scottish family segregating FEVR in an autosomal dominant fashion.¹³ *EVR3* spans 14 cM and is flanked by the markers GATA34E08 (telomeric) and D11S4102 (centromeric). To date no other families have been reported to map to *EVR3* and the mutated gene is still unidentified.¹³

The fourth locus, *EVR4*, was only recently identified on chromosome 11q13 in a family originally reported as linking to the *EVR1* locus.¹⁵ After the identification of *FZD4* as the *EVR1* gene, it was screened in this family and excluded on the basis of both mutation analysis and haplotype data.¹² The causative gene in this family was mapped to a region within

Abbreviations: FEVR, familial exudative vitreoretinopathy

RESULTS

Clinical evaluation

The family studied is shown in figure 1. The phenotype in affected individuals concurred well with descriptions of FEVR in the literature. The proband (V:6) and two additional family members (III:1 and III:3) had bilateral tractional retinal detachments in childhood (fig 2A). Other affected family members were more mildly affected with a picture predominantly of retinal exudation. Seven adults (II:3, IV:2, IV:4, IV:5, IV:6, IV:8, and IV:9) had clusters of exudates throughout the retina (fig 2B), whereas three young patients (V:1, V:2, and V:3) had only isolated exudates. We were unable to identify the clinical status in three individuals. Individual II:4 had cataracts which obscured an adequate evaluation of his retina. Two young patients (V:4 and V:5) had minimal abnormalities in the far retinal periphery which could not be adequately photographed with the Kowa RC-2 camera. The proband had hand motion vision in his right eye and 20/60 vision in his left eye following surgery to halt the progression of its peripheral retinal detachment and lens irrigation and aspiration to treat its shallow anterior chamber. III:1 and III:3 were totally blind. All other family members were 20/20 best corrected except II:4 who had 20/400 vision primarily because of his cataracts. The slit lamp examinations on two affected patients revealed nasally displaced pupils without well defined collarettes and some shallowing of the anterior chambers (more pronounced in V:6 than in IV:6). Indocyanine green angiography failed to demonstrate normal vascularisation of the iris. Fluorescein angiography demonstrated the typical exudates of FEVR and the termination of peripheral vessels before reaching the ora serrata in IV:6, and macular dragging with peripheral retinal atrophic areas in V:6.

Exclusion of the FEVR loci

The family clearly shows an autosomal dominant inheritance pattern (fig 1), with male to male transmission ruling out the possibility that this family harbours a mutation in the X linked *EVR2* gene, *NDP*. Analysis therefore focused on the three known FEVR autosomal dominant loci and family members were genotyped with markers from chromosome 11 spanning *EVRI*, *EVR3*, and *EVR4*.

To test for linkage to the *EVRI* gene *FZD4*, genotyping was performed with marker D11S896, which according to the July 2003 version of the UCSC genome browser (genome.cse.ucsc.edu/index) is contained within the same genomic clone as *FZD4* (RP11-736K20-AP001528). To test for linkage to the *EVR4* gene *LRP5*, genotyping was performed with markers D11S913 and D11S4113. These markers flank *LRP5* and, according to the Marshfield genetic map, are separated by 1 cM.²⁷ The genotyping data for these markers is shown in figure 1 and the results of two point linkage analysis obtained with these markers are shown in table 1. The results show convincing exclusion of linkage to all three markers and

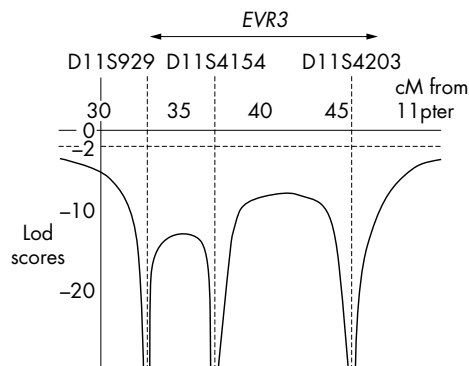


Figure 3 Multipoint graph showing exclusion of the *EVR3* locus. The approximate position of *EVR3* is shown above the graph. Lod scores lower than -2 are statistically significant for exclusion.

therefore rule out both *FZD4* and *LRP5* as the mutated gene in this family.

As the *FEVR* gene at the *EVR3* locus is still unknown, linkage analysis was performed using four markers spanning this locus. Markers and distances used are as follows; 11pter - 33 cM - D11S929 - 1 cM - D11S4956 - 4 cM - D11S4154 - 8 cM - D11S4203 - 102 cM - 11qtel. Each family member's haplotype obtained from these markers is shown in figure 1. Two point lod scores for these markers show convincing exclusion of linkage for *EVR3* (table 1) and multipoint linkage analysis with a subset of these markers (D11S929, D11S4154, and D11S4203) also show statistically significant exclusion across *EVR3* (lod score < -8) (fig 3). These data provide convincing exclusion of all three known autosomal dominant FEVR loci in this family.

DISCUSSION

We have provided evidence for the existence of a fourth autosomal dominant FEVR locus by excluding the three known dominant loci in a large Mexican family. This result implies that there are now at least five genes responsible for this phenotype, four autosomal dominant^{13 18 24} and one X linked.¹⁹ This number of genes is likely to increase further as recessive FEVR families have been described in the literature but a locus has yet to be reported.^{6 7} The increasing heterogeneity observed in FEVR is also evident from recent *FZD4* and *LRP5* mutation screens. Although *EVRI* has historically been reported as the major autosomal dominant locus for FEVR, mutations in *FZD4* and *LRP5* have been shown to account for only 40% of patients,^{24 29 30} suggesting that other unidentified genes play a significant part in this condition.

The phenotype described in this family fits well with the classic description of FEVR^{1 4} and with the phenotype seen in families linking to other FEVR loci.^{15 27-29} This pedigree shows

Table 1 Two point exclusion data for the *EVRI* (*FZD4*) and *EVR4* (*LRP5*) genes and the *EVR3* locus (11p12-13)

	Marker	cM for 11pter	0.0	0.01	0.05	0.1	0.2	0.3	0.4
<i>EVR3</i>	D11S929	33.0	-infini	-7.41	-4.00	-2.59	-1.32	-0.67	-0.27
	D11S4956	33.6	-infini	-5.53	-2.86	-1.80	-0.88	-0.43	-0.16
	D11S4154	37.6	-infini	-7.00	-3.63	-2.29	-1.11	-0.54	-0.21
	D11S4203	46.0	-infini	-6.84	-3.47	-2.12	-0.95	-0.42	-0.15
<i>EVR4</i>	D11S913	67.5	-infini	-10.88	-6.05	-4.03	-2.11	-1.08	-0.43
	D11S4113	68.0	-infini	-5.22	-2.56	-1.53	-0.68	-0.31	-0.12
<i>EVRI</i>	D11S896	89.2	-infini	-5.49	-2.82	-1.77	-0.86	-0.42	-0.16

a majority of individuals with retinal exudates which corresponds well with the original classification of the disease.⁴ Other pedigrees published showed less evidence of this feature³¹ but as exudation is a variable aspect of the phenotype this may not be significant. The only atypical features observed in this family were the anterior segment anomalies seen in individuals IV:6 and V:6. Several other affected family members were thought to have shallow anterior chambers and abnormal irides but because these individuals were examined in their own homes during a field trip to Mexico, they were examined without slit lamp biomicroscopy. It is therefore not possible to say whether these features invariably co-segregated with the retinal phenotype in this family. Lenticular anomalies in FEVR patients have been described previously⁷ but whether anterior segment anomalies are specific to mutations in particular FEVR genes remains to be determined. To date it is difficult to distinguish between the phenotypes seen at all four dominant FEVR loci without molecular testing. This fact is likely to hinder the development of a diagnostic screening service for FEVR as screening multiple genes for a rare disorder is unlikely to be cost effective.

By continuing to identify the genes responsible for FEVR and dissecting the genetic pathways involved in normal and abnormal retinal vessel formation, it is hoped that we can improve the understanding of this disease and facilitate improved diagnosis and treatment for people who have it.

Note added on proof

Since this paper was accepted recessive mutations have been described in the autosomal dominant *EVR4* gene, *LRP5* (Jiao *et al*, Autosomal recessive familial exudative vitreoretinopathy is associated with mutations in *LRP5*. *Am J Hum Genet* 2004;**75**:878–84).

ACKNOWLEDGEMENTS

We thank the FEVR family for their help with this study. The financial support of the Wellcome Trust (grants 069718/Z/02 and 055145/Z/98) is gratefully acknowledged. HMH is supported by grants from the Hermann Eye Fund, Houston, TX; Research to Prevent Blindness, Inc, New York, NY, USA; and by Vision Core National Institutes of Health, Bethesda, MD, USA (grant EY10608).

Authors' affiliations

C Toomes, L M Downey, H M Bottomley, C F Inglehearn, Molecular Medicine Unit, School of Medicine, University of Leeds, UK
H A Mintz-Hittner, Department of Ophthalmology and Visual Science, University of Texas-Houston Medical School, TX, USA

CT and LMD contributed equally to this work.

REFERENCES

- Benson WE. Familial exudative vitreoretinopathy. *Trans Am Ophthalmol Soc* 1995;**93**:473–521.
- van Nouhuys CE. Signs, complications, and platelet aggregation in familial exudative vitreoretinopathy. *Am J Ophthalmol* 1991;**111**:34–41.
- Ober RR, Bird AC, Hamilton AM, *et al*. Autosomal dominant exudative vitreoretinopathy. *Br J Ophthalmol* 1980;**64**:112–20.
- Gow J, Oliver GL. Familial exudative vitreoretinopathy. *Arch Ophthalmol* 1971;**86**:150–5.

- Laqua H. Familial exudative vitreoretinopathy. *Albrecht Von Graefes Arch Klin Exp Ophthalmol* 1980;**213**:121–33.
- Shastry BS, Trese MT. Familial exudative vitreoretinopathy: further evidence for genetic heterogeneity. *Am J Med Genet* 1997;**69**:217–18.
- De Crecchio G, Simonelli F, Nunziata G. Autosomal recessive familial exudative vitreoretinopathy: evidence for genetic heterogeneity. *Clin Genet* 1998;**54**:315–20.
- Plager DA, Orgel IK, Ellis FD, *et al*. X-linked recessive familial exudative vitreoretinopathy. *Am J Ophthalmol* 1992;**114**:145–8.
- Shastry BS, Liu X, Hejtmanck JF, *et al*. Evidence for genetic heterogeneity in X-linked familial exudative vitreoretinopathy. *Genomics* 1997;**44**:247–8.
- Fullwood P, Jones J, Bunday S, *et al*. X-linked exudative vitreoretinopathy: clinical features and genetic linkage analysis. *Br J Ophthalmol* 1993;**77**:168–70.
- Li Y, Muller B, Fuhrmann C, *et al*. The autosomal dominant familial exudative vitreoretinopathy locus maps on 11q and is closely linked to D11S533. *Am J Hum Genet* 1992;**51**:749–54.
- Toomes C, Downey LM, Bottomley HM, *et al*. Identification of a fourth locus (*EVR4*) for familial exudative vitreoretinopathy (FEVR). *Mol Vis* 2004;**10**:37–42.
- Downey LM, Keen TJ, Roberts E, *et al*. A new locus for autosomal dominant familial exudative vitreoretinopathy maps to chromosome 11p12-13. *Am J Hum Genet* 2001;**68**:778–81.
- Muller B, Orth U, Van Nouhuys CE, *et al*. Mapping of the autosomal dominant exudative vitreoretinopathy locus (*EVR1*) by multipoint linkage analysis in four families. *Genomics* 1994;**20**:317–19.
- Price SM, Periam N, Humphries A, *et al*. Familial exudative vitreoretinopathy linked to D11S533 in a large Asian family with consanguinity. *Ophthalmic Genet* 1996;**17**:53–7.
- Shastry BS, Hejtmanck JF, Hiraoka M, *et al*. Linkage and candidate gene analysis of autosomal-dominant familial exudative vitreoretinopathy. *Clin Genet* 2000;**58**:329–32.
- Kondo H, Ohno K, Tahira T, *et al*. Delineation of the critical interval for the familial exudative vitreoretinopathy gene by linkage and haplotype analysis. *Hum Genet* 2001;**108**:368–75.
- Robitaille J, MacDonald ML, Kaykas A, *et al*. Mutant Frizzled-4 disrupts retinal angiogenesis in familial exudative vitreoretinopathy. *Nat Genet* 2002;**32**:326–30.
- Chen ZY, Battinelli EM, Fielder A, *et al*. A mutation in the Norrie disease gene (*NDP*) associated with X-linked familial exudative vitreoretinopathy. *Nat Genet* 1993;**5**:180–3.
- Berger W. Molecular dissection of Norrie disease. *Acta Anat* 1998;**162**:95–100.
- Johnson K, Mintz-Hittner HA, Perry YM, *et al*. X-linked exudative vitreoretinopathy caused by an arginine to leucine substitution in exon 3 (R121L) of the Norrie gene. *Clin Genet* 1996;**50**:113–15.
- Meindl A, Berger W, Meitinger T, *et al*. Norrie disease is caused by mutations in an extracellular protein resembling C-terminal globular domain of mucins. *Nat Genet* 1992;**2**:139–43.
- Xu Q, Wang Y, Dabdoub A, *et al*. Vascular development in the retina and inner ear: control by Norrin and Frizzled-4, a high-affinity ligand-receptor pair. *Cell* 2004;**116**:883–95.
- Toomes C, Bottomley HM, Jackson RM, *et al*. Mutations in *LRP5* or *FZD4* underlie the common FEVR locus on chromosome 11q. *Am J Hum Genet* 2004;**76**:721–30.
- Lathrop GM, Lalouel JM, Julier C, *et al*. Strategies for multilocus linkage analysis in humans. *Proc Natl Acad Sci USA* 1984;**81**:3443–6.
- Dib C, Faure S, Fizames C, *et al*. A comprehensive genetic map of the human genome based on 5,264 microsatellites. *Nature* 1996;**380**:152–4.
- Broman KW, Murray JC, Sheffield VC, *et al*. Comprehensive human genetic maps: Individual and sex-specific variation in recombination. *Am J Hum Genet* 1998;**63**:861–9.
- Kong A, Gudbjartsson DF, Sainz J, *et al*. A high-resolution recombination map of the human genome. *Nat Genet* 2002;**31**:241–7.
- Kondo H, Hayashi H, Oshima K, *et al*. Frizzled 4 gene (*FZD4*) mutations in patients with familial exudative vitreoretinopathy with variable expressivity. *Br J Ophthalmol* 2003;**87**:1291–5.
- Toomes C, Bottomley HM, Scott S, *et al*. Spectrum and frequency of *FZD4* mutations in familial exudative vitreoretinopathy (FEVR). *Invest Ophthalmol Vis Sci* 2004;**45**:2083–90.
- Bamashmus MA, Downey LM, Inglehearn CF, *et al*. Genetic heterogeneity in familial exudative vitreoretinopathy: exclusion of the *EVR1* locus on chromosome 11q in a large autosomal dominant pedigree. *Br J Ophthalmol* 2000;**84**:358–63.



Further evidence of genetic heterogeneity in familial exudative vitreoretinopathy; exclusion of *EVR1*, *EVR3*, and *EVR4* in a large autosomal dominant pedigree

C Toomes, L M Downey, H M Bottomley, et al.

Br J Ophthalmol 2005 89: 194-197
doi: 10.1136/bjo.2004.042507

Updated information and services can be found at:
<http://bjournal.bmj.com/content/89/2/194.full.html>

References

These include:

This article cites 30 articles, 6 of which can be accessed free at:
<http://bjournal.bmj.com/content/89/2/194.full.html#ref-list-1>

Article cited in:
<http://bjournal.bmj.com/content/89/2/194.full.html#related-urls>

Email alerting service

Receive free email alerts when new articles cite this article. Sign up in the box at the top right corner of the online article.

Notes

To request permissions go to:
<http://group.bmj.com/group/rights-licensing/permissions>

To order reprints go to:
<http://journals.bmj.com/cgi/reprintform>

To subscribe to BMJ go to:
<http://group.bmj.com/subscribe/>