

## EXTENDED REPORT

## Impact of lesion size on photodynamic therapy with verteporfin of predominantly classic lesions in age related macular degeneration

L Arias, O Pujol, J Berniell, M Rubio, G Roca, L Castillo, E Acebes

*Br J Ophthalmol* 2005;89:312–315. doi: 10.1136/bjo.2004.050997

**Aim:** To determine if photodynamic therapy (PDT) outcomes are related to lesion size in patients with subfoveal predominantly classic choroidal neovascularisation (CNV) secondary to age related macular degeneration (AMD).

**Methods:** According to greatest linear dimension (GLD) of the entire lesion determined with fluorescein angiography (FA) patients were divided into two groups. In the first group GLD was <3000 µm and in the second one GLD was 3000–5000 µm. All eyes were treated with standard PDT with the verteporfin protocol. The primary outcome was the proportion of eyes in both groups that did not show significant leakage in FA at the end of follow up. Secondary outcomes were changes in GLD and in best corrected visual acuity (BCVA).

**Results:** 64 patients (mean (SD) age, 76.7 (7.7) years; range 58–95 years) were recruited to participate in the study. All participants in the study completed the follow up time (mean 16.6 months). 24 patients (75%) in the group of smaller lesions (n=32) compared with 15 patients (46.8%) in the group of larger lesions (n=32) did not show significant leakage in FA at the end of follow up (p=0.02). A GLD increase >1000 µm was recorded in nine eyes (28.1%) in the group of smaller lesions and in 16 eyes (50%) in the group of larger lesions (p=0.07). 22 eyes (68.7%) in the group of smaller lesions compared with 19 eyes (59.3%) in the group of larger lesions lost less than three lines of vision (p=0.06). Relevant side effects related to verteporfin therapy were not recorded, except for four patients (6.2%) with infusion related back pain.

**Conclusions:** These results suggest that lesion size at baseline may be a prognosis factor in PDT in patients with subfoveal predominantly classic CNV secondary to AMD. There are no relevant side effects or safety concerns derived from verteporfin therapy.

See end of article for authors' affiliations

Correspondence to: Luis Arias, Department of Ophthalmology, Bellvitge University Hospital, C/Feixa Llarga, sn, 08907, L'Hospitalet de Llobregat, Barcelona, Spain; [luisarias@telefonica.net](mailto:luisarias@telefonica.net)

Accepted for publication 1 August 2004

Photodynamic therapy (PDT) with verteporfin (Visudyne; Novartis Pharma AG, Basel, Switzerland) has been shown to reduce the risk of moderate and severe vision loss in selected patients with subfoveal choroidal neovascularisation (CNV) due to age related macular degeneration (AMD).<sup>1–3</sup> This therapy is recommended for AMD patients with: (1) subfoveal predominantly classic lesions (in which the area of classic CNV occupies at least 50% of the area of the entire lesion) and (2) occult with no classic subfoveal CNV in the presence of either a smaller lesion size ( $\leq 4$  MPS disc areas) or lower levels of visual acuity ( $< 20/50$ ) and presumed recent disease progression (blood associated with the CNV, visual acuity loss of at least one line within the past 12 weeks or growth of the lesion's GLD of at least 10% within the past 12 weeks). In contrast, no beneficial effect of PDT was seen in AMD patients with minimally classic lesions (area of classic CNV >0% but <50% of the area of the entire lesion), although retrospective analyses have suggested that the verteporfin therapy might be beneficial for a minimally classic lesion with a smaller size ( $\leq 4$  MPS disc areas) and a lower level of visual acuity ( $< 20/50$ ). Analyses showed that the treatment effect varied according to the baseline composition and size of CNV.<sup>4</sup>

Given the results derived from clinical trials, the indication of the verteporfin therapy is based on lesion composition. Nevertheless, current information derived from further investigations enhances the role of lesion size at baseline.

The objectives of this study were to evaluate if PDT outcomes were related to lesion size in patients with subfoveal predominantly classic lesions caused by AMD.

## PATIENTS AND METHODS

We conducted this prospective study at Bellvitge University Hospital, a referral centre for PDT in Catalonia (Spain) with a six million population. Patients were enrolled between January 2001 and September 2001. Informed consent was received from each subject before participation in our study. Each subject underwent a complete ophthalmic examination, including visual acuity testing with ETDRS charts, intraocular pressure measurement, slit lamp biomicroscopy, indirect ophthalmoscopy, and fluorescein angiography (FA).

To be eligible for the study patients must have met the following criteria: (1) 50 years of age or older, (2) neovascular AMD, (3) CNV under the geometric centre of the fovea (subfoveal), (4) area of classic CNV occupying at least 50% of the area of the entire lesion (predominantly classic), (5) greatest linear dimension (GLD) of the lesion  $\leq 5000$  µm, (6) Snellen visual acuity equivalent of 20/40 to 20/800 at baseline. Neovascular AMD was diagnosed by clinical examination and then further categorised by FA.

Patients were excluded if they had any condition other than AMD to account for CNV (such as pathologic myopia). Patients could not have been treated for CNV before being recruited for our study. Patients with severe liver disease or porphyria or hypersensitivity to porphyrins were excluded.

**Abbreviations:** AMD, age related macular degeneration; BCVA, best corrected visual acuity; CNV, choroidal neovascularisation; FA, fluorescein angiography; GLD, greatest linear dimension; PDT, photodynamic therapy

They were divided into two groups of 32 patients each one according to GLD of the entire lesion. In the first group GLD was <3000 μm and in the second one GLD was 3000–5000 μm. The GLD was determined in all cases by the same investigator from a digital fluorescein angiogram obtained with Imagenet (Topcon TRC-50XT; Topcon Corporation, Tokyo, Japan). The GLD was measured including all lesion components. This term refers to CNV (classic, occult, or both) and features that could obscure the boundaries of CNV (thick blood, hypofluorescence not corresponding to blood, serous detachment of the RPE, hyperfluorescent staining from fibrous tissue). The GLD was determined with the early to mid-phase angiograms, as these images are typically the most useful frames for measuring the classic lesions. The FA used to calculate the GLD was obtained within 1 week before PDT.

All patients received PDT with verteporfin following the standard protocol of treatment.<sup>1</sup> Verteporfin (6 mg/m<sup>2</sup> body surface area) was administered via intravenous infusion of 30 ml over 10 minutes. Fifteen minutes after the start of the infusion, a diode laser light at 689 nm (Zeiss Jena GmbH, Jena, Germany) delivered 50 J/cm<sup>2</sup> at an intensity of 600 mW/cm<sup>2</sup> over 83 seconds using a spot size with a diameter 1000 μm larger than the GLD of the lesion. The patients were instructed to avoid direct sunlight or bright indoor light for 48 hours after treatment.

Three months (SD 2 weeks) after the initial treatment patients were scheduled for a new ophthalmological examination, including an FA. If significant leakage from CNV was observed, the patient had further verteporfin treatment. Any change in GLD was documented.

This sequence was followed during the planned follow up time (18 months).

The primary outcome was the proportion of eyes in both groups that did not show significant leakage in FA at the end of follow up. No significant leakage was interpreted as complete absence of leakage from CNV or as minimal leakage (<50% of the area treated previously).<sup>5</sup> Secondary outcomes were changes in GLD and in best corrected visual acuity (BCVA).

**Statistical methods**

Statistical analysis for descriptive statistics was performed using SPSS statistical software. Categorical analysis was performed using the χ<sup>2</sup> test. Normally distributed continuous variables were compared with the independent samples *t* test, as appropriate. A *p* value less than 0.05 was considered to be significant.

**RESULTS**

Sixty four patients (mean (SD) age 76.7 (7.7) years; range 58–95 years), 28 women (43.7%) and 36 men (56.2%), were recruited to participate in the study. Patients were enrolled consecutively between January 2001 and September 2001. We decided to recruit at least 60 patients for statistical purposes, with the same number of patients in each group. The enrolment in the group of smaller lesions finished 1 month earlier than in the other group. Forty nine patients

(76.5%) were phakic and 15 patients (23.4%) were pseudophakic. In 27 cases (42.1%) the right eye was the affected one and in 37 cases (57.8%) it was the left eye. No patient with bilateral involvement was enrolled. Twenty six patients (40.6%) had a disciform scar in the fellow eye.

All participants in the study completed the follow up time (mean 16.6 months). By the last examination, but before any re-treatment at that visit, patients received an average of 3.0 treatments in the group of smaller lesions (<3000 μm). The average of treatments in the group of larger lesions (3000–5000 μm) was 3.4 per participant.

We did not record relevant side effects related to verteporfin therapy, except for four patients (6.2%) with infusion related back pain.

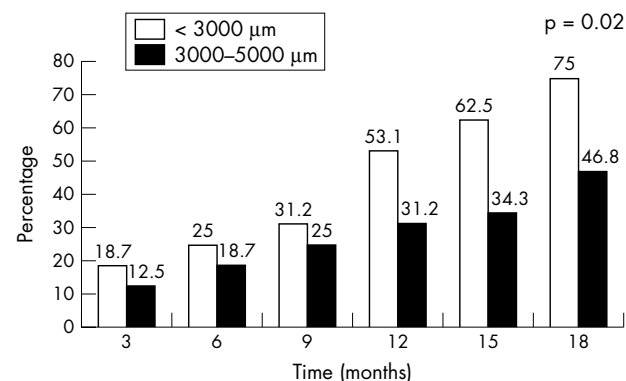
**Fluorescein angiographic outcomes**

At the end of follow up, 24 eyes (75%) in the group of smaller lesions compared with 15 eyes (46.8%) in the group of larger lesions did not show significant leakage in FA (*p* = 0.02) (fig 1). Therefore, these patients did not need to receive another verteporfin treatment at that time, although they were scheduled for a new examination outside the present study.

Changes in GLD are summarised in table 1. Mean GLD in the group of smaller lesions went from 2280 μm at baseline to 2950 μm at month 18 (mean increase of +670 μm). Mean GLD in the group of larger lesions went from 3940 μm at baseline to 5010 μm at month 18 (mean increase of +1070 μm). A GLD increase >1000 μm was recorded in nine eyes (28.1%) in the group of smaller lesions and in 16 eyes (50%) in the group of larger lesions (*p* = 0.07). Nevertheless, it must be noted that an increase of this order is more relevant in a small lesion than in a larger one.

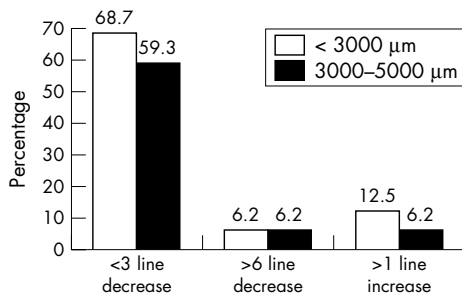
**Vision outcomes**

Visual acuity categories in study eyes are summarised in table 2. At the end of follow up, 22 eyes (68.7%) in the group of smaller lesions compared with 19 eyes (59.3%) in the group of larger lesions lost less than three lines of vision



**Figure 1** Percentage of eyes with no significant leakage from choroidal neovascularisation at each 3 month study visit over time.

	<3000 μm		3000–5000 μm	
	GLD at baseline	Final GLD	GLD at baseline	Final GLD
Mean	2281.2	2953.1	3940.6	5012.5
SD	457.5	1052.1	544.1	1224.1
Range	1400–3000	1400–5600	3100–5000	2600–7300



**Figure 2** Main changes in visual acuity observed in both groups of patients at the end of the study.

( $p = 0.06$ ) (fig 2). Two eyes in both groups (6.2%) lost six lines or more of vision. Eyes in the group of smaller lesions had more improvements of one or more lines of visual acuity compared with the other group (12.5% v 6.2%).

**DISCUSSION**

As shown from clinical trials, lesion composition is the most important factor to determine who may benefit from PDT with verteporfin in patients with subfoveal CNV as a result of AMD.<sup>1, 2</sup> Recent data suggest that lesion size might influence the treatment benefit in lesions composed of occult CNV with no classic CNV<sup>3</sup> or in those composed of minimally classic CNV.<sup>6</sup> The present study outcomes suggest that lesion size might influence the treatment benefit in lesions composed of predominantly classic CNV. The study compares the outcomes derived from verteporfin therapy in AMD patients divided into two groups according to GLD of the lesion. The primary outcome (proportion of eyes without significant angiographic leakage) is statistically significant in favour of the group of smaller lesions. Secondary outcomes (changes in GLD and in BCVA) are not statistically significant but they tend to be better in the group of smaller lesions.

In this study, the GLD of the lesion was immediately read on the screen using a digital based camera software. It is known that modern retinal practices have incorporated digital angiography, avoiding the time delay inherent to film based procedures and enhancing photographic productivity. In the present study we have used the measurement of the GLD of the lesion instead of the estimation of the size of the lesion in MPS disc areas. In the Treatment of Age Related Macular Degeneration with Photodynamic Therapy (TAP) investigation and the Verteporfin in Photodynamic Therapy (VIP) trial, lesion size was measured in MPS disc areas using film based cameras. To avoid misinterpretations as a result of the different angiographic system used in the measurement we have preferred to present our results as they are shown. To our knowledge, there has been no study that compares film and digital systems to determine if there are significant differences between these two systems in the interpretation of the lesions. In applying the results of the TAP investigation or VIP trial to clinical practice, clinicians should be aware of these considerations.

It is known that one of the most important findings of the TAP investigation was a differential benefit of verteporfin treatment depending on the amount of classic and occult CNV present in the lesion at baseline. In the subgroup analysis, predominantly classic lesions (classic CNV  $\geq 50\%$  of the entire lesion) were found to have greater treatment benefit than other types of lesion for all primary and secondary outcomes at both the 12 and 24 month follow up. In the TAP investigation 242 patients were included with predominantly classic CNV, 159 patients receiving verteporfin, and 83 patients receiving placebo. Our study included 64 patients, all of them treated with verteporfin.

The main outcome to evaluate was the proportion of eyes in both groups that did not show significant leakage in FA at the end of follow up. No significant leakage was interpreted as complete absence of leakage from CNV or as minimal leakage (<50% of the area treated previously). The results yield statistically significant differences between both groups of patients in favour of the group of smaller lesions (75% versus 46.8%;  $p = 0.02$ ). Nevertheless, it should be considered that in a larger lesion there is presumably more neovascular tissue and therefore this could impact on the amount of leakage observed. In the TAP investigation, 37% of patients with predominantly classic lesions receiving verteporfin showed complete absence of leakage from classic CNV at month 18. In our study we considered the proportion of eyes with complete absence of leakage and minimal leakage to indicate the patients who did not need to receive further verteporfin treatment at that time.

Changes in GLD recorded in our study showed that lesions had a tendency to enlarge despite receiving PDT. The mean increase was more important in the group of larger lesions than in the group of smaller lesions (+1070 μm versus +670 μm), although it must be considered in relation to the original lesion size at baseline. In fact, it must be noted that the proportional growth of the lesions was much the same whether they were small or large and this observation was not significantly different. However, an enlargement of the lesion should not be interpreted as a failure of the treatment.

Vision outcomes in our study are quite similar to those observed in the TAP investigation.

In the TAP investigation, 67% of patients with predominantly classic lesions receiving verteporfin at month 12, and 59% at month 24, lost less than 15 letters (three lines). In our study, 69% of patients in the group of smaller lesions compared with 59% in the group of larger lesions lost less than 15 letters at month 18. Nevertheless, it must be noted that 44% of patients in each one of our groups presented visual acuity levels less than 20/200 at baseline. On the other hand, in the TAP investigation these patients would not have been recruited. The initial visual acuity was slightly lower in the group of larger lesions (table 2). This should be considered when interpreting the results.

The average of treatments in the group of smaller lesions (3.0) and in the group of larger lesions (3.4) at month 18 is lower than that observed in the TAP investigation (5.6 at month 24). There is evidence among clinicians that the rate

**Table 2** Main visual acuity categories in study eyes

	<3000 μm BCVA at baseline	<3000 μm Final BCVA	3000-5000 μm BCVA at baseline	3000-5000 μm Final BCVA
>20/100	4 (12.5%)	2 (6.2%)	3 (9.3%)	1 (3.1%)
20/100-20/200	14 (43.7%)	14 (43.7%)	15 (46.8%)	12 (37.5%)
<20/200	14 (43.7%)	16 (50%)	14 (43.7%)	19 (59.3%)

BCVA, best corrected visual acuity.

of re-treatments in general practice is lower than that observed in PDT clinical trials.

In our study there were no relevant side effects or safety concerns derived from verteporfin therapy. It is known that the overall safety profile of verteporfin therapy is very good.<sup>7</sup>

We only observed four patients (6.2%) with infusion related back pain which did not affect the viability of the treatment. In the literature, some different approaches have been proposed to prevent this complication.<sup>8,9</sup>

This study has some limitations, and the recognition of these should help refine future research efforts. There was a limited number of patients enrolled at a single centre and there were no controls. The physicians were not blinded during examination of the patients or angiograms. The findings cannot be extrapolated to those obtained in the TAP investigation as some inclusion criteria and primary and secondary outcomes were different and lesion size was obtained in digital systems.

Despite the above limitations, the research findings demonstrate that small predominantly classic lesions in AMD patients respond better to verteporfin therapy than larger lesions.

The recognition of prognostic factors is important so that patients who may benefit from verteporfin therapy can be identified and treated adequately.<sup>10,11</sup> In addition, it will be valuable to improve clinical effectiveness and cost utility of photodynamic therapy.<sup>12,13</sup>

#### Authors' affiliations

L Arias, O Pujol, J Berniell, M Rubio, G Roca, L Castillo, E Acebes, Department of Ophthalmology, Bellvitge University Hospital, L'Hospitalet de Llobregat, Barcelona, Spain

The authors have no financial or proprietary interest in any product mentioned in this article.

This paper was presented during the American Academy of Ophthalmology Annual Meeting held in Anaheim (California) in November 2003.

#### REFERENCES

- 1 **Treatment of Age-Related Macular Degeneration with Photodynamic Therapy (TAP) Study Group.** Photodynamic therapy of subfoveal choroidal neovascularization in age-related macular degeneration with verteporfin: one-year results of 2 randomized clinical trials—TAP report 1. *Arch Ophthalmol* 1999;**117**:1329–45.

- 2 **Treatment of Age-related Macular Degeneration with Photodynamic Therapy (TAP) Study Group.** Photodynamic therapy of subfoveal choroidal neovascularization in age-related macular degeneration with verteporfin. Two-year results of 2 randomized clinical trials—TAP Report 2. *Arch Ophthalmol* 2001;**119**:198–207.
- 3 **Verteporfin in Photodynamic Therapy (VIP) Study Group.** Verteporfin therapy of subfoveal choroidal neovascularization in age-related macular degeneration: 2-year results of a randomized clinical trial including lesions with occult with no classic choroidal neovascularization—VIP Report 2. *Am J Ophthalmol* 2001;**131**:541–60.
- 4 **Treatment of Age-Related Macular Degeneration with Photodynamic Therapy (TAP) Study Group.** Verteporfin therapy of subfoveal choroidal neovascularization in patients with age-related macular degeneration. Additional information regarding baseline lesion composition's impact on vision outcomes—TAP report No 3. *Arch Ophthalmol* 2002;**120**:1443–54.
- 5 **Verteporfin Roundtable 2000 and 2001 Participants.** Treatment of Age-Related Macular Degeneration With Photodynamic Therapy (TAP) Study Group Principal Investigators, and Verteporfin in Photodynamic Therapy (VIP) Study Group Principal Investigators. Guidelines for using verteporfin in photodynamic therapy to treat choroidal neovascularization due to age-related macular degeneration and other causes. *Retina* 2002;**22**:6–18.
- 6 **Treatment of Age-Related Macular Degeneration With Photodynamic Therapy (TAP) and Verteporfin in Photodynamic Therapy (VIP) Study Groups.** Photodynamic therapy of subfoveal choroidal neovascularization with verteporfin. Fluorescein Angiographic Guidelines for Evaluation and Treatment—TAP and VIP Report No. 2. *Arch Ophthalmol* 2003;**121**:1253–68.
- 7 **Treatment of Age-Related Macular Degeneration With Photodynamic Therapy (TAP) and Verteporfin in Photodynamic Therapy (VIP) Study Groups.** Verteporfin therapy of subfoveal choroidal neovascularization in age-related macular degeneration: meta-analysis of 2-year safety results in three randomized clinical trials: Treatment of Age-Related Macular Degeneration with Photodynamic Therapy and Verteporfin in Photodynamic Therapy Study Report No 4. *Retina* 2004;**24**:1–12.
- 8 **Borodoker N, Spaide RF, Maranan L, et al.** Verteporfin infusion-associated pain. *Am J Ophthalmol* 2002;**133**:211–14.
- 9 **Tornambe PE.** Using intravenous diphenhydramine to minimize back pain associated with photodynamic therapy with verteporfin. *Arch Ophthalmol* 2002;**120**:872.
- 10 **Axer-Siegel R, Ehrlich R, Yassur Y, et al.** Photodynamic therapy for age-related macular degeneration in a clinical setting: visual results and angiographic patterns. *Am J Ophthalmol* 2004;**137**:258–64.
- 11 **Mandal N, Chisholm IH.** Identifying the proportion of age related macular degeneration patients who would benefit from photodynamic therapy with verteporfin. *Br J Ophthalmol* 2002;**86**:118–19.
- 12 **Sharma S, Brown GC, Brown MM, et al.** The cost-effectiveness of photodynamic therapy for fellow eyes with subfoveal choroidal neovascularization secondary to age-related macular degeneration. *Ophthalmology* 2001;**108**:2051–9.
- 13 **Meads C, Salas C, Roberts T, et al.** Clinical effectiveness and cost-utility of photodynamic therapy for wet age-related macular degeneration: a systematic review and economic evaluation. *Health Technol Assess* 2003;**7**:1–108.



## Impact of lesion size on photodynamic therapy with verteporfin of predominantly classic lesions in age related macular degeneration

L Arias, O Pujol, J Berniell, et al.

*Br J Ophthalmol* 2005 89: 312-315  
doi: 10.1136/bjo.2004.050997

---

Updated information and services can be found at:  
<http://bjo.bmj.com/content/89/3/312.full.html>

- 
- References** *These include:*  
This article cites 13 articles, 6 of which can be accessed free at:  
<http://bjo.bmj.com/content/89/3/312.full.html#ref-list-1>
- Article cited in:  
<http://bjo.bmj.com/content/89/3/312.full.html#related-urls>
- Email alerting service** Receive free email alerts when new articles cite this article. Sign up in the box at the top right corner of the online article.

- 
- Topic Collections** Articles on similar topics can be found in the following collections
- [Retina](#) (1217 articles)
  - [Choroid](#) (435 articles)
  - [Neurology](#) (1042 articles)

---

### Notes

---

To request permissions go to:  
<http://group.bmj.com/group/rights-licensing/permissions>

To order reprints go to:  
<http://journals.bmj.com/cgi/reprintform>

To subscribe to BMJ go to:  
<http://group.bmj.com/subscribe/>