

PostScript

LETTER

Recurrence of Thiel-Behnke corneal dystrophy: an electron microscopic study

The hereditary Thiel-Behnke corneal dystrophy, first described in 1967,¹ is frequently confused with Reis-Bucklers dystrophy. Both conditions affect Bowman's layer and can be difficult to differentiate both clinically and histopathologically. Previously, electron microscopic studies of corneal dystrophies affecting Bowman's layer identified characteristic "curly fibres," but it was unclear whether these were diagnostic of Thiel-Behnke or Reis-Bucklers.² More recently, Kuchle *et al* have attempted to clarify the situation, identifying these corneal dystrophies as two separate disease entities, and proposing the less confusing nomenclature of corneal dystrophy of Bowman's layer (CDB) type I (geographic or "true" Reis-Bucklers dystrophy) and CDB type II (honeycomb or Thiel-Behnke dystrophy).³ In this report we present a case of Thiel-Behnke dystrophy diagnosed by electron microscopy after recurrence in the corneal graft. This case illustrates the diagnostic difficulties surrounding corneal dystrophies of Bowman's layer, and highlights the continuing importance of electron microscopy as a diagnostic tool.

Case report

Following diagnosis of a familial corneal dystrophy, our patient underwent a left penetrating keratoplasty in 1967 at another hospital, at the age of 34 years. Although the pathological report of this was not available to us, the dystrophy was labelled "lattice type." The following year her care was transferred to our hospital. At this time she was found to have a clear graft in the left eye with a visual acuity of 6/9, and multiple granular honeycomb-shaped corneal opacities at the level of Bowman's layer in the right eye with a visual acuity of 6/12. By 1981 her right visual acuity had deteriorated to 6/18 so she underwent right penetrating keratoplasty. The pathology report commented on subepithelial fibrosis and patchy destruction of Bowman's membrane, in keeping with Reis-Bucklers corneal dystrophy or possibly

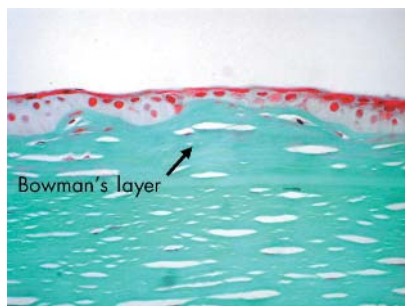


Figure 1 Corneal graft showing apparent subepithelial fibrosis (arrow). Masson's Trichrome, magnification $\times 400$.

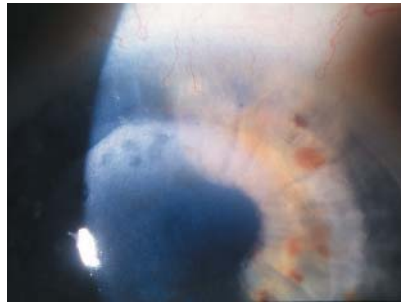


Figure 2 Slit lamp biomicroscopy showing recurrence of the "honeycomb" deposits in the corneal graft.

Salzmann's dystrophy (fig 1). Lattice, macular and granular dystrophies were excluded with appropriate stains.

Following a period of care at another hospital, she was re-referred to our hospital in 1999 with deteriorating visual acuity secondary to possible recurrence of the corneal dystrophy in both grafts. Best corrected visual acuities were 6/24 and 6/36 in the right and left eyes, respectively. Subepithelial corneal opacities were noted in the peripheral portions of both grafts (fig 2). She was also noted to have bilateral cataracts, so underwent right phacoemulsification in 2000. Postoperative recovery was uneventful, with visual acuity improving to 6/12. In 2002 complicated left cataract surgery led to graft decompensation requiring repeat grafting in 2003. Histopathology revealed apparent subepithelial fibrosis

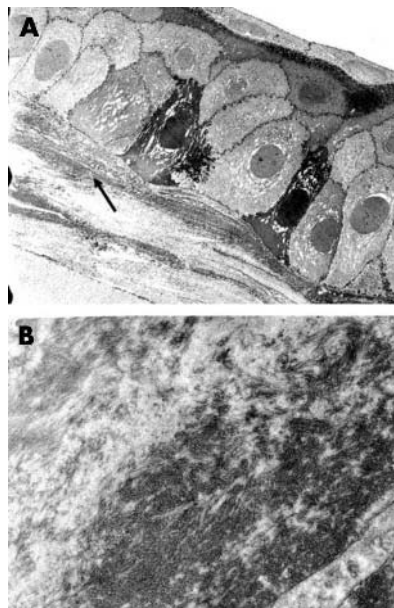


Figure 3 (A) Transmission electron microscopy showing the location of the "curly fibres" beneath the epithelium (arrow). Magnification $\times 4000$ (B) "Curly fibres" seen at higher magnification ($\times 12\,000$).

associated with patchy loss of Bowman's layer. The endothelium was found to be markedly attenuated. Review of the previous pathology section from 1981 showed the apparent subepithelial fibrosis to be similar in both samples. Electron microscopy of both samples revealed the presence of "curly fibres" beneath the basal epithelium (fig 3), leading to the diagnosis of Thiel-Behnke corneal dystrophy with recurrence in the graft.

Comment

Owing to confusion surrounding the nomenclature of corneal dystrophies of Bowman's layer, this patient was diagnosed as having Reis-Bucklers corneal dystrophy in 1981 following histological analysis of her right corneal button. However, the clinical picture is more in keeping with that described for Thiel-Behnke dystrophy with later, moderate visual loss and honeycomb-shaped opacities at the level of Bowman's layer. The geographical opacities seen in Reis-Bucklers dystrophy are associated with early, marked visual loss, therefore differentiation between these dystrophies is important for the patient's visual prognosis.³ The discovery of the characteristic curly fibres of Thiel-Behnke dystrophy on electron microscopy of both corneal buttons illustrates the importance of electron microscopy in the diagnosis of corneal dystrophies.

H C Gear, K Ramaesh

Tennent Institute of Ophthalmology, Gartnavel General Hospital, Glasgow, UK

F Roberts

University Department of Pathology, Western Infirmary, Glasgow, UK

Correspondence to: Dr Heather C Gear, Gartnavel General Hospital, Glasgow G11 6NT, UK; heathergear@hotmail.com

doi: 10.1136/bjo.2004.051029

Accepted for publication 11 August 2004

References

- 1 Thiel HJ, Behnke H. Ein bisher unbekannte, subepitheliale hereditäre Hornhautdystrophie. *Klin Monatsbl Augenheilkd* 1967;150:862-74.
- 2 Perry HD, Fine BS, Caldwell DR. Reis-Bucklers' dystrophy. A study of eight cases. *Arch Ophthalmol* 1979;97:664-70.
- 3 Kuchle M, Green WR, Volcker HE, *et al*. Reevaluation of corneal dystrophies of Bowman's layer and the anterior stroma (Reis-Bucklers and Thiel-Behnke types): a light and electron microscopic study of eight corneas and a review of the literature. *Cornea* 1995;14:333-54.

MAILBOX

Author! Author!

We thank the *BJO* for publishing our letter regarding appending authors' qualifications¹ and for inviting correspondence from its readership on the issue in the editorial "Who is Ivan Schwab?"²

The editors wisely remind us that medical authorities have suppressed important

findings by lesser known authors, using the notable example of Semmelweis. Even today, critical new information remains vulnerable to suppression by authorities, medical or otherwise. Perhaps the most memorable rejection was that of Novotny and Alvis, whose seminal work on fluorescein angiography was rejected by the *American Journal of Ophthalmology* in 1960.³

We agree with the editors that publication of an article should be based on its scientific merit, not on its authors' qualifications or eminence. We would emphasise that publication is an editorial prerogative based on advice from reviewers, who are a select group, rather than from a journal's readership. In our modern age, the editorial decision to publish an article in a Medline indexed journal equates to enduring worldwide dissemination. Therefore, we agree with the proposal that authors' names and qualifications should be masked from reviewers. We would go even further to suggest that this information, and the authors' institutional affiliations, should also be masked from the editorial board, until a preliminary decision is made regarding publication. This would ensure the primacy of the article's scientific content, making it more likely that first rate articles from unfamiliar and little known authors are published at the expense of second rate articles from eminent authors.

In contrast with the function of a reviewer, the task of the reader is, in our opinion, facilitated by a journal providing information about the authors, including their qualifications. We, as readers, seek information on the authors' educational background and professional experience (using their qualifications as a proxy), and also previous publications. We do this in order to understand their perspective, and to help us put their interpretations of results into context. This information is perhaps most important when the writing involves opinion and speculation, which includes the discussion of results. In any event, in the age of internet search engines, the qualifications and background of many authors are not hidden.

On another point, we do not begrudge the trolley boy's scholarly aspirations. We agree with the editors that he may be well positioned to write about his first hand observations in the hospital. As readers, we would prefer to know when it was the trolley boy's work, in order to understand his perspective and the context of his writing. We may have interpreted the same article differently had it been written by the professor of infectious diseases, the senior lecturer in surgery, or the newly graduated trainee in dermatology.

Finally, we commend Ivan Schwab for his fascinating *BJO* articles. We warmly welcome him to our country, and we hope he enjoys studying our fauna.

D Papalkar, I C Francis

Prince of Wales Hospital, Randwick, Sydney 2031, Australia

Correspondence to: Dr Ian C Francis, Suite 12, Chatswood Grove, 12-14 Malvern Avenue, Chatswood 2067, Australia; if@student.unsw.edu.au

doi: 10.1136/bjo.2004.058982

Accepted 29 September 2004

References

- 1 **Papalkar D**, Francis IC. Authors' qualifications. *Br J Ophthalmol* 2004;**88**:1227-8.
- 2 **Hoyt CS**, Dick A, Bhisitkul B. Who is Ivan Schwab? *Br J Ophthalmol* 2004;**88**:1106.
- 3 **Novotny HR**, Alvis DL. A method of photographing fluorescence in circulating blood in the human retina. *Circulation* 1961;**24**:82-6.

NOTICES

Worldwide clinical trials for new technique for early detection of eye disease

A unique new non-invasive technique for high resolution optical imaging of the eye is

receiving global acclaim. By combining two high-resolution imaging technologies, the new technique provides doctors with 3-D images of the retina, macula and the optic nerve.

For more information, contact the Media Office on 01227 823581/823100 or email MediaOffice@kent.ac.uk News releases can also be found at: <http://www.kent.ac.uk/news>

Trachoma control

The latest issue of *Community Eye Health* (No 52) discusses new developments in the control of trachoma. For further information please contact: Journal of Community Eye Health, International Resource Centre, International Centre for Eye Health, Department of Infectious and Tropical Diseases, London School of Hygiene and Tropical Medicine, Keppel Street, London WC1E 7HT, UK (tel: +44 (0)20 7612 7964; email: Anita.Shah@lshtm.ac.uk; online edition: www.jceh.co.uk). Annual subscription (4 issues) UK £28/US\$45. Free to developing country applicants.

British Oculoplastic Surgery Society

Call for papers for the 5th annual meeting of the BOPSS to be held on 15 and 16 May 2005 at The Belfry, Birmingham. The abstract submission deadline is 4 February 2005, and abstracts can be submitted online at www.bopss.org.

World Ophthalmology Congress 2006 – Brazil

The World Ophthalmology Congress (which is replacing the International Congress of Ophthalmology) is meeting in February 2006 in Brazil.

Further information on the congress and committees, scientific program, and coordinators of different areas is available at the congress website www.ophthalmology2006.com.br



Author! Author!

D Papalkar and I C Francis

Br J Ophthalmol 2005 89: 518-519
doi: 10.1136/bjo.2004.058982

Updated information and services can be found at:
<http://bjo.bmj.com/content/89/4/518.2.full.html>

These include:

References

This article cites 3 articles, 3 of which can be accessed free at:
<http://bjo.bmj.com/content/89/4/518.2.full.html#ref-list-1>

Email alerting service

Receive free email alerts when new articles cite this article. Sign up in the box at the top right corner of the online article.

Notes

To request permissions go to:
<http://group.bmj.com/group/rights-licensing/permissions>

To order reprints go to:
<http://journals.bmj.com/cgi/reprintform>

To subscribe to BMJ go to:
<http://group.bmj.com/subscribe/>