

Threshold Amsler grid

# Hydroxychloroquine screening

A G Lee

## Who needs it, when, how, and why?

Almony *et al* report in this issue of the *BJO* (p 569) the use of a threshold Amsler grid (TAG) as a screening tool for asymptomatic patients taking hydroxychloroquine (HCQ). They studied 56 patients taking HCQ and 12 controls. Patients were tested with a “white on black” Amsler grid (AG), a “red on black” AG (RAG), and the threshold AG (TAG). TAG uses cross polarising filters to reduce the perceived luminance of the grid. Scotomas were detected in two patients (3.6%) with the standard AG and five patients (8.9%) with RAG, but 25 (45%) patients with TAG. The TAG testing detected the two positive AG screens and the five positive RAG screens. The authors concluded that TAG has increased sensitivity to the detection of subtle scotomas in patients taking HCQ. Unfortunately, because there is no “gold standard” for HCQ retinopathy in asymptomatic or presymptomatic patients without visible retinopathy the specificity of the TAG results is unknown.

If the scotomas seen on TAG were also detected reproducibly in the same location using another central field test (for example, Humphrey 10-2) this would provide evidence for the specificity of the TAG findings. I would encourage the authors to continue to follow their cohort of HCQ treated patients and perhaps even test the patients with the abnormal TAG findings again with an automated (Humphrey) 10-2 strategy or even a multifocal electroretinogram (MERG). Although the sensitivity and specificity of MERG in HCQ toxicity continues to be explored it may be that objective

electrophysiological testing might be superior to subjective tests of visual function like the AG.<sup>1</sup>

One of the patients in this study (case 63) was only taking HCQ for 1 month and yet had large bilateral central scotomas. It is unlikely that this represented HCQ retinopathy and this patient did not have a baseline eye examination. This case demonstrates the limitations of not specifically excluding from the study any patients who did not have complete ophthalmological examinations before starting HCQ. It may be that false positive screens may be a significant limiting factor for the TAG. Pluennke and Blomquist reported that 6–11% of HCQ and control patients tested with RAG had a false positive result.<sup>2</sup> The false positive rate for the TAG is not known from the study by Almony *et al*.

Although there have been many guidelines in the United States, Canada, and the United Kingdom for screening examinations for patients taking HCQ, the cost effectiveness and diagnostic yield of these recommendations have not been evaluated in a rigorous and critical evidence based manner.<sup>3-5</sup> The risk of HCQ toxicity is exceedingly rare for low risk patients and over one million patients up to 2002 have been treated with HCQ with only 20 cases of toxicity at the “subthreshold” dose of <6.5 mg/kg/day. All of these 20 cases had taken the drug for more than 5 years. In addition, there still remains controversy as to the timing and content of screening examinations for these patients. The American Academy of Ophthalmology (AAO) has provided a screening strategy

composed of three parts: (1) informed consent obtained by the prescribing primary physician with explicit written documentation in the medical record; (2) detection and minimisation of toxicity rather than prevention itself; (3) definition of high and low risk patients (see table 1); and (4) stratification of screening based upon risk factors. If a baseline eye examination is normal and the patient is taking a low dose (<6.5 mg/kg/day) of HCQ then the recommended screening interval follows the AAO screening recommendations for regular eye examinations in the general population. Annual screening was recommended for patients with higher or unknown dose or duration (>5 years) of HCQ therapy.<sup>3</sup> Almony *et al* recorded several of the risk factors proposed by the AAO (see table 1) for HCQ retinopathy including weight adjusted doses, duration of HCQ therapy, and the age of the patients. They did not however include data on renal or hepatic insufficiency and no patients had documented other macular pathology.

The specific recommendation of the American Academy of Ophthalmology is for a baseline examination (listed in table 2) for all patients starting HCQ treatment. Unfortunately, there is no “gold standard” for identification of toxicity before the development of the ophthalmoscopic changes (that is, pigmentary changes and “bull’s eye maculopathy”). Despite the recommendation of the AAO, it is not clear that a baseline examination is cost effective given the large numbers of patients on HCQ and the relatively low incidence of retinopathy. In the United Kingdom, the Royal College of Ophthalmologists, the British Association of Dermatologists, and the British Society for Rheumatology recommend baseline assessment of renal and liver function, inquiry about visual symptoms, and recording

**Table 1** Criteria of low and higher risk for developing retinopathy (modified from Marmor *et al*<sup>6</sup>)

Criteria	Low risk	Higher risk
Dosage	<6.5 mg/kg	>6.5 mg/kg
Duration	<5 years	>5 years
Habitus	Lean or average fat	High fat level
Renal/liver disease	Absent	Present
Concomitant retinal disease	Absent	Present
Age	<60 years	>60 years

**Table 2** Baseline examination for all patients treated with hydroxychloroquine recommended by the American Academy of Ophthalmology (AAO)

- Complete ophthalmological exam including dilated fundus exam
- Baseline visual field testing (eg, Amsler or Humphrey 10-2)
- Optional colour vision testing (eg, screen for pretreatment colour blindness)
- Optional fundus photography (eg, if pretreatment macular pigmentary changes)
- Optional specialised tests (eg, fluorescein angiography or multifocal electroretinogram)

of near visual acuity with inquiry about visual symptoms at each visit and measurement of visual acuity annually. Buckley *et al* in the April 2004 guidelines from the United Kingdom for screening suggest that a baseline eye examination and regular ophthalmological screening may not be required in patients taking low (<6.5 mg/kg) doses of HCQ.<sup>5</sup> These guidelines do recommend referral to an ophthalmologist for patients with ocular disease at baseline or for those who develop visual symptoms on treatment. Interestingly the Amsler grid is not included in the annual evaluation recommended for the rheumatology and dermatology clinics but is included in the assessment by ophthalmology.<sup>5</sup> Publication of these recommendations and national guidelines may not ensure compliance however. Samanta *et al* reported wide variation among consultant rheumatologists in the United Kingdom and nearly half of surveyed respondents did not assess either baseline visual symptoms or visual acuity.<sup>6</sup>

In summary, despite the limitations of the study by Almony *et al*, TAG may be a more sensitive means for detecting

subtle scotomas in patients taking HCQ. The specificity of the TAG however remains to be defined. High risk and low risk features of the individual patient should determine the timing of screening for HCQ retinopathy. Appropriate informed consent, adequate documentation in the medical record, and an appropriate baseline assessment by the prescribing physician are important for medicolegal as well as medical reasons. Because the incidence of HCQ toxicity is extremely low at doses <6.5 mg/kg in asymptomatic and otherwise visually healthy patients, the need and cost effectiveness of baseline and more frequent screening examinations by an ophthalmologist remains debatable. The rationale for examining a patient within the first year of HCQ treatment is to establish a baseline and to document any pretreatment eye disease. The TAG however may be a more sensitive tool for detecting patients in the non-ophthalmology clinic setting who may need a full ophthalmology examination. More frequent screening should be performed in patients taking HCQ with high risk characteristics.

*Br J Ophthalmol* 2005;**89**:521–522.  
doi: 10.1136/bjo.2004.061473

Correspondence to: Dr A G Lee, Departments of Ophthalmology, Neurology, and Neurosurgery, The University of Iowa Hospitals and Clinics, Iowa City, IA 52242, USA; [leea@horus.ophth.uiowa.edu](mailto:leea@horus.ophth.uiowa.edu)

## REFERENCES

- 1 Maturi RK, Minzhou Y, Weleber RG. Multifocal electroretinographic evaluation of long-term hydroxychloroquine users. *Arch Ophthalmol* 2004;**122**:973–81.
- 2 Plueneke AC, Blomquist PH. Utility of red amsler grid screening in a rheumatology clinic. *J Rheumatol* 2004;**31**:1754–5.
- 3 Marmor MF, Carr RE, Easterbrook M, *et al*. Recommendation on screening for chloroquine and hydroxychloroquine retinopathy. A report by the American Academy of Ophthalmology. *Ophthalmology* 2002;**109**:1377–82.
- 4 Easterbrook M. Screening for antimalarial toxicity: current concepts. *Can J Ophthalmol* 2002;**37**:325–8.
- 5 Buckley R, Graham E, Jones S, *et al*. Ocular toxicity and hydroxychloroquine: guidelines for screening 2004. ([www.rcophth.ac.uk/scientific/docs/oculartoxicity2004.pdf](http://www.rcophth.ac.uk/scientific/docs/oculartoxicity2004.pdf), last accessed on 4 November 2004).
- 6 Samanta A, Goh L, Bawendi A. Are evidence-based guidelines being followed for the monitoring of ocular toxicity of hydroxychloroquine? A nationwide survey of practice amongst consultant rheumatologists and implications for clinical governance. *Rheumatology (Oxford)* 2004;**43**:346–8.

## Vision restoration therapy

# Vision restoration therapy

B A Sabel, S Kenkel, E Kasten

## Expanding our view

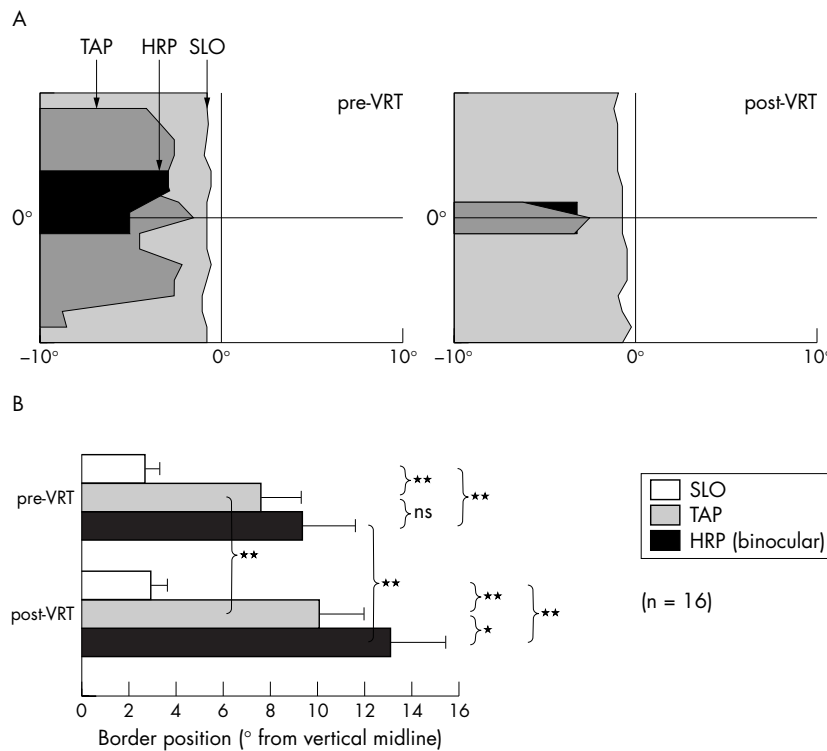
We have followed with interest the discussion ignited by the paper by Reinhard *et al*<sup>1</sup> by way of editorial comments from Horton<sup>2</sup> and Plant.<sup>3</sup> As co-authors of the paper by Reinhard *et al*<sup>1</sup> and collaborators on that study, we have no objections to the data as presented. However, Horton's interpretation that these data indicate that "no therapeutic intervention ... can correct effectively the underlying visual field deficit" after post-chiasmatic injury is not supported by current scientific evidence. On the contrary, a comprehensive and critical review of the literature reveals that there is a sound scientific basis for recommending vision restoration therapy (VRT) for some patients with hemianopia.

The Reinhard study<sup>1</sup> used scanning laser ophthalmoscopy (SLO) to evaluate visual fields before and after a 6 month course of VRT and found no change in the size of the blind field detected by

this methodology. An important point well taken by Horton is that rather than relying on the VRT computer based tests alone, it would be "more compelling if visual field improvements could be demonstrated with any standard clinical perimeter." Although not reported in the Reinhard article, the same patients were also tested by two other perimetric methods: the Tübingen automated perimeter (TAP) and high resolution perimetry (HRP, which is a campimetric visual field test).<sup>4</sup> We acknowledge that Horton did not have access to this important information which was in press at the time. We believe that not considering these other perimetric data could lead to incorrect conclusions. Even before VRT began, the SLO border was already located significantly closer to the vertical midline than the absolute TAP and HRP borders (fig 1). After VRT, the SLO border was unchanged, but the absolute TAP and HRP borders had

significantly shifted, confirming improvement on these measures.<sup>4</sup> Similar enlargement of the visual field after therapy has been demonstrated on "standard clinical perimetry" by various investigators and laboratories.<sup>5–9</sup>

This apparent discrepancy between the conventional perimetric data and the SLO findings, both at baseline and after therapy, probably reflects the comparatively greater task difficulty of the SLO. It is well known that perimetric performance is task dependent, and the size of the visual field depends critically on stimulus characteristics. In the joint study of the Tübingen-Magdeburg groups<sup>1–4</sup> a single near threshold (TAP) or superthreshold bright dot (HRP) was presented on a dark or grey background and the patients had to respond to single stimuli by pressing a button. Contrast these techniques with SLO in which three black dots (a reverse stimulus) were presented on a bright red background which perceptually flickers because it is created by parallel laser lines (the "McKay effect", see Sabel *et al*<sup>1</sup>). Furthermore, patients had to verbally (that is, consciously) report what they were seeing while the experimenter interpreted their verbal reports. Simultaneous stimulus discrimination and detection of negative stimuli on a bright background are probably tasks beyond the abilities of a damaged visual



**Figure 1** This graph (adapted from Sabel *et al*<sup>4</sup>) displays the visual field border position in the right eye as assessed by the three perimetric tests. (A) The results of patient CH where grey areas represent the area of the defect. A mismatch in perimetric fields was noted even before therapy. After VRT, the HRP and TAP border shifted away from the vertical meridian whereas the SLO border remained roughly in the same position, exaggerating the border mismatch. (B) Shows the absolute visual field border for SLO, TAP, and HRP in the central 10° region in degrees of visual angle from the 0° vertical meridian before and after VRT (mean (SEM)). Whereas the SLO border was almost identical pre-VRT compared with post-VRT, the HRP and TAP borders were not only significantly different before VRT (mismatch), but also both shifted significantly after VRT, producing a visual field enlargement.<sup>4</sup>

system. It makes a dramatic difference what kind of psychophysical task is being used during perimetric testing and the results have to be interpreted in this context. Plant himself makes a very insightful comment when he says that “it remains possible that improvements may have been in the nature of relative defects which would have not been detected by the method employed in this study to detect absolute defects.”<sup>3</sup> This is indeed confirmed by the data analysis of the SLO study patients<sup>4</sup>: when “relative defects” in TAP and HRP were calculated, the “relative” border was found to be roughly identical to the SLO border. The SLO method appears to be insensitive to relative defects describing areas with residual function as being absolutely “blind.”

Both commentators<sup>2,3</sup> erroneously assume that just because the SLO study showed no visual field expansion, eye movement artefacts must have caused the VRT effects on other forms of perimetry. However, the task difficulty and the superior fixation control of the SLO are independent variables. The SLO study leaves unanswered the question if

or to what extent eye movements contribute to the VRT effects. Fortunately, there are several other parameters measured in the same patients which help clarify this issue. First of all, most of the patients showed excellent fixation on the SLO, even after VRT, and none of the patients showed stable eccentric fixation on SLO.<sup>1</sup> Secondly, both TAP fixation performance and HRP fixation performance were unchanged after VRT, and both used standard, clinically verified fixation control measures.<sup>4</sup> Additionally, Trauzettel-Klosinski and Reinhard,<sup>10</sup> two of the authors on the study in question, have previously stated that lack of a shift in the blind spot position is a good indicator that fixation is not eccentric. In 12 out of the 16 patients in the SLO study, the blind spot position remained identical after VRT. Among the only four patients who showed a small shift of the blind spot on SLO, none profited from VRT on the other forms of perimetry either. Finally, if eye movements were the cause of visual field expansion, one would expect the entire visual field border to shift. In most patients this is not what is seen. A dramatic example of this is the recently

reported selective border shift only within the region of an attention cue.<sup>8</sup> Or take the patient shown in figure 1, in which the visual field defect shrank by shifting of the horizontal border without affecting the vertical border, and the deficit next to the fixation spot was unchanged. If eye movement artefacts had occurred, the reverse would be expected: a shift of the vertical border and no change in the horizontal border. Such border dynamics are incompatible with eye movement artefacts.

Horton is concerned that VRT improvements may simply be a result of placebo effects. However, the study by Kasten *et al*<sup>6</sup> described two independent clinical trials in which the placebo effect was controlled for by a randomised, placebo controlled trial and showed that the placebo treatment had no effect in the post-chiasmatic group and only a small effect in the optic nerve group. In this study<sup>6</sup> and in others,<sup>5,7</sup> patients also reported subjective benefits after VRT, including improved visual function in reading, navigation, and confidence. We agree it is essential to further investigate VRT effects on standardised functional measures of visual performance on everyday life tasks in addition to just perimetry.

There is increasing evidence supported by controlled clinical trials and functional neuroimaging that neuroplasticity is active in many regions of the brain. Training paradigms are now standard in the field of rehabilitation medicine. They are not limited to locomotion therapy, but well established in other functional domains as well (for example, cognitive therapy, memory therapy, speech therapy, auditory therapy, etc). There is no reason why the visual system should be the great exception from all other functional systems of the brain. After all, normal adult subjects are capable of perceptual learning,<sup>11</sup> and there is an entire body of evidence on activity dependent use and neuroplasticity, such as studies on adult receptive field expansions following retinal or brain lesions.<sup>12-15</sup> We also should remember that the visual system is not purely “sensory.” It utilises many cognitive mechanisms as seen, for example, in the phenomenon of physiological blind spot “filling in” and in the many other mechanisms that contribute to visual perception such as lateral interactions and contour integration.<sup>11</sup>

The precise mechanisms of visual neuroplasticity in the human are not yet defined. Horton believes that in patients with complete hemianopia there is “no fringe of injured but salvageable tissue.” This assumption may be true in some patients, but most patients actually have incomplete hemianopia where

residual neurons survive within or near the damaged zones ("relative defects"). Even patients with "complete" V1 damage have some preserved visual functions. For example, patients can show non-conscious visual responses (blind sight) which are mediated either by surviving primary cortical afferents<sup>16</sup> and islands of residual vision<sup>17</sup> or by undamaged projections via the colliculus and pulvinar.<sup>18, 19</sup> This latter pathway has most recently been discovered to relay attention relevant information to the eye movement control system<sup>20</sup> and attentional networks are now known to contribute to VRT induced recovery.<sup>8</sup> There is yet another pathway bypassing V1 altogether, as elegantly described by Hortons group<sup>21</sup>: a direct projection from lateral geniculate neurons to the motion sensitive area MT (V5). Thus, there are apparently multiple pathways whereby visual information can reach higher cortical regions without involving V1. Whether or not such pathways have a role in VRT induced visual field enlargements is currently not known, but the search for neurobiological mechanisms of vision restoration deserves further study.

Sensational support of or enthusiastic opposition to a viable technique can only be justified after a meticulous analysis of the *complete* data in order to enhance scientific discourse. It is true that VRT does not assist all patients. Predictors of recovery have not been completely defined, except that the size of the relative defect tends to correlate with recovery. VRT has now been applied in over 700 patients with confirmation of its effectiveness from several independent studies and laboratories. The FDA has cleared VRT to be offered in the United States and has done so in recognition of the results

from the Tübingen-Magdeburg trial. Several clinical centres throughout the United States are now beginning to observe similar improvements with their first patients, confirming the approach to be helpful to patients. Clearly, the relation of objective and subjective visual function after VRT needs further clarification and the role of eye movement compensation in individual hemianopic patients is of interest. However, many hemianopic patients, especially those with partial deficits, benefit from VRT. The evidence supports the conclusion that some visual improvement is possible.

*Br J Ophthalmol* 2005;**89**:522–524.  
doi: 10.1136/bjo.2005.068163

#### Authors' affiliations

**B A Sabel, S Kenkel, E Kasten**, Institute of Medical Psychology, Otto-von-Guericke University of Magdeburg, Magdeburg, Germany

Correspondence to: Bernhard A Sabel, PhD, Institute of Medical Psychology, Otto-von-Guericke University of Magdeburg, Leipzigerstrasse. 44, 39120 Magdeburg, Germany; [bernhard.sabel@medizin.uni-magdeburg.de](mailto:bernhard.sabel@medizin.uni-magdeburg.de)

#### REFERENCES

- 1 Reinhard J, Schreiber A, Schiefer U, *et al*. Does visual restitution training change absolute homonymous visual field defect? A fundus controlled study. *Br J Ophthalmol* 2005;**89**:30–5.
- 2 Horton JC. Disappointing results from NovaVision's visual restoration therapy. *Br J Ophthalmol* 2005;**89**:1–2.
- 3 Plant GT. A workout for hemianopia. *Br J Ophthalmol* 2005;**89**:2.
- 4 Sabel BA, Kenkel S, Kasten E. Vision restoration therapy (VRT) efficacy as assessed by comparative perimetric analysis and subjective questionnaires. *Restor Neural Neurosci* 2004;**22**:399–420.
- 5 Julkunen L, Tenovo O, Jääskeläinen S, *et al*. Rehabilitation of chronic post-stroke visual field

- defect with computer-assisted training. *Restor Neural Neurosci* 2003;**21**:19–28.
- 6 Kasten E, Wüst S, Behrens-Baumann W, *et al*. Computer-based training for the treatment of partial blindness. *Nat Med* 1998;**4**:1083–7.
- 7 Mueller I, Poggel DA, Kenkel S, *et al*. Vision restoration therapy (VRT) after brain damage: subjective improvements of activities of daily life and their relationship to visual field enlargements. *Visual Impairm Res* 2003;**5**:157–78.
- 8 Poggel DA, Kasten E, Sabel BA. Attentional cueing improves vision restoration therapy in patients with visual field loss. *Neurology* 2004;**63**:2069–76.
- 9 Zihl J, von Cramon D. Visual field recovery from scotoma in patients with postgeniculate damage. A review of 55 cases. *Brain* 1985;**108**:335–65.
- 10 Trauzettel-Klosinski S, Reinhard J. The vertical field border in hemianopia and its significance for fixation and reading. *Invest Ophthalmol Vis Sci* 1998;**39**:2177–86.
- 11 Gilbert CD, Sigman M, Crist RE. The neural basis of perceptual learning. *Neuron* 2001;**31**:681–97.
- 12 Eysel T, Gonzalez-Aguilar F, Mayer U. A functional sign of reorganization in the visual system of adult cats: lateral geniculate neurons with displaced receptive fields after lesions of the nasal retina. *Brain Res* 1980;**181**:285–300.
- 13 Chino YM, Smith EG 3rd, Kaas JH, *et al*. Receptive-field properties of deafferented visual cortical neurons after topographic map reorganization in adult cats. *J Neurosci* 1995;**15**:2417–33.
- 14 Gilbert CD, Wiesel TN. Receptive field dynamics in adult primary visual cortex. *Nature* 1992;**356**:150–2.
- 15 Kaas JH, Krubitzer LA, Chino YM, *et al*. Reorganization of retinotopic cortical maps in adult mammals after lesions of the retina. *Science* 1990;**248**:229–31.
- 16 Wüst S, Kasten E, Sabel BA. Blindsight after optic nerve injury indicates functionality of spared fibers. *J Cogn Neurosci* 2002;**14**:243–53.
- 17 Fendrich R, Wessinger CM, Gazzaniga MS. Residual vision in a scotoma: implications for blindsight. *Science* 1992;**258**:27.
- 18 Pöppel E, Held R, Frost D. Residual visual functions after brain wounds involving the central visual pathways in man. *Nature* 1973;**243**:295–6.
- 19 Weiskrantz L, Warrington EK, Sanders MD, *et al*. Visual capacity in the hemianopic field following a restricted occipital ablation. *Brain* 1974;**97**:709–28.
- 20 Cavanaugh J, Wurtz RH. Subcortical modulation of attention counters change blindness. *J Neurosci* 2004;**24**:11236–43.
- 21 Sincich LC, Park KF, Wohlgenuth MJ, *et al*. Bypassing V1: a direct geniculate input to area MT. *Nat Neurosci* 2004;**7**:1123–8.



## Vision restoration therapy

B A Sabel, S Kenkel and E Kasten

*Br J Ophthalmol* 2005 89: 522-524  
doi: 10.1136/bjo.2005.068163

---

Updated information and services can be found at:  
<http://bjo.bmj.com/content/89/5/522.full.html>

---

*These include:*

### References

This article cites 21 articles, 11 of which can be accessed free at:  
<http://bjo.bmj.com/content/89/5/522.full.html#ref-list-1>

Article cited in:  
<http://bjo.bmj.com/content/89/5/522.full.html#related-urls>

### Email alerting service

Receive free email alerts when new articles cite this article. Sign up in the box at the top right corner of the online article.

---

### Notes

---

To request permissions go to:  
<http://group.bmj.com/group/rights-licensing/permissions>

To order reprints go to:  
<http://journals.bmj.com/cgi/reprintform>

To subscribe to BMJ go to:  
<http://group.bmj.com/subscribe/>