

SCIENTIFIC REPORT

Refractive lens exchange in high myopia: long term follow up

N Horgan, P I Condon, S Beatty

Br J Ophthalmol 2005;89:670–672. doi: 10.1136/bjo.2004.052720

Aim: To establish long term outcomes and incidence of complications following refractive lens exchange (RLE) for the correction of high myopia.

Methods: Operative and postoperative records of 62 cases of small incision phacoemulsification RLE performed in 37 patients over an 11 year period, by a single surgeon, were reviewed. In addition, patients were recalled for a follow up examination, which included dilated retinal examination with scleral indentation.

Results: Two cases (3.2%) of retinal detachment occurred at intervals of 2 months and 5 months following uncomplicated RLE procedures. A posterior chamber intraocular lens was inserted in 46 eyes (74%). YAG laser posterior capsulotomy was performed in 38 of 62 eyes (61%) and did not represent a risk for retinal detachment.

Conclusion: Refractive lens exchange results in rapid and predictable improvement in unaided vision in patients with high myopia. However, the risks of sight threatening complications inherent in any intraocular procedure underlie the need for appropriate patient selection.

The aim of this follow up study was to establish the long term visual outcomes and incidence of complications following refractive lens exchange (RLE) performed for the correction of high myopia.

PATIENTS AND METHODS

Patients who underwent RLE between January 1990 and December 2001 were identified from the operative log books of a single surgeon (PIC), and were invited to attend a special clinic set up for the purpose of this study.

Refractive lens exchange had been performed in preference to corneal refractive surgery for the correction of myopia in patients who (a) had peripheral lens opacities despite a clear central crystalline lens, and/or (b) where the degree of myopia exceeded that which could safely be corrected by laser in situ keratomileusis (LASIK) or photorefractive keratectomy (PRK). Many of the patient group were already presbyopic, and therefore loss of accommodation was not a concern in these cases.

All surgical procedures were performed by one surgeon (PIC). Briefly, the surgical technique comprised a limbal 3.2 mm incision, continuous curvilinear capsulorhexis of 5.5–6.0 mm, and lens extraction by low powered phacoemulsification. In the majority of cases a PMMA intraocular lens (IOL) was inserted “in the bag” after widening the incision to 6.5 mm. The wound was closed with two or three 10-0 nylon interrupted sutures, which were removed in the postoperative period.

RESULTS

Fifty five patients who had undergone RLE (93 eyes) were identified, of whom 37 agreed to attend the study clinic.

Twenty five volunteers had undergone sequential bilateral clear lens extraction (CLE), and therefore 62 cases of RLE were reviewed (66.7% of identified cases).

The male:female ratio was 10:27, and the mean age (SD) was 45.3 (9.0) years.

Preoperative axial length measurements were available in 43 cases, and ranged from 25.25 mm to 33.38 mm (mean 29.3 (2.3) mm). Preoperative refractive error (spherical equivalent) ranged from –7.00 dioptres to –22.75 dioptres (mean –13.7 (4.3) D), and postoperatively the mean refractive error was –1.09 (1.34) dioptres, with a range of +2.00 to –5.375 DS.

Best corrected Snellen visual acuity was 6/12 or better in 48 eyes before surgery. Six eyes were amblyopic, and myopic macular degenerative changes (MMD) were seen in seven study eyes. Of note, MMD and amblyopia were not co-existent preoperatively in any eye.

Preoperatively, posterior vitreous detachment was documented as present in five eyes, and absent in four eyes, whereas there was no comment relating to the state of the vitreous in the remaining 53 cases. Peripheral retinal degenerative changes were seen in six eyes (9.6%) before surgery, and these included three cases of lattice degeneration, two cases of pavingstone degeneration, and an operculated retinal hole was present in one eye. Of these, prophylactic laser treatment was performed in three eyes. Of note, however, two other eyes had previously undergone prophylactic laser therapy, and one eye had undergone successful retinal detachment surgery with an external procedure. Intraoperatively, a posterior capsule tear occurred in two of the 62 eyes (3.2%), and the IOL was implanted in the capsular bag in both cases. No other intraoperative complications were recorded.

A posterior chamber IOL was implanted in 46 of the 62 study eyes (74.2%). No IOL was inserted in the remaining 16 eyes and these were, therefore, rendered aphakic. These cases represent those performed earliest in the series, before the ready availability of low powered, plano or minus powered IOLs. Standard practice at that time was to leave the eye aphakic if target postoperative refraction would be achieved by an IOL of lower power than available from IOL manufacturers.

Early postoperative and long term follow up unaided visual acuities (UVA) are shown in figure 1.

The interval from RLE surgery to review for the purpose of this study ranged from 9 months to 10 years 8 months (mean 63.7 (35.7) months). Average age at follow up was 50.3 (8.3) years.

Myopic macular degeneration had developed in a further 12 eyes, resulting in a total of 19 eyes with visually

Abbreviations: CLE, clear lens extraction; IOL, intraocular lens; LASIK, laser in situ keratomileusis; MMD, myopic macular degenerative changes; PRK, photorefractive keratectomy; RLE, refractive lens exchange; UVA, unaided visual acuities

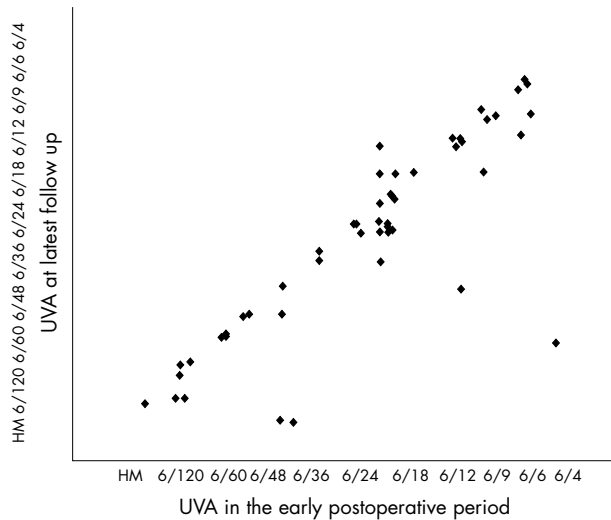


Figure 1 Comparison of unaided visual acuity (UVA) in the early postoperative period and at long term follow up. In order to ensure graphical representation of all data points of categorical visual acuity data, each level of Snellen visual acuity was ascribed an integer score and random numbers <0.5 (generated by Excel) were added to these integers.

consequential macular changes evident at final follow up (three of these eyes were amblyopic). The posterior vitreous was detached in 54 eyes (87%), attached in seven eyes (11.3%), and one eye had undergone vitrectomy.

YAG laser posterior capsulotomy had been performed in 38 of 62 eyes (61.3%), at intervals ranging from 6 months to 78 months following RLE.

Peripheral retinal degenerative changes were seen in 30 eyes (48.4%), paving stone peripheral degeneration in 13 eyes (20.9%), lattice degeneration in 14 eyes (22.6%), and combined paving stone and lattice degeneration in three eyes (4.8%).

Two cases of rhegmatogenous retinal detachment occurred in the postoperative period. One case occurred 2 months following uncomplicated RLE, with “in the bag” IOL insertion, in an amblyopic eye with a refractive error of -8.50 dioptres and peripheral paving stone degeneration. In the other case, the retina detached 5 months after uneventful RLE, with “in the bag” IOL placement, for correction of -10.25 dioptres of myopia in an eye of axial length 27.80 mm. Interestingly, prophylactic laser to areas of lattice degeneration had been performed in this eye before surgery. Of note, YAG capsulotomy had not been performed in either

of the eyes that had a retinal detachment. None of the 16 aphakic eyes developed a retinal break or detachment.

DISCUSSION

This study provides follow up data on 62 cases of RLE performed over a 10 year period by a single surgeon. In order to ensure the quality of our findings, we report only those patients who returned for a thorough ophthalmic examination, with particular attention to retinal and vitreous findings.

Previous studies have reported incidences of retinal detachment following RLE ranging between 0% and 8.1% (table 1), comparable with the 3.2% incidence in our study. Interestingly, both cases in this series occurred within 6 months of uncomplicated RLE with “in the bag” IOL insertion, and neither eye had undergone YAG capsulotomy. The published series of RLE have insufficient power to draw firm conclusions regarding the benefits of prophylactic retinal laser in eyes scheduled for RLE, or the putative additional risk following YAG capsulotomy in these eyes. There is a consensus, however, that laser capsulotomy in highly myopic eyes increases the incidence of posterior vitreous detachment, thereby potentially precipitating a retinal detachment.³ Interestingly, in this patient series, the rate of YAG capsulotomy was 61% over the follow up period. Although high by current standards, it should be remembered that many of the cases included underwent RLE with IOL insertion before the availability of square edged IOLs and were of younger age than the average phacoemulsification patient.

Estimates of retinal detachment risk in the unoperated highly myopic population vary from 0.4% to 0.68% per person year.^{9 10} In this group of 37 patients over a mean follow up of 64 months, this would translate into an expected occurrence of between 0.79 and 1.34 cases of retinal detachment in this time interval. The observed occurrence was of two retinal detachment cases, however.

Refractive lens exchange is an effective form of refractive surgery, which may be considered in patients with high myopia in whom excimer laser is inappropriate. For example, older patients in whom loss of accommodation is not a concern, or in whom early peripheral lens opacities are present, are often good candidates for RLE. This procedure employs phacoemulsification techniques familiar to the cataract surgeon, and recent developments, including smaller incision sizes, foldable IOLs, and improved intraoperative anterior chamber stability, are leading to increasingly refined surgery with less disturbance to the anatomical and physiological homeostasis within the eye. Furthermore, the predictability of target postoperative refraction continues to improve, with laser interferometry axial length technology,

Table 1 Published incidences of retinal detachment following clear lens extraction

Author	Prospective/retrospective	No of cases	Average follow up (months)	Range of follow up	Incidence of retinal detachment
Colin ¹	Prospective	52	12	NA	0%
Colin ²	Prospective	52	48	NA	1.9%
Colin ³	Prospective	52	84	NA	8.1%
Barraquer ⁴	Retrospective	165	31	3 months minimum	7.3%
Gris ⁵	Retrospective	46	?	6-15 months	2.17%
Pucci ⁶	Retrospective	25	42.9	39-49 months	4%
Lee ⁷	Retrospective	24	15	?	0%
Fernandez-Vega ⁸	Retrospective	190	57.6	37-96 months	2.1%

NA, not applicable.

and third and fourth generation biometric formulas, enhancing accuracy in longer eyes.

Nevertheless, RLE is an intraocular procedure with real sight threatening risks including acute intraoperative suprachoroidal haemorrhage, retinal detachment, and endophthalmitis. The low incidence of these complications in cataract surgery¹¹ does not diminish the visual consequences, should they occur.

CONCLUSION

Refractive lens exchange by modern small incision phacoemulsification is an effective means of correcting high myopia. RLE is particularly suitable for patients with high myopia who are presbyopic, or who are approaching presbyopia, especially in the presence of peripheral crystalline lens opacification.

Authors' affiliations

N Horgan, S Beatty, Department of Ophthalmology, Waterford Regional Hospital, Waterford, Republic of Ireland

P I Condon, Department of Ophthalmology, Aut Even Hospital, Kilkenny and Waterford Eye Clinic, Waterford, Republic of Ireland

Correspondence to: Noel Horgan, Royal Victoria Eye and Ear Hospital, Adelaide Road, Dublin 2, Republic of Ireland: noelhorg@hotmail.com

Accepted for publication 1 November 2004

REFERENCES

- 1 **Colin J**, Robinet A. Clear lensectomy and implantation of low-power posterior chamber intraocular lens for the correction of high myopia. *Ophthalmology* 1994;**101**:107-12.
- 2 **Colin J**, Robinet A. Clear lensectomy and implantation of low-power posterior chamber intraocular lens for correction of high myopia. *Ophthalmology* 1997;**104**:73-8.
- 3 **Colin J**, Robinet A, Cochener B. Retinal detachment after clear lens extraction for high myopia. *Ophthalmology* 1999;**106**:2281-5.
- 4 **Barraquer C**, Cavelier C, Mejia L. Incidence of retinal detachment following clear-lens extraction in myopic patients. *Arch Ophthalmol* 1994;**112**:336-9.
- 5 **Gris O**, Guell J, Manero F, *et al*. Clear lens extraction to correct high myopia. *J Cataract Refract Surg* 1996;**22**:686-9.
- 6 **Pucci V**, Morselli S, Romanelli F, *et al*. Clear lens phacoemulsification for correction of high myopia. *J Cataract Refract Surg* 2001;**27**:896-900.
- 7 **Lee KH**, Lee JH. Long-term results of clear lens extraction for severe myopia. *J Cataract Refract Surg* 1996;**22**:1411-15.
- 8 **Fernandez-Vega L**, Alfonso J, Villacampa T. Clear lens extraction for the correction of high myopia. *Ophthalmology* 2003;**110**:2349-54.
- 9 **Burton TC**. The influence of refractive error and lattice degeneration on the incidence of retinal detachment. *Trans Am Ophthalmol Soc* 1990;**87**:143-55.
- 10 **Perkins ES**. Morbidity from myopia. *Sightsav Rev* 1979;**49**:11-19.
- 11 **Desai P**, Misassian DC, Reidy A. The national cataract survey 1997-8: a report of the results of the clinical outcomes. *Br J Ophthalmol* 1999;**83**:1336-40.



Refractive lens exchange in high myopia: long term follow up

N Horgan, P I Condon and S Beatty

Br J Ophthalmol 2005 89: 670-672
doi: 10.1136/bjo.2004.052720

Updated information and services can be found at:
<http://bjo.bmj.com/content/89/6/670.full.html>

References

These include:

This article cites 11 articles, 2 of which can be accessed free at:
<http://bjo.bmj.com/content/89/6/670.full.html#ref-list-1>

Article cited in:
<http://bjo.bmj.com/content/89/6/670.full.html#related-urls>

Email alerting service

Receive free email alerts when new articles cite this article. Sign up in the box at the top right corner of the online article.

Topic Collections

Articles on similar topics can be found in the following collections

[Optic nerve](#) (558 articles)
[Optics and refraction](#) (385 articles)
[Ophthalmologic surgical procedures](#) (971 articles)
[Retina](#) (1217 articles)

Notes

To request permissions go to:
<http://group.bmj.com/group/rights-licensing/permissions>

To order reprints go to:
<http://journals.bmj.com/cgi/reprintform>

To subscribe to BMJ go to:
<http://group.bmj.com/subscribe/>