

EXTENDED REPORT

Optic disc topographic parameters measured in the normal cynomolgus monkey by confocal scanning laser tomography

T Taniguchi, M Shimazawa, M Araie, G Tomita, M Sasaoka, Y Kitazawa, H Hara

Br J Ophthalmol 2005;89:1058–1062. doi: 10.1136/bjo.2004.062513

See end of article for authors' affiliations

Correspondence to: Hideaki Hara, PhD, Department of Biofunctional Molecules, Gifu Pharmaceutical University, 5-6-1 Mitahara-higashi, Gifu 502-8585, Japan; hidehara@gifu-pu.ac.jp

Accepted for publication 1 February 2005

Aim: To study optic disc topographic parameters in normal cynomolgus monkeys by Heidelberg retina tomograph (HRT).

Methods: 12 optic disc topographic parameters were investigated in 36 normal eyes in 18 male monkeys. Mean (SD) and interocular differences were obtained for each parameter from three independent measurements made during a 1 week period. Correlations among the topographic parameters were analysed, too.

Results: No significant differences between right and left eyes were detected for any topographic parameters. Disc area, rim area, and height variation contour showed smaller right-left differences than other parameters. The coefficients of variation for rim area, height variation contour, rim volume, mean cup depth, maximum cup depth, mean retinal nerve fibre layer (RNFL) thickness, and RNFL cross section area were less than 10% (for rim area, less than 5%). Rim area and height variation contour showed relatively weak interrelations and neither showed a correlation with disc area.

Conclusion: For evaluating time related changes in the optic disc by HRT in monkeys, rim area and height variation contour might be useful parameters because coefficients of variation and right-left differences were lower than for other parameters and because these parameters showed weak interrelations and no correlation with disc area.

In cynomolgus and rhesus monkeys, the optic nerve head (ONH) resembles the human ONH in appearance and the pathophysiological changes that occur in experimental glaucoma resemble those in patients with glaucoma.^{1–4} Hence, the monkey eye is a useful model for the study of glaucoma. Half the 30 or so reports on ONH morphology in monkeys have noted ONH changes in experimental glaucoma in cynomolgus or rhesus monkeys. Many ONH studies in glaucomatous monkeys have employed in traditional methodologies, such as fundus photography and histological analysis, and have revealed enlargement of the optic disc cup, localised retinal nerve fibre defects, and selective loss of ganglion cells with thinning of the nerve fibre layer in experimental glaucoma eyes.^{1–9} On the other hand, Jonas and colleagues¹⁰ used fundus photographs to evaluate the normal optic disc as a prerequisite for a proper understanding of experimentally induced optic nerve changes such as those associated with glaucomatous damage in rhesus monkeys. However, these methods do not provide a full quantitative evaluation because optic disc parameters obtained from fundus photographs are usually expressed in relative terms and, moreover, histological comparisons may be affected by tissue shrinkage.^{1–10} In the clinical assessment of the optic disc from fundus photographs it is difficult to be objective; indeed, results vary particularly between different observers, even if they have adequate experience.¹¹ Furthermore, two dimensional analysis from fundus photographs may be unable to detect subtle changes in the progression of glaucoma, because glaucomatous changes in the optic disc are three dimensional.

By contrast, confocal scanning laser tomography allows us to obtain three dimensional images of the human optic disc.^{12–13} This device has been used to make quantitative, objective measurements of ONH structures in humans with reasonable reproducibility and potential advantages over

other techniques.^{12–17} Recently, this method has been used to study ONH structure in monkeys.^{18–22} The monkey ONH was studied using a computerised digital image analyser, rather than confocal scanning laser tomography.^{23–26} HRT (Heidelberg retina tomograph, Heidelberg Engineering), which operates on tomographic principles, is the most widely used optic nerve imaging tool in glaucoma clinics.^{12–14–17} Yücel and colleagues²¹ reported quantitative differences in the optic disc topographic parameters measured using HRT between the control fellow and experimental glaucoma eyes in cynomolgus monkeys. However, for a proper study of ONH changes in cynomolgus monkeys using HRT it is necessary to know the reproducibility of the measurements and also the variation in HRT parameters between individual normal monkeys. Further, the information about interocular differences (right-left differences) in normal monkeys is essential to use the fellow eye as a control for the experimental glaucoma eye. To our knowledge, however, appropriate data have yet to be published. We examined (a) the reproducibility of HRT measurements in a total of 36 eyes in 18 normal monkeys, (b) the interindividual variability and the right-left differences in each parameter, and (c) correlations among HRT parameters.

MATERIALS AND METHODS

Animals

Eighteen normal male cynomolgus monkeys (*Macaca fascicularis*) aged between 4.0 years and 5.5 years, weighing 4.0–

Abbreviations: CA, cup area; C/D, cup/disc area ratio; CSM, cup shape measure; CV, cup volume; DA, disc area; HRT, Heidelberg retina tomograph; HVC, height variation contour; IOP, intraocular pressure; MnCD, mean cup depth; MnRNFLT, mean RNFL thickness; MxCD, maximum cup depth; ONH, optic nerve head; RA, rim area; RCSA, RNFL cross section area; RNFL, retinal nerve fibre layer; RV, rim volume

5.0 kg were used. None of the eyes had been used in any other experiment, undergone any surgical procedure, or received any medical treatment. Monkeys were housed in an air conditioned room (24°C (SD 2°C), 60% (10% humidity) and allowed food and water ad libitum. All investigations were in accordance with the ARVO statement for the use of animals in ophthalmic and vision research.

Experimental protocol

Intraocular pressure (IOP) was measured using a calibrated pneumatonometer under ketamine anaesthesia (8.75–10 mg/kg, intramuscular: im), with local anaesthesia before any optic disc topographic images were taken. Optic disc topographic parameters were analysed using HRT (Heidelberg Engineering, Heidelberg, Germany) under ketamine (8.75–10 mg/kg, im) plus xylazine (0.5 mg/kg, im) anaesthesia. Before topographic image acquisition, the refractive index and corneal curvature radius were measured in each eye, then entered into the patient data submenu for the examined eye to allow correction of magnification effects on the images. The SD, which indicates the precision of the measurement process, was always less than 30 µm. The disc contour line was determined by an experienced operator while viewing fundus photographs. The following 12 optic disc topographic parameters were investigated: disc area (DA), cup area (CA), cup/disc area ratio (C/D), rim area (RA), height variation contour (HVC), cup volume (CV), rim volume (RV), mean cup depth (MnCD), maximum cup depth (MxCD), cup shape measure (CSM), mean retinal nerve fibre layer (RNFL) thickness (MnRNFLT), and RNFL cross section area (RCSA). The position of the reference plane was 50 µm posterior to the mean retinal height between 350 degrees and 356 degrees (temporal) along the operator drawn contour line delineating the optic disc margin. Topographic parameters were obtained three times over a 1 week period as independent measurements. The disc contour line was defined during the first measurement and this definition was transported to the topographic images obtained during the second and three measurements. Right-left differences in topographic parameters were calculated for each animal as the absolute difference between two eyes as previously described.²⁷ Measurements of HRT parameters and data analysis were each performed by an operator who was masked as to the purpose of this study.

Statistical analysis

Correlations analyses were assessed using Pearson’s correlation test. A Student’s *t* test was used to compare topographic parameters between the right and left eyes.

RESULTS

The fundus photographs showed no obvious retinal lesions, nerve fibre layer defects, or abnormalities of either the ONH or vascular structures in any of the eyes examined (fig 1A). Topographic images of the optic disc were obtained using HRT (figs 1B and 1C). The IOP values (mean (SD) *n* = 18) obtained for the right and left eyes were 20.7 (3.8) mm Hg and 20.0 (3.2) mm Hg, respectively. No statistically

significant correlations were observed between any topographic parameters and IOP (data not shown). The mean data of refraction in right and left eyes are shown in table 1. There was no significant difference between right and left eyes.

The mean (SD) values and right-left differences for each topographic parameter are shown in table 2. No statistically significant differences between the two eyes were found in all topographic parameters. Right-left differences were relatively large (>40% of mean value for right eye) for CA, C/D, and CV but relatively small (about 10% or <10% of mean for right eye) for DA, RA, and HVC. On the basis of data (mean (SD), and sample size) in table 2, we calculated the statistical power for detecting a 20% right-left difference in each parameter using a Student’s *t* test. Statistical power was more than 80% for RA, HVC, MnRNFLT, and RCSA. Thus, under our experimental conditions, a statistically significant difference would be detected in several parameters with a fair degree of certainty if the difference between right and left eyes was about 20%.

Seven topographic parameters (RA, HVC, RV, MnCD, MxCD, MnRNFLT, and RCSA) had coefficient of variation less than 10% for both eyes, with the smallest coefficient of variation (<5%) in each eye being shown by RA (table 3). For CA, C/D, CV, and CSM, the coefficient of variation was more than 10% in each eye, with that for CV being the highest (30–40%).

Finally, correlations among HRT parameters were examined (on the basis of the mean of three independent measurements from each eye) using Pearson’s correlation coefficient (table 4). CA, C/D, CV, RV, and MnCD displayed relatively strong interrelations (correlation coefficient more than 0.7), with significance being demonstrated for each eye, while DA, RA, HVC, and CSM exhibited relatively weak interrelations.

DISCUSSION

In this study, we measured optic disc topographic parameters in normal monkey eyes by means of HRT. The mean values obtained for each HRT parameter in the right and left eyes are comparable to those obtained for control fellow eyes in the previous study of experimental glaucoma in cynomolgus monkeys.²¹ Moreover, the coefficient of variation for parameters related to the optic disc cup (namely, CA, C/D, CV, and CSM) exceeded 10%, which is compatible with findings reported by others for humans.²⁸ By contrast, RA, HVC, RV, MnCD, MxCD, MnRNFLT, and RCSA each had coefficient of variation less than 10% for both eyes than those relating to the optic disc cup, suggesting that the values obtained for these parameters may be more reliable in monkeys. The coefficient of variation for RA was particularly low in this study and, interestingly, Tan and colleagues²⁸ noted that RA was the most reproducible parameter in humans. Previous reports have indicated that RA correlates well with the visual field and the degree of glaucomatous optic disc damage in humans.^{15–17} These findings suggest that RA should be suited for the evaluation of glaucomatous changes using HRT in monkey eyes as well as in humans.

There are two ways to define the disc contour line for evaluating time related changes in HRT parameters. One is to transport the contour line obtained for the base HRT image to subsequent images, the other is to redefine the contour line for each image. Roff *et al* compared the data variability between these two methods.²⁹ Their results indicated that the use of transport led to a lower data variability than redefinition. When investigating the coefficient of variation, it is desirable to limit data variability, and so in this study we used the transport method to define the disc contour line.

Although previous reports have investigated right-left differences in HRT parameters in healthy human subjects,^{30 31}

Table 1 Refraction in normal cynomolgus monkey eyes

	Right eye	Left eye
	Mean (SD)	Mean (SD)
Refraction (dioptries)	1.01 (1.52)	1.27 (1.45)

No significant difference between right and left eyes. Each value represents mean (SD) for 18 eyes.

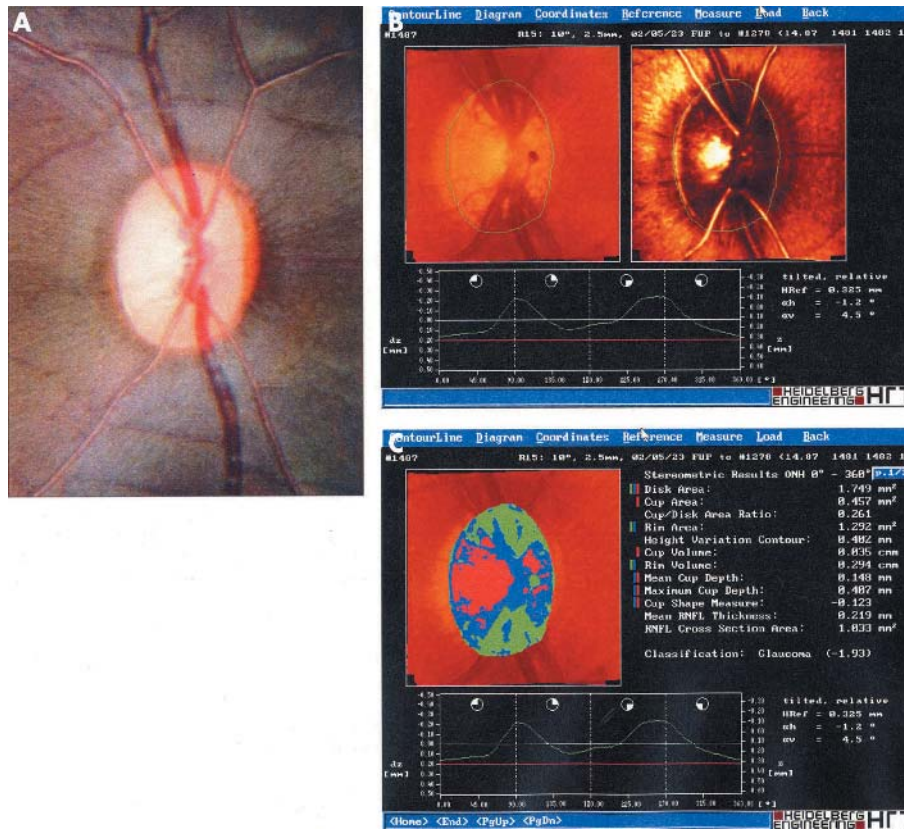


Figure 1 Representative fundus photograph and mean topographic images of optic disc obtained from HRT in normal cynomolgus monkey eye. (A) Fundus photograph; (B) mean topographic images; (C) analysis results for topographic parameters.

there have been no such reports in normal monkeys (table 5). RV and MnRNFLT were significantly lower in the left eye.³¹ MnRNFLT and RCSA were significantly lower in the right eye.³⁰ Although the reason for the discrepancy between these two reports is unclear, the age, sex ratio, and sample size were different between the two studies. By contrast, we observed no significant differences in HRT parameters between right and left eyes in monkeys that were all of one sex (male) and from a narrow age range, although the sample size was much smaller than in the previous reports on humans.³⁰⁻³¹ The values we obtained when we expressed right-left differences as a percentage of the mean value obtained for the right eye (R-L difference ratio) were lower (less than 20%) for RA, HVC, RV, MnCD, MxCD, CSM, MnRNFLT, and RCSA than for the other parameters.

Therefore, when evaluating longitudinal changes in HRT parameters in experimental glaucoma eyes (using non-treated fellow eyes as controls), these parameters, especially RA and HVC (each of which had an R-L difference ratio of about 10%), may be suitable parameters. By contrast, for CA, C/D, and CV, R-L difference ratios were greater than 40%, suggesting that these parameters are not suitable for this purpose.

Here, correlations among HRT parameters were investigated using Pearson's correlation coefficient, as described elsewhere.³²⁻³³ CA, C/D, CV, and MnCD showed stronger interrelations than the other parameters, a result compatible with previous findings in normal humans.³² This supports the optic disc structure of the monkey being comparable to that of humans. HRT parameters are determined following the

Table 2 Optic disc topographic parameters in normal cynomolgus monkey eyes

Parameters	Right eye		Left eye		Right-left difference		As % of mean value for right eye
	Mean	SD	Mean	SD	Mean	SD	
Disc area (mm ²)	1.62	0.24	1.62	0.24	0.08	0.06	4.9
Cup area (mm ²)	0.30	0.29	0.31	0.24	0.14	0.18	46.7
Cup/disc area ratio	0.17	0.15	0.18	0.12	0.08	0.09	47.1
Rim area (mm ²)	1.32	0.25	1.31	0.13	0.15	0.19	11.4
Height variation contour (mm)	0.40	0.05	0.39	0.05	0.04	0.03	10.0
Cup volume (mm ³)	0.03	0.05	0.03	0.03	0.02	0.03	66.7
Rim volume (mm ³)	0.33	0.10	0.31	0.06	0.06	0.07	18.2
Mean cup depth (mm)	0.13	0.05	0.12	0.04	0.02	0.02	15.4
Maximum cup depth (mm)	0.35	0.12	0.34	0.11	0.05	0.02	14.3
Cup shape measure	-0.17	0.06	-0.16	0.06	0.03	0.04	-17.6
Mean RNFL thickness (mm)	0.23	0.04	0.22	0.04	0.04	0.04	17.4
RNFL cross section area (mm ²)	1.04	0.21	0.97	0.17	0.17	0.19	16.3

No significant differences between right and left eyes.

Each value represents mean (SD) for 18 eyes. RNFL, retinal nerve fibre layer.

Right-left difference was calculated using the absolute difference between right and left eyes for each animal.

Table 3 Reproducibility of the optic topographic parameters measured using HRT

Parameters	Coefficient of variation			
	Right	SD	Left	SD
Cup area (mm ²)	23.3	24.8	24.2	28.2
Cup/disc area ratio	23.4	24.9	24.1	28.0
Rim area (mm ²)	3.4	3.4	3.1	2.3
Height variation contour (mm)	7.0	4.1	7.1	3.8
Cup volume (mm ³)	30.7	28.7	40.9	47.3
Rim volume (mm ³)	8.3	4.7	8.0	4.8
Mean cup depth (mm)	7.0	4.1	8.1	7.1
Maximum cup depth (mm)	6.0	4.0	5.8	5.8
Cup shape measure	12.6	6.3	13.1	11.1
Mean RNFL thickness (mm)	7.1	5.3	7.2	4.2
RNFL cross section area (mm ²)	7.1	5.3	7.1	4.2

Coefficient of variation was obtained from measurement at three times over a 1 week period. Disc area was defined in the first measurement, and transported to the second and third topographic images. No significant differences between right and left eyes. Each value represents mean (SD) for 18 eyes. RNFL, retinal nerve fibre layer

Table 4 Correlations among HRT parameters

		CA	C/D	RA	HVC	CV	RV	MnCD	MxCD	CSM	MnRNFLT	RCSA
DA	right	0.57*	0.50*	0.31	0.32	0.48*	0.01	0.60**	0.43	0.64**	-0.10	0.26
	left	0.86**	0.81**	0.24	0.16	0.78**	-0.23	0.56*	0.42	0.42	-0.30	0.08
CA	right		0.99**	-0.61**	-0.13	0.94**	-0.70**	0.87**	0.74**	0.65**	-0.73**	-0.53*
	left		0.99**	-0.28	0.16	0.90**	-0.59**	0.72**	0.53*	0.64**	-0.48*	-0.17
C/D	right			-0.66**	-0.19	0.92**	-0.74**	0.89**	0.77**	0.64**	-0.74**	-0.56*
	left			-0.36	0.17	0.87**	-0.61**	0.77**	0.58*	0.67**	-0.47	-0.17
RA	right				0.46	-0.62**	0.81**	-0.43	-0.43	-0.13	0.74**	0.86**
	left				<-0.01	-0.24	0.69**	-0.32	-0.21	-0.43	0.36	0.48*
HVC	right					-0.07	0.54*	0.01	-0.02	0.15	0.52*	0.59**
	left					0.02	0.22	0.24	0.15	0.24	0.36	0.42
CV	right						-0.63**	0.79**	0.72**	0.48*	-0.74**	-0.57*
	left						-0.47*	0.79**	0.71**	0.32	-0.35	-0.07
RV	right							-0.55*	-0.47*	-0.44	0.89**	0.87**
	left							-0.25	-0.10	-0.59**	0.77**	0.72**
MnCD	right								0.94**	0.56*	-0.47*	-0.26
	left								0.94**	0.29	0.06	0.27
MxCD	right									0.27	-0.37	-0.23
	left									-0.04	0.18	0.35
CSM	right										-0.45	-0.19
	left										-0.45	-0.30
MnRNFLT	right											0.93**
	left											0.93**

Values are shown as the Pearson correlation coefficient for 18 animals. *p<0.05, **p<0.01 (Pearson's correlation test). DA, disc area; CA, cup area; C/D, cup/disc area ratio; RA, rim area; HVC, height variation contour; CV, cup volume; RV, rim volume; MnCD, mean cup depth; MxCD, maximum cup depth; CSM, cup shape measure; MnRNFLT, mean RNFL thickness; RCSA, RNFL cross section area; RNFL, retinal nerve fibre layer.

Table 5 HRT parameters in normal human eyes of human in published studies

	Herman <i>et al</i> ³¹		Ghergel <i>et al</i> ³⁰	
	154 (female), 728 (male)		80 (female), 77 (male)	
	Age range 35-70 years		Age range 14-77 years	
	Right	Left	Right	Left
Disc area (mm ²)	1.83 (0.39)	1.81 (0.39)	1.92 (0.38)	1.90 (0.37)
Cup area (mm ²)	0.44 (0.32)	0.44 (0.32)	0.49 (0.26)	0.47 (0.28)
Cup/disc area ratio	0.22 (0.13)	0.22 (0.13)	0.24 (0.10)	0.23 (0.11)
Rim area (mm ²)	1.39 (0.27)	1.37 (0.27)	1.43 (0.28)	1.42 (0.25)
Cup volume (mm ³)	NA	NA	0.12 (0.10)	0.11 (0.11)
Rim volume (mm ³)	0.38 (0.13)	0.36 (0.12)	0.37 (0.12)	0.40 (0.13)
Maximum cup depth (mm)	NA	NA	0.66 (0.18)	0.69 (0.18)
Cup shape measure	NA	NA	-0.23 (0.07)	-0.24 (0.07)
Mean RNFL thickness (mm)	0.26 (0.07)	0.25 (0.07)	0.25 (0.06)	0.27 (0.06)
RNFL cross section area (mm ²)	NA	NA	1.20 (0.32)	1.33 (0.32)

Each value represents mean (SD). RNFL, retinal nerve fibre layer. NA, not available. Data in table are derived from previous reports by Herman *et al*³¹ and Ghergel *et al*³⁰ (see column headings).

drawing of contour lines to define DA. This procedure is to some extent observer dependent. Therefore, it is important to know which parameters are influenced by DA. In our study, DA correlated with CA, C/D, CV and MnCD (in both eyes), and CSM (in the right eye only). Further, for most of these parameters both the coefficient of variation and R-L difference ratio were relatively high. By contrast, RA, HVC, RV, MxCD, MnRNFLT, and RCSA seemed to be unaffected by DA in either eye. For these parameters, both the coefficient of variation (less than 10%) and the R-L difference ratio (less than 20%) were relatively low. These findings suggest that these parameters, especially RA and HVC may be more suitable than the other parameters for evaluating optic disc changes.

When evaluating HRT parameters in another non-human primate (for example, rhesus monkey) under our experimental conditions, our results (in particular, coefficient of variation) may be useful. However, as previous reports have indicated that the optic structures measured by HRT display racial differences,^{34, 35} it is possible that the monkey optic disc structure also differs among the various kinds of monkeys.

In conclusion, we examined optic disc topographic parameters in normal eyes in male cynomolgus monkeys of similar ages. RA and HVC showed relatively low coefficient of variation values (less than 10%), low R-L difference ratios (about 10%), no correlation with DA in either eye, and relatively weak interrelations. These basic results may be useful when HRT is used in monkeys to evaluate optic disc changes in experimentally induced optic disc damage and also to evaluate the efficacy of potential treatments.

Authors' affiliations

T Taniguchi, M Sasaoka, Research and Development Center, Santen Pharmaceutical Co Ltd, Nara, Japan
M Shimazawa, H Hara, Department of Biofunctional Molecules, Gifu Pharmaceutical University, Gifu, Japan
M Araie, G Tomita, Department of Ophthalmology, University of Tokyo School of Medicine, Tokyo, Japan
Y Kitazawa, Department of Ophthalmology, Gifu University School of Medicine, Gifu, Japan

REFERENCES

- 1 Gaasterland D, Kupfer C. Experimental glaucoma in the rhesus monkey. *Invest Ophthalmol Vis Sci* 1974;**13**:455-7.
- 2 Varma R, Quigley HA, Pease ME. Changes in optic disk characteristics and number of nerve fibers in experimental glaucoma. *Am J Ophthalmol* 1992;**114**:554-9.
- 3 Hayreh SS, Pe'er J, Zimmerman MB. Morphologic changes in chronic high-pressure experimental glaucoma in rhesus monkeys. *J Glaucoma* 1999;**8**:56-71.
- 4 Jonas JB, Hayreh SS. Localised retinal nerve fibre layer defects in chronic experimental high pressure glaucoma in rhesus monkeys. *Br J Ophthalmol* 1999;**83**:1291-5.
- 5 Quigley HA, Hohman RM, Addicks EM, et al. Blood vessels of the glaucomatous optic disc in experimental primate and human eyes. *Invest Ophthalmol Vis Sci* 1984;**25**:918-31.
- 6 Derick RJ, Pasquale LR, Pease ME, et al. A clinical study of peripapillary crescents of the optic disc in chronic experimental glaucoma in monkey eyes. *Arch Ophthalmol* 1994;**112**:846-50.
- 7 Hayreh SS, Jonas JB, Zimmerman MB. Parapapillary chorioretinal atrophy in chronic high-pressure experimental glaucoma in rhesus monkeys. *Invest Ophthalmol Vis Sci* 1998;**39**:2296-303.
- 8 Jonas JB, Hayreh SS. Optic disk morphology in experimental central retinal artery occlusion in rhesus monkeys. *Am J Ophthalmol* 1999;**127**:523-30.
- 9 Jonas JB, Hayreh SS. Influence of experimental chronic high-pressure glaucoma on age-related macular degeneration in rhesus monkeys. *Invest Ophthalmol Vis Sci* 2000;**41**:2972-7.
- 10 Jonas JB, Hayreh SS. Ophthalmoscopic appearance of the normal optic nerve head in rhesus monkeys. *Invest Ophthalmol Vis Sci* 2000;**41**:2978-83.
- 11 Varma R, Steinmann WC, Scott IU. Expert agreement in evaluating the optic disc for glaucoma. *Ophthalmology* 1992;**99**:215-21.
- 12 Malinovsky VE. An overview of the Heidelberg retina tomograph. *J Am Optom Assoc* 1996;**67**:457-67.
- 13 Ahn BS, Kee C. Ability of a confocal scanning laser ophthalmoscope (TopSS) to detect early glaucomatous visual field defect. *Br J Ophthalmol* 2000;**84**:852-5.
- 14 Azuara-Blanco A, Harris A, Cantor LB. Reproducibility of optic disk topographic measurements with the Topcon ImageNet and the Heidelberg retina tomograph. *Ophthalmologica* 1998;**212**:95-8.
- 15 Lester M, Mikelberg FS, Courtright P, et al. Correlation between the visual field indices and Heidelberg retina tomograph parameters. *J Glaucoma* 1997;**6**:78-82.
- 16 Eid TM, Spaeth GL, Katz LJ, et al. Quantitative estimation of retinal nerve fiber layer height in glaucoma and the relationship with optic nerve head topography and visual field. *J Glaucoma* 1997;**6**:221-30.
- 17 Lan YW, Henson DB, Kwartz AJ. The correlation between optic nerve head topographic measurements, peripapillary nerve fibre layer thickness, and visual field indices in glaucoma. *Br J Ophthalmol* 2003;**87**:1135-41.
- 18 Heickell AG, Bellezza AJ, Thompson HW, et al. Optic disc surface compliance testing using confocal scanning laser tomography in the normal monkey eye. *J Glaucoma* 2001;**10**:369-82.
- 19 Burgoyne CF, Mercante DE, Thompson HW. Change detection in regional and volumetric disc parameters using longitudinal confocal scanning laser tomography. *Ophthalmology* 2002;**109**:455-66.
- 20 Ervin JC, Lemij HG, Mills RP, et al. Clinician change detection viewing longitudinal stereophotographs compared to confocal scanning laser tomography in the LSU Experimental Glaucoma (LEG) Study. *Ophthalmology* 2002;**109**:467-81.
- 21 Yücel YH, Gupta N, Kalichman MW, et al. Relationship of optic disc topography to optic nerve fiber number in glaucoma. *Arch Ophthalmol* 1998;**116**:493-7.
- 22 Hare WA, WoldeMussie E, Weinreb RN, et al. Efficacy and safety of memantine treatment for reduction of changes associated with experimental glaucoma in monkey, II: Structural measures. *Invest Ophthalmol Vis Sci* 2004;**45**:2640-51.
- 23 Quigley HA, Pease ME. Change in the optic disc and nerve fiber layer estimated with the glaucoma-scope in monkey eyes. *J Glaucoma* 1996;**5**:106-16.
- 24 Shirakashi M, Abe H, Sawaguchi S, Iwata K. The relationship between deterioration and reversal of optic disc cupping in monkeys with chronic experimental high-pressure glaucoma. *Graefes Arch Clin Exp Ophthalmol* 1998;**236**:546-52.
- 25 Burgoyne CF, Varma R, Quigley HA, et al. Global and regional detection of induced optic disc change by digitized image analysis. *Arch Ophthalmol* 1994;**112**:261-8.
- 26 Burgoyne CF, Quigley HA, Thompson HW, et al. Measurement of optic disc compliance by digitized image analysis in the normal monkey eye. *Ophthalmology* 1995;**102**:1790-9.
- 27 Saruhan A, Orgul S, Kocak I, et al. Descriptive information of topographic parameters computed at the optic nerve head with the Heidelberg retina tomograph. *J Glaucoma* 1998;**7**:420-9.
- 28 Tan JC, Garway-Heath DF, Hitchings RA. Variability across the optic nerve head in scanning laser tomography. *Br J Ophthalmol* 2003;**87**:557-9.
- 29 Roff EJ, Hosking SL, Barnes DA. The influence of contour line size and location on the reproducibility of topographic measurement with the Heidelberg retina tomograph. *Ophthalmic Physiol Opt* 2001;**21**:173-81.
- 30 Gherghel D, Orgul S, Prunte C, et al. Interocular differences in optic disc topographic parameters in normal subjects. *Curr Eye Res* 2000;**20**:276-82.
- 31 Hermann MM, Theofylaktopoulos I, Bangard N, et al. Optic nerve head morphometry in healthy adults using confocal laser scanning tomography. *Br J Ophthalmol* 2004;**88**:761-5.
- 32 Nakamura H, Maeda T, Suzuki Y, et al. Scanning laser tomography to evaluate optic discs of normal eyes. *Jpn J Ophthalmol* 1999;**43**:410-14.
- 33 Durukan AH, Yucler I, Akar Y, et al. Assessment of optic nerve head topographic parameters with a confocal scanning laser ophthalmoscope. *Clin Experiment Ophthalmol* 2004;**32**:259-64.
- 34 Tsai CS, Zangwill L, Gonzalez C, et al. Ethnic differences in optic nerve head topography. *J Glaucoma* 1995;**4**:248-57.
- 35 Girkin CA, McGwin G Jr, McNeal SF, et al. Racial differences in the association between optic disc topography and early glaucoma. *Invest Ophthalmol Vis Sci* 2003;**44**:3382-7.



Optic disc topographic parameters measured in the normal cynomolgus monkey by confocal scanning laser tomography

T Taniguchi, M Shimazawa, M Araie, et al.

Br J Ophthalmol 2005 89: 1058-1062

doi: 10.1136/bjo.2004.062513

Updated information and services can be found at:

<http://bjo.bmj.com/content/89/8/1058.full.html>

These include:

References

This article cites 35 articles, 15 of which can be accessed free at:

<http://bjo.bmj.com/content/89/8/1058.full.html#ref-list-1>

Email alerting service

Receive free email alerts when new articles cite this article. Sign up in the box at the top right corner of the online article.

Notes

To request permissions go to:

<http://group.bmj.com/group/rights-licensing/permissions>

To order reprints go to:

<http://journals.bmj.com/cgi/reprintform>

To subscribe to BMJ go to:

<http://group.bmj.com/subscribe/>