

SCIENTIFIC REPORT

Follow up of patients with ocular scarring secondary to LOC syndrome treated by amniotic membrane transplantation

J E Moore, S Shah, V Kumar, J R Ainsworth, A B Page, W H I McLean

Br J Ophthalmol 2005;89:939–941. doi: 10.1136/bjo.2004.059121

Aims: To document and discuss the long term outcome of a new ophthalmic treatment for laryngo-onycho-cutaneous (LOC) syndrome.

Methods: Two children were treated by excision of ocular granulation tissue and ocular surface rehabilitation with frozen amniotic membrane (AM). The clinical course of both patients was followed and documented at 2 years and 4 years following the surgery.

Results: Patient 1 demonstrated limited recurrence of granulation tissue at 10 months. After 36 months, re-growth of granulation and scar tissue required a further three subsequent operations to the right eye in an attempt to keep the optical axis clear. 4 years postoperatively, neither eye has a clear visual axis. In contrast similar surgery for the right eye of patient 2 has been highly successful, with only very limited non-progressive recurrence after 2 years of follow up. The operation to the left eye has been similarly effective although the follow up is only 6 months.

Conclusions: Ocular surface rehabilitation with AM is the first partially effective treatment for the eye complications of LOC syndrome. The surprising benefit from AM may stem from the primary pathology of the condition. LOC syndrome is caused by a genetic defect resulting in an unusual N-terminal deletion of the $\alpha 3a$ chain of the basement membrane protein laminin 5. One mechanism through which AM transplantation may act to reduce ocular scarring in this disease is to supplement the abnormal secreted laminin 5 with healthy transplanted laminin. Despite its initial efficacy one episode of AM treatment does not guarantee long term control of the scarring process and variations in AM graft efficacy may be related to other complicating factors such as limbal stem cell deficiency or severity of the initial scarring process.

Laryngo-onycho-cutaneous syndrome (LOC syndrome) is a recently described homozygous recessive condition.¹ It is characterised by proliferation of mucosal and dermal granulation tissue and progressive scarring of the conjunctiva and cornea is a common cause of blindness in LOC syndrome.² To date no effective treatment has been demonstrated to manage the ocular surface disease in this condition and repeated excision of granulation tissue has been suggested to exacerbate progression of the disease.

We have previously reported a single case in which we implemented a novel method of ocular surface reconstruction using amniotic membrane (AM).³ This was partially effective during short to medium review, with reversal of scarring, increased eyelid mobility, and improved vision in the treated eyes.

The genetic cause of LOC syndrome was unknown until recently. We localised the causative gene for LOC syndrome

to the long arm of human chromosome 18 by homozygosity mapping in consanguineous kindreds.⁴ The causative gene was found to be LAMA3, encoding at least three alternatively spliced forms of the laminin $\alpha 3$ protein. In LOC syndrome, there is expression of laminin $\alpha 3a$ with an N-terminal deletion of 226 amino acids. The resultant truncated protein is assembled into laminin 5 trimers and efficiently secreted by keratinocytes.⁴ It is hypothesised that the laminin $\alpha 3a$ N-terminal domain negatively regulates granulation tissue formation by the underlying mesenchyme. Since LOC patients lack this domain, excessive granulation tissue develops in certain epithelial tissues where there is mild but constant physical trauma, such as the ocular surface and vocal cords.

The initial report described the first 10 months of post-operative course. We now report longer term follow up in the same patient and another patient treated with AM. We discuss how this may counteract ocular scarring and suggest possible future therapies.

METHODS

Case 1

A 10 year old male British Pakistani child, with LOC syndrome was found to be homozygous for the reported LOC mutation, 151insG in exon 39 of the laminin $\alpha 3$ gene.⁴ He presented at 1½ years of age. The first operative procedure was carried out that year and over subsequent years, extensive granulation tissue has been systematically excised when the cornea appeared threatened, at approximately 4 month intervals. Other treatment used included topical 2% ciclosporin, topical 5-fluorouracil, systemic steroids, and thalidomide, none of which altered the regrowth rate of granulation tissue. It was decided to embark on AM transplantation because of the intractable nature of the disorder.

The initial procedure consisted of release of symblepharon and ankyloblepharon followed by dissection and excision of the extensive granulation tissue. Multiple previous operations to the left eye had resulted in a thin cornea secondary to previous superficial keratectomies. Human AM (preserved in 10% DMSO as described by Dua *et al*⁵) was used epithelial side upwards to cover all of the cornea and as much of the scleral and subtarsal surface as possible, sutured into fornix and subtarsally. Postoperative management consisted of a bandage lens over the membrane graft, preservative free 1% prednisolone acetate drops and 0.5% chloramphenicol drops four times a day tapered after 4 weeks.

The procedure for the right eye was similar but more limited. Two subsequent operations were required to the left eye and one to the right because of recurrence of fibrovascular scarring, this time using double layered AM in the temporal region and bolsters to fashion fornices.

Abbreviations: AM, amniotic membrane; LOC, laryngo-onycho-cutaneous

Case 2

A 10 year old female British Pakistani girl with LOC syndrome, of consanguineous parentage, was homozygous for the 151insG mutation. Ocular granulation tissue presented in the first year of life. Many previous eye operations had been performed before referral as with patient 1. These operations had only a temporary effect on ocular surface scar tissue, which quickly reinvaded the cornea within weeks of surgery. At referral bilateral extensive scarring of the ocular surface included cornea and visual axis. The right eye was initially chosen for surgery because it retained at least 180 degrees of unaffected limbus, implying significant healthy limbus with stem cell function was present (fig 1A).

Amniotic membrane grafting was then performed on the basis of our previous favourable published results.³ Surgery followed a similar technique to patient 1 but differed by use of double layers of AM throughout, except in the temporal region where triple layers were used.

After a 12 month successful follow up a similar procedure was carried out to the left eye. The left eye was, however, much more extensively involved by scar tissue with most if not all limbus affected by scar tissue (fig 1B).

RESULTS

Patient 1

In the left eye, initial postoperative results were good, with early resolution of postoperative inflammation and regression of residual forniceal granulation tissue. Improvement was maintained for a 10 month period before recurrence in scar tissue at the temporal aspect of the conjunctiva; a substantial improvement over previous treatments. Despite a further AM transplantation, scar tissue recurred again at 10 months and on this occasion 360 degrees of the limbus was involved. One further similar operative procedure was attempted to clear the visual axis, but on this occasion surface scar tissue recurred within 6 months.

Surgical intervention to the right eye was similarly successful in the medium term. However, there was recrudescence of scar tissue in the superotemporal fornix 9 months after the surgery, which progressed to the visual axis by 13 months. A repeat operation only retained a clear

visual axis for 8 months. Forty eight months after the first AM grafting procedure, neither visual axis is clear.

Patient 2

This patient has maintained a successful outcome compared to patient 1, with follow up of more than 24 months. Complications have been limited to mild focal recurrence in the right eye (fig 1C) while the left eye has to date also responded well with regression of corneal vascularisation (fig 1D), but follow up for the left eye is still short, at 6 months.

DISCUSSION

LOC syndrome has been demonstrated by McLean *et al* to occur secondary to a genetic defect in laminin $\alpha 3a$.⁴ One of the many mechanisms⁶ through which AM may help in controlling ocular complications of this disease process is by introducing healthy laminin $\alpha 3a$ in the form of laminin 5 to the ocular surface.⁷ AM disappears, however, with time and it might be expected therefore that disease activity would return. Some aspects of the disease process ameliorate with time and if the visual axis remained scar free until adulthood, eye disease might then reduce in severity. Before using amniotic membrane in LOC syndrome, all treatment options for the ocular surface have resulted in rapid recurrence of invasive granulation tissue.² AM transplantation has provided clear initial benefit.³ Longer follow up has demonstrated recurrence in both patients, more marked in patient 1. Long term prognosis of this treatment strategy may depend on the pathological state of the ocular surface before treatment. Patient 1 had had limbal stem cell failure in either one or both eyes in addition to marked scarring of the ocular surface.

Rehabilitation of the ocular surface in the right eye of patient 2 has been extremely successful after 24 months. The right eye of patient 2, despite having severe disease, still retained an area of unaffected limbus (170 degrees)⁸ (fig 1C), which may be an important factor in the treatment success. We hypothesise that the inability to maintain remission in patient 1 may have been due to pre-existing limbal stem cell failure with resulting conjunctivalisation of the cornea. In such cases a combined corneal and conjunctival stem cell

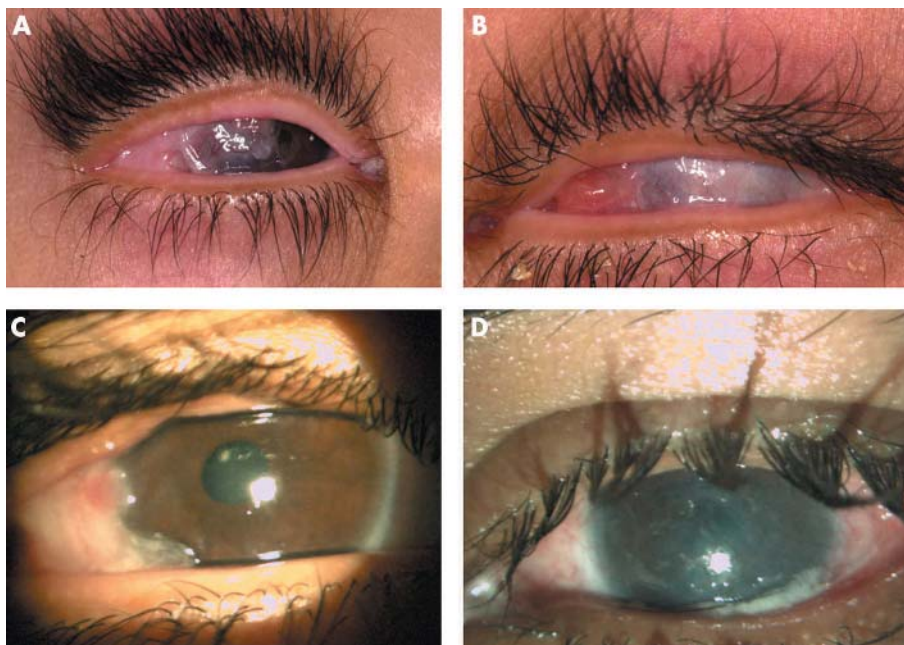


Figure 1 (A) The preoperative appearance of the right eye of patient 2. The temporal aspect of this patient's eye is completely scarred with symblepharon and scar tissue has invaded the cornea covering the visual axis. Fortunately, more than 180 degrees of the limbus is unaffected along with the whole nasal aspect of the ocular surface conjunctiva. (B) The preoperative appearance of the left eye of patient 2 showing gross ocular surface scarring. (C) Right eye 2 years postoperatively of patient 2 showing post-ocular surface reconstruction with amniotic membrane. There is evidence of limited localised recurrence of granulation scar tissue affecting the temporal aspect of the ocular surface. (D) Left eye 9 months postoperatively in patient 2. The ocular surface remains scar free. Some corneal stromal blood vessels are still obvious.

transplantation procedure might offer a further therapeutic option.^{9 10} An advantage of allogenic grafting would be the introduction of cells expressing laminin 5 without the LAMA3 gene defect of LOC but long term immunosuppression would be required.

At present it is unclear why scarring initiates in the superior temporal aspect of the conjunctiva. This may be due to selective expression of laminin α 3a by the conjunctival epithelial cells in this region, or local variation in abrasive forces. Certainly, conjunctival epithelial cells express hemidesmosomes,¹¹ and it is likely that these associate with basement membrane containing laminin 5. Buccal¹⁰ or nasal mucosal^{12 13} transplantation are options to consider in LOC, particularly if the ocular surface has become dry; success may depend in part on the degree of abnormal laminin α 3a expressed in the basement membranes of other mucosa.¹⁴

Gene replacement therapy is theoretically possible, ex vivo retrovirally transduced cultured autologous conjunctival epithelial cells could be reintroduced to the ocular surface. Another approach might use recombinant proteins such as recombinant laminin 5 to the ocular surface. Again, this might have a temporary effect at best. The laminin 5 trimer is a large protein complex unlikely to pass through intact epithelial layers to reach basement membrane. Of the 226 amino acids missing in the LOC protein product only 57 are specific to the α 3a isoform.⁴ Use of a recombinant peptide analogue of the small missing laminin α 3a N-terminus alone might improve delivery. We are currently investigating the interactions of the laminin α 3a N-terminal domain and its effects on mesenchymal cell behaviour with a view to developing anti-granulation tissue therapy. A developed transgenic animal model of LOC, as has been done for other genetic diseases of epithelia,^{15 16} would allow testing of the above therapies.

To our knowledge, these are the first, and possibly the only, patients with LOC syndrome to undergo successful treatment for a significant postoperative period for ocular complications of the disease. Success may not be long term. The factors determining duration of benefit are unknown. We speculate that limbal stem cell deficiency secondary to multiple previous operative procedures may have a negative effect on the outlook for these patients after treatment with AM.

Authors' affiliations

J E Moore, A B Page, Department of Ophthalmology, RVH, Belfast, Northern Ireland, UK

S Shah, V Kumar, Department of Ophthalmology, BMEC, Birmingham, UK

J R Ainsworth, Birmingham Children's Hospital, Birmingham, UK
W H I McLean, Epithelial Genetics Group, Human Genetics Unit, Division of Pathology and Neuroscience, Ninewells Medical School, Dundee DD1 9SY, UK

Correspondence to: Mr J E Moore, Department of Ophthalmology, Royal Victoria Hospital, Grosvenor Road, Belfast BT12 6BA, UK; johnnymoore@doctors.org.uk

Accepted for publication 9 January 2005

REFERENCES

- 1 Shabbir G, Hassan M, Kazmi A. Laryngo-onycho-cutaneous syndrome—a study of 22 cases. *Biomedica* 1986;**2**:15–25.
- 2 Ainsworth JR, Spencer AF, Dudgeon J, et al. Laryngeal and ocular granulation tissue formation in two Punjabi children: LOGIC syndrome. *Eye* 1991;**5**:717–22.
- 3 Moore JE, Dua HS, Page AB, et al. Ocular surface reconstruction in LOGIC syndrome by amniotic membrane transplantation. *Cornea* 2001;**20**:753–6.
- 4 McLean WH, Irvine AD, et al. An unusual N-terminal deletion of the laminin α 3a isoform leads to the chronic granulation tissue disorder laryngo-onycho-cutaneous syndrome. *Hum Mol Genet* 2003;**12**:2395–409.
- 5 Dua HS, Azuara-Blanco A. Amniotic membrane transplantation. *Br J Ophthalmol* 1999;**83**:748–52.
- 6 Tseng SCG, Espana EM, Kawakita T, et al. How does amniotic membrane work? *The Ocular Surface* 2004;**2**:177–87.
- 7 Kurpakus-Wheater M. Laminin-5 is a component of preserved amniotic membrane. *Curr Eye Res* 2001;**22**:353–7.
- 8 Holland EJ. Epithelial transplantation for the management of severe ocular surface disease. *Trans Am Ophthalmol Soc* 1996;**94**:677–743.
- 9 Sangwan VS, Vemuganti GK, Iftikhar G, et al. Use of autologous cultured limbal and conjunctival epithelium in a patient with severe bilateral ocular surface disease induced by acid injury: a case report of unique application. *Cornea* 2003;**22**:478–81.
- 10 Coster DJ, Aggarwal RK, Williams KA. Surgical management of ocular surface disorders using conjunctival and stem cell allografts. *Br J Ophthalmol* 1995;**79**:977–82.
- 11 Sellheyer K, Spitznas M. Ultrastructural observations on the development of the human conjunctival epithelium. *Graefes Arch Clin Exp Ophthalmol* 1988;**226**:489–99.
- 12 Naumann GOH, Lang GK, Rummelt V, et al. Autologous nasal mucosa transplantation in severe bilateral conjunctival mucus deficiency syndrome. *Ophthalmology* 1990;**97**:1011–17.
- 13 Hartmut W, Volker R, Gottfried OHN. Long term results after autologous nasal mucosal transplantation in severe mucus deficiency syndromes. *Br J Ophthalmol* 2000;**84**:279–84.
- 14 Kosmehl H, Berndt A, Strassburger S, et al. Distribution of laminin and fibronectin isoforms in oral mucosa and oral squamous cell carcinoma. *Br J Cancer* 1999;**81**:1071–9.
- 15 Arin MJ, Longley MA, Wang XJ, et al. Focal activation of a mutant allele defines the role of stem cells in mosaic skin disorders. *J Cell Biol* 2001;**152**:645–9.
- 16 Cao T, Longley MA, Wang X-J, et al. An inducible mouse model for epidermolysis bullosa simplex: implications for gene therapy. *J Cell Biol* 2001;**152**:651–6.



Follow up of patients with ocular scarring secondary to LOC syndrome treated by amniotic membrane transplantation

J E Moore, S Shah, V Kumar, et al.

Br J Ophthalmol 2005 89: 939-941
doi: 10.1136/bjo.2004.059121

Updated information and services can be found at:
<http://bjo.bmj.com/content/89/8/939.full.html>

These include:

References

This article cites 13 articles, 6 of which can be accessed free at:
<http://bjo.bmj.com/content/89/8/939.full.html#ref-list-1>

Email alerting service

Receive free email alerts when new articles cite this article. Sign up in the box at the top right corner of the online article.

Topic Collections

Articles on similar topics can be found in the following collections

[Paediatrics](#) (278 articles)

Notes

To request permissions go to:
<http://group.bmj.com/group/rights-licensing/permissions>

To order reprints go to:
<http://journals.bmj.com/cgi/reprintform>

To subscribe to BMJ go to:
<http://group.bmj.com/subscribe/>