

## SCIENTIFIC REPORT

## Lateral rectus muscle disinsertion and reattachment to the lateral orbital wall

Y Morad, L Kowal, A B Scott

*Br J Ophthalmol* 2005;89:983–985. doi: 10.1136/bjo.2004.051219

**Background/aims:** Surgical correction of ocular alignment in patients with third cranial nerve paralysis is challenging, as the unopposed lateral rectus muscle often pulls the eye back to exotropia following surgery. The authors present a simple surgical approach to overcome this difficulty. This approach is also applicable to removal of unwanted over-activity of the lateral rectus in Duane syndrome.

**Methods:** A review was made of the records of four patients with third cranial nerve paralysis and one with Duane syndrome with exotropia in which the lateral rectus muscle was removed from its scleral insertion and reattached to the orbital wall. Additional surgery to bring the eye to the midline included medial rectus resection, medial transposition of the vertical recti, and passive suturing of the eye to the medial orbit wall.

**Results:** All patients achieved satisfactory ocular alignment following surgery. Ocular ductions were limited. These results were stable for 1.5–4 years of follow up. No major complications occurred.

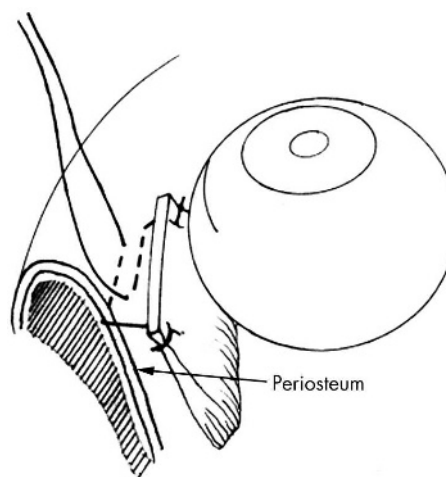
**Conclusion:** Lateral rectus muscle disinsertion and reattachment to the orbital wall to absorb its force and thus remove abduction torque was a simple and safe surgical procedure for restoring ocular alignment in four patients with third cranial nerve paralysis and in one patient with Duane syndrome with severe exotropia.

Surgical treatment of third cranial nerve paralysis is a challenging problem. The lateral rectus and superior oblique muscles with no antagonist to counteract their activity place the eye in a divergent and depressed position with minimal movement. Conventional recession-resection procedure results in a drift back to exotropia.<sup>1</sup> Additional techniques are transposition of the superior oblique tendon to a position on the medial aspect of the globe,<sup>2–4</sup> temporal mattress suture,<sup>5</sup> splitting and reattaching the lateral rectus muscle near the vortex veins,<sup>6</sup> transposition of the lateral rectus to the medial rectus insertion,<sup>7,8</sup> fixation of the eye to the medial orbit using fascia lata or a periosteal flap,<sup>9,10</sup> and excision of a major portion of the lateral rectus muscle.<sup>11</sup>

We report a small case series of a simple surgical technique to balance the forces on the eye in third nerve palsy: disinsertion of the lateral rectus and reattachment to the orbital wall. This approach is also useful in removing the abnormal activity of the lateral rectus in Duane syndrome.

## METHOD

See figure 1. Through a lateral limbal conjunctival incision, the lateral rectus muscle is cleared of adherent tissues, cutting the intermuscular membranes attached to the borders of the muscle for a distance of 15 mm posterior to the insertion. The tendon is sutured using non-absorbable suture,

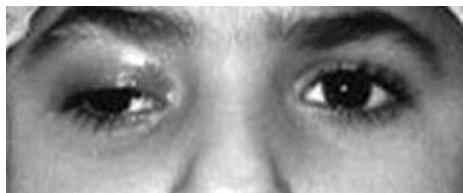


**Figure 1** Sketch of the procedure.

and detached from the sclera. Ethicon No 8726, 6-0 polypropylene is advantageous as the C-1 taper point cardiovascular needles do not cut out when inserted into the thin periosteum. Dacron suture has also worked well. The small amount of tissue between the lateral rectus and the lateral orbital wall can be swept away by blunt dissection, augmented if necessary with a few snips of scissors. The lateral rectus tendon is sutured to the periosteum under slight tension with one or more needle bites to make a secure connection. This is technically easy with a virgin lateral rectus, which can be pulled anteriorly to the orbit rim. The shortened and tight lateral rectus resulting from previous recession is sutured to the lateral orbital wall as much as 15 mm more posteriorly. The cut edges of the upper and lower intermuscular membranes are sutured together over the lateral sclera with one or two non-absorbable suture to form a barrier to adherence of the lateral rectus to the eye. The lateral conjunctiva is recessed upon closure if it is found to be tight. Adduction of the eye should be rather free at this point. If not, a tight superior oblique muscle is probably present, and tenotomy of the superior oblique tendon should be considered. The paretic medial rectus is resected enough, typically 12–13 mm, to bring the eye to 5–10 degrees of adduction. If it is excessively atrophic or damaged by previous surgery, then passive suturing of the eye to the orbit, or attachment of the superior oblique tendon to the sclera medially should be considered.

All five cases treated by the authors over the past 4 years are included.

**Abbreviations:** IR, inferior rectus; MRI, magnetic resonance imaging; SR, superior rectus



**Figure 2** Case 3, preoperative alignment.

### Case 1

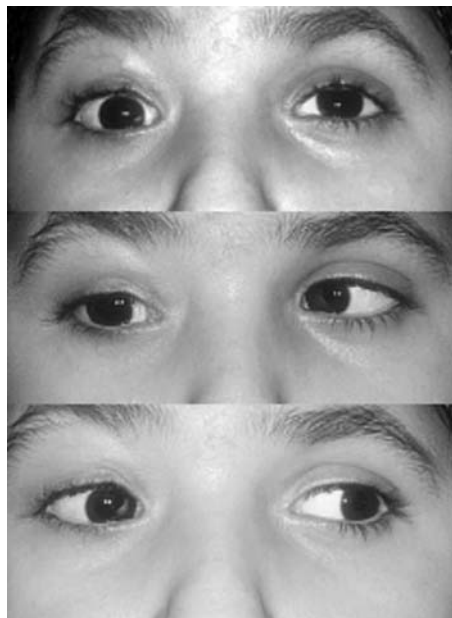
An 18 year old woman had had a closed head injury in a road accident 18 months earlier. The right eye findings were 20 degrees of exotropia, enlarged and fixed pupil, ptosis of the upper lid, and absent ductions medially, superiorly, and inferiorly. Magnetic resonance imaging (MRI) showed atrophy of the right medial, inferior rectus (IR) and superior rectus (SR) and the superior oblique muscles. At surgery on the right eye the lateral rectus tendon was detached from the eye and sutured to the lateral orbit wall using 6-0 polypropylene suture. The medial rectus was resected 12 mm and the medial halves of the SR and IR were transposed nasally. The atrophic the superior oblique was not operated. The eye position was 10 degrees of esotropia at the end of the procedure. The lid was sutured to the frontalis muscle. The eye has remained at 2–3 degrees exotropia for 21 months. Duction amplitude is 2–3 degrees in any direction. There is fusion with stereopsis over a range of 3–4 degrees, but the patient uses this infrequently. Corneal exposure with vessel growth into the lower cornea is a mild problem.

### Case 2

A 64 year old man had had a left third cranial nerve paralysis from a head injury 40 years earlier. Two strabismus and eyelid procedures had been done, each of which improved the eye position for only several months. Exotropia of 20 degrees was present without diplopia. The dilated left pupil contracted slightly on adduction attempt. The palpebral aperture was 9 mm, with an upper lid excursion of 5 mm. Ductions from the primary position were adduction, none; abduction, 20 degrees; elevation, 10 degrees; depression, 15 degrees. There was no active medial rectus force. The medial, inferior, and superior rectus muscles and the superior oblique were atrophic on MRI scan. At surgery, the tight lateral rectus was detached from the eye and anchored to the lateral orbital wall. The tight lateral conjunctiva was recessed. The medial rectus was just a thread of fibrous tissue. A 6-0 polypropylene suture was used to suture the medial rectus insertion to the posterior lacrimal crest and tightened to bring the eye into 10 degrees of esotropia at the end of surgery. The eye gradually moved laterally over the first few months after operation; it has remained at 5 degrees of exotropia for 2 years.

### Case 3

A boy aged 4 years old fell from the third floor onto the street sidewalk with resulting hemiparesis and right third cranial nerve paralysis. A frontalis sling operation was performed on the right upper lid 2 months after the injury to prevent amblyopia. Six months after the accident, the right eye position was 45 degrees exotropia and 10 degrees hypotropia (fig 2). There was no adduction or vertical movement. Lateral rectus disinsertion and reattachment to the orbital rim was performed, together with superior oblique tenotomy and medial rectus resection of 12 mm. The medial rectus was sutured 6 mm superior to the original horizontal line of insertion. Eighteen months postoperatively the right eye



**Figure 3** Case 3, postoperative alignment and horizontal rotations.

position was 3–4 degrees of hypotropia (fig 3) There was 20 degrees of horizontal movement, showing that this was no longer a complete third cranial nerve paralysis.

### Case 4

A 54 year old man had right congenital third cranial nerve paralysis. The right eye was amblyopic with exotropia of 45 degrees. There was no adduction movement beyond the midline. On abduction the right upper lid elevated slightly and on attempted depression, intorsion combined with abduction was seen. The right fundus was intorted. At surgery the right lateral rectus was disinserted and sutured to the orbital margin using 6/0 Mersilene suture. The right superior oblique tendon was transposed to the upper margin of the medial rectus insertion. Postoperatively, the right eye position was 9 degrees of exotropia and 10 degrees of hypertropia. At a second operation, passive infraduction was restricted. The superior oblique tendon was disinserted. The inferior oblique muscle was resected 5 mm and sutured to the sclera just anteriorly and temporally to the inferior rectus insertion. The right medial rectus was resected 10 mm. The lateral rectus was explored to ascertain that no reattachment to the globe occurred. A year postoperatively the right eye position was 6 degrees of exotropia and 5 degrees of hypertropia. Ductions were limited to a few degrees.

### Case 5

A 56 year old woman complained of diplopia and of a head turn to the right. She had undergone three previous strabismus operations for her Duane syndrome with left exotropia; each included a left lateral rectus recession. She fused in 15 degrees left gaze. In the primary position there was 15 degrees of exotropia. She could adduct the left eye 5 degrees and abduct 25 degrees. Enophthalmos of 2 mm and hypertropia (“upshoot”) occurred with adduction. Right eye motility was normal. At surgery on the left eye there was restriction to passive adduction. The lateral rectus was found attached to the sclera in scar tissue 20 mm from the limbus. It was sutured near its insertion and detached from the globe. Passive adduction was improved. The lateral rectus was sutured to the lateral periosteum. The lateral halves of the

superior and the inferior rectus muscles were detached and sutured near the lateral rectus insertion. The medial rectus was resected 6 mm on an adjustable suture. Postoperatively, 3 degrees of left exotropia remained. The left eye could abduct 10 degrees and adduct 10 degrees. Enophthalmos on adduction was gone. The improved status has been stable for 4 years.

## DISCUSSION

There are many cases involving paralysis of the eye muscles in which alignment is the overriding goal. We concur with others that in third cranial nerve paralysis even a dramatically recessed lateral rectus will take up slack and, via posterior orbital connections, abduct the eye over time. The solution offered here is to tie the muscle to the orbit so that its force is dissipated there and so that it cannot shorten; in effect, giving up motility for alignment. Another approach along this line is to further weaken the lateral rectus muscle by partial excision.<sup>11</sup> This was not permanently effective in that report, or in our own experience. Complete lateral rectus muscle excision would surely work, but is very invasive.<sup>12</sup> Anchoring the eye medially using orbital fascia or fascia lata graft was effective, but surgically demanding and invasive.<sup>9-10</sup> Tenotomy of the superior oblique tendon removes a source of abduction, and its reinsertion medially stabilises the eye. While rather simple to do, this results in hypertropia in some cases.<sup>2-4</sup> Transposition of the lateral rectus muscle to the medial rectus insertion area was suggested by Taylor.<sup>7</sup> In such a case done by one of us, exotropia recurred, and the procedure is demanding.<sup>8</sup> Once the lateral rectus is disabled, some tissue or suture must hold the eye nasally. Our cases show that the resected medial rectus muscle, the transposed superior and inferior rectus muscles, and suturing the eye from the medial rectus insertion to the medial orbit can all serve this function. As seen in case 5, the technique is effective in removing the abnormal lateral rectus activity in Duane syndrome with exotropia. The reduction of eye movement from this procedure is variable. Useful horizontal motility resulted in case 3 from slight reinnervation of the medial rectus giving a small amount of adduction, combined with a small amount of abduction, probably from force transmitted via posterior connections of the lateral rectus through Tenon tissues. Very little movement remained in

case 1, making binocular fusion difficult even when alignment was attained. The procedure is potentially reversible, though we have no experience of such reversal. Extension of this principle to other extraocular muscles seems practical.

## Authors' affiliations

**Y Morad**, Pediatric Ophthalmology Service, Assaf Harofeh Medical Center, Tel-Aviv University, Zrifin, Israel

**L Kowal**, Centre for Eye Research Australia and Ocular Motility Clinic, Royal Victorian Eye and Ear Infirmary, Melbourne, Australia

**A B Scott**, Smith-Kettlewell Eye Research Institute, San Francisco, CA, USA

Supported in part by National Institutes of Health, National Eye Institute, under award number R01 EY12216, and by Pacific Vision Foundation.

Correspondence to: Alan B Scott, MD, Smith-Kettlewell Eye Research Institute 2318 Fillmore Street, SF, CA 94115, USA; [abs@ski.org](mailto:abs@ski.org)

Accepted for publication 16 December 2004

## REFERENCES

- 1 Metz HS. 20th annual Frank Costenbader Lecture—muscle transposition surgery. *J Pediatr Ophthalmol Strabismus* 1993;**30**:346–53.
- 2 Saunders RA, Rogers GL. Superior oblique transposition for third nerve palsy. *Ophthalmology* 1982;**89**:310–6.
- 3 Reinecke RD. Superior oblique surgery. *Am Orthopt J* 1974;**24**:23–6.
- 4 Scott AB. Transposition of the superior oblique. *Am Orthopt J* 1977;**27**:11–14.
- 5 Callahan A. The arrangement of the conjunctiva in surgery for oculomotor paralysis and strabismus. *Arch Ophthalmol* 1961;**66**:241–6.
- 6 Kaufmann H. Lateralis splitting in total oculomotor paralysis with trochlear nerve paralysis. *Fortschr Ophthalmol* 1991;**88**:314–16.
- 7 Taylor JN. Surgical management of oculomotor nerve palsy with lateral rectus transplantation to the medial side of globe. *Aust N Z J Ophthalmol* 1989;**17**:27–31.
- 8 Morad Y, Nemet P. Medial transposition of the lateral rectus muscle in combined third and fourth nerve palsy. *J AAPOS* 2000;**4**:246–7.
- 9 Goldberg RA, Rosenbaum AL, Tong JT. Use of apically based periosteal flaps as globe tethers in severe parietic strabismus. *Arch Ophthalmol* 2000;**118**:431–7.
- 10 Salazar-Leon JA, Ramirez-Ortiz MA, Salas-Vargas M. The surgical correction of paralytic strabismus using fascia lata. *J Pediatr Ophthalmol Strabismus* 1998;**35**:27–32.
- 11 Sato M, Maeda M, Ohmura T, et al. Myectomy of lateral rectus muscle for third nerve palsy. *Jpn J Ophthalmol* 2000;**44**:555–8.
- 12 Sinskey RM, Eshete A. Maximal subtotal extirpation of the horizontal rectus extraocular muscles for the treatment of nystagmus with no null point. *Binocular Vision and Strabismus Quarterly* 2002;**17**:297–303.



## Lateral rectus muscle disinsertion and reattachment to the lateral orbital wall

Y Morad, L Kowal and A B Scott

*Br J Ophthalmol* 2005 89: 983-985  
doi: 10.1136/bjo.2004.051219

---

Updated information and services can be found at:  
<http://bjo.bmj.com/content/89/8/983.full.html>

---

*These include:*

### References

This article cites 10 articles, 1 of which can be accessed free at:  
<http://bjo.bmj.com/content/89/8/983.full.html#ref-list-1>

### Email alerting service

Receive free email alerts when new articles cite this article. Sign up in the box at the top right corner of the online article.

---

### Topic Collections

Articles on similar topics can be found in the following collections

[Muscles](#) (184 articles)  
[Neurology](#) (1042 articles)

---

### Notes

---

To request permissions go to:  
<http://group.bmj.com/group/rights-licensing/permissions>

To order reprints go to:  
<http://journals.bmj.com/cgi/reprintform>

To subscribe to BMJ go to:  
<http://group.bmj.com/subscribe/>