

SCIENTIFIC REPORT

Genetic and phenotypic heterogeneity in pattern dystrophy

P J Francis, D W Schultz, A M Gregory, M B Schain, R Barra, J Majewski, J Ott, T Acott, R G Weleber, M L Klein

Br J Ophthalmol 2005;89:1115–1119. doi: 10.1136/bjo.2004.062695

Background: The pattern dystrophies (PD) represent a clinically heterogeneous family of inherited macular diseases frequently caused by mutations in the *peripherin/RDS* gene. Most previous studies have detailed the clinical findings in single families, making it difficult to derive data from which progression and visual outcome can be generalised.

Methods: Families were ascertained and clinically evaluated including angiography and electrophysiology where appropriate.

Results: In each of the six families with autosomal dominant PD, a mutation in the *peripherin/RDS* gene was identified, including a novel Cys250Phe variant. These data suggest that the condition is characterised by the accumulation of yellow to grey subretinal flecks, followed by pigmentary change accompanied by patches of chorioretinal atrophy. Subsequently, 50% (16/32) of individuals with PD developed poor central vision because of chorioretinal geographic atrophy or subretinal neovascularisation. The risk of these complications appears to increase with age.

Conclusion: PD should not necessarily be considered a benign condition. Instead, patients should be counselled that there is a significant chance of losing central vision in their later years. Some elderly patients with probands showing PD may be misdiagnosed with age related macular degeneration owing to the phenotypic similarities between these conditions in the advanced state.

Pattern dystrophy (PD) is a dominantly inherited macular disease characterised by the accumulation of lipofuscin at the level of the retinal pigment epithelium.¹ Considerable phenotypic variability has been reported and names attributed to the condition.² Mutations in the *peripherin/RDS* gene are a frequent cause of PD³ as well as other inherited retinal dystrophies.⁴

Although several authors have suggested that PD is relatively benign,^{5–6} some reports describe families in which late vision loss occurs because of pigment epithelial atrophy or choroidal neovascularisation.^{1,7,8} Most accounts detail clinical findings in single families, making it difficult to generalise about progression and visual outcome in PD. In this paper, we report the phenotypic characterisation of six families with molecularly confirmed pattern dystrophy.

MATERIALS AND METHODS

PD pedigrees were identified and examined during the course of collecting families for a genetic study of macular degeneration in the United States. The diagnosis was made in those with yellow, gold, grey, or black subretinal deposits arranged in fleck-like, branching, round, or irregular plaque-like patterns centred about the fovea bilaterally. Patterns were usually most easily discerned in younger family members. Drusen were usually absent. Further investigations

were undertaken as necessary. Mutational analyses were performed on DNA collected from family members.

RESULTS

The six families (median age 61, range 36–91) with PD are shown in figure 1. Autosomal dominant inheritance was supported by affected individuals in consecutive generations, equal numbers of affected males and females, and evidence of male to male transmission (except family D). Figure 1 shows abridged pedigrees.

Phenotype examples are shown in figure 2. A segregating heterozygous mutation in the *peripherin/RDS* gene was identified in each family.

Family A (mutation, *peripherin/RDS* Cys250Phe)

The dystrophy was characterised by discrete yellow-white subretinal lesions of varying size throughout the macula with some involvement nasal to the disc. Subretinal pigment accumulation was also evident close to the fovea. Older individuals had atrophic depigmented lesions or evidence of previous subretinal neovascularisation.

Family B (*peripherin/RDS* Tyr141Cys)

The subretinal deposits were smaller and more widely spaced than family A. Some individuals had patterned, pigmented shapes centred on the fovea. Individual 109 had retinitis pigmentosa and 1002 had a vitelliform-like subfoveal lesion in one eye.

Families C-F (*peripherin/RDS* IVS2+3A→T)

By contrast, the maculae of affected individuals in these families showed only a few yellow-white or pigmented subretinal deposits in a parafoveal distribution. In some, the deposits formed figures. Small areas of atrophy were also present. Family F comprised two individuals. Both had large patterns centred on the fovea with atrophy.

Phenotype progression

We did not perform a longitudinal assessment of phenotypic progression. Instead, we evaluated individuals from each generation. Overall, good acuity was usually retained until the end of the sixth decade. Thereafter, significant central visual loss was observed, down to the counting fingers level bilaterally and correlated with phenotype progression (figs 3 and 4). Phenotype progression was grouped into three age groups.

Aged 30–49 years (nine individuals)

These younger individuals were likely to have discrete yellow or grey deposits in subretinal figures or patterns. None had developed either geographic atrophy (GA), defined as a sharply demarcated area of pigment epithelial atrophy

Abbreviations: AMD, age related macular degeneration; CNV, choroidal neovascularisation; GA, geographic atrophy; PD, pattern dystrophies

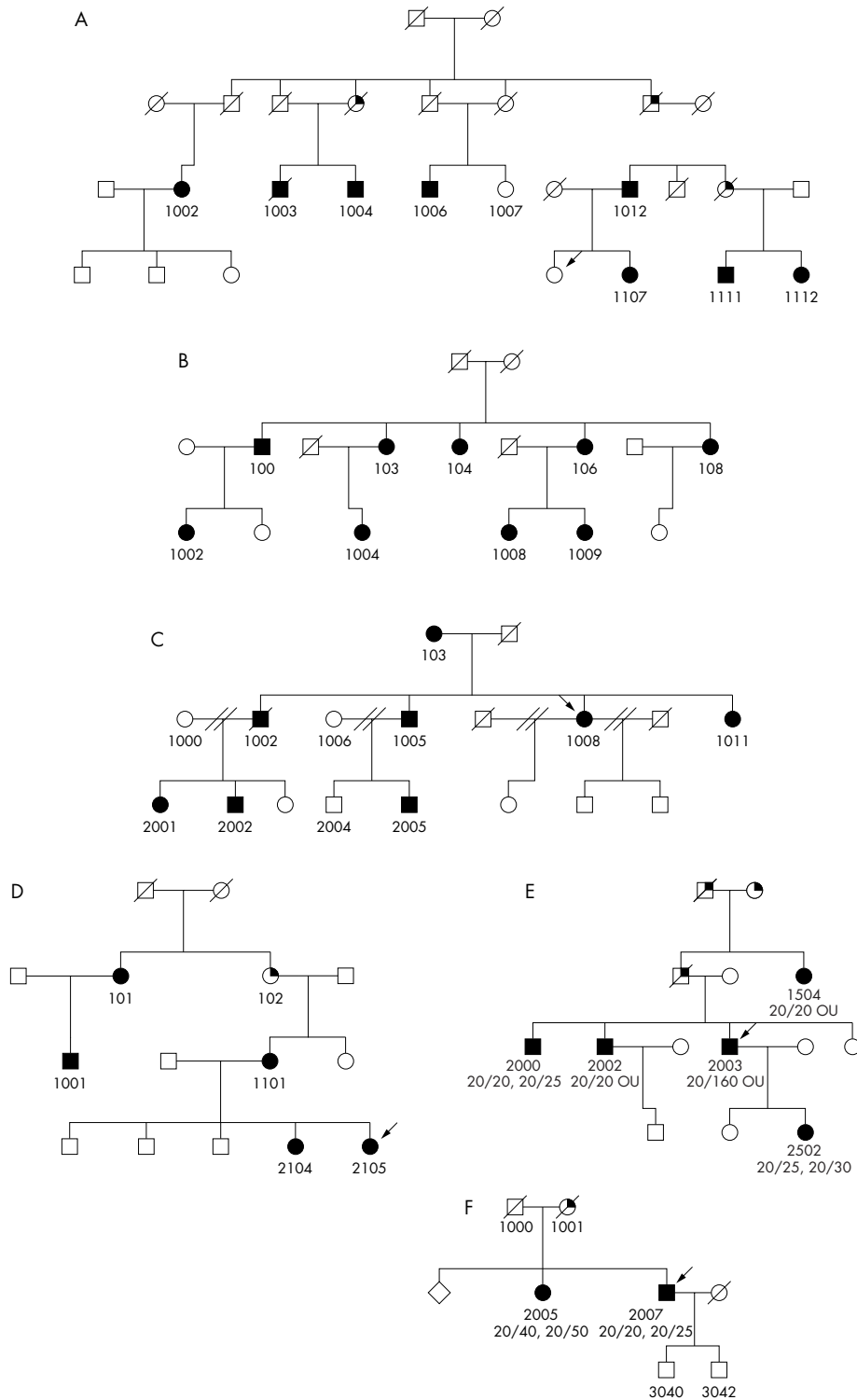


Figure 1 Abridged pedigrees of families A to F, showing individuals who participated in the study. Solid, open, and scored symbols indicate affected, unaffected, and deceased individuals, respectively. Probands are marked with arrows. Pedigree identification numbers correspond with those in figures 2, 3, and 4.

through which choroidal vessels were visible, or choroidal neovascularisation (CNV). Only two of nine affected had worse vision than 20/40.

Aged 50–69 years (13 individuals)

Pigment figures tended to be more extensive. Mild pigment epithelial atrophy was common, and was present in five of 13 affected, usually associated with some fading of the pigment epithelial deposit. GA was present in five individuals; CNV in

one; and CNV and GA in the fellow eye of was present in one eye and GA in the other eye of one individual.

Aged 70–91 years (16 individuals)

Nearly all eyes had developed some degree of pigment epithelial atrophy. CNV and GA occurred frequently, with the latter becoming more extensive and associated with more profound vision loss. Four of 16 individuals had geographic atrophy, and five of 16 had CNV. Only three of 16 maintained

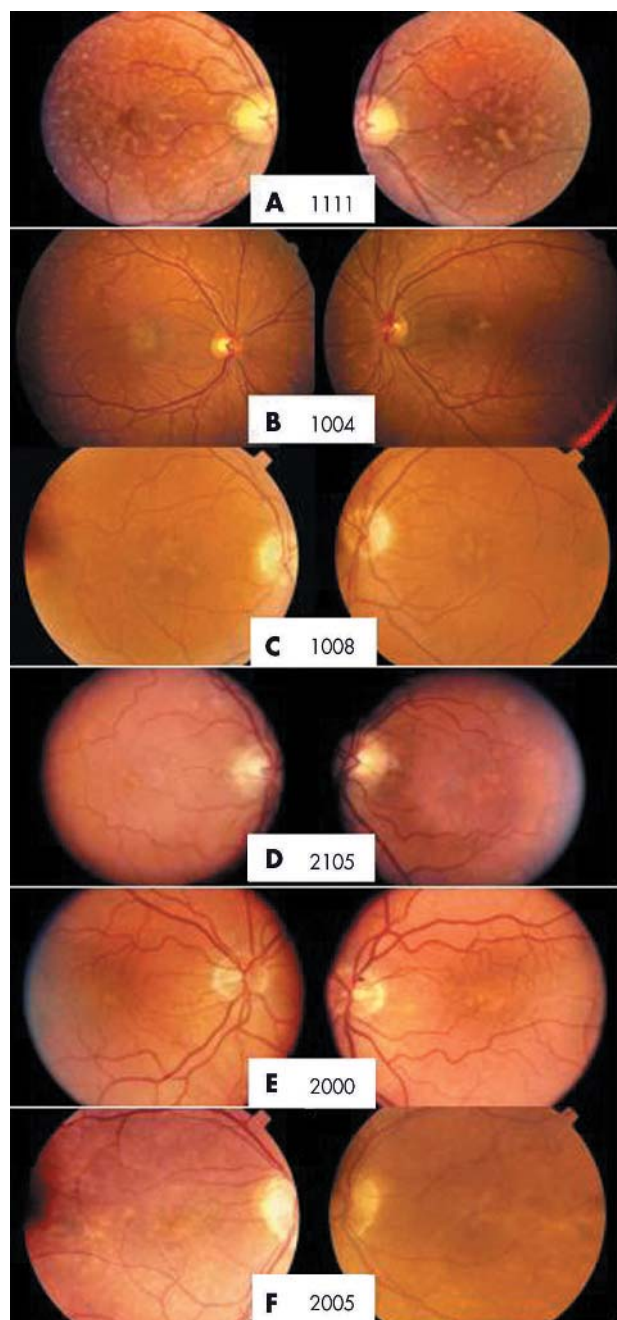


Figure 2 Colour fundus photographs of a representative (numbered) from each family (A–F) with pattern dystrophy.

better than 20/40 or better vision in both eyes, while seven individuals had significant visual impairment of less than 20/40 in both eyes.

DISCUSSION

Molecular genetic studies have contributed significantly to defining the clinical entity that is PD. Peripherin/RDS mutations have been found in a significant number of families with the condition; however, genetic heterogeneity is known.^{9–11} The heterozygous peripherin/RDS-Cys250Phe mutation segregating in family A is novel. Experimentally, substitution of this conserved residue prevents a disulfide bond forming interfering with normal protein folding.¹² The mutation, Tyr141Cys found in family B, has been described in a single family with a late onset dominant macular

dystrophy.¹³ Our remaining four pedigrees all shared the same splice site mutation, although by haplotype analysis, the families are not closely related. This mutation, peripherin/RDS IVS2+3A→T, presumably reflects therefore a “hotspot” within the gene and has previously been reported to cause autosomal dominant retinal degeneration.^{14 15}

Previous authors have addressed the progression of the PD phenotype,¹⁶ however usually in single families. Some have considered that PD causes only mild visual disability,^{5–7 17 18} while others have documented families in whom visual loss appears more marked.^{7 8}

Although this was not a longitudinal study, we had the opportunity to clinically evaluate individuals in all families across a wide spectrum of ages. An age dependent pattern of phenotype progression was evident. Individuals under 50 years of age generally had smaller and less widespread changes. These usually were present as subretinal pigment deposits in the form of figures or patterns and were sometimes accompanied by mild pigment epithelial atrophy. Vision was normal or mildly impaired. In individuals over 50 years of age, these lesions developed increasing pigment epithelial atrophy and became more complex and widespread. Visual loss in at least one eye was common. GA or CNV occurred with increasing frequency and severity, accompanied by significant visual loss.

The severity of the disease in older individuals was surprising. The more advanced stages of macular degenerative disease (GA and CNV) were present in 42% (16/38) of all affected individuals, with GA present in 26% (10/38) and CNV in 18% (7/38). After age 70, severe vision loss was common, with 50% (eight of 16) of individuals becoming legally blind (20/200 or less) in at least one eye and 19% (three of 16) losing vision in both eyes.

Selection bias must be considered in view of the fact that these families were identified as part of an effort to recruit families with age related macular degeneration (AMD). It is conceivable that our PD families may have been biased toward those with older members and particularly towards those with advanced macular disease resembling AMD. We therefore reviewed the literature for previous reports of molecularly confirmed PD that provided detailed phenotype information. We identified eight reports describing 10 such families.^{1 3 8 13 19–22} These families were comparable to ours by the presence of advanced macular changes and the incidence of significant visual loss. Of the total of 53 affected individuals in these families, 38% had advanced macular changes of GA and/or CNV, with GA present in 25% and CNV in 15%. In the nine individuals more than 70 years old, vision loss to 20/200 or less in at least one eye was present in 67%, including 44% in both eyes. From these data, we conclude that our families are comparable to other PD families with peripherin/RDS mutations.

In addition, the different peripherin/RDS mutations may exert an influence on phenotype. In the four families (C–F) with the splice site mutation, earlier stages of the disease were characterised by round spots of variable pigmentation and hypopigmentation. These progressed to more confluent lesions, often assuming a branch-like configuration with increasing RPE atrophy. A family with this same splice site mutation¹⁹ has been reported with macular RPE degenerative changes and yellow flecks.

In family B (Tyr141Cys), there was marked phenotypic heterogeneity. One individual had retinitis pigmentosa and others had yellow subfoveal plaques. This family also had the highest incidence of CNV (three of 10 affected individuals) similar to another family with this mutation.¹³ Although these authors did not designate their family as having PD, we think that both families have features in common that are similar to those found in other families with this diagnosis.

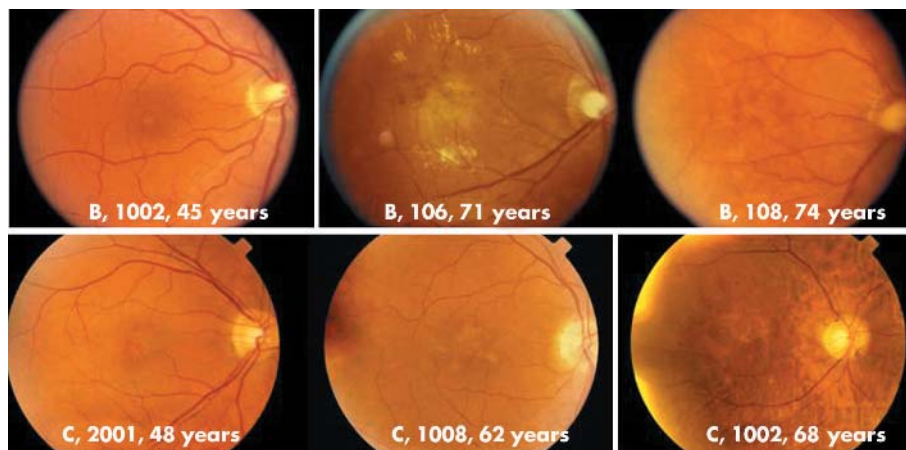


Figure 3 Colour fundus photographs of individuals from families B and C showing phenotypic progression with advancing years often complicated by choroidal neovascularisation. Numbers correspond to pedigree identification numbers in figure 1.

AMD can be indistinguishable from the late appearances of PD since drusen often become less prominent or disappear in advanced stages of the disease. Furthermore, some patients with PD have deposits resembling drusen or in fact might have age related drusen. Therefore, a small proportion of older individuals with PD may be misdiagnosed with AMD. Since six of the 120 families (5%) collected in the genetics of the AMD study were initially thought to have AMD by family members and their ophthalmologists, a similar prevalence of PD may exist among AMD patients with a family history of macular degenerative disease.

We conclude that intra-familial clinical heterogeneity is largely the result of age dependent phenotype progression. PD is also not necessarily visually benign. Progression often results in significant impairment and legal blindness in its advanced stages. Thus, individuals may be informed that the prognosis is good for retention of useful vision in at least one eye before age 70, but that the likelihood of significant visual impairment in both eyes increases in later years.

ACKNOWLEDGEMENTS

This work is supported in part by US PHS Grant 5 M01 RR000334, by an unrestricted grant from the RPB, the Foundation Fighting Blindness NIH EY012203 (MLK), and the Macular Degeneration Centre Research Fund. Fellowship grant funding to PJF was from the Royal College of Ophthalmologists and the TFC Frost Charitable Trust.

Authors' affiliations

P J Francis, D W Schultz, A M Gregory, M B Schain, R Barra, T Acott, R G Weleber, M L Klein, Macular Degeneration Center, Casey Eye Institute, Oregon Health and Science University, 3375 SW Terwilliger Blvd, Portland, OR 97239-4197, USA
P J Francis, Guy's and St Thomas's Hospital, Lambeth Palace Road, London SE1 7EH, UK
J Majewski, J Ott, Rockefeller University, 1230 York Avenue, New York, NY 10021-6399, USA

Correspondence to: Michael Klein, MD, Casey Eye Institute, Oregon Health and Science University, 3375 SW Terwilliger Blvd, Portland, OR 97239-4197, USA; kleinm@ohsu.edu

Accepted for publication 6 February 2005

REFERENCES

- Zhang K, Garibaldi DC, Li Y, et al. Butterfly-shaped pattern dystrophy: a genetic, clinical, and histopathological report. *Arch Ophthalmol* 2002;**120**:485-90.
- Aaberg TM, Han DP. Evaluation of phenotypic similarities between Stargardt flavimaculatus and retinal pigment epithelial pattern dystrophies. *Trans Am Ophthalmol Soc* 1987;**85**:101-19.
- Grover S, Fishman GA, Stone EM. Atypical presentation of pattern dystrophy in two families with peripherin/RDS mutations. *Ophthalmology* 2002;**109**:1110-17.
- Souied EH, Rozet JM, Gerber S, et al. Two novel missense mutations in the peripherin/RDS gene in two unrelated French patients with autosomal dominant retinitis pigmentosa. *Eur J Ophthalmol* 1998;**8**:98-101.
- Lim J, Enger C, Fine S. Foveomacular dystrophy. *Am J Ophthalmol* 1994;**117**:1-5.
- Watzke RC, Folk JC, Lang RM. Pattern dystrophy of the retinal pigment epithelium. *Ophthalmology* 1982;**89**:1400-6.
- Marmor MF, McNamara JA. Pattern dystrophy of the retinal pigment epithelium and geographic atrophy of the macula. *Am J Ophthalmol* 1996;**122**:382-92.
- Yang Z, Lin W, Moshfeghi D, et al. A novel mutation in the RDS/peripherin gene causes adult-onset foveomacular dystrophy. *Am J Ophthalmol* 2003;**135**:213-18.
- Van Lith-Verhoeven JJ, Cremers FP, van den Helm B, et al. Genetic heterogeneity of butterfly-shaped pigment dystrophy of the fovea. *Mol Vis* 2003;**9**:138-43.
- Weigell-Weber M, Kryenbuhl C, Buchi ER, et al. Genetic heterogeneity in autosomal dominant pattern dystrophy of the retina. *Mol Vis* 1996;**2**:6.
- Daniele S, Carbonara A, Daniele C, et al. Pattern dystrophies of the retinal pigment epithelium. *Acta Ophthalmol Scand* 1996;**74**:51-5.
- Goldberg AF, Loewen CJ, Molday RS. Cysteine residues of photoreceptor peripherin/rds: role in subunit assembly and autosomal dominant retinitis pigmentosa. *Biochemistry* 1998;**37**:680-5.

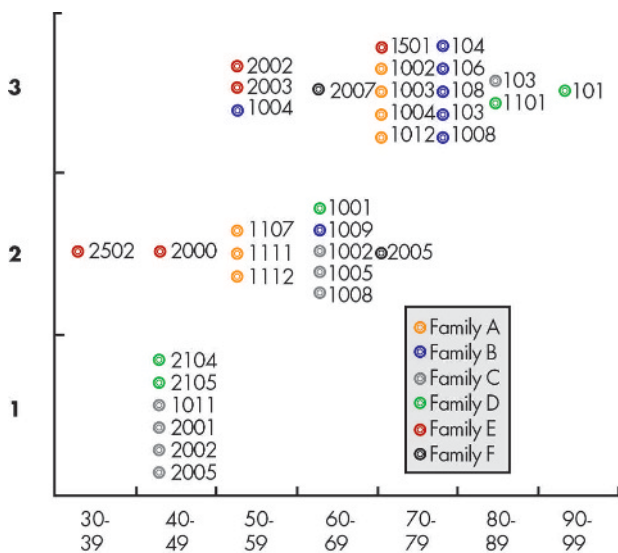


Figure 4 Schematic showing stage of disease progression with age in each family. Numbers correspond to pedigree identification numbers in figure 1. Stage 1 (early disease): spots of subretinal deposits, minimal pigmentary changes, no atrophy or choroidal neovascularisation (CNV). Stage 2: larger accumulations of deposits, pigment figures, and/or small atrophic areas, no CNV. Stage 3 (advanced disease): extensive atrophy and/or CNV.

- 13 **Khani SC**, Karoukis AJ, Young JE, *et al*. Late-onset autosomal dominant macular dystrophy with choroidal neovascularization and nonexudative maculopathy associated with mutation in the RDS gene. *Invest Ophthalmol Vis Sci* 2003;**44**:3570–7.
- 14 **Sullivan L**, Guilford S, Birch D, *et al*. A novel splice site mutation in the gene for peripherin/RDS causing autosomal dominant retinal degeneration. *Invest Ophthalmol Vis Sci* 1996;**37**:S1145.
- 15 **Sohocki M**, Daiger S, Bowne S, *et al*. Prevalence of mutations causing retinitis pigmentosa and other inherited retinopathies. *Hum Mutat* 2001;**17**:42–51.
- 16 **Thomann U**, Buchi ER, Suppiger M, *et al*. Age-dependent phenotypic expression of a pattern dystrophy of the retina. *Eur J Ophthalmol* 1995;**5**:107–12.
- 17 **Saatci AO**, Yasti ZO, Kose S, *et al*. Butterfly-like pattern dystrophy and unilateral choroidal neovascularization. *Acta Ophthalmol Scand* 1998;**76**:734–6.
- 18 **Sabates R**, Pruett R, Hirose T. Pseudovitelliform macular degeneration. *Retina* 1982;**2**:197–205.
- 19 **Sears JE**, Aaberg TA Sr, Daiger SP, *et al*. Splice site mutation in the peripherin/RDS gene associated with pattern dystrophy of the retina. *Am J Ophthalmol* 2001;**132**:693–9.
- 20 **Fossarello M**, Bertini C, Galantuomo MS, *et al*. Deletion in the peripherin/RDS gene in two unrelated Sardinian families with autosomal dominant butterfly-shaped macular dystrophy. *Arch Ophthalmol* 1996;**114**:448–56.
- 21 **Kim RY**, Dollfus H, Keen TJ, *et al*. Autosomal dominant pattern dystrophy of the retina associated with a 4-base pair insertion at codon 140 in the peripherin/RDS gene. *Arch Ophthalmol* 1995;**113**:451–5.
- 22 **Weleber RG**, Carr RE, Murphey WH, *et al*. Phenotypic variation including retinitis pigmentosa, pattern dystrophy, and fundus flavimaculatus in a single family with a deletion of codon 153 or 154 of the peripherin/RDS gene. *Arch Ophthalmol* 1993;**111**:1531–42.



Genetic and phenotypic heterogeneity in pattern dystrophy

P J Francis, D W Schultz, A M Gregory, et al.

Br J Ophthalmol 2005 89: 1115-1119

doi: 10.1136/bjo.2004.062695

Updated information and services can be found at:

<http://bjo.bmj.com/content/89/9/1115.full.html>

References

These include:

This article cites 22 articles, 5 of which can be accessed free at:

<http://bjo.bmj.com/content/89/9/1115.full.html#ref-list-1>

Article cited in:

<http://bjo.bmj.com/content/89/9/1115.full.html#related-urls>

Email alerting service

Receive free email alerts when new articles cite this article. Sign up in the box at the top right corner of the online article.

Topic Collections

Articles on similar topics can be found in the following collections

[Macula](#) (24 articles)

[Public health](#) (377 articles)

[Retina](#) (1207 articles)

Notes

To request permissions go to:

<http://group.bmj.com/group/rights-licensing/permissions>

To order reprints go to:

<http://journals.bmj.com/cgi/reprintform>

To subscribe to BMJ go to:

<http://group.bmj.com/subscribe/>