



## Photodynamic therapy with verteporfin in paediatric and young adult patients: long-term treatment results of choroidal neovascularisations

A Lipski, N Bornfeld and B Jurklies

*Br J Ophthalmol* 2008 92: 655-660 originally published online March 20, 2008  
doi: 10.1136/bjo.2007.134429

---

Updated information and services can be found at:

<http://bjo.bmj.com/content/92/5/655.full.html>

---

*These include:*

### References

This article cites 39 articles, 6 of which can be accessed free at:

<http://bjo.bmj.com/content/92/5/655.full.html#ref-list-1>

### Email alerting service

Receive free email alerts when new articles cite this article. Sign up in the box at the top right corner of the online article.

---

### Topic collections

Articles on similar topics can be found in the following collections

[Choroid](#) (371 articles)

[Editor's choice](#) (495 articles)

---

### Notes

---

To order reprints of this article go to:

<http://bjo.bmj.com/cgi/reprintform>

To subscribe to *British Journal of Ophthalmology* go to:

<http://bjo.bmj.com/subscriptions>

# Photodynamic therapy with verteporfin in paediatric and young adult patients: long-term treatment results of choroidal neovascularisations

A Lipski, N Bornfeld, B Jurklies

Department of Ophthalmology,  
University Hospital Essen, Essen,  
Germany

Correspondence to:  
Dr A Lipski, Department of  
Ophthalmology,  
Universitätsklinikum Essen,  
Hufelandstraße 55, D-45122  
Essen, Germany; andreas.  
lipski@uni-duisburg-essen.de

Accepted 20 January 2008  
Published Online First  
20 March 2008

## ABSTRACT

**Background:** Vision impairment in children and young adults may derive from choroidal neovascularisation (CNV) related to numerous conditions. The aim of this study is to highlight the applicability of photodynamic therapy using verteporfin (PDT) in these patients.

**Methods:** In 16 eyes of 16 consecutive patients aged 30 years or younger, prospective open-label PDT was performed. Outcomes of visual acuity as well as changes in CNV lesion parameters were evaluated.

**Results:** The mean patient age at first PDT was 19.7 (SD 8.7) years (range 6–30). 81% of the patients retained stable vision within two lines or exceedingly improved vision during follow-up of 34 (24) months. Significant vision gain was denoted in seven paediatric patients (2.7 (1.4) lines, mean (SD);  $p = 0.019$ ) as well as in a subgroup of 12 patients not affected by active uveitis (2.6 (2.0) lines,  $p = 0.0005$ ). Two patients with multifocal choroiditis and panuveitis (MCP) experienced vision losses of five and 11 lines after four PDT sessions despite receiving additional steroidal treatment. Except for one patient with MCP and two patients who dismissed follow-up, a mean of 2.2 (1.3) PDTs per patient sufficiently inactivated CNV lesions during follow-up. In the area of the former PDT spot, alterations of the pigment epithelium increased by 40% without correlation to changes in vision.

**Conclusions:** The results indicate good PDT efficacy and tolerability most promising in a subgroup of patients with vision-impairing CNV not associated with active uveitis. PDT in young patients with CNV remains a valuable treatment with good risk–benefit profile over the long term.

Choroidal neovascularisation (CNV) may develop in children and young adults due to pathological myopia, the presumed ocular histoplasmosis syndrome (POHS), retinchoroiditis as well as secondary to angioid streaks, trauma or idiopathically.<sup>1–3</sup> Within these disease groups, healing and treatment responses may be influenced by age-dependent mechanisms.<sup>4</sup> A therapy proven in adults could therefore be expected to be either less or even more effective in young individuals. It may thus be valuable to separately prove the effectiveness of CNV treatment in patients younger than 30 years of age.<sup>4–6</sup>

Among the approaches of CNV treatment, laser photocoagulation and photodynamic therapy with verteporfin (PDT) besides surgical CNV extraction have currently been considered.<sup>7–15</sup> More recently, intravitreal injections of agents antagonising the binding activity of the vascular endothelial growth

factor family have been extending the therapeutic armament.<sup>16–19</sup>

Perspectives for young patient care must exceedingly focus on healing strategies. This implies the proposition of CNV inactivation by means of maximum efficacy and avoidance of procedure-related risks. Photodynamic therapy using verteporfin in adults is a well-established and safe treatment for CNV related to various causes.<sup>4 7 13 20–25</sup> Probably due to the overall low incidence of CNV in young patients, the efficacy and safety of PDT in paediatric or young adult patients have been subject to analysis in only a few reports so far.<sup>5 6 15</sup> In this prospective interventional open-label study, we followed courses of PDT treatment over the long term to verify its applicability in paediatric and younger patients with CNV.

## PATIENTS AND METHODS

We analysed CNV treatment courses of patients younger than 31 years of age at initial PDT treatment in our clinic between 1999 and 2006. Active CNV leakage and symptomatic vision impairment had to be present before the first PDT. No further exclusion criteria regarding vision or CNV localisation were implemented. We excluded eyes with previously performed laser photocoagulation. PDT-treated patients secondary to angioma formation and CNV due to angioid streaks were not eligible to follow-up, as either outcomes have already been described separately or patients were beyond the age of 30 years at initial treatment.<sup>25 26</sup> The diagnosis of CNV secondary to toxoplasmic chorioretinitis was guided by ophthalmoscopic and angiographic detection of CNV adjacent to “punched out” pigmented atrophic chorioretinal scars. Serological verification of toxoplasmosis as a cause of CNV was performed in two out of 16 patients using ELISA (IgG > 100 U/ml).

Ophthalmological examination included best-corrected visual acuity testing, tonometry, ophthalmoscopy, photography and fluorescein angiography using standard techniques. Best-corrected visual acuity (VA) was examined using Landolt optotypes at a distance of 5 m (Snellen, DIN 58220) and converted to log(MAR) for statistical analyses.

Measurements of linear lesion diameters were performed on standardised 30° printouts of respective HRA II-angiograms (Heidelberg Engineering, Heidelberg, Germany).<sup>27</sup> Parameters of angiographic lesion identification and measurement

## Clinical science

included the greatest linear dimension measure (GLD), which encompasses the wet lesion borders including haemorrhages, pigment epithelial detachment as well as CNV with its hypofluorescent margins or, if present, scarring, respectively.<sup>27</sup> Additionally, the pigment epithelial lesion diameter (PLD) outlines any homogenous area of dry stippled or plane angiographic hyperfluorescence due to pigment epithelial atrophy which may be interspersed by fine mottling of pigmentation. The choroidal neovascular lesion diameter was indicated as CLD. It encounters the CNV lesion including its hypofluorescent margins during the early- or midphase angiogram. Classic CNV was characterised by a well-demarcated area of hyperfluorescence in the early phases with leakage through the mid and late phases which obscures the boundaries of this area.

PDT treatment was applied using the following conditions: after infusing Verteporfin (Visudyne, Novartis, Basel, Switzerland) intravenously over 10 min (6 mg/m<sup>2</sup> body surface area in a volume of 30 ml), 50 J/m<sup>2</sup> of light was applied using a 689 nm diode laser (Zeiss, Germany) at an intensity of 600 mW/cm<sup>2</sup> using a contact lens (Volk, Mentor, OH). The laser spot size was selected by adding a 500 µm safety diameter to fully cover the estimated GLD. Treatment was repeated after 3 months if fluorescein angiography revealed persistent leakage activity of the CNV.

Statistical evaluation was performed using a two-sided Student t test (level of significance = 5%). Values represent mean (SD) except otherwise indicated. Correlations were analysed using Pearson's method.

## RESULTS

Sixteen patients have been enrolled into the study. Nine patients exhibited CNV related to POHS, three patients had

CNV related to pathological myopia, and four patients showed CNV formation secondary to toxoplasmosis or multifocal choroiditis and panuveitis (MCP, table 1). The mean patient age at first PDT was 19.7 (8.7) years (range: 6–30). No injection site-related complications were recorded, and PDT was well tolerated. Only during fluorescein angiography did one patient develop mild allergic skin reactions after intravenous application of diagnostic fluorescein solution. Two patients of the POHS subgroup declined follow-up after 3 and 6 months because of personal preferences for alternative treatments (homeopathy and acupuncture). A pregnant patient with POHS declined PDT treatment as well as angiography. PDT treatment was again performed after ablation.

Figure 1A,B and table 1 show the courses of VA during the follow-up period of 34 (24) months (range: 3–85) and a mean number of 2.19 (1.3) PDT sessions. In the total cohort, longitudinal VA testing revealed a statistically insignificant increase from log(MAR) = 0.60 (0.35) before the first PDT to 0.49 (0.39) at the end of follow-up which was equal to a mean gain of 1.13 (4.10) lines ( $p = 0.1$ ,  $n = 16$ ). Improvement of vision of at least two lines was observed in 11 patients (69%), while two patients remained stable (12%). A decrease in VA was noted in three patients (19%) with a loss of 2, 5 and 11 lines, respectively.

Separate analysis of the seven paediatric patients (no. 1, 4, 7, 10, 12, 13, 14) in the different subgroups revealed statistically significant mean improvements of 2.7 (1.4) lines (from mean log(MAR) = 0.69 (0.43) to 0.43 (0.29),  $p < 0.02$ ) after 2.4 (1.3) PDT sessions and 37 (24) months follow-up. Patients with follow-up periods of longer than 24 months ( $n = 7$ ; no. 7, 8, 11, 12, 13, 15, 16) retained stable vision (from mean log(MAR) = 0.45 (0.25) to 0.48 (0.48),  $p = 0.9$ ) after 2.6 (1.6) PDT sessions and 56 (21) months follow-up.

**Table 1** Patient and lesion characteristics of the subgroups presumed ocular histoplasmosis syndrome (POHS) ( $n = 9$ ), multifocal choroiditis and panuveitis/toxoplasmosis ( $n = 4$ ) and myopia ( $n = 3$ )

Pt. no.	Gender	Eye	CNV location	CNV type	CNV cause	Follow-up (months)	Age (years)	PDT (no.)	Log(MAR)		ΔVA (lines)	PLD pre (µm)	PLD last (µm)	GLD pre (µm)	GLD last (µm)	CLD pre (µm)
									VA pre	VA last						
1	F	OD, B	Subfov	Class	POHS	18	11	3	0.7	0.3	4	1800	1800	1800	800	1800
2	F	OS	Juxtafov	Class	POHS	19	23	3	0.6	0.4	2	1400	2400	1400	2400	1400
3	F	OS, B	Subfov	Class	POHS	3	29	1	0.6	0.8	-2	2100	3000	4600	1600	2100
4	F	OD	Subfov	Class	POHS	18	8	1	1.5	1.0	3	3800	5400	3800	3800	3800
5	F	OD	Subfov	Class	POHS	18	29	1	0.3	0.0	2	850	1200	900	600	900
6	F	OD	Subfov	Class	POHS	6	24	1	0.9	0.7	2	2000	2500	3000	2500	2000
7	F	OD	Subfov	Class	POHS	85	6	2	1.0	0.5	6	3800	4100	3800	4100	4000
8	F	OS	Subfov	Class	POHS	62	28	1	0.5	0.0	5	1100	2780	1900	1900	1100
9	M	OD	Subfov	Class	POHS	23	18	2	1.0	0.7	3	800	1500	800	600	800
10	M	OS, B	Subfov	Class	Myopia	23	13	3	0.8	0.6	2	2600	2700	800	900	800
11	F	OS	Subfov	Class	Myopia	80	31	1	0.5	0.3	2	1700	2800	2000	1500	1200
12	M	OS, B	Extrafov	Class	myopia	35	15	1	0.2	0.0	2	1100	1100	1000	600	900
				$n = 12$	Mean (SD)	<b>32 (28)</b>	<b>19.9 (8.8)</b>	<b>1.7 (0.9)</b>	<b>0.76 (0.31)</b>	<b>0.48** (0.30)</b>	<b>2.6 (1.9)</b>	<b>1921 (985)</b>	<b>2607** (1171)</b>	<b>2150 (1274)</b>	<b>1775 (1169)</b>	<b>1733 (1062)</b>
13	F	OS	Subfov	Class	Toxo	59	10	5	0.3	0.3	0	2600	4000	3200	2200	2300
14	F	OD	Extrafov	Class	Toxo	23	13	2	0.3	0.3	0	1500	2800	3200	1100	1700
15*	M	OS	Subfov	Class	MCP	27	30	4	0.2	0.7	-5	900	3300	900	1800	900
16†	M	OS	Subfov	Class	MCP	41	28	4	0.4	1.5	-11	500	4000	800	4000	500
				$n = 16$	Mean (SD)	<b>34 (24)</b>	<b>19.7 (8.7)</b>	<b>2.2 (1.3)</b>	<b>0.60 (0.35)</b>	<b>0.49 (0.39)</b>	<b>1.1 (4.1)</b>	<b>1722 (864)</b>	<b>2836** (1118)</b>	<b>2119 (1251)</b>	<b>1963 (1387)</b>	<b>1625 (1300)</b>

Mean values (SD) are indicated in bold. Mean values of the total cohort ( $n = 16$ ) are shown below.

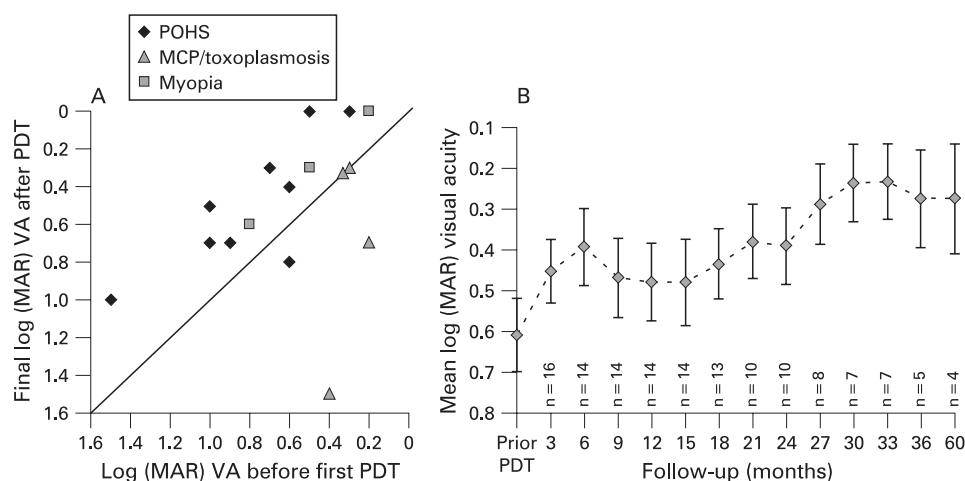
\*Patient 15 received systemic steroid treatment during 3 months after first PDT.

†Patient 16 received long-term systemic steroid treatment and one intravitreal injection the day after first PDT.

\*\* $p > 0.05$  (paired two-sided Student t test).

B, bilateral choroidal neovascularisation; class, classic CNV subtype; CLD, neovascularisation lesion dimension; CNV, choroidal neovascularisation; fov, foveal; GLD, greatest linear lesion dimension; M/F, male/female; OD/OS, study eye, oculus dexter/sinister; PLD, pigment epithelial lesion dimension; Pt. no., patient number; Toxo, toxoplasmosis; VA, visual acuity.

**Figure 1** (A) Log(MAR) visual acuity (VA) before treatment and at the end of observation (n = 16). The subgroups are separated by the indicated signs. (B) Changes in mean log(MAR) visual acuity during the follow-up period. Values represent the mean (SEM) and show increased vision during follow-up after a mean of 2.2 (1.3) photodynamic therapy using verteporfin (PDT) sessions per patient. For details, refer to table 1. MCP, multifocal choroiditis and panuveitis; POHS, presumed ocular histoplasmosis syndrome.



### POHS

In the POHS subgroup, VA increased statistically significantly from log(MAR) = 0.79 (0.33) before the first PDT to 0.49 (0.33) (+2.80 (2.15) lines) during follow-up of 28 (26) months ( $p = 0.0038$ ,  $n = 9$ ). Patients in this subgroup received 1.7 (0.8) PDT sessions during 28 (26) months (or 0.72 (0.38) PDTs per year). Three patients with POHS gained two lines of VA, two patients gained three lines, and three patients gained four to six lines at the end of follow-up. One patient lost two lines after one PDT session and denied further treatment, although the lesion still showed (reduced) leakage during angiography.

### Pathological myopia

In the subgroup of three patients with CNV due to pathological myopia, subjects unexceptionally gained two lines each. During the follow-up period of 46 (22) months, patients received a mean of 1.7 (1.3) PDTs (or 0.45 (0.66) PDTs per year).

After combined analysis of patients with CNV related to POHS and pathological myopia, vision after 33 (27) months increased, statistically significantly, by 2.6 (2.0) lines from mean log(MAR) 0.72 (0.34) to 0.44 (0.32) ( $p = 0.0005$ ,  $n = 12$ ). In this combined group, the mean PDT application number was 1.67 (0.87) (or 0.62 (0.39) PDT sessions per year).

### Toxoplasmosis/MCP

A mean of 3.8 (1.1) PDT sessions were applied during 38 (14) months (corresponding to 1.20 (0.93) PDT sessions per year). Two patients with toxoplasmosis-related CNV after 38 (14) months follow-up revealed stable vision. Two patients with CNV secondary to MCP sustained decreases of five and 11 chart lines, respectively. Both patients were additionally treated with systemic steroid, and patient no. 13 once received an intravitreal injection of 4 mg of triamcinolone acetate 1 day after initial PDT (table 1). No further patients underwent steroidal treatment. In patient 13, CNV growth continued despite the application of four PDTs and additional steroidal systemic and intravitreal treatment.

### Lesion parameters

Table 1 further depicts lesion parameters of the patients before treatment and at the end of follow-up. All CNV lesions were of the classic type. Lesion localisation was sub- or juxtafoveal in all but two patients. One patient with toxoplasmosis-related CNV exhibited a vision-limiting foveal scar with extrafoveal

localisation of the CNV. In one further patient with myopic extrafoveal CNV, the initial vision loss was related to sub- and intraretinal fluid involving the fovea.

CNV inactivation was achieved in all except for three patients (81%) as documented by fluorescein angiography. Two POHS patients declined further treatment and were lost to follow-up 3 and 6 months after initial PDT. Both patients responded to treatment with reduced GLD and leakage activity during angiography. As only one single patient with MCP (no. 13) exhibited CNV lesion growth and leakage despite four PDT administrations and additional steroidal systemic and intravitreal treatment, the rate of non-responding was  $1/16 = 6\%$ .

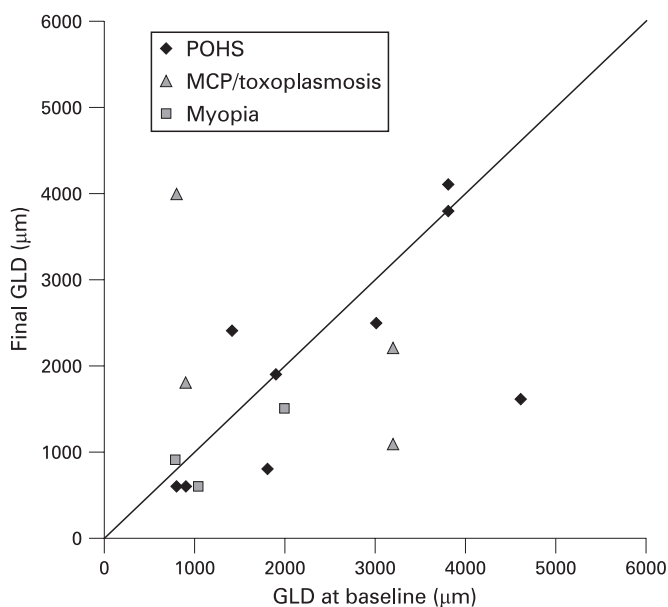
In four patients (25%), the contralateral eye showed CNV formation. In three out of these four patients, no treatment efforts were necessary as lesions revealed no leakage activity during follow-up. Visual acuity of the fellow eyes with inactive CNV was at stable 0.7 log(MAR) during the observation interval without treatment. The fellow eye of one myopic patient with active extrafoveal CNV retained full vision after thermal photocoagulation.

The mean diameters of pigment epithelial alteration (PLD) increased, statistically significantly, by 40% during the observation period (from 1722 (864)  $\mu\text{m}$  before first PDT to 2836 (1118)  $\mu\text{m}$  mean (SD) at the end of follow-up;  $p = 0.0002$ ;  $n = 16$ ). PLD differences before and after PDT remained statistically significant in the subgroup analyses. Analysis of the mean greatest linear dimensions (GLD) did not evince significant differences during follow-up.

However, courses of visual acuity showed no correlation with changes in PLD or GLD. Only in the MCP subgroup was the prevalent lesion growth accompanied by decreased vision ( $r = 0.99$ ). Figure 2 depicts GLD values before and after therapy, and clearly shows the divergent GLD courses of the patients in the subgroups.

The cases shown in fig 3 represent positive and negative examples of treatment results. Although in both patients significant changes in pigment epithelial layer are represented by stippled window defects surrounding the CNV lesion during angiography, only patient no. 15 sustained vision loss as well as increased GLD. The CNV revealed no leakage activity after therapy in both cases (table 1, fig 3).

Figure 4 correlates changes in vision with PDT administration numbers. Patients in the POHS and myopia subgroups did not sustain major vision decreases after two or three PDT administrations. Conversely, two MCP patients significantly



**Figure 2** Greatest linear lesion dimensions (GLD) of the patients before and after 34.4 (24) months at the end of the observation. MCP, multifocal choroiditis and panuveitis; POHS, presumed ocular histoplasmosis syndrome.

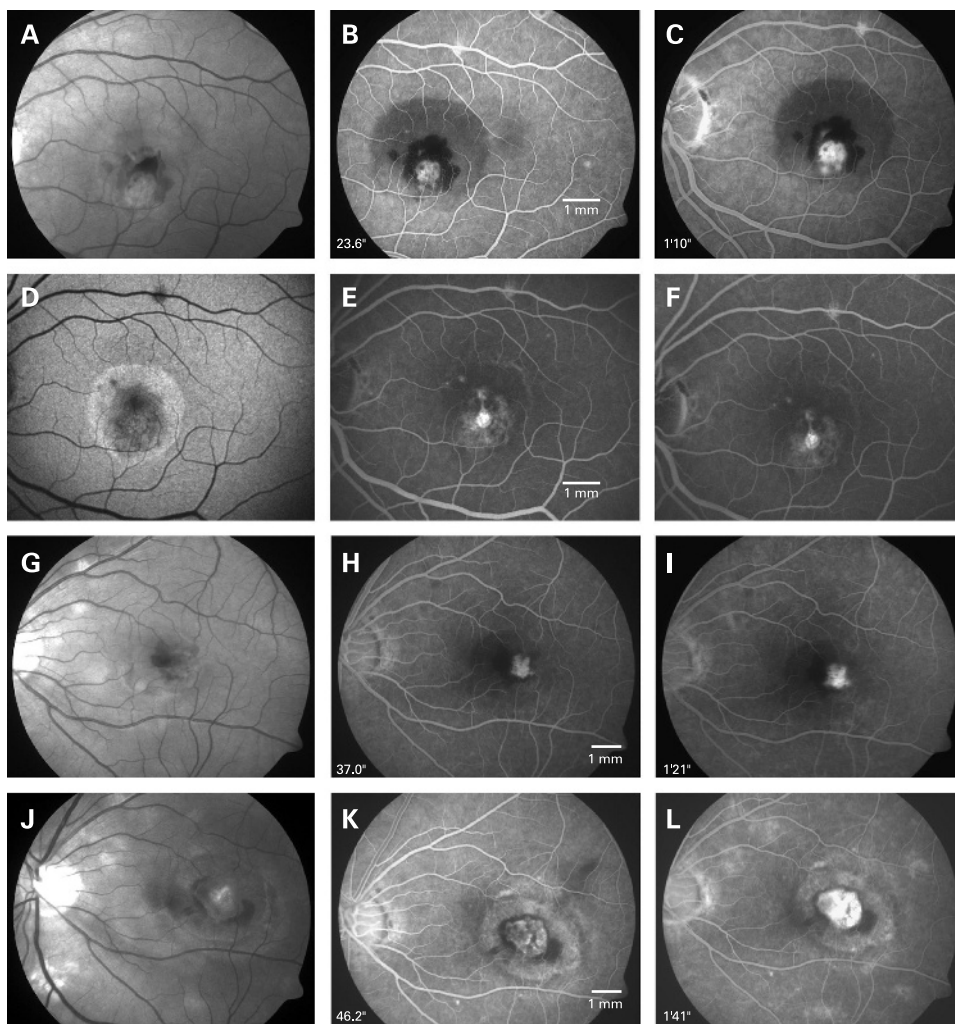
lost vision after four PDT sessions. One patient with toxoplasmosis-related CNV retained stable vision even after five PDT sessions. Neither final vision nor vision changes during the observation period correlated with PDT application frequency (data not shown).

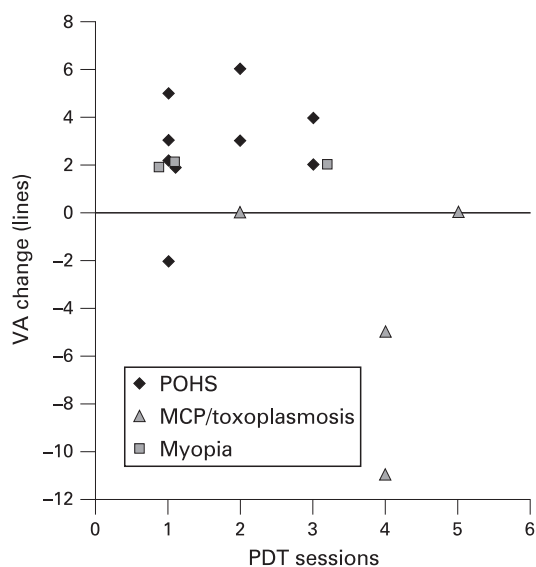
## DISCUSSION

The results indicate good if not excellent efficacy and tolerability which were most promising in a subgroup of patients with vision-impairing CNV not associated with active uveitis. With intent to surpass age inconsistencies within our collective, we separately analysed the seven paediatric patients from all disease entities. This evinced significant vision increases after 2.4 PDT sessions and 37 months of follow-up in this subgroup.

Sickenberg and co-workers were the first to report on beneficial results after PDT in subfoveal CNV lesions due to other reasons than age-related macular degeneration.<sup>15</sup> Then, the Verteporfin in Ocular Histoplasmosis Study Group (VOHS) after 24 months achieved a median vision gain of 1.2 lines in a cohort with a median age of 50 at initial PDT.<sup>7</sup> Several further studies recorded vision improvements after PDT of idiopathic CNV and CNV secondary to chorioretinal inflammation including POHS.<sup>14 15 28-35</sup> Although published data on PDT for CNV attributable to MCP suggest favourable results,<sup>32 33</sup> our

**Figure 3** (A–F) Left eye red-free fundus photography (A), fundus autofluorescence (D) and angiography (B, C, E, F) of patient no. 8 with choroidal neovascularisation (CNV) related to presumed ocular histoplasmosis syndrome before (A–C) and after one photodynamic therapy using verteporfin (PDT) session/ 62 months later (D–F). Vision increased by five lines. (G–L) Left eye red-free fundus photography (G, J) and angiography (H, I, K, L) of patient no. 15 with CNV related to multifocal choroiditis and panuveitis before (G–I) and after 21 months/four PDT sessions (J–L). Vision decreased by five lines.





**Figure 4** Relation of change in visual acuity and PDT session numbers in the subgroups. Patients who received two or more PDT administrations were not predetermined to sustain vision loss (n = 16).

experience with PDT in inflammatory CNV in young patients is limited. Within this series, two patients with MCP sustained significant vision decreases as well as increases in lesion size. Even since corticosteroidal supplementation fails to explain the courses, our case observations point to possible disease inhomogeneities leading to treatment failures in this disease group.

Congruent with a recent report on PDT in young individuals with CNV secondary to toxoplasmotic retinochoroiditis,<sup>34</sup> our likewise affected patients had stable 20/40 vision after PDT and 23 or 59 months of follow-up, respectively. Probably due to the lesion location, vision was better in both of our patients when compared with cases reported in the study.

Successful PDT treatment of CNV in patients with pathological myopia was outlined in prospective randomised multicentre trials for subfoveal<sup>21</sup> as well as in retrospective analyses for non-subfoveal CNV.<sup>22</sup> Favourable results of PDT treatment of extrafoveal CNV in myopic patients were reported in a small case series by Gelisken and associates after a follow-up period of 36 months.<sup>23</sup> In the present study, two CNV lesions with vision-impairing extrafoveal location were included (patient no. 12 and 14). In both cases, laser photocoagulation would have been an alternative<sup>11 12</sup> which was indeed used in the second eye of the myopic patient no. 12 with bilateral extrafoveal CNV. Here, full vision was retained after argon laser coagulation of the lesion during 24 months of observation. Since the PDT treated eye recovered full vision after one PDT session during 35 months and since the PDT scar remained stable in contrast to expanded size in the fellow eye, PDT treatment remains a reasonable alternative in this case. Notably, without considering treatment courses of patients with extrafoveal CNV, vision results after PDT for CNV due to POHS and myopia significantly improved from 0.76 (0.31) to 0.48 (0.30) ( $p = 0.001$ ,  $n = 11$ ).

Consistent positive PDT effects on CNV cessation in paediatric patients were shown in limited further case series. Although treatment regimes as well as CNV causes differed, the treatment safety and efficacy of PDT were affirmed in all cases.<sup>5 6 35 36</sup>

One side-effect of PDT in young patients could result from the appearance of circumscribed pigment epithelial alteration and atrophy phenomena most probably arising from damage induced in the area of the laser spot. The presumed mechanism of verteporfin uptake by the retinal pigment epithelium and direct light activation may vary with age and thus be increased in young individuals. The significance of the atrophy phenomenon after PDT was highlighted by histochemical analyses in animal models and enucleated eyes<sup>36-38</sup> as well as in clinical observations.<sup>5 6 15 39</sup> However, vision was unaffected during up to 3 years of observation.<sup>5 36</sup> Four of five paediatric patients in the series of Giansanti and associates showed pigment epithelial atrophy in the area of the laser spot which did not lead to vision loss.<sup>6</sup> In the study by Wachtlin *et al*, two paediatric patients with idiopathic CNV 13 and 22 months after PDT revealed no RPE reaction,<sup>15</sup> but Mimouni reported on three paediatric cases with idiopathic CNV and treatment with PDT, of which at least one showed the typical RPE change.<sup>5</sup> In our series, four of the seven paediatric patients (57%) and eight of 16 cases in the total collective (50%) revealed gradually different forms of pigment epithelial alteration with variations in shape and size. Thus, the mean pigment epithelial lesion diameters (PLD) increased by 40%, which did not show a correlation with changes in vision. Notably, most lesions remained stable after therapy. Furthermore, compensation mechanisms have to be postulated, as RPE disturbances did not influence vision outcomes. Further investigations should be addressed on alterations of the pigment epithelium secondary to PDT in young patients as the outstanding side-effect in this study.

New treatment approaches of intravitreal pharmacotherapy using VEGF-binding substances in POHS or pathological myopia are promising. Nevertheless, the results still remain to be followed over a longer period.<sup>16-18</sup> The probable necessity to maintain effective intravitreal concentrations over a longer period yet implies sustained intravitreal injections. However, Chan and associates reported an absence of leakage 3 months after three monthly injections of bevacizumab in 100% of 15 patients with CNV attributable to pigmented inner choroidopathy, central serous choroidopathy or idiopathic origin.<sup>19</sup> Different to adults, paediatric patients may be able to stand the procedure of intravitreal injections only after sedation or anaesthesia. The cumulative risk of adverse events related to the injection procedure is another disadvantage compared with PDT in young patients.

PDT in this study provides good efficacy and safety in the treatment of paediatric and young adult patients with CNV attributable to POHS or pathological myopia. Although in our study only two patients with MCP responded unfavourably to PDT, non-responding may increasingly occur with a larger subset of patients and intravitreal injections of anti-VEGF substances may be administered in cases of resistance to photodynamic monotherapy.<sup>18</sup>

**Funding:** University Eye Clinic, Essen.

**Competing interests:** None.

**Ethics approval:** The design of the study was reviewed by the authors and the institutional review board. All procedures were in full accordance with local ethics board requirements.

## REFERENCES

1. Spaide RF. Choroidal neovascularization in younger patients. *Curr Opin Ophthalmol* 1999;**10**:177-81.
2. Cohen SY, Laroche A, Leguen Y, *et al*. Etiology of choroidal neovascularization in young patients. *Ophthalmology* 1996;**103**:1241-4.

3. **Lindblom B**, Andersson. The prognosis of idiopathic choroidal neovascularization in persons younger than 50 years of age. *Ophthalmology* 1998;**105**:1816–20.
4. **Muller-Velten R**, Michels S, Schmidt-Erfurth, *et al*. Photodynamic therapy: extended indication. *Ophthalmologie* 2003;**100**:384–90.
5. **Mimouni KF**, Bressler SB, Bressler NM. Photodynamic therapy with verteporfin for subfoveal choroidal neovascularization in children. *Am J Ophthalmol* 2003;**135**:900–2.
6. **Giansanti F**, Virgili G, Varano M, *et al*. Photodynamic therapy for choroidal neovascularization in pediatric patients. *Retina* 2005;**25**:590–6.
7. **Rosenfeld PJ**, Saperstein DA, Bressler NM, *et al*. Verteporfin in Ocular Histoplasmosis Study Group. Photodynamic therapy with verteporfin in ocular histoplasmosis: uncontrolled, open-label 2-year study. *Ophthalmology* 2004;**111**:1725–33.
8. **Gass JD**, Wilkinson CP. Follow-up study of presumed ocular histoplasmosis. *Trans Am Acad Ophthalmol Otolaryngol* 1972;**76**:672–94.
9. **Hawkins BS**, Bressler NM, Bressler SB, *et al*. Surgical removal vs observation for subfoveal choroidal neovascularization, either associated with the ocular histoplasmosis syndrome or idiopathic: I. Ophthalmic findings from a randomized clinical trial: Submacular Surgery Trials (SST) Group H Trial: SST Report No. 9. *Arch Ophthalmol* 2004;**122**:1597–611.
10. **Macular Photocoagulation Study Group**. Argon laser photocoagulation for neovascular maculopathy. Five-year results from randomized clinical trials. *Arch Ophthalmol* 1991;**109**:1109–14.
11. **Macular Photocoagulation Study Group**. Laser photocoagulation for juxtafoveal choroidal neovascularization. Five-year results from randomized clinical trials. *Arch Ophthalmol* 1994;**112**:500–9.
12. **Macular Photocoagulation Study Group**. Five year follow-up of fellow eyes of individuals with ocular histoplasmosis and unilateral extrafoveal or juxtafoveal choroidal neovascularization. *Arch Ophthalmol* 1996;**114**:677.
13. **Sickenberg M**, Schmidt-Erfurth U, Miller JW, *et al*. A preliminary study of photodynamic therapy using verteporfin for choroidal neovascularization in pathologic myopia, ocular histoplasmosis syndrome, angioid streaks, and idiopathic causes. *Arch Ophthalmol* 2000;**118**:327–36.
14. **Wachtlin J**, Heimann H, Behme T, *et al*. Long-term results after photodynamic therapy with verteporfin for choroidal neovascularizations secondary to inflammatory chorioretinal diseases. *Graefes Arch Clin Exp Ophthalmol* 2003;**241**:899–906.
15. **Wachtlin J**, Wehner A, Heimann H, *et al*. Photodynamic treatment with verteporfin for patients with idiopathic choroidal neovascularization. Two-year results. *Ophthalmologie* 2004;**101**:489–95.
16. **Hernández-Rojas ML**, Quiroz-Mercado H, Dalma-Weiszhausz J, *et al*. Short-term effects of intravitreal bevacizumab for subfoveal choroidal neovascularization in pathologic myopia. *Retina* 2007;**27**:707–12.
17. **Chan WM**, Lai TY, Liu DT, *et al*. Intravitreal bevacizumab (avastin) for myopic choroidal neovascularization. Six-month results of a prospective pilot study. *Ophthalmology* 2007;**114**:2190–6.
18. **Schadlu R**. Intravitreal bevacizumab (Avastin) treatment of choroidal neovascularisations secondary to the ocular histoplasmosis syndrome. *IOVS* 2007;**48**:E-Abstract 1458.
19. **Chan WM**, Lai TY, Liu DT, *et al*. Intravitreal bevacizumab (avastin) for choroidal neovascularization secondary to central serous chorioretinopathy, secondary to punctate inner choroidopathy, or of idiopathic origin. *Am J Ophthalmol* 2007;**143**:977–83.
20. **O'Toole L**, Tufail A, Pavesio C. Management of choroidal neovascularization in uveitis. *Int Ophthalmol Clin* 2005;**45**:157–77.
21. **Blinder KJ**, Blumenkranz MS, Bressler NM, *et al*. Verteporfin therapy of subfoveal choroidal neovascularization in pathologic myopia: 2-year results of a randomized clinical trial-VIP report no. 3. *Ophthalmology* 2003;**110**:667–73.
22. **Virgili G**, Varano M, Giacomelli G, *et al*. Photodynamic therapy for nonsubfoveal choroidal neovascularization in 100 eyes with pathologic myopia. *Am J Ophthalmol* 2007;**143**:77–82.
23. **Gelissen F**, Inhoffen W, Hermann A, *et al*. Verteporfin photodynamic therapy for extrafoveal choroidal neovascularisation in pathologic myopia. *Graefes Arch Clin Exp Ophthalmol* 2004;**242**:926–30.
24. **Azab M**, Benchaboune M, Blinder KJ, *et al*. Verteporfin therapy of subfoveal choroidal neovascularization in age-related macular degeneration: meta-analysis of 2-year safety results in three randomized clinical trials: treatment of age-related macular degeneration with photodynamic therapy and verteporfin in photodynamic therapy study report no. 4. *Retina* 2004;**24**:1–12.
25. **Jurkles B**, Bornfeld N, Schilling H. Photodynamic therapy using verteporfin for choroidal neovascularization associated with angioid streaks-long-term effects. *Ophthalmic Res* 2006;**38**:209–17.
26. **Jurkles B**, Anastassiou G, Ortmans S, *et al*. Photodynamic therapy using verteporfin in circumscribed choroidal haemangioma. *Br J Ophthalmol* 2003;**87**:84–9.
27. **Chamberlin JA**, Bressler NM, Bressler SB, *et al*. The use of fundus photographs and fluorescein angiograms in the identification and treatment of choroidal neovascularization in the Macular Photocoagulation Study. *Ophthalmology* 1989;**96**:1526–34.
28. **Yoo MH**, Boo HD, Kim HK. Result of photodynamic therapy for idiopathic subfoveal choroidal neovascularization. *Korean J Ophthalmol* 2005;**19**:264–8.
29. **Rogers AH**, Duker JS, Nichols N, *et al*. Photodynamic therapy of idiopathic and inflammatory choroidal neovascularization in young adults. *Ophthalmology* 2003;**110**:1315–20.
30. **Busquets MA**, Shah GK, Wickens J, *et al*. Ocular photodynamic therapy with verteporfin for choroidal neovascularization secondary to ocular histoplasmosis syndrome. *Retina* 2003;**23**:299–306.
31. **Spaide RF**, Martin ML, Slakter J, *et al*. Treatment of idiopathic subfoveal choroidal neovascular lesions using photodynamic therapy with verteporfin. *Am J Ophthalmol* 2002;**134**:62–8.
32. **Spaide RF**, Freund KB, Slakter J, *et al*. Treatment of subfoveal choroidal neovascularization associated with multifocal chorioiditis and panuveitis with photodynamic therapy. *Retina* 2002;**22**:545–9.
33. **Gerth C**, Spital G, Lommatzsch A, *et al*. Photodynamic therapy for choroidal neovascularization in patients with multifocal chorioiditis and panuveitis. *Eur J Ophthalmol* 2006;**16**:111–8.
34. **Mauget-Faysse M**, Mimoun G, Ruiz-Moreno JM, *et al*. Verteporfin photodynamic therapy for choroidal neovascularization associated with toxoplasmic retinochoroiditis. *Retina* 2006;**26**:396–403.
35. **Liu JC**, Boldt HC, Folk JC, *et al*. Photodynamic therapy of subfoveal and juxtafoveal choroidal neovascularization in ocular histoplasmosis syndrome: a retrospective case series. *Retina* 2004;**24**:863–70.
36. **Harissi-Dagher M**, Sebag M, Gauthier D, *et al*. Photodynamic therapy in young patients with choroidal neovascularization following traumatic choroidal rupture. *Am J Ophthalmol* 2005;**139**:726–8.
37. **Haimovici R**, Kramer M, Miller JW, *et al*. Localization of lipoprotein-delivered benzoporphyrin derivative in the rabbit eye. *Curr Eye Res* 1997;**16**:83–90.
38. **Schlotzer-Schrehardt U**, Viestenz A, Naumann GO, *et al*. Dose-related structural effects of photodynamic therapy on choroidal and retinal structures of human eyes. *Graefes Arch Clin Exp Ophthalmol* 2003;**240**:748–57.
39. **Postelmans L**, Pasteels B, Coquelet P, *et al*. Severe pigment epithelial alterations in the treatment area following photodynamic therapy for classic choroidal neovascularization in young females. *Am J Ophthalmol* 2004;**138**:803–8.