



Increased incidence of sterile endophthalmitis following intravitreal preserved triamcinolone acetonide

J Jonisch, J C Lai, V A Deramo, et al.

Br J Ophthalmol 2008 92: 1051-1054

doi: 10.1136/bjo.2007.136069

Updated information and services can be found at:

<http://bjo.bmj.com/content/92/8/1051.full.html>

These include:

References

This article cites 25 articles, 11 of which can be accessed free at:

<http://bjo.bmj.com/content/92/8/1051.full.html#ref-list-1>

Email alerting service

Receive free email alerts when new articles cite this article. Sign up in the box at the top right corner of the online article.

Topic collections

Articles on similar topics can be found in the following collections

[Choroid](#) (371 articles)

[Eye \(globe\)](#) (450 articles)

Notes

To order reprints of this article go to:

<http://bjo.bmj.com/cgi/reprintform>

To subscribe to *British Journal of Ophthalmology* go to:

<http://bjo.bmj.com/subscriptions>



Increased incidence of sterile endophthalmitis following intravitreal preserved triamcinolone acetonide

J Jonisch,¹ J C Lai,^{1,2} V A Deramo,^{1,2} A J Flug,¹ D M Fastenberg^{1,2}

¹ Department of Ophthalmology, North Shore-Long Island Jewish Health System, Great Neck, NY, USA; ² Long Island and Queens Vitreo-Retinal Consultants, Great Neck, NY, USA

Correspondence to: Dr J C Lai, 98-1079 Moanualua Rd, Suite 470, Aiea, HI 96701, USA; jimretina@yahoo.com

Accepted 25 April 2008

ABSTRACT

Aim: To report an increased incidence of sterile endophthalmitis following intravitreal injection of preserved triamcinolone acetonide (IVTA) from 1 May to 31 July 2006.

Methods: Charts were reviewed for all patients who underwent IVTA injections between 1 January 2005 and 31 July 2006 at the offices of a referral vitreo-retinal practice. Patients were included if they presented post-IVTA with a clinical picture consistent with endophthalmitis.

Results: Between 1 January 2005 and 31 July 2006, 554 eyes underwent IVTA. Eleven eyes (1.9%) developed an endophthalmitis. All eleven eyes underwent vitreous tap and intravitreal injection of antibiotics. All cultures and gram stains were negative for bacterial or fungal organisms. From 1 May to 31 July 2006, 97 eyes underwent IVTA. Nine eyes (9.3%) developed sterile endophthalmitis. This represented a statistically significant ($p < 0.0001$) clustering of cases. Triamcinolone acetonide phials from affected lot numbers were analysed and were all found to be negative for bacterial endotoxin (< 0.05 EU/ml).

Conclusion: Over the 19-month period analysed, 11 cases of sterile endophthalmitis occurred following IVTA, and nine of these cases were clustered over a 3-month period. No endotoxin was detected in the phials tested. The aetiology of this increased incidence of sterile endophthalmitis is still unclear.

Intravitreal injection of triamcinolone acetonide (IVTA) has been shown to be beneficial in the treatment of macular oedema secondary to vein occlusion, diabetes and uveitis, as well as adjunctive treatment of exudative macular degeneration.¹⁻¹⁰ The most common side effects include ocular hypertension and cataract progression.¹¹⁻¹⁴ Infectious endophthalmitis, pseudoendophthalmitis and sterile endophthalmitis are also well-known complications following IVTA.¹⁵⁻²¹ Pseudoendophthalmitis has been defined as cases where the injected agent, triamcinolone acetonide, creates the appearance of intraocular inflammation and/or hypopyon.¹⁴⁻¹⁹ Non-infectious or sterile endophthalmitis is defined as true intraocular inflammation following injection of IVTA not attributed to an infectious process.¹⁴ Historically, the commercially available form of triamcinolone acetonide used for intravitreal injection in the United States has been Kenalog (Bristol-Myers Squibb, Princeton, NJ) which comes in a preservative-containing formulation. The aetiology of sterile endophthalmitis is unknown, but several

possible aetiologies have been proposed. It has been hypothesised that sterile endophthalmitis represents an inflammatory reaction to the triamcinolone acetonide, the preservatives in which it is suspended, or a form of bacterial endophthalmitis caused by contamination with bacterial toxins or endotoxin not detected by standard culture methods.¹⁷⁻²¹ The reported incidence of sterile endophthalmitis ranges between 0.1% and 1.6% when using the preserved formulation.¹⁴⁻¹⁶⁻¹⁸

In the months of May-July 2006, we observed an increased number of patients presenting with severe intraocular inflammation following injection of preserved IVTA. The purpose of this study is to analyse the incidence of sterile endophthalmitis following intravitreal injection of preserved triamcinolone acetonide from 1 January 2005 to 31 July 2006, to evaluate whether there was a statistically significant increased incidence.

METHODS

The North Shore-Long Island Jewish University Hospital System institutional review board approved the study protocol. Charts were reviewed for all patients who underwent intravitreal injection with preserved triamcinolone acetonide (Kenalog; Bristol-Myers Squibb, Princeton, NJ) between 1 January 2005 and 31 July 2006 at the offices of a referral vitreo-retinal practice. Charts were obtained by searching the computer database for all intravitreal injections performed, and included only those patients who underwent intravitreal injection with preserved triamcinolone acetonide. Records were reviewed of all patients who developed postinjection presumed endophthalmitis following intravitreal injection of preserved triamcinolone acetonide. Patients were included if they presented with a clinical picture consistent with endophthalmitis defined as postinjection vitritis, with fibrinoid anterior chamber reaction and/or hypopyon. Patients with pseudoendophthalmitis, with suspended triamcinolone crystals, were excluded.

Written informed consent was obtained from each patient prior to steroid injection. Standard aseptic techniques were used, and the procedure was performed in the office setting for all cases. The operative eye was given a preoperative topical antibiotic of the physician's choice. After the eye was anaesthetised with topical anaesthetic, a sterile lid speculum was placed in the eye. The temporal conjunctiva was then anaesthetised with a 4% lidocaine-hydrochloride soaked cotton tip. A 5% povidone-iodine solution was applied to the eye

Table 1 Patient demographics

Patient with post-IVTA endophthalmitis	Age	Indication	Culture results	Phakic status	Capsule status	Pre-IVTA injection visual acuity	Presenting visual acuity	Visual acuity, 1 month	Month
1	62	RVO	Negative	Pseudophakic	Intact	20/100	HM	20/80	May 2005
2	76	RVO	Negative	Phakic	NA	20/80	HM	20/60	Jan 2006
3	73	RVO	Negative	Phakic	NA	20/100	CF	20/50	May 2006
4	67	DME	Negative	Pseudophakic	Intact	CF	HM	20/400	May 2006
5	65	DME	Negative	Phakic	NA	20/200	CF	20/150	May 2006
6	76	RVO	Negative	Pseudophakic	Ruptured	20/60	HM	20/100	June 2006
7	69	CME	Negative	Pseudophakic	Intact	20/50	HM	20/70	June 2006
8	85	CME	Negative	Pseudophakic	Intact	20/150	HM	20/50	July 2006
9	81	DME	Negative	Pseudophakic	Intact	20/60	HM	20/60	July 2006
10	67	CME	Negative	Pseudophakic	Intact	20/70	HM	20/70	July 2006
11	85	DME	Negative	Phakic	NA	20/150	HM	20/60	July 2006

CF, count fingers; CME, cystoid macular oedema secondary to pseudophakia; DME, diabetic macular oedema; HM, hand motion; IVTA, intravitreal injection of triamcinolone acetonide; NA, not applicable; RVO, retinal vein occlusion.

several minutes prior to intravitreal injection, as well as to the rubber stopper of the individual phials. The triamcinolone acetonide was prepared by drawing out 0.1 ml from a 1 ml single-use phial (Kenalog 40 mg/ml) after vigorously shaking the suspension. The formulation was neither diluted nor changed, and the solvent was not removed. Intraocular pressure postinjection was measured. The injection protocol and the physicians performing the procedure were similar throughout the studied period. Patients were instructed to use a topical third- or fourth-generation fluoroquinolone four times per day for 3 days postinjection.

Patient age, phakic status, status of capsular bag, any history of intraocular inflammation, indication for injection, month of injection and number of days to presentation with endophthalmitis were recorded for affected patients. Visual acuity was recorded on the day of IVTA injection, on day of presentation and at 1 month post-IVTA. The data were analysed using the Fisher exact test. Triamcinolone acetonide phials from three of the lot numbers affected were analysed for bacterial endotoxin using the limulus amoebocyte assay.²²

North Shore-Long Island Jewish Hospital's Department of Biostatistics was consulted to evaluate the significance of the cluster. The statistical question was whether the number of events (ie, cases of sterile endophthalmitis) follows a Poisson distribution. The Poisson distribution is frequently used in situations where events are rare, and one wishes to evaluate the significance of a cluster. The Poisson distribution assumes rare

events occur at an average rate and independently of the time since the last event. A standard chi-square goodness of fit test was used to test the Poisson hypothesis, where the Poisson parameter, λ , was estimated as the total number of observed events/number of months in the study.

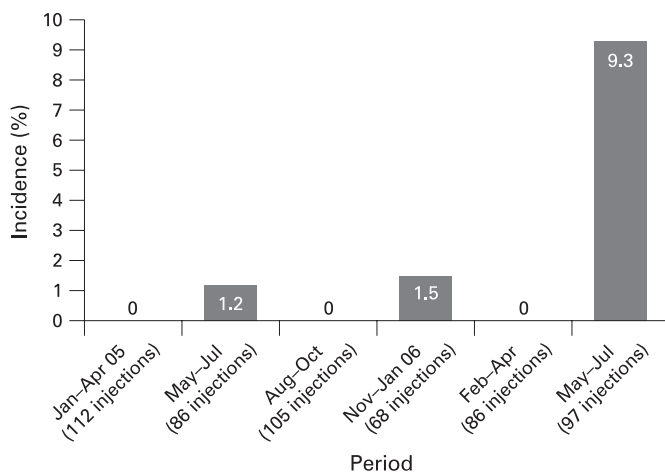
RESULTS

From 1 January 2005 through 31 July 2006, 554 eyes underwent IVTA. Eleven eyes (1.9%) developed an endophthalmitis (table 1). Patient ages ranged from 62 to 85. Indications for injection for these eyes included macula oedema secondary to vein occlusion ($n=4$), diabetes ($n=4$) and pseudophakia ($n=3$). All patients presented by day 4 post-IVTA (average = 1.33 days). Seven of 11 eyes were pseudophakic, and six of the seven pseudophakic eyes had intact posterior capsules. None of the 11 affected eyes had a prior history of intraocular inflammation. Pre-IVTA visual acuity ranged from 20/50 to hand motion. All patients with endophthalmitis presented with worsened visual acuity. Visual acuity at presentation with endophthalmitis was either hand motion or counting fingers vision. Visual acuity at 1 month post-IVTA injection ranged from 20/50 to 20/400. In nine of the 11 eyes affected, visual acuity at 1 month was equal to or better than the pre-IVTA injection visual acuity. All 11 eyes underwent vitreous tap and intravitreal injection of antibiotics with 1 mg of vancomycin and 2.25 mg of ceftazidime. All cultures and Gram stains were negative for bacterial or fungal organisms.

Between 1 May and 31 July 2006, 97 eyes underwent IVTA injections. Nine eyes (9.3%) following the 97 injections developed a clinical picture of endophthalmitis.

Phials used from these cases were from varying lot numbers. Three phials from separate lot numbers affected were sent for endotoxin analysis using the limulus amoebocyte assay, and each returned negative (<0.05 EU/ml) for bacterial endotoxin.

From 1 May to 31 July 2005, 86 eyes underwent IVTA injections. One eye (1.1%) underwent a vitreous tap and intravitreal injection of antibiotics for endophthalmitis. In 2006, there were three cases in May, two cases in June and four cases in July. In 2005, there was one case in May and no cases in June or July. In the same 3-month time period the incidence rose from 1.1% to 9.7% ($p=0.02$) from 2005 to 2006. No patient in either group had culture-positive endophthalmitis. The number of cases and the total number of IVTA injections for each 3-month period studied are shown in fig 1. Beginning in August 2006, we began using a preservative-free formulation of triamcinolone acetonide.

**Figure 1** Incidence of sterile endophthalmitis.

To evaluate the statistical significance of this cluster of cases, a standard chi-square goodness-of-fit (GOF) test was used to test the whether the number of cases of a rare event occur in a Poisson distribution. The Poisson distribution assumes that rare events occur at an average rate and independently of the time since the last event. The parameter, λ , was estimated as the total number of observed events/number of months in the study. The estimated mean for the Poisson distribution was $\lambda = 11/19 = 0.58$ events/month. The GOF test showed a significant lack of fit for the Poisson distribution ($p < 0.0001$). The data were not consistent with the Poisson distribution assumption and support the hypothesis of a true cluster.

DISCUSSION

Preserved intravitreal triamcinolone acetonide has been reported to be therapeutically useful in cases of macular oedema due to multiple aetiologies and adjunctively in exudative macular degeneration.¹⁻¹⁰ Infectious and non-infectious endophthalmitis remain important clinical entities. The reported incidence of sterile endophthalmitis following intravitreal injection of preserved triamcinolone acetonide ranges from 0.1% to 1.6%.¹⁶⁻¹⁸ Our observed incidence of 9.7% from 1 May to 31 July 2006 represents a statistically significant increased incidence when compared with the same time period 1 year earlier, and was a dramatic increase from our prior experience with Kenalog.

The reported incidence varies throughout the literature partly due to the variability in terminology used. We reserve the term sterile endophthalmitis, in the post-IVTA setting, to include a severe intraocular inflammation, which includes vitritis with an anterior chamber fibrinoid reaction and/or hypopyon not directly attributed to an infectious aetiology. The term pseudoendophthalmitis, in the post-IVTA setting, is reserved for cases in which the triamcinolone crystals appear in the anterior chamber with minimal associated inflammation.

Nelson *et al* reported seven cases of noninfectious endophthalmitis following 440 intravitreal Kenalog injections (1.6%), although included in that number was at least one patient with only steroid particles within the anterior chamber 30 min postinjection.¹⁷ The actual incidence of non-infectious endophthalmitis was likely lower when eliminating the cases of pseudoendophthalmitis. Sutter and Gillies reported four cases following approximately 600 injections (0.6%) that were described by the authors as pseudo-endophthalmitis, though each case presented with a dense vitreous haze.²⁰ In a study by Roth *et al*, the incidence of sterile endophthalmitis was noted to be much higher (6.7%, seven cases out of 104 injections) during a 14-month period between 1 May 2001 and 30 June 2002.²¹

The aetiology of sterile endophthalmitis is unclear. It has been postulated that sterile endophthalmitis may represent an atypical form of bacterial endophthalmitis caused by bacterial toxins or endotoxins not detected by standard culture methods.¹⁷ However, in our series, the triamcinolone acetonide was sent for analysis, and no endotoxin was detected. To our knowledge, this is the first reported formal analysis looking for endotoxin contamination of the triamcinolone.

Another theory is that sterile endophthalmitis represents an inflammatory reaction to the preservatives and additives contained in the Kenalog phials which includes benzyl alcohol, carboxymethylcellulose sodium, and polysorbate 80 in suspension.^{17, 21} This hypothesis is supported by the work of Jonas *et al*, who report an incidence of 0% in 454 eyes when the solvent was removed from triamcinolone acetonide.⁶ However, the recent reports of sterile endophthalmitis following intravitreal

injection of preservative free triamcinolone acetonide would suggest that there is a yet-to-be-identified aetiology for this severe postinjection inflammation.²³

There does not appear to be a good explanation for the statistically significant spike in the number of cases of sterile endophthalmitis that was witnessed in our practice during the spring of 2006. It is unknown how many other ophthalmologists experienced a similar increased incidence in this time period. There have been anecdotal reports of a similar rise in the number of cases of sterile endophthalmitis throughout parts of the country during the same time period (Eaton AM, personal communication). However, we are unaware of any published reports of this trend in a peer reviewed journal.

The development of complications following the off-label usage of a drug is particularly worrisome, particularly in light of the letter issued by the manufacturer of Kenalog (November 2006 letter to healthcare providers from Bristol-Myers Squibb Company, Princeton, NJ) (Lewis-Hall F, written communication, 22 November 2006). Reporting on the side-effect profile of medications becomes increasingly important with off-label usage, and the importance of the peer-review process cannot be overstated in these instances. As demonstrated by the recall of contact lens solution following the outbreak of *Fusarium* keratitis, postmarketing vigilance is critical in detecting alarming trends that could alter currently accepted practice patterns.²⁴ Specifically in this case, the spike in sterile endophthalmitis was the impetus for our decision to switch to preservative-free triamcinolone acetonide in an attempt to minimise the incidence of sterile endophthalmitis.

The side-effect profile of triamcinolone acetonide with and without preservatives needs further study. Recently the United States Food and Drug Administration (FDA) has approved a preservative-free formulation for intraocular use (Triesence; Alcon Laboratory, Fort Worth, TX). Furthermore, a new formulation of triamcinolone acetonide designed for intraocular use is currently being examined in national clinical trials for macular oedema secondary to diabetes and vein occlusions.²⁵ Until we gain a better understanding for the cause of sterile endophthalmitis, caution should be advised for the use of intravitreal Kenalog.

Competing interests: None.

Ethics approval: The North Shore-Long Island Jewish University Hospital System institutional review board approved the study protocol.

Patient consent: Obtained.

REFERENCES

1. Greenberg PB, Martidis A, Rogers AH, *et al*. Intravitreal triamcinolone acetonide for macular oedema due to central retinal vein occlusion. *Br J Ophthalmol* 2002;**86**:247-8.
2. Martidis A, Duker JS, Greenberg PB, *et al*. Intravitreal triamcinolone for refractory diabetic macular edema. *Ophthalmology* 2002;**109**:920-7.
3. Jonas JB, Kreissig I, *et al*. Intravitreal injection of triamcinolone for diffuse diabetic macular edema. *Arch Ophthalmol* 2003;**121**:57-61.
4. Jonas JB, Sofker A. Intraocular injection of crystalline cortisone as adjunctive treatment of diabetic macular edema. *Am J Ophthalmol* 2001;**132**:425-7.
5. Antcliff RJ, Spalton DJ, Stanford MR, *et al*. Intravitreal triamcinolone for uveitic cystoid macular edema: an optical coherence tomography study. *Ophthalmology* 2001;**108**:765-72.
6. Jonas JB, Kreissig I, Degenring RF. Intravitreal triamcinolone acetonide for pseudophakic cystoid macular edema. *Am J Ophthalmol* 2003;**136**:384-6.
7. Challa JK, Gillies MC, Penfold PL, *et al*. Exudative macular degeneration and intravitreal triamcinolone: 18-month follow-up. *Aust N Z J Ophthalmol* 1998;**26**:277-81.
8. Danis RP, Ciulla TA, *et al*. Intravitreal triamcinolone acetonide in exudative age-related macular degeneration. *Retina* 2000;**20**:244-50.
9. Jonas JB, Kreissig I, Hugger P, *et al*. Intravitreal triamcinolone acetonide for exudative age related macular degeneration. *Br J Ophthalmol* 2003;**87**:462-8.

10. **Spaide RF**, Sorenson J, Maranan L. Photodynamic therapy with verteporfin combined with intravitreal injection of triamcinolone acetonide for choroidal neovascularization. *Ophthalmology* 2005;**112**:301–4.
11. **Wingate RJ**, Beaumont PE. Intravitreal triamcinolone and elevated intraocular pressure. *Aust N Z J Ophthalmol* 1999;**27**:431–2.
12. **Bakri SJ**, Beer PM. The effect of intravitreal triamcinolone acetonide on intraocular pressure. *Ophthalmic Surg Lasers Imaging* 2003;**34**:386–90.
13. **Jonas JB**, Kreissig I, Degenring R. Intraocular pressure after intravitreal injection of triamcinolone acetonide. *Br J Ophthalmol* 2003;**87**:24–7.
14. **Jager RD**, Aiello LP, *et al.* Risks of intravitreal injection: a comprehensive review. *Retina* 2004;**24**:676–98.
15. **Jonas JB**, Kreissig I, Degenring RF. Endophthalmitis after intravitreal injection of triamcinolone acetonide. *Arch Ophthalmol* 2003;**121**:1663–4.
16. **Moshfeghi DM**, Kaiser PK, Scott IU, *et al.* Acute endophthalmitis following intravitreal triamcinolone acetonide injection. *Am J Ophthalmol* 2003;**136**:791–6.
17. **Nelson ML**, Tennant MT, Sivalingam A, *et al.* Infectious and presumed noninfectious endophthalmitis after intravitreal triamcinolone acetonide injection. *Retina* 2003;**23**:686–91.
18. **Westfall AC**, Osborn A, Kuhl D, *et al.* Acute endophthalmitis incidence: intravitreal triamcinolone. *Arch Ophthalmol* 2005;**123**:1075–7.
19. **Moshfeghi AA**, Scott IU, *et al.* Pseudohypopyon after intravitreal triamcinolone acetonide injection for cystoid macular edema. *Am J Ophthalmol* 2004;**138**:489–92.
20. **Sutter FK**, Gillies MC. Pseudo-endophthalmitis after intravitreal injection of triamcinolone. *Br J Ophthalmol* 2003;**87**:972–4.
21. **Roth DB**, Chieh J, Spirn MJ, *et al.* Noninfectious endophthalmitis associated with intravitreal triamcinolone injection. *Arch Ophthalmol* 2003;**121**:1279–82.
22. **Pearson FC**, Dubczak J, Weary M, *et al.* Detection of endotoxin in the plasma of patients with Gram-negative bacterial sepsis by the Limulus amoebocyte lysate assay. *J Clin Microbiol* 1985;**21**:865–8.
23. **Lorenzo CJ**, González BM, Pérez FI. Sterile endophthalmitis after benzyl alcohol filtered triamcinolone acetonide injection. *Arch Ophthalmol* 2008;**126**:142–3.
24. **Chang DC**, Grant GB, O'Donnell K, *et al.* Multistate outbreak of *Fusarium* keratitis associated with use of a contact lens solution. *JAMA* 2006;**296**:953–63.
25. **Bhavsar AR**, Ip MS, Glassman AR, DRCRnet and the SCORE Study Groups. The risk of endophthalmitis following intravitreal triamcinolone injection in the DRCRnet and SCORE clinical trials. *Am J Ophthalmol* 2007;**144**:454–6.

Video report

Endocapsular phacoemulsification without hydrodissection: an effective technique for cataract surgery following anterior capsular tear

ABSTRACT

A radial tear of the anterior capsule can occur either as a primary tear-out during capsulorrhexis or as a secondary event during phaco. Endocapsular surgery in this situation is hazardous and the risk of posterior propagation of the tear is significantly increased by performing hydrodissection. We describe an alternative technique of endocapsular phacoemulsification without primary hydrodissection. The risk of tear propagation is reduced whilst at the same time auto-hydrodissection of the cortico-capsular connections occurs, enabling rotation and removal of the nucleus. This simple modification of conventional phacoemulsification reduces the risk of posterior extension in cases of radial anterior capsular tear and allows the relatively safe completion of endocapsular phacoemulsification.

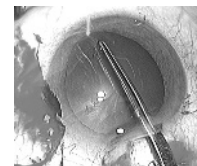R I Angunawela, B Little

Department of Ophthalmology, Royal Free Hospital, London, UK

Correspondence to: Mr B Little, Consultant Ophthalmologist, Royal Free Hospital, London NW3 2QG, UK; brianlittle@blueyonder.co.uk

To view the full report and accompanying video please go to:
<http://bjo.bmj.com/cgi/content/full/92/8/1054/DC1>

All videos from the **BJO video report collection** are available from:
<http://bjo.bmj.com/video/collection.dtl>



See online video reports