

Cornea verticillata supports a diagnosis of Fabry disease in non-classical phenotypes: results from the Dutch cohort and a systematic review

Linda van der Tol,¹ Marije L Sminia,^{2,3} Carla E M Hollak,¹ Marieke Biegstraaten¹

► Additional material is published online only. To view please visit the journal online (<http://dx.doi.org/10.1136/bjophthalmol-2014-306433>).

¹Department of Endocrinology and Metabolism, Amsterdam Lysosome Center 'Sphinx', Academic Medical Center, University of Amsterdam, Amsterdam, The Netherlands

²Department of Pediatrics, Academic Medical Center, University of Amsterdam, Amsterdam, The Netherlands

³Department of Ophthalmology, Medical Center Alkmaar, Alkmaar, The Netherlands

Correspondence to

Dr Marieke Biegstraaten, Academic Medical Center, Department of Internal Medicine, Room F5-166, Meibergdreef 9, Amsterdam 1105 AZ, The Netherlands; M. Biegstraaten@amc.uva.nl

Received 20 November 2014

Revised 11 January 2015

Accepted 17 January 2015

Published Online First

12 February 2015

ABSTRACT

Background Screening for Fabry disease (FD) increasingly reveals individuals without characteristic features and with a variant of unknown significance in the α -galactosidase A (GLA) gene. Cornea verticillata (CV) assessment, as a characteristic sign of FD, may be a valuable diagnostic tool to assess whether these individuals have a non-classical phenotype or no FD at all.

Methods We performed a systematic review to estimate the prevalence of CV in FD. Additionally, CV prevalence was assessed in the Dutch FD cohort. Data were stratified by gender and phenotype (classical, non-classical, uncertain, no-FD) using predefined criteria.

Results CV was assessed in 21 cohorts (n=753, 330 men, age 0–85 years). Pooled prevalence was 69% (74% men, 66% women). In six studies, 77 (19 men) individuals with a non-classical or uncertain diagnosis were identified. Individual data were available in 4/6 studies (n=66, 16 men). CV was present in 24% (n=16, 2 men). 101 (35 men) subjects from the Dutch cohort were grouped as classical, of whom 86% (94% men, 82% women including five women who used amiodarone) had CV. Of the 25 (11 men) non-classical patients, 4 (three men) had CV. Subjects in the uncertain and no-FD groups did not have CV.

Conclusions CV is related to classical or biopsy-proven non-classical FD, with a very high sensitivity in classical men. Thus, presence of CV in an individual with an uncertain diagnosis of FD indicates a pathogenic GLA variant, in the absence of medication that may induce CV; if CV is absent, FD cannot be excluded.

INTRODUCTION

The lysosomal storage disorder Fabry disease (FD) is caused by variants in the X-chromosomal α -galactosidase A (GLA) gene.¹ Due to impaired function of the lysosomal hydrolase α -galactosidase A (α GalA), globotriaosylceramide (Gb3) accumulates. Absent or near absent enzyme activity in men usually leads to classical FD, which is characterised by neuropathic pain with childhood onset, angiokeratoma and cornea verticillata (CV). End organ complications of the heart, kidney and brain arise later in life. Due to the X-linked nature of the disease, women are usually less severely affected.

Screening for FD and individual case finding has resulted in the identification of an increasing number of individuals with a GLA variant. While the birth prevalence of FD was previously estimated to be between 1:40 000 and 170 000,^{1–3} screening studies in high-risk populations (ie, groups with heart, kidney or brain disease) reveal a much higher prevalence of up to >1%. These individuals have a

non-specific sign such as left ventricular hypertrophy or chronic kidney disease that may be attributable to FD, but most do not have the characteristic clinical and biochemical features of FD that are required to confirm a definite diagnosis of FD.⁴ Thus, the majority of these individuals have an uncertain diagnosis of FD in the presence of a genetic variant of unknown significance in the GLA gene.⁴ They may have a non-classical FD phenotype, or a neutral, non-disease-causing GLA variant.

Diagnostic tools are needed to confirm the presence of FD, but also to avoid unjustified labelling of individuals with a non-disease-causing GLA variant and wrongful initiation of costly treatment.

CV assessment may be a useful, non-invasive tool in the diagnosis of FD, specifically for those with an uncertain diagnosis of FD, since it has a high prevalence among patients with FD. The whorl-like pattern of corneal opacities is specific for FD,⁵ with the exception of some medications that may induce a corneal whorling that cannot be distinguished from that in FD (among others, amiodarone and chloroquine; for review, see Hollander and Aldave⁶). With this study we aim to value the presence of CV in the diagnosis of FD by investigating the prevalence of CV in individuals with a classical or non-classical FD phenotype and in individuals with an uncertain diagnosis of FD or no FD.

METHODS

Systematic review

Search

MEDLINE and EMBASE (1980 till January 2013) were searched for studies that assessed eye abnormalities in patients with FD. Search terms used were 'Fabry disease' combined with 'Eye', 'Ophthalmology', 'Cornea verticillata', 'Tortuous retinal veins', 'Corneal opacity' and their synonyms, Mesh terms (MEDLINE) and headings (EMBASE). In EMBASE, limits were used to exclude conference papers and abstracts.

First selection was done based on title and abstract. We selected full-text articles and reports with original data on eye abnormalities in subjects with FD in all languages (with an English abstract), including papers that presented data from international FD registries (Fabry Registry, Genzyme, a Sanofi company and Fabry Outcome Survey, FOS, Shire HGT). Case reports, newborn screening studies, comments, reviews and book chapters were excluded. Subsequently, studies were screened and included based on full text if the inclusion criteria were met.



CrossMark

To cite: van der Tol L, Sminia ML, Hollak CEM, et al. *Br J Ophthalmol* 2016;**100**:3–8.

Data collection and analysis

Data were recorded on the type of study (registry, screening or cohort study), participating study centre(s), number of subjects, gender and age groups (children and/or adults), together with the type of eye abnormalities assessed and therapy status at the time of ophthalmology assessment. A subanalysis was performed on subjects designated as non-classical or uncertain FD. For this purpose, subjects were selected who were reported to have

- ▶ a high residual enzyme activity;
- ▶ non-classical FD disease manifestations such as a cardiac or renal variant;
- ▶ a GLA variant that has frequently been associated with a non-classical FD phenotype;
- ▶ a GLA variant that is generally considered non-pathogenic/neutral, or which pathogenicity is currently discussed in the literature (eg, p.R112H, p.P389A, p.N215S, p.A143T, c.936+919G>A (IVS4+919G>A)).⁴

Raw prevalence data from all studies were combined for calculation of a weighed pooled prevalence, and specified for gender. Data from registry and screening studies were analysed separately.

Dutch cohort

Patient selection and groups

The Dutch database, comprising data from all subjects that visited the outpatient FD clinic with any GLA variant, was searched for all adults (>18 years of age). Data on the use of amiodarone and/or chloroquine at any time during the medical history were retrieved from the medical records.

Previously reported criteria were applied to classify subjects into four groups.⁴⁻⁷ *Classical*: the strict criteria for a definite diagnosis of FD were used to identify patients with a classical FD phenotype. Criteria include very low or absent enzyme activity in leucocytes (men), very high lysoGb3, FD-specific clinical characteristics (neuropathic pain, CV and angiokeratoma) and a family history that is positive for classical FD (see online supplementary table S1).⁷ For this study, an exception was made: CV was not used as a criterion to group subjects as 'classical' because CV is the feature under investigation in this study. *Non-classical*: subjects who do not fulfil these detailed criteria for a definite diagnosis as described in online supplementary table S1 were grouped as non-classical if this subject or a family member has FD characteristic storage on electron microscopy in a biopsy of an affected organ (ie, heart or kidney). *Uncertain*: subjects who do not fulfil the strict criteria, and of whom a biopsy was not available, were grouped as uncertain. *No FD*: subjects were grouped as no FD (a neutral GLA variant) if a biopsy from a subject or from one of his/her family members did not show FD characteristic storage, or if the individual carried the well-known neutral variant p.D313Y.⁸⁻⁹ Subjects were excluded from the analyses if data were insufficient to apply the above criteria and/or CV assessment was missing.

Age at the time of the database search was calculated for all groups, and stratified by gender. For deceased subjects, age at death was used.

CV assessments

Assessment of CV was performed as part of regular clinical care at adulthood or adolescence. A slit-lamp examination was performed by an experienced ophthalmologist or trained physician (LT, supervised by ophthalmologist MS) to assess the left and right cornea. CV was recorded as present, mild or absent. Corneal photographs were obtained in some illustrative cases

(see figure 2). Data on lenticular changes and retinal vessel tortuosity were not available.

Data analyses

Prevalence of CV was calculated for 'classical', 'non-classical', 'uncertain' and 'no FD' groups and specified for gender. The 95% CIs for proportions were calculated using the modified Wald method.¹⁰ Positive and negative predictive values were calculated for individuals who initially presented with an uncertain diagnosis of FD (non-classical and no FD, uncertain cases were excluded).

RESULTS

Systematic review

Search

In total, 460 records were retrieved from MEDLINE and EMBASE after duplicates were removed. Twenty-three studies were selected for data extraction. Two studies were subsequently added by the authors because of their interest for the research question: Whybra *et al*,¹¹ not selected with the search, and Sher *et al*,¹² initially excluded based on the publication date <1980. These studies included 21 cohort studies,¹³⁻³¹ 2 high-risk group screening studies³²⁻³³ and 2 registry studies.³⁴⁻³⁵ Details on selection and inclusion are presented in figure 1.

Prevalence of CV

CV was assessed in 753 individuals (330 men) from 21 cohorts with an age range of 0–85 years; for details, see table 1.¹¹⁻³¹ Pooled prevalence of CV was 69% (range 26–96). Gender-specific data were available for 18 out of 21 studies (n=685, 295 men),^{11-12 14-16 18-24 26-31} revealing a pooled prevalence of 74% (range 14–94) for men and 66% (range 31–100) for women. Thirteen studies reported data on enzyme replacement therapy (ERT) administration, although in most cases the timing of CV assessment in relation to ERT administration was not specified. Therefore, further analysis of these data was not feasible.

In six cohort studies, 77 (19 men) individuals with a non-classical phenotype or uncertain FD could be identified (see table 2). Separate data for gender were available in four out of these six studies (n=66, 16 men). CV was present in 24% of non-classical or uncertain subjects (n=16, two men), mainly comprising the GLA variant c.936+919G>A (IVS4+919G>A) (n=15, one man) from one study on this specific GLA variant.²² Allen *et al*¹³ (and personal communication) reported mild CV in a 3.5-year-old boy with a p.A143T variant, while his brother with the same GLA variant did not have CV at age 1.5 years.

One of the registry studies reported a CV prevalence of 75% (men 73%, women 77%),³⁰ while the second reported that in 11% of men and 12% of women CV was the presenting symptom.³⁴ The high-risk group screening studies revealed that CV was absent in all adult individuals (n=29, 12 men) who were identified with a GLA variant.³²⁻³³

Dutch cohort

Patient selection and groups

In total, 194 records of adults with a GLA variant were retrieved from the database, of whom 50 were excluded because data were not sufficient to fulfil the study criteria for disease groups and/or CV assessment was not (yet) performed due to lost to follow-up or because they had died before assessments were completed (n=45), or patients were recently referred and investigations were ongoing at the time of the study (n=5). In total,

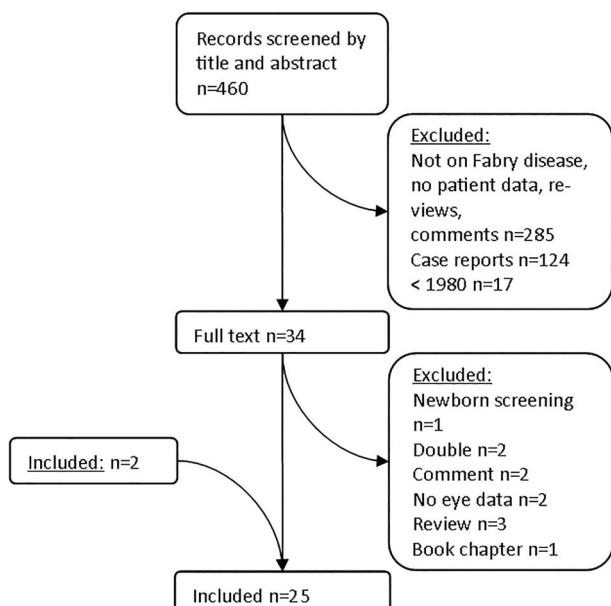


Figure 1 Selection of studies.

144 subjects (56 men, 4 men deceased) were included in the analyses.

Most subjects fit the criteria for a definite diagnosis of FD (classical, $n=101$, 35 men) and 25 subjects (11 men) were grouped as 'non-classical'. FD was excluded in 7 subjects (no FD, five men), and in 11 subjects (five men) the diagnosis of FD was still uncertain.

One exception to the classification criteria was made. In three families ($n=5$ subjects), biopsies of an affected organ were lacking. Because other families in our cohort with the same GLA variant did have positive biopsies, these subjects were classified as non-classical, biopsy-proven disease.

CV prevalence and details

CV prevalence in the Dutch cohort is depicted in [table 3](#). Nearly all men in the classical group had CV (94%). The two subjects without CV had received >9 years of treatment with ERT at the time of CV assessment. These two men had the p.D136Y and

p.R342Q GLA variant causing complete absence of α GalA activity in leucocytes, very high lysoGb3 in plasma, acroparesthesia, white matter lesions and left ventricular hypertrophy. Eighty-two per cent of women in the classical group had CV, of whom five women had used amiodarone for cardiac rhythm abnormalities before or at the time of CV assessment. See [figure 2A](#) for an example of characteristic CV.

Of the 25 non-classical subjects, 4 (16%, three men and one woman) had CV. One woman and two men had the p.P389A variant, and one man had the p.R112H variant. The clinical and biochemical characteristics of the subject and family members with the p.R112H variant are described in detail by Smid *et al.*³⁶ The corneal changes in these patients were subtle and limited to one or two small subepithelial deposits, thereby differing from the typical whorl-like pattern that is seen in classical patients with FD ([figure 2B](#)). These subjects did not use medication that is associated with CV.

There were no false-positive cases (none of the subjects in the no-FD group had CV). For individuals who presented to our clinic with an uncertain diagnosis (groups non-classical and no-FD), the positive predictive value of CV is 1 and the negative predictive value is 0.25.

DISCUSSION

Screening for FD is often performed in high-risk groups, for example, among individuals with chronic kidney disease, left ventricular hypertrophy or stroke, which may be attributed to FD. If a genetic variant in the GLA gene is found, the diagnosis of FD can be uncertain since characteristic FD signs or symptoms are often lacking.⁴ CV assessment may be helpful in these cases. Our study revealed a high prevalence of 94% in classically affected men, and there were no false positives. In patients with FD with a classical phenotype, CV is usually diffuse with a typical whorl-like pattern. In patients with the non-classical phenotype, subtle changes were identified, which confirms previous findings of CV in individuals with a non-classical phenotype with the c.936+919G>A (IVS4+919G>A) variant.²² Our findings suggest that the presence of CV, in the absence of medication that may induce CV, confirms the diagnosis of classical or non-classical FD. The absence of CV, however, does not exclude FD. Especially in cases with a non-classical phenotype, CV may be absent, even if characteristic storage is present in an affected organ, such as the heart or kidney.

Figure 2 (A) Cornea verticillata (arrow) in a 45-year-old untreated woman with a classical Fabry disease (FD) phenotype. Arrow: origin of the pigmented verticillata. (B and C) Subtle cornea deposits (arrow) in a 36-year-old man with a non-classical FD phenotype.

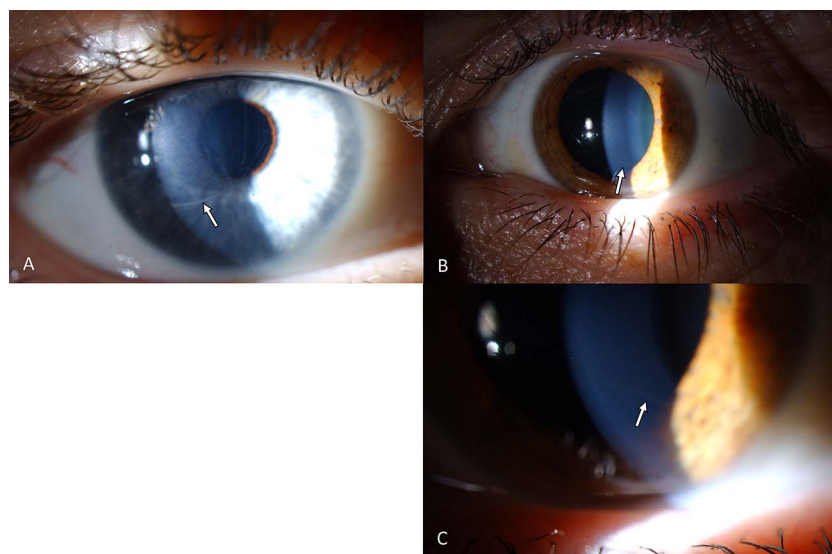


Table 1 Cornea verticillata (CV) prevalence in reviewed studies

Author	Year	Centre	Patients n (m/f)	CV prevalence		
				Total (%)	Men (%)	Women (%)
Allen*	2010	UK (Cambridge)	26 (12/14)	50	—	—
Barba Romero	2004	Spain	14 (14/0)	36	36	—
Beltran-Becerra	2012	Mexico	13 (7/6)	46	57	33
Borgwardt	2012	Denmark	10 (6/4)	90	83	100
Choi	2008	Korea	11 (8/3)	82	—	—
Falke	2009	Germany (Rostock)	22 (6/16)	46	50	44
Gupta*	2005	USA (Maryland)	57 (0/57)	82	—	82
Kaminsky	2013	France (Nancy)	108 (41/67)	54	51	55
Kobayashi	2008	Japan	36 (0/36)	50	—	50
Lin*	2010	Taiwan	52 (7/45)	29	14	31
Nguyen	2005	Australia	66 (34/32)	83	94	72
Orssaud	2003	France (Paris)	32 (32/0)	56	56	—
Pitz	2009	Germany (Mainz)	31 (15/16)	81	—	—
Rákóczi*	2007	Hungary	31 (15/16)	65	67	63
Reisin	2010	Argentina	54 (31/23)	96	94	100
Ries*	2003	Germany (Mainz), Italy (Milan), Sweden, UK (Cambridge)	33 (15/18)	76	73	78
Ries*	2005	USA (Maryland)	24 (24/0)	88	88	—
Sher	1979	USA (Minnesota)	62 (37/25)	92	95	88
Sodi	2013	Italy (Florence), Belgium (Charleroi), UK (London), Germany (Mainz)	35 (17/18)	89	94	83
Tøndel	2008	Norway	16 (9/7)	94	89	100
Whybra	2001	Germany (Mainz)	20 (0/20)	70	—	70
Total†			753 (330/423)	69	74	66

*Non-classical or uncertain cases were reported; see [table 2](#) for details.

†Only studies that reported gender-specific data were used for male and female prevalence.

—, not applicable or missing data; m/f, male/female.

The prevalence of CV among patients with FD in the literature is variable and generally lower in comparison to the Dutch cohort. This discrepancy is probably caused by the inclusion of subjects with a non-classical phenotype or even subjects with a neutral GLA variant in the reviewed studies. It was not possible to correct for this bias because the required clinical, biochemical and genetic details were most often not provided.

Additionally, age may have affected the prevalence of CV because of the inclusion of children in several studies. Borgwardt *et al*¹⁶ described two boys who started ERT treatment at the age of 10 and 12, in whom CV was absent at baseline, but who developed CV after 1 year of follow-up. These

cases suggest that CV may not always be present from birth. Although in the above cases ERT did not seem to influence the development of CV, the effect of ERT on CV has not been studied systematically and may have influenced the data. In the Dutch cohort, two men did not have CV at adulthood, while clinical and biochemical evaluation as well as the family history demonstrated a classical FD phenotype. As previously suggested by Sodi *et al*,³⁵ we postulate that long-term ERT may have corrected the corneal changes in these subjects.

This study focused on CV and did not study other ocular changes that are related to FD. Posterior lens cataract has previously been described as a specific feature in FD.³⁷ This type of

Table 2 CV prevalence in non-classical/uncertain cases in the literature

				CV prevalence						
Author	Year	n (m/f)	GLA variant	Total		Men		Women		Details
				Per cent	n	Per cent	n	Per cent	n	
Allen	2010	9 (6/3)	7x p.N215S 2x p.A143T	11	1	17	1	0	0	Mild CV in a 3.5-year-old boy with p.A143T (personal communication)
Gupta	2005	7 (0/7)	4x p.R112H 3x p.N215S	—	—	—	—	—	—	
Lin	2010	52 (7/45)	c.936+919G>A (IVS4+919G>A)	29	15	14	1	31	14	
Ries	2003	2 (2/0)	p.A143T	0	0	0	0	—	—	
Ries	2005	3 (3/0)	2x p.R112H 1x p.A97V	0	0	0	0	—	—	
Rákóczi	2007	4 (1/3)	p.N215S	—	—	—	—	—	—	

—, not applicable or missing data; CV, cornea verticillata; m/f, male/female.

Table 3 Dutch cohort.

Group (age median, range)	Median age (range)	n	Percentage CV (n, 95% CI)	Details
Classical				
Males	40 (19–65)	35	94% (33, 80–99)	2 subjects without CV received >9 years of treatment with ERT
Females	48 (19–81)	66	82% (54, 71–89)	5 subjects with CV received amiodarone treatment before or during CV assessment
Total		101	86% (87, 78–92)	
Non-classical				
Males	64 (36–74)	11	27% (3, 9–57)	In all patients with CV, corneal changes were minimal
Females	39 (18–78)	14	7% (1, <0.01–34)	
Total		25	16% (4, 6–35)	
Uncertain				
Males	49 (45–71)	5	0 (0–48)	
Females	57 (30–68)	6	0 (0–44)	
Total		11	0 (0–30)	
No FD				
Males	41 (23–70)	5	0 (0–48)	
Females	49 (52–46)	2	0 (0–71)	
Total		7	0 (0–40)	

CV, cornea verticillata, ERT, enzyme replacement therapy. FD, Fabry disease.

cataract has been reported in a few studies only with a prevalence up to 53% of men with FD.^{12 24 30 35}

Another FD-associated ocular feature is retinal vascular tortuosity. This feature has not often been reported in the literature. Importantly, and in analogy with tortuosity and dilatation of the cerebral basilar artery,^{38 39} the specificity is yet uncertain as tortuous and dilated retinal vessels are reported to be present in other diseases that affect the vasculature such as diabetes and may be subjected to age.⁴⁰ Because our study was observational and cataract and retinal vessels are not assessed routinely, these data were not available for the Dutch cohort.

In addition, we did not strive to study the nature of FD-related ocular changes, but we pursued to assess the diagnostic applicability of an assessment that is non-invasive and worldwide applicable in order to discern patients with a classical and non-classical FD phenotype from those without FD. We are confident that CV assessment, as the current most extensively studied and understood ocular feature in FD and with the highest prevalence, is the best suitable ophthalmological assessment to use for diagnostic purposes.

Data from the Dutch cohort show a correlation between CV and a classical FD phenotype or biopsy-proven non-classical FD. But the number of subjects who were classified as 'no FD' in this cohort is small. Further studies are needed to confirm that CV is not present in subjects with a neutral GLA variant (no FD), and thus, that the presence of CV predicts a classical or non-classical FD phenotype. We are confident, however, that the presence of diffuse CV with a whorl-like pattern can substitute the gold standard for FD (a biopsy of an affected organ) in patients with an uncertain diagnosis of FD. Whether this also applies to the more subtle changes that are usually seen in non-classical patients with FD should be subject of further studies.

In conclusion, in individuals with an uncertain diagnosis of FD, when no medication is used that can cause CV, the presence of CV provides evidence for FD.

Acknowledgements We thank Frouke Kingma, medical student at the University of Amsterdam, for her contribution to the literature study. Dick de Vries is acknowledged for his assistance with the cornea photography.

Contributors LvdT: study design, data acquisition, data analyses, data interpretation and first draft of manuscript. MLS: data acquisition and supervision,

data interpretation and revision of manuscript. MB and CEH: study design, data interpretation and revision of manuscript.

Funding This study was performed within the framework of the Dutch Top Institute Pharma (TIPharma, project number T6-504: 'Fabry or not Fabry: valorization of clinical and laboratory tools for improved diagnosis of Fabry disease'. TIPharma is a non-profit organisation that catalyses research by founding partnerships between academia and industry. Partners: Genzyme, a Sanofi company; Academic Medical Center, University of Amsterdam; Subsidiary Party: Shire HGT. <http://www.tipharma.com/pharmaceutical-research-projects/drug-discovery-development-and-utilisation/hamlet-study.html>. The industry partners had no role in the content of this manuscript.

Competing interests LvdT has received travel support and reimbursement of expenses from Actelion, Shire HGT or Genzyme. MB and CEH have received travel support, honoraria for consultancies and educational grants from Actelion, Genzyme, Shire HGT, Protalix or Amicus. All financial arrangements are made with the AMC Medical research BV in accordance with the AMC Research Code. MLS reader of retinal images in FIELD study, a randomised controlled trial, Genzyme.

Ethics approval Institutional review board/ethics committee ruled that approval was not required for this study.

Provenance and peer review Not commissioned; externally peer reviewed.

REFERENCES

- Desnick RJ, Ioannou YA, Eng CM. Chapter 150: α -Galactosidase A deficiency: Fabry disease. In: D Valle, ed. *The Online Metabolic and Molecular bases of Inherited Disease*. 2007:3733–74.
- Meikle PJ, Hopwood JJ, Clague AE, et al. Prevalence of lysosomal storage disorders. *JAMA* 1999;281:249–54.
- Poorthuis BJ, Wevers RA, Kleijer WJ, et al. The frequency of lysosomal storage diseases in The Netherlands. *Hum Genet* 1999;105:151–6.
- van der Tol L, Smid BE, Poorthuis BJ, et al. A systematic review on screening for Fabry disease: prevalence of individuals with genetic variants of unknown significance. *J Med Genet* 2014;51:1–9.
- van der Tol L, Cassiman D, Houge G, et al. Uncertain diagnosis of fabry disease in patients with neuropathic pain, angiokeratoma or cornea verticillata: consensus on the approach to diagnosis and follow-up. *JIMD Rep* 2014;17:83–90.
- Hollander DA, Aldave AJ. Drug-induced corneal complications. *Curr Opin Ophthalmol* 2004;15:541–8.
- Smid BE, van der Tol L, Cecchi F, et al. Uncertain diagnosis of Fabry disease: Consensus recommendation on diagnosis in adults with left ventricular hypertrophy and genetic variants of unknown significance. *Int J Cardiol* 2014;177:400–8.
- Froissart R, Guffon N, Vanier MT, et al. Fabry disease: D313Y is an alpha-galactosidase A sequence variant that causes pseudodeficient activity in plasma. *Mol Genet Metab* 2003;80:307–14.
- Yasuda M, Shabbeer J, Benson SD, et al. Fabry disease: characterization of alpha-galactosidase A double mutations and the D313Y plasma enzyme pseudodeficiency allele. *Hum Mutat* 2003;22:486–92.
- Agresti A, Coull BA. Approximate is better than "exact" for interval estimation of binomial proportions. *Am Stat* 1998;52:119–26.

- 11 Whybra C, Kampmann C, Willers I, *et al.* Anderson-Fabry disease: clinical manifestations of disease in female heterozygotes. *J Inherit Metab Dis* 2001;24:715–24.
- 12 Sher NA, Letson RD, Desnick RJ. The ocular manifestations in Fabry's disease. *Arch Ophthalmol* 1979;97:671–6.
- 13 Allen LE, Cosgrave EM, Kersey JP, *et al.* Fabry disease in children: correlation between ocular manifestations, genotype and systemic clinical severity. *Br J Ophthalmol* 2010;94:1602–5.
- 14 Barba Romero MA, De Lorenzo YM. Fabry's disease in Spain. Study of 24 cases. *Med Clin* 2004;123:57–60.
- 15 Beltran-Becerra KJ, Rios-Gonzalez BE, Gutierrez-Amavizca BE, *et al.* [Ophthalmic manifestations in Mexican patients with Fabry disease]. *Arch Soc Esp Oftalmol* 2012;87:373–5.
- 16 Borgwardt L, Feldt-Rasmussen U, Rasmussen AK, *et al.* Fabry disease in children: agalsidase-beta enzyme replacement therapy. *Clin Genet* 2013;83:432–8.
- 17 Choi JH, Cho YM, Suh KS, *et al.* Short-term efficacy of enzyme replacement therapy in Korean patients with Fabry disease. *J Korean Med Sci* 2008;23:243–50.
- 18 Falke K, Buttner A, Schittkowski M, *et al.* The microstructure of cornea verticillata in Fabry disease and amiodarone-induced keratopathy: a confocal laser-scanning microscopy study. *Graefes Arch Clin Exp Ophthalmol* 2009;247:523–34.
- 19 Gupta S, Ries M, Kotsopoulos S, *et al.* The relationship of vascular glycolipid storage to clinical manifestations of Fabry disease: A cross-sectional study of a large cohort of clinically affected heterozygous women. *Medicine* 2005;84:261–8.
- 20 Kaminsky P, Noel E, Jaussaud R, *et al.* Multidimensional analysis of clinical symptoms in patients with Fabry's disease. *Int J Clin Pract* 2013;67:120–7.
- 21 Kobayashi M, Ohashi T, Sakuma M, *et al.* Clinical manifestations and natural history of Japanese heterozygous females with Fabry disease. *J Inherit Metab Dis* Published Online First: 21 Jan 2008. doi:10.1007/s10545-007-0740-6
- 22 Lin HY, Huang CH, Yu HC, *et al.* Enzyme assay and clinical assessment in subjects with a Chinese hotspot late-onset Fabry mutation (IVS4 + 919G→A). *J Inherit Metab Dis* 2010;33:619–24.
- 23 Nguyen TT, Gin T, Nicholls K, *et al.* Ophthalmological manifestations of Fabry disease: a survey of patients at the Royal Melbourne Fabry Disease Treatment Centre. *Clin Experiment Ophthalmol* 2005;33:164–8.
- 24 Orssaud C, Dufier J, Germain D. Ocular manifestations in Fabry disease: a survey of 32 hemizygous male patients. *Ophthalmic Genet* 2003;24:129–39.
- 25 Pitz S, Grube-Einwald K, Renieri G, *et al.* Subclinical optic neuropathy in Fabry disease. *Ophthalmic Genet* 2009;30:165–71.
- 26 Rakoczi E, Gorogh S, Grubits J, *et al.* [Molecular pathology and clinical manifestations of Fabry disease]. *Orv Hetil* 2007;148:1087–94.
- 27 Reisin RC, Doxastakis G, Ferrari G, *et al.* Evaluation of patients with Fabry disease in Argentina. *Medicina* 2010;70:37–43.
- 28 Ries M, Gupta S, Moore DF, *et al.* Pediatric Fabry disease. *Pediatrics* 2005;115:e344–55.
- 29 Ries M, Ramaswami U, Parini R, *et al.* The early clinical phenotype of Fabry disease: a study on 35 European children and adolescents. *Eur J Pediatr* 2003;162:767–72.
- 30 Sodi A, Guarducci M, Vauthier L, *et al.* Computer assisted evaluation of retinal vessels tortuosity in Fabry disease. *Acta Ophthalmol* 2013;91:e113–19.
- 31 Tondel C, Bostad L, Hirth A, *et al.* Renal biopsy findings in children and adolescents with Fabry disease and minimal albuminuria. *Am J Kidney Dis* 2008;51:767–76.
- 32 De Brabander I, Yperzeele L, Ceuterick-De Groote C, *et al.* Phenotypical characterization of alpha-galactosidase A gene mutations identified in a large Fabry disease screening program in stroke in the young. *Clin Neurol Neurosurg* 2013;115:1088–93.
- 33 Nakao S, Takenaka T, Maeda M, *et al.* An atypical variant of Fabry's disease in men with left ventricular hypertrophy. *N Engl J Med* 1995;333:288–93.
- 34 Eng CM, Fletcher J, Wilcox WR, *et al.* Fabry disease: baseline medical characteristics of a cohort of 1765 males and females in the Fabry Registry. *J Inherit Metab Dis* 2007;30:184–92.
- 35 Sodi A, Ioannidis AS, Mehta A, *et al.* Ocular manifestations of Fabry's disease: data from the Fabry Outcome Survey. *Br J Ophthalmol* 2007;91:210–14.
- 36 Smid BE, Hollak CE, Poorthuis BJ, *et al.* Diagnostic dilemmas in Fabry disease: a case series study on GLA mutations of unknown clinical significance. *Clin Genet* Published Online First: 7 Jul 2014. doi:10.1111/cge.12449
- 37 Spaeth GL, Frost P. Fabry's disease. Its ocular manifestations. *Arch Ophthalmol* 1965;74:760–9.
- 38 Fellgiebel A, Keller I, Martus P, *et al.* Basilar artery diameter is a potential screening tool for Fabry disease in young stroke patients. *Cerebrovasc Dis* 2011;31:294–9.
- 39 Üçeyler N, Homola GA, Guerrero Gonzalez H, *et al.* Increased arterial diameters in the posterior cerebral circulation in men with Fabry disease. *PLoS ONE* 2014;9:e87054.
- 40 van der Tol L, Üçeyler N, Burlina A, *et al.* The value of specific brain imaging characteristics in the diagnosis of Fabry disease. 2014; submitted.

Supplementary table 1*Diagnostic criteria for a definite diagnosis of FD* (adopted from Smid et al with permission [1]).

Definite diagnosis of FD	
Males GLA variant + αGalA deficiency of ≤5% of mean reference value in leukocytes +	Females GLA variant + normal or deficient αGalA in leukocytes +
A or B or C A ≥1 characteristic FD sign/symptom (Fabry neuropathic pain, cornea verticillata or clustered angiokeratoma) B an increase of plasma (lyso)Gb3 (within range of males with definite FD diagnosis) C A family member with a definite FD diagnosis carrying the same GLA variant	
Uncertain diagnosis of FD	
Males/Females All patients presenting with a non-specific FD sign (such as LVH, stroke at young age, proteinuria) who do not fulfil the criteria for a definite diagnosis of FD have a GLA GVUS. Further evaluations are needed, following diagnostic algorithms**.	
Gold standard for uncertain FD diagnoses	
In subjects with an uncertain FD diagnosis, a GVUS and a non-specific FD sign, the demonstration of characteristic storage in the affected organ (e.g. heart, kidney, aside from skin) by electron microscopy analysis, according to the judgment of an expert pathologist, in the absence of medication that can lead to storage, confirms FD.	

***Definitions:**

Fabry neuropathic pain meets the 'characteristic clinical criteria' if there is neuropathic pain in hands and/or feet, starting before age 18 years or increasing with heat, fever. Quantitative sensory testing (QST) reveals a decreased cold detection threshold and the intraepidermal nerve fiber density is increased. There is no other cause for neuropathic pain.

Angiokeratoma meet the 'characteristic clinical criteria' if they are clustered and present in characteristic areas: bathing trunk area, lips, and umbilicus. There is no other cause for angiokeratoma.

Cornea verticillata meets the 'characteristic clinical criteria' if there is a whorl like pattern of corneal opacities. There is no other cause (medication induced, among other: amiodarone, chloroquine).

Abbreviations: GLA: α-Galactosidase A gene, αGalA: α-Galactosidase A enzyme, GVUS: genetic variant of unknown significance.

**For organ specific algorithms see Smid et al [1] and Van der Tol et al [2 3].

1. Smid BE, van der Tol L, Cecchi F, et al. Uncertain diagnosis of Fabry disease: Consensus recommendation on diagnosis in adults with left ventricular hypertrophy and genetic variants of unknown significance. *International journal of cardiology* 2014;**177**(2):400-08
2. van der Tol L, Svarstad E, Ortiz A, et al. Chronic kidney disease and an uncertain diagnosis of Fabry disease: Approach to a correct diagnosis. *Mol Genet Metab* 2014 epub ahead of print.
3. van der Tol L, Üçeyler N, Burlina A et al. The value of specific brain imaging characteristics in the diagnosis of Fabry disease 2014;submitted.