



OPEN ACCESS

Clinical science

# Papillary vitreous detachment as a possible accomplice in non-arteritic anterior ischaemic optic neuropathy

Dong Li ,<sup>1,2</sup> Shuo Sun,<sup>1</sup> Jingli Liang,<sup>1</sup> Yi Yue,<sup>1</sup> Jihong Yang,<sup>2</sup> Yuntao Zhi,<sup>2</sup> Xiaomin Zhang ,<sup>1</sup> Rongguo Yu,<sup>1</sup> Xiaorong Li <sup>1</sup>

► Additional supplemental material is published online only. To view, please visit the journal online (<http://dx.doi.org/10.1136/bjo-2022-322726>).

<sup>1</sup>Tianjin Key Laboratory of Retinal Functions and Diseases, Tianjin Branch of National Clinical Research Center for Ocular Disease, Eye Institute and School of Optometry, Tianjin Medical University Eye Hospital, Tianjin, China

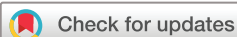<sup>2</sup>Department of Ophthalmology, Shanxi Eye Hospital, Taiyuan, China

## Correspondence to

Dr Xiaorong Li, Tianjin Medical University Eye Hospital, Tianjin, Tianjin, 300392, China; [xiaorli@163.com](mailto:xiaorli@163.com)

DL and SS are joint first authors. RY and XL are joint senior authors.

Received 13 October 2022  
Accepted 15 March 2023  
Published Online First  
13 April 2023



© Author(s) (or their employer(s)) 2024. Re-use permitted under CC BY-NC. No commercial re-use. See rights and permissions. Published by BMJ.

**To cite:** Li D, Sun S, Liang J, et al. *Br J Ophthalmol* 2024;**108**:607–612.

## ABSTRACT

**Aim** To evaluate the role of papillary vitreous detachment in the pathogenesis of non-arteritic anterior ischaemic optic neuropathy (NAION) by comparing the features of vitreopapillary interface between NAION patients and normal individuals.

**Methods** This study included 22 acute NAION patients (25 eyes), 21 non-acute NAION patients (23 eyes) and 23 normal individuals (34 eyes). All study participants underwent swept-source optical coherence tomography to assess the vitreopapillary interface, peripapillary wrinkles and peripapillary superficial vessel protrusion. The statistical correlations between peripapillary superficial vessel protrusion measurements and NAION were analysed. Two NAION patients underwent standard pars plana vitrectomy.

**Results** Incomplete papillary vitreous detachment was noted in all acute NAION patients. The prevalence of peripapillary wrinkles was 68% (17/25), 30% (7/23) and 0% (0/34), and the prevalence of peripapillary superficial vessel protrusion was 44% (11/25), 91% (21/23) and 0% (0/34) in the acute, non-acute NAION and control groups, respectively. The prevalence of peripapillary superficial vessel protrusion was 88.9% in the eyes without retinal nerve fibre layer thinning. Furthermore, the number of peripapillary superficial vessel protrusions in the superior quadrant was significantly higher than that in the other quadrants in eyes with NAION, consistent with the more damaged visual field defect regions. Peripapillary wrinkles and visual field defects in two patients with NAION were significantly attenuated within 1 week and 1 month after the release of vitreous connections, respectively.

**Conclusion** Peripapillary wrinkles and superficial vessel protrusion may be signs of papillary vitreous detachment-related traction in NAION. Papillary vitreous detachment may play an important role in NAION pathogenesis.

## INTRODUCTION

Non-arteritic anterior ischaemic optic neuropathy (NAION) is the most common acute optic neuropathy among older adults.<sup>1 2</sup> It typically presents as acute, painless and unilateral vision loss, with relative afferent pupillary defects, visual field defects and optic disc swelling.<sup>3</sup> Optic disc swelling and nerve compression are usually presumed to result from acute

## WHAT IS ALREADY KNOWN ON THIS TOPIC

⇒ In 2015, Parsa and Hoyt initially proposed a complete pathophysiological mechanism of how vitreous separation could cause non-arteritic anterior ischaemic optic neuropathy (NAION). However, there is a lack of dedicated imaging of papillary vitreous detachment-related traction in the development of NAION.

## WHAT THIS STUDY ADDS

⇒ Our study provides dedicated evidence of papillary vitreous detachment-related traction in the development of NAION using swept-source optical coherence tomography: peripapillary wrinkles and peripapillary superficial vessel protrusion, which supports Parsa and Hoyt's hypothesis.

## HOW THIS STUDY MIGHT AFFECT RESEARCH, PRACTICE OR POLICY

⇒ Our study suggests that papillary vitreous detachment is associated with NAION pathogenesis. Focusing on the vitreous status of such patients may be instructive for therapeutic intervention in the affected eyes and assessment and follow-up of the contralateral eye.

hypoperfusion or circulatory insufficiency of the short posterior ciliary arteries, which causes axonal degeneration and retinal ganglion cell apoptosis.<sup>3 4</sup> However, the pathophysiology of NAION is controversial, and no single mechanism has been definitively proven.<sup>5 6</sup>

In 2015, Parsa and Hoyt initially proposed a complete pathophysiologic mechanism for how vitreous separation could cause NAION and proposed renaming this kind of optic neuropathy as papillary vitreous detachment neuropathy.<sup>7</sup> This novel pathogenetic mechanism is further elaborated in detail.<sup>6 8–10</sup>

However, there is inadequate dedicated imaging of papillary vitreous detachment-related traction in NAION development. Therefore, we aimed to further evaluate the role of papillary vitreous detachment in NAION pathogenesis by comparing the features of the vitreopapillary interface between patients with NAION and

normal individuals using swept-source optical coherence tomography (SS-OCT).

## MATERIALS AND METHODS

### Participants

This study was approved by the Tianjin Medical University Eye Hospital Institutional Review Board and adhered to the Declaration of Helsinki. We evaluated NAION and normal individuals who underwent both SS-OCT scan and optical biometry and were eligible for inclusion from the Neuro-ophthalmology Service at Tianjin Medical University Eye Hospital (between 18 February 2022 and 13 May 2022). Patients with NAION were categorised as either acute ( $\leq 3$  weeks) or non-acute ( $> 3$  weeks) based on the disease course. Using this retrospective dataset of NAION patients with NAION and normal subjects, we aimed to evaluate the features of the vitreopapillary interface between patients with NAION and normal subjects and explore signs of papillary vitreous detachment-related traction in NAION by using SS-OCT. Subsequently, we consecutively collected eligible NAION and normal individuals who underwent SS-OCT and optical biometry to detect and verify these identified signs (between 13 May 2022 and 3 August 2022).

The inclusion criteria for NAION patients were acute visual loss, relative afferent pupillary defect and characterised visual field defects consistent with optic neuropathy.<sup>3</sup> The exclusion criteria included: (1) inflammatory, hereditary, traumatic and other causes of optic nerve diseases; (2) retinopathy, such as high myopia and proliferative diabetic retinopathy (3) obvious turbidity of the refractive medium.

For control individuals, a randomised clinical trial with an observational cohort indicated that fellow eyes in patients with new NAION were at a high risk of developing NAION.<sup>11</sup> Since we cannot predict contralateral eye occurrence, we randomly collected normal eyes instead of contralateral eyes as the control group.

Therefore, the inclusion criteria for normal individuals were (1) age, sex, hypertension and diabetes matched with NAION patients; (2) incomplete or complete papillary vitreous detachment; (3) best-corrected visual acuity (BCVA)  $\geq 0.8$ ; (4) intraocular pressure (IOP)  $\leq 21$  mm Hg with no history of elevated IOP; (5) no history of optic neuropathy, optic pathway or central nervous system disorders; (6) no obvious turbidity of the refractive medium and no history of ocular trauma. The exclusion criteria were (1) axial length  $\geq 25.5$  mm (2) absence of papillary vitreous detachment.

It is worth mentioning that the reason why we specially recruited and observed some control individuals with papillary vitreous detachment is to explore whether vitreous body-induced vessel and nerve traction will also occur in the process of papillary vitreous detachment in normal people.

### SS-OCT data acquisition and processing

All study participants were examined using SS-OCT (VG200, SVision Imaging, Luoyang, China). A  $6 \times 6$  mm and  $12 \times 12$  mm cube scan centred automatically on the optic disc and fovea, respectively, were obtained (online supplemental eFigure 1C,D). Images were acquired using a 1050 nm light source.<sup>12</sup> The retinal nerve fibre layer (RNFL) structure was measured in the peripapillary area using the VG200 along a 3.45 mm circle diameter around the optic nerve head (online supplemental eFigure 1A,B). Circular peripapillary and macular area OCT scans were used to assess the presence of papillary vitreous detachment and peripapillary wrinkles and superficial vessel protrusion

at the vitreous–papillary interface. Peripapillary superficial vessel protrusion is a phenomenon found on circular peripapillary OCT imaging, defined as peripapillary superficial retinal vessels protruding over the surface of the nerve fibre layer with or without adhesion to the vitreous body, which was thought to be pulled by the vitreous body. Two blinded junior readers individually assessed and calculated the number of peripapillary superficial vessel protrusions in all OCT images in parallel. An independent data transcriptionist recorded discrepant values between junior readers. When both readers recorded equivalent measurements, the value was accepted for data analysis without arbitration. Otherwise, the average of the measurements was used for data analysis. Senior readers arbitrated all measurements used for data analysis.

### Statistical analysis

Statistical analyses were performed using SPSS software (IBM SPSS Statistics V.26, New York). Descriptive statistics included mean, SD, median, IQR and percentages, where appropriate. The  $\chi^2$  test was used to compare the sex, hypertension and diabetes of participants in the acute and non-acute NAION and control groups. One-way analysis of variance (ANOVA) for independent samples was used to compare axial lengths. The Kruskal-Wallis test for independent samples was used to compare age, BCVA, spherical equivalent, C/D, Vertical C/D, RNFL thickness, cup area, cup volume, optic disc area and RIM area (area between the optic disc margin and cup area) between each group. Student's t test and ANOVA were used to analyse the number of peripapillary superficial vessel protrusion in NAION eyes.  $P < 0.05$  was considered statistically significant for all analyses, and all  $P$  values were from two-sided tests.

## RESULTS

### Patient characteristics

The study population consisted of 25 eyes of 22 patients with acute NAION (median age, 56 years), 23 eyes of 21 patients with non-acute NAION (median age, 52 years) and 34 eyes of 23 healthy individuals (median age, 52 years). Table 1 summarises the distribution of demographic and ocular characteristics of all groups. No statistically significant differences were observed between the groups in terms of age ( $p = 0.155$ ), sex ( $p = 0.074$ ), spherical equivalent ( $p = 0.784$ ) and some systemic risk factors such as hypertension ( $p = 0.581$ ) and diabetes ( $p = 0.056$ ). Significant differences were found in the axial length ( $p = 0.001$ ), BCVA ( $p = 0.000$ ), C/D ( $p = 0.000$ ), vertical C/D ( $p = 0.000$ ), RNFL thickness ( $p = 0.000$ ), cup area ( $p = 0.000$ ), cup volume ( $p = 0.000$ ), optic disc area ( $p = 0.000$ ) and RIM area ( $p = 0.000$ ).

### Papillary vitreous detachment is the premise for dynamic traction on the optic disc

The prevalence of incomplete papillary vitreous detachment was 100% and 92% in the acute and non-acute groups (two patients with non-acute NAION had complete papillary vitreous detachment), respectively. Once vitreous detachment occurs, the vitreous can move easily. Vitreous movement, vis-à-vis the optic disc, can generate forces on vitreo-glial-axonal attachments in the peripapillary and papillary areas. Although it is difficult to detect these transient forces before NAION onset, we can present dynamic papillary vitreous detachment-related traction in patients diagnosed with NAION. In case 1, SS-OCT revealed optic disc swelling and incomplete papillary vitreous detachment in both eyes and vitreous haemorrhage in the right eye at initial presentation (figure 1A1,B1,C1,D1,E1,F1). Intriguingly,

**Table 1** Demographic and ocular characteristics of the study population

Groups (eyes)	Acute (n=25)	Non-acute (n=23)	Normal (n=34)	P value
Age, median (IQR), years	56 (50–61.5)	52 (46–57)	52 (50–61)	0.155
Sex (male/female)	18/7	15/8	15/19	0.074
BCVA, logMAR, median (IQR)	0.10 (0.00–0.61)	0.22 (0.00–0.40)	0.00 (0.00–0.00)	0.000
Spherical equivalent, median (IQR)	0.00 (0.56–1.38)	0.00 (0.50–0.50)	0.00 (0.56–0.72)	0.784
Axial length, mean (SD), mm	22.61±0.93	22.75±0.63	23.44±1.03	0.001
C/D, median (IQR)	0.00 (0.00–0.07)	0.25 (0.00–0.55)	0.48 (0.33–0.64)	0.000
Vertical C/D ratio, median (IQR)	0.00 (0.00–0.05)	0.22 (0.00–0.52)	0.46 (0.31–0.59)	0.000
RNFL thickness, median (IQR), µm	217.00 (184.00–325.00)	68.00 (57.00–91.00)	104.50 (100.00–111.25)	0.000
Cup area, median (IQR), mm <sup>2</sup>	0.00 (0.00–0.02)	0.15 (0.00–0.67)	0.45 (0.20–0.93)	0.000
Cup volume, median (IQR), mm <sup>3</sup>	0.000 (0.000–0.001)	0.008 (0.000–0.264)	0.300 (0.053–0.904)	0.000
Optic disc area, median (IQR), mm <sup>2</sup>	4.70 (3.52–5.36)	2.61 (2.02–2.96)	2.17 (1.90–2.57)	0.000
RIM area, median (IQR), mm <sup>2</sup>	4.68 (3.52–5.36)	2.12 (1.64–2.45)	1.64 (1.44–1.88)	0.000
Hypertension (yes/no)	12/13	8/15	16/18	0.581
Diabetes (yes/no)	10/15	4/19	5/29	0.056

Data are presented as mean±SD or median (IQR). Differences were considered statistically significant at p<0.05.  
BCVA, best-corrected visual acuity; C/D, cup/disc; LogMAR, logarithm of the minimum angle of resolution; RNFL, retinal nerve fibre layer.

a 10-day follow-up visit showed mild foveal vitreous macular traction (VMT) in the left eye (figure 1A2,B2,C2,D2,E2,F2). Furthermore, severe VMT with foveal anatomical deformation was present in both eyes at the 20-day follow-up (figure 1A3,B3,C3,D3,E3,F3). Papillofoveal traction has previously been implicated in the pathogenesis of macular hole.<sup>13 14</sup> In such patients, there is an abnormal attachment of the vitreous to the optic disc margin and fovea, resulting in papillofoveal tractional forces,<sup>15</sup> which partially demonstrates that incomplete papillary vitreous detachment causes dynamic traction on the optic disc.

### Peripapillary wrinkles may be induced by papillary vitreous detachment-related traction

In 1936, Paton described peripapillary wrinkles in papilledema on fundus examinations.<sup>16</sup> Peripapillary wrinkles were defined as closely spaced concentric or spiral folds within half the disc diameter of the optic disc head, and they were confined to the RNFL.<sup>17</sup> Kupersmith *et al*<sup>18</sup> found that peripapillary wrinkles can also be detected in NAION on OCT.<sup>18</sup> Our study also found obvious peripapillary wrinkles in patients with either acute or non-acute NAION. The prevalence of peripapillary wrinkles was 17/25 (68%), 7/23 (30%) and 0/34 (0%) in the acute, non-acute NAION and control groups, respectively. In case 2, the OCT scan showed mild peripapillary wrinkles on the vitreous–peripapillary interface with incomplete papillary vitreous detachment in the left eye at initial presentation (figure 2A1,B1,C1). At 15 days after onset, significant wrinkles on the vitreous–peripapillary interface were found around the left eye (figure 2A2,B2,C2). Although patients received neuroprotective treatment for 2 weeks, there was no regression of optic disc swelling in the left eye in 22 days. Furthermore, more severe wrinkles occurred on the vitreous–peripapillary interface and in the fovea (figure 2A3,B3,C3,D,E). Meanwhile, papillary vitreous detachment was continued (figure 2A1,A2,A3). Intriguingly, the peripapillary wrinkles in case 2 and another patient significantly reduced following pars plana vitrectomy (PPV) (figure 4A,B and online supplemental eFigure 3A,B), which will be discussed later. Therefore, we speculate that vitreous separation may play an important role in peripapillary wrinkle formation.

### Peripapillary superficial vessel protrusion may be a sign of papillary vitreous detachment-related traction in NAION

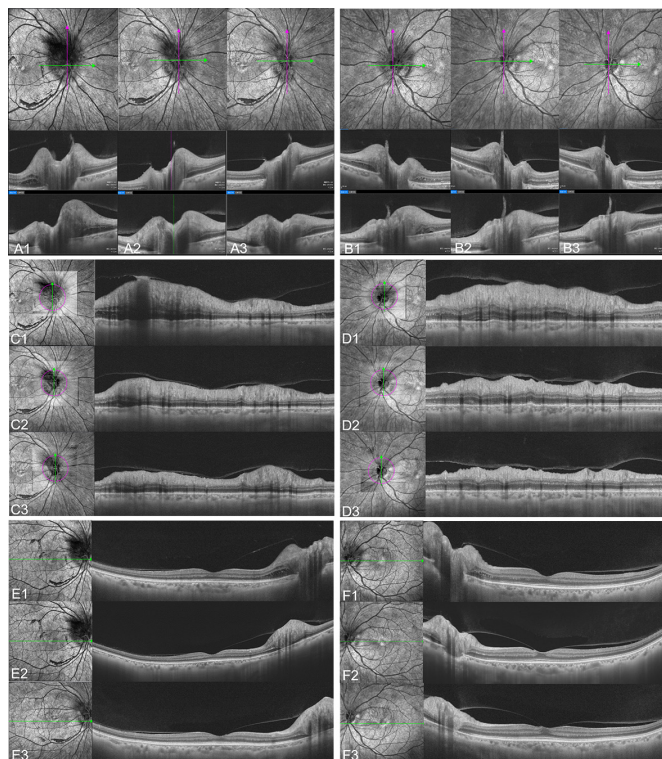
Several previous studies have described peripapillary haemorrhage due to papillary vitreous detachment.<sup>19 20</sup> In our study, there was strong evidence of peripapillary haemorrhage in 72% of acute NAION patients. Interestingly, after carefully reviewing the full set of high-resolution SS-OCT scans, we found peripapillary superficial vessels protruding over the surface of the nerve fibre layer with or without adhesion to the vitreous body in eyes with NAION (figure 2D and online supplemental eFigure 2). The prevalence of peripapillary superficial vessel protrusion was 44% (11/25), 91% (21/23) and 0% (0/34) in the acute, non-acute NAION and control groups, respectively. The number of peripapillary superficial vessel protrusions in the superior quadrant was significantly higher than that in the other quadrants (p<0.0001), consistent with the more damaged visual field defect regions of NAION (inferior region) (figure 3A,B).<sup>21 22</sup>

However, blood vessels can become exposed on the surface of the thinned RNFL in some optic disorders, such as glaucoma,<sup>23</sup> which is similar to peripapillary superficial vessel protrusion. OCT instruments can provide a circular peripapillary OCT colour-code report for prompting ophthalmologists that a numeric RNFL value falls within or outside the normal range relative to the reference database.<sup>24</sup> Therefore, we regrouped patients with non-acute NAION into eyes with or without RNFL thinning in the superior quadrant. The prevalence of peripapillary superficial vessel protrusion in the superior quadrant (89%) was very high in eyes without RNFL thinning. These results indicate that peripapillary superficial vessel protrusion is not caused by RNFL thinning but may be triggered by the vitreous body.

Overall, our findings suggest that peripapillary wrinkles and peripapillary superficial vessel protrusion may be signs of papillary vitreous detachment-related traction in NAION.

### DISCUSSION

Parsa and Hoyt combed through a spectrum of consequences of vitreopapillary traction and separation, initially proposed as NAION caused by vitreous separation on the optic disc.<sup>7</sup> Parsa suggested that this perception is open to scrutiny and encouraged researchers to use more imaging technologies to further



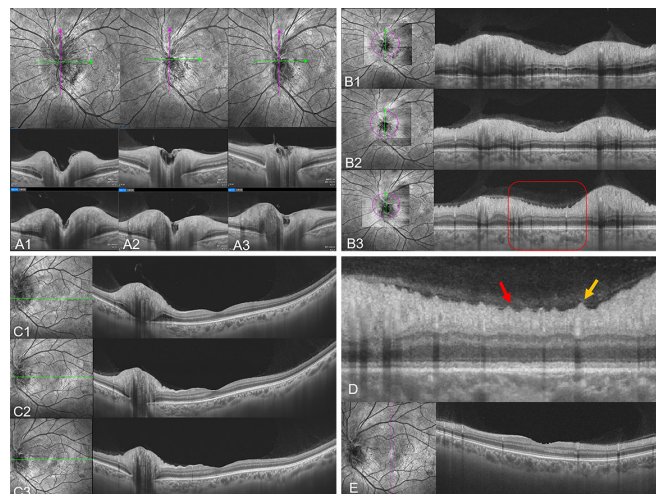
**Figure 1** Representative swept-source optical coherence tomography (SS-OCT) scans in a patient with bilateral non-arteritic anterior ischaemic optic neuropathy (NAION). A 62-year-old woman presented with a black film over the visual field of both eyes for 10 days (case 1). (A) Scanning laser ophthalmoscopy (SLO) and optical coherence tomography (OCT) scans of the right optic disc in the same direction at initial presentation (1), 10-day follow-up (2) and 20-day follow-up (3). (B) SLO and OCT scans of the left optic disc in the same direction at initial presentation (1), 10-day follow-up (2) and 20-day follow-up (3). (C) Imaging of circular peripapillary OCT scans in the right eye at initial presentation (1), 10-day follow-up (2) and 20-day follow-up (3). (D) Imaging of circular peripapillary OCT scans in the left eye at initial presentation (1), 10-day follow-up (2) and 20-day follow-up (3). (E) Macular OCT scan of the right eye at initial presentation (1), 10-day follow-up (2) and 20-day follow-up (3). (F) Macular OCT scan of the left eye at initial presentation (1), 10-day follow-up (2) and 20-day follow-up (3).

clarify the role of vitreous separation in mechanical dynamic stretch injury to the optic disc in patients with NAION.<sup>6</sup>

Our study provides reliable evidence of papillary vitreous detachment-related traction in NAION development using SS-OCT: peripapillary wrinkles and peripapillary superficial vessel protrusion, supporting Parsa and Hoyt's hypothesis.<sup>7</sup>

In our study, we speculated that vitreous separation might play an important role in peripapillary wrinkle formation. As expected, peripapillary wrinkles in two NAION patients were significantly reduced within 1 week after the release of vitreous connections. These results indicate that dynamic vitreous traction induces peripapillary wrinkles in NAION patients. Although prior work by Kupersmith *et al* on peripapillary wrinkles attributed it to oedema,<sup>18</sup> we could not ignore the effect of vitreous separation on peripapillary wrinkles.

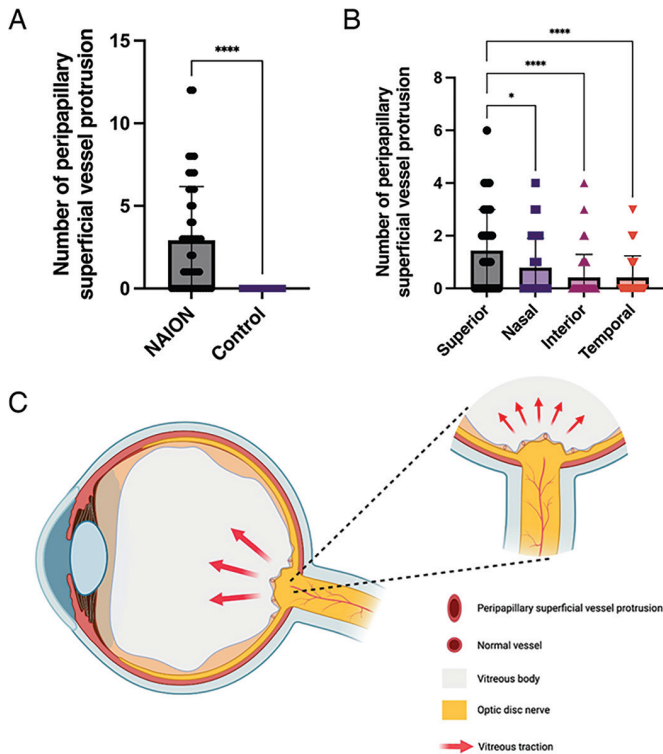
We also found a novel sign that may be caused by papillary vitreous detachment-related traction in NAION patients: peripapillary superficial vessel protrusion (online supplemental eFigure 2). Although optic disc swelling was ameliorated in the



**Figure 2** Representative SS-OCT scans in a patient with unilateral NAION. A 43-year-old man presented with vision disturbance in his left eye for 8 days (case 2). (A) SLO and OCT scans of the left optic disc in the same direction at initial presentation (1), 7-day follow-up (2), and 14-day follow-up (3). (B) Imaging of circular peripapillary OCT scans in the left eye at initial presentation (1), 7-day follow-up (2), and 14-day follow-up (3). (C) Horizontal macular OCT scan of the left eye at initial presentation (1), 7-day follow-up (2), and 14-day follow-up (3). (D) The image shows a higher magnification view of the peripapillary wrinkles (red arrow) and peripapillary superficial vessel protrusion (yellow arrow). (E) Vertical macular OCT scan of the left eye at 14-day follow-up. NAION, non-arteritic anterior ischaemic optic neuropathy; OCT, optical coherence tomography; SLO, scanning laser ophthalmoscopy; SS-OCT, swept-source optical coherence tomography.

non-acute phase, these vascular protrusions persisted, indicating a permanent change following vitreous traction. We further compared the number of peripapillary superficial vessel protrusions in the different quadrants. The number of vitreous-pulled peripapillary vessels in the superior quadrant was significantly higher than in other quadrants. This suggests that the superior vessels are more susceptible to being pulled. Presumably, the superior nerve fibres are also more susceptible to being pulled, consistent with more damaged visual field defects in patients with NAION.<sup>21</sup> Furthermore, it is consistent with the direction of vitreous detachment, and spontaneous papillary vitreous detachment usually starts from the superior section due to the influence of gravity. This type of shearing force reaches the maximum kinetic energy when papillary vitreous detachment reaches the superior area around the optic disc.<sup>20 25</sup>

However, there are still some conflicting opinions on whether papillary vitreous detachment causes NAION.<sup>26–28</sup> Some studies have argued that papillary vitreous detachment is not related to classical NAION development because vitreopapillary traction was not detected in any eye with NAION using spectral domain optical coherence tomography (SD-OCT).<sup>26 27</sup> The traditional designation of 'vitreopapillary traction' is associated with a static angulated V-shaped hyaloid vitreous.<sup>26</sup> Parsa suggested that vitreopapillary traction should not be confused with dynamic papillary vitreous detachment.<sup>6</sup> First, once the vitreous body begins to undergo liquefaction and papillary vitreous detachment, it is kinetic in the eye and has traction related to the body position or the rapid eye movement sleep process.<sup>29</sup> Second, the traction generated from the separation of the optic disc and vitreous body is not necessarily persistent or 'V-shaped' on OCT scan, it may be intermittent.<sup>6</sup> These instantaneous and



**Figure 3** Peripapillary superficial vessel protrusion significantly increased in patients with NAION. (A) The number of peripapillary superficial vessel protrusions was quantified and compared between NAION and control eyes. (B) The number of peripapillary superficial vessel protrusions was quantified and compared between the different quadrants in eyes with NAION. (C) Schematic diagram of papillary vitreous detachment-related traction in patients with NAION. NAION, non-arteritic anterior ischaemic optic neuropathy.

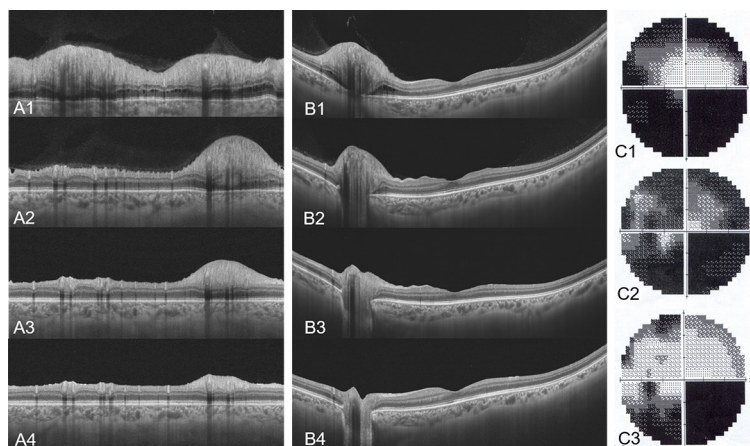intermittent forces produced in papillary vitreous detachment are difficult to capture using OCT. This differs from the static or V-shaped vitreous traction mentioned previously.

In case 1, OCT showed incomplete papillary vitreous detachment in both eyes on initial presentation. VMT was observed during follow-up. Papillofoveal traction has already been shown

to be related to the pathogenesis of the macular hole.<sup>13 14</sup> The vitreopapillary adhesion produces centrifugal tangential traction on the fovea,<sup>15</sup> leading to the formation of the macular hole. Similarly, this adhesion also enhances the traction on the optic disc, while the image does not necessarily present as a ‘V-shape’ on the OCT scan. In other words, as long as papillary vitreous detachment occurs, there will be dynamic and intermittent vitreous traction on the optic disc, even if it does not appear as ‘V shape’ on the OCT scan. Furthermore, incomplete papillary vitreous detachment was also noted in 100% of patients with acute NAION using SS-OCT in our study, which was much higher than normal (68%), in accordance with previous studies.<sup>30 31</sup> This suggests that the premise of dynamic vitreous traction already exists in such patients.

Papillary vitreous detachment is a dynamic and occasionally rapid process of vitreous separation. Vitreous separation alone is insufficient for producing NAION, as vitreous separation speed at the papilla level and age-related axonal fragility are two other main factors.<sup>6</sup> When such papillary vitreous detachment is accompanied by vision loss and visual field defects, occasionally rapid vitreous traction on the papilla caused by a rotational body or eye movement may trigger further axonal rupture and progressive vision loss frequently referred to as ‘progressive’ or ‘recurrent’ NAION.<sup>6</sup> At the 2-month follow-up, case 2 had a worsened visual field defect. The patient underwent a standard PPV to diminish the potential shearing force that may injure the remaining axons. Surprisingly, the visual field defect in this patient was partially attenuated in the first month after the release of vitreous connections (figure 4C1–3). Another patient with NAION also underwent standard PPV with vitreous connection release 20 days after the onset of visual symptoms, which partially improved the visual field (online supplemental eFigure 3C1–2). These results demonstrate that releasing vitreous connections can ameliorate visual field defects but not complete recovery.

In 2007, Modarres *et al* also performed standard PPV in some NAION patients with posterior vitreous detachment.<sup>32</sup> They proposed that persistent traction following incomplete papillary vitreous detachment could give rise to NAION, not that the separation of the vitreous body itself was the cause of NAION.



**Figure 4** Release of vitreous connections significantly reduces peripapillary wrinkles and partially attenuates visual field defects. A 43-year-old man presented with vision disturbance in his left eye for 8 days (case 2). (A) Imaging of circular peripapillary optical coherence tomography (OCT) scans in the left eye at initial presentation (1), before pars plana vitrectomy (PPV) (2), 1-week follow-up after PPV (3) and at 1-month follow-up after PPV (4). (B) Macular OCT scan of the left eye at initial presentation (1), before PPV (2), at 1-week follow-up after PPV (3) and at 1-month follow-up after PPV (4). (C) Visual field test in the left eye at initial presentation (1), before PPV (2) and at 1-month follow-up after PPV (3).

Compared with SD-OCT, SS-OCT can provide relatively intact information about the posterior vitreous structure, including the posterior cortex.<sup>33</sup> Our study had some limitations. The sample size was small, and we could not obtain OCT images from patients before the onset of NAION symptoms. In the future, larger sample size observations are required, including close observation of the contralateral vitreous state and imaging of the vitreous–papillary interface before the onset of NAION symptoms, which will provide clearer insight into the role of papillary vitreous detachment in the pathogenesis of NAION.

## CONCLUSIONS

Our study found evidence of papillary vitreous detachment-related traction accompanying NAION development following a comparison of the vitreous–papillary interface in NAION patients with normal individuals, suggesting that papillary vitreous detachment may be associated with the pathogenesis of NAION. Focusing on the vitreous status of such patients may be instructive for therapeutic intervention in the affected eyes and assessment and follow-up of the contralateral eye.

**Contributors** XL is guarantor. XL, RY, SS and DL contributed to the study conception and design. Data collection and analysis were performed by DL, JL, YY, JY, YZ, XZ.

**Funding** The study was supported by National Natural Science Foundation of China (82171085); Key Project of Internet Cross-Border Integration Innovation and Technology of Tianjin (18ZXRHSY00210); Tianjin Key Medical Discipline (Specialty) Construction Project (TJYXZDXK-037A); Science and Technology Project of Tianjin Binhai New Area Health Commission (2022BWKQ011); The Natural Science Foundation of Tianjin City (22JCQNJC01220).

**Competing interests** None declared.

**Patient consent for publication** Consent obtained directly from patient(s).

**Ethics approval** The Tianjin Medical University Eye Hospital Institutional Review Board ID: 2022KY(L)-15. Participants gave informed consent to participate in the study before taking part.

**Provenance and peer review** Not commissioned; externally peer reviewed.

**Data availability statement** No data are available.

**Supplemental material** This content has been supplied by the author(s). It has not been vetted by BMJ Publishing Group Limited (BMJ) and may not have been peer-reviewed. Any opinions or recommendations discussed are solely those of the author(s) and are not endorsed by BMJ. BMJ disclaims all liability and responsibility arising from any reliance placed on the content. Where the content includes any translated material, BMJ does not warrant the accuracy and reliability of the translations (including but not limited to local regulations, clinical guidelines, terminology, drug names and drug dosages), and is not responsible for any error and/or omissions arising from translation and adaptation or otherwise.

**Open access** This is an open access article distributed in accordance with the Creative Commons Attribution Non Commercial (CC BY-NC 4.0) license, which permits others to distribute, remix, adapt, build upon this work non-commercially, and license their derivative works on different terms, provided the original work is properly cited, appropriate credit is given, any changes made indicated, and the use is non-commercial. See: <http://creativecommons.org/licenses/by-nc/4.0/>.

## ORCID iDs

Dong Li <http://orcid.org/0000-0002-7607-8053>

Xiaomin Zhang <http://orcid.org/0000-0003-4898-4152>

Xiaorong Li <http://orcid.org/0000-0003-0641-2797>

## REFERENCES

- Hattenhauer MG, Leavitt JA, Hodge DO, *et al*. Incidence of nonarteritic anterior ischemic optic neuropathy. *Am J Ophthalmol* 1997;123:103–7.

- Augstburger E, Ballino A, Keilani C, *et al*. Follow-up of nonarteritic anterior ischemic optic neuropathy with optical coherence tomography angiography. *Invest Ophthalmol Vis Sci* 2021;62:42.
- Biousse V, Newman NJ. Ischemic optic neuropathies. *N Engl J Med* 2015;372:2428–36.
- Rizzo JF. Unraveling the enigma of nonarteritic anterior ischemic optic neuropathy. *J Neuroophthalmol* 2019;39:529–44.
- Arnold AC. Pathogenesis of nonarteritic anterior ischemic optic neuropathy. *J Neuroophthalmol* 2003;23:157–63.
- Parsa CF, Williams ZR, Van Stavern GP, *et al*. Does vitreopapillary traction cause nonarteritic anterior ischemic optic neuropathy? *J Neuroophthalmol* 2022;42:260–71.
- Parsa CF, Hoyt WF. Nonarteritic anterior ischemic optic neuropathy (NAION): a misnomer. Rearranging pieces of a puzzle to reveal a nonischemic papillopathy caused by vitreous separation. *Ophthalmology* 2015;122:439–42.
- Parsa CF. Reply: to PMID 25703466. *Ophthalmology* 2015;122:e74–5.
- Parsa CF, Hoyt WF. Reply: to PMID 25703466. *Ophthalmology* 2015;122.
- Parsa CF. Reply: to PMID 26592683. *Ophthalmology* 2015;122:e76–7.
- Newman NJ, Scherer R, Langenberg P, *et al*. The fellow eye in NAION: report from the ischemic optic neuropathy decompression trial follow-up study. *Am J Ophthalmol* 2002;134:317–28.
- Yang J, Wang E, Yuan M, *et al*. Three-dimensional choroidal vascularity index in acute central serous chorioretinopathy using swept-source optical coherence tomography. *Graefes Arch Clin Exp Ophthalmol* 2020;258:241–7.
- Chauhan DS, Antcliff RJ, Rai PA, *et al*. Papillofoveal traction in macular hole formation: the role of optical coherence tomography. *Arch Ophthalmol* 2000;118:32–8.
- Wang MY, Nguyen D, Hindoyan N, *et al*. Vitreous–papillary adhesion in macular hole and macular pucker. *Retina* 2009;29:644–50.
- Sebag J, ed. *Vitreous: in health and disease*. New York: Springer, 2014.
- Paton L. Papilledema and optic neuritis. *Arch Ophthalmol* 1936;15:1.
- Sibony PA, Kupersmith MJ, Feldon SE, *et al*. Retinal and choroidal folds in papilledema. *Invest Ophthalmol Vis Sci* 2015;56:5670–80.
- Kupersmith MJ, Sibony PA, Dave S. Nonarteritic anterior ischemic optic neuropathy induced retinal folds and deformations. *Invest Ophthalmol Vis Sci* 2017;58:4286–91.
- Cibis GW, Watzke RC, Chua J. Retinal hemorrhages in posterior vitreous detachment. *Am J Ophthalmol* 1975;80:1043–6.
- Katz B, Hoyt WF. Intrapapillary and peripapillary hemorrhage in young patients with incomplete posterior vitreous detachment. signs of vitreopapillary traction. *Ophthalmology* 1995;102:349–54.
- Hayreh SS, Zimmerman B. Visual field abnormalities in nonarteritic anterior ischemic optic neuropathy: their pattern and prevalence at initial examination. *Arch Ophthalmol* 2005;123:1554–62.
- Lee YH, Kim KN, Heo DW, *et al*. Difference in patterns of retinal ganglion cell damage between primary open-angle glaucoma and non-arteritic anterior ischaemic optic neuropathy. *PLOS ONE* 2017;12:e0187093.
- Chen TC. Spectral domain optical coherence tomography in glaucoma: qualitative and quantitative analysis of the optic nerve head and retinal nerve fiber layer (an aosis thesis). *Trans Am Ophthalmol Soc* 2009;107:254–81.
- Kim CY, Jung JW, Lee SY, *et al*. Agreement of retinal nerve fiber layer color codes between Stratus and Cirrus OCT according to glaucoma severity. *Invest Ophthalmol Vis Sci* 2012;53:3193–200.
- Schepens CL. Clinical aspects of pathologic changes in the vitreous body. *Am J Ophthalmol* 1954;38:8–21.
- Thompson AC, Bhatti MT, Gospe SM. Spectral-domain optical coherence tomography of the vitreopapillary interface in acute nonarteritic anterior ischemic optic neuropathy. *Am J Ophthalmol* 2018;195:199–208.
- Molaie AM, Pramil V, Hedges TR 3rd, *et al*. Vitreoretinal findings in nonarteritic ischemic optic neuropathy. *J Neuroophthalmol* 2022;42:e124–9.
- Lee MS, Foroozan R, Kosmorsky GS. Posterior vitreous detachment in AION. *Ophthalmology* 2009;116:597.
- Tsukahara M, Mori K, Gehlbach PL, *et al*. Posterior vitreous detachment as observed by wide-angle OCT imaging. *Ophthalmology* 2018;125:1372–83.
- Sanjari MS, Falavarjani KG, Mohammad-Mehdi P, *et al*. Vitreopapillary traction in nonarteritic anterior ischemic optic neuropathy. *Iran J Ophthalmic Res* 2006;1:110–2.
- Parsa CF, Hoyt WF. Nonarteritic anterior ischemic optic neuropathy (NAION): a misnomer. A non-ischemic papillopathy caused by vitreous separation. *Acta Ophthalmol* 2015;93:n.
- Modarres M, Sanjari MS, Falavarjani KG. Vitrectomy and release of presumed epipapillary vitreous traction for treatment of nonarteritic anterior ischemic optic neuropathy associated with partial posterior vitreous detachment. *Ophthalmology* 2007;114:340–4.
- Schaal KB, Pang CE, Pozzoni MC, *et al*. The premacular bursa's shape revealed in vivo by swept-source optical coherence tomography. *Ophthalmology* 2014;121:1020–8.

