

Recurrence of pterygium after excision

R. M. YOUNGSON

St. John Ophthalmic Hospital, Jerusalem

Pterygium is so common among Israeli Arabs that they have a vernacular word for the condition (*duffir*—literally “a fingernail”). In Jerusalem, many hundreds of these patients attend for treatment each year, and since conservative measures are ineffective one repeatedly faces the decision whether surgical interference is justified. This study was undertaken to enquire into the effects of the excision of pterygia: the results were unexpectedly interesting and seem to throw some light on the nature and aetiology of this minor but surprisingly enigmatic lesion.

During 1970 I operated on 174 patients with pterygium, 66 (38 per cent.) being males and 108 (62 per cent.) females. Previous experiences of poor result after various recommended techniques (Majoros, 1950; Rosenthal, 1953; Cabanas, 1953; Sato, 1954; Kamel, 1954; Newton, 1957; Escapini, 1958; Fry, 1959; Pierse and Casey, 1959; Rankine, 1961; da Campos, 1963; Naib, 1964; Haik, 1966; Aratoon, 1967) had led me to the opinion that a rapid recurrence was likely if any free conjunctiva remained in the immediate vicinity of the corneal pterygial site.

Technique

The head of the pterygium was grasped in fine-toothed forceps near the apex and put on tension by drawing it away from the cornea. This manoeuvre makes it easy to achieve a superficial keratectomy extending a little beyond the corneal lesion all round and sufficiently deep to Bowman's membrane to produce a perfectly clear cornea in the excised area. The keratectomy was continued to the limbus, where the plane of excision was brought to the surface, thus freeing the pterygium. The conjunctiva and fascia were then well undermined towards the caruncle and perilibally above and below. Scissors were then used to cut the conjunctiva as closely as possible to the limbus and the excision was completed as shown in Fig. 1. A cautery was used to destroy all visible vessels within 3 or 4 mm of the limbus, steroid-antibiotic ointment was applied, and the eye was padded for a few days.

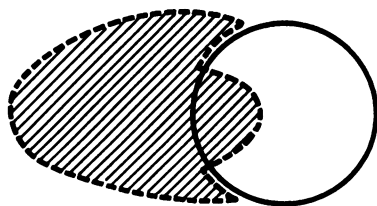


FIG. 1 Area of excision shown by shading

Plentiful support for such a “bare-sclera” technique may be found in the literature. Holland (cited by Somerset, 1940), D’Ombrain (1948), Sugar (1959), Barrons and King (1961), Walter (1961), Agler (1964), Bernstein and Unger (1960), Sang (1966), and many others have advocated various forms of this method, and most have claimed impressive success. In this trial the rationale behind the choice of method was the supposition that postoperative healing involved a “race” between re-

epithelialization of the bare corneal area by epithelial slide and re-covering of the bare scleral area by extension of the conjunctival epithelium. It was presumed that, since the entire pathological tissue had been removed, a permanent cure would be obtained if corneal cover could be achieved before the conjunctiva reached the limbus.

Results

Of the 174 patients, 74 (42 per cent.) failed to return for surveillance, leaving a convenient number for study. The remaining 100 cases were divided into four arbitrary grades, as shown in Fig. 2. This classification is useful in that it helps to express quantitatively the important fact that the incidence of recurrence rises steeply with the size of the lesion at the time of excision. The supplementary classification into normal and broad (B) sub-groups brings out the additional fact that the tendency to recurrence is a function not so much of the linear dimension of the pterygium as of its area. Thus, the percentage of recurrences in Grade 2B lesions was 39 per cent. and in Grade 4B lesions 100 per cent. The area of a pterygium is, in general, an index of activity: it is unnecessary to record details of vascularity, thickness, presence or absence of "islets of Fuchs", areas of hyaline degeneration, etc. No lesions corresponding to Grade 3B were seen. This is possibly because the majority of Grade 3 pterygia are in process of extending centrally.

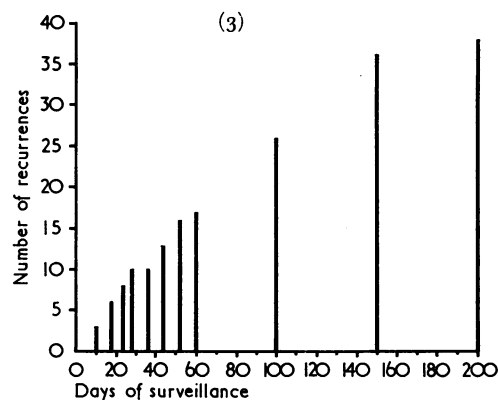
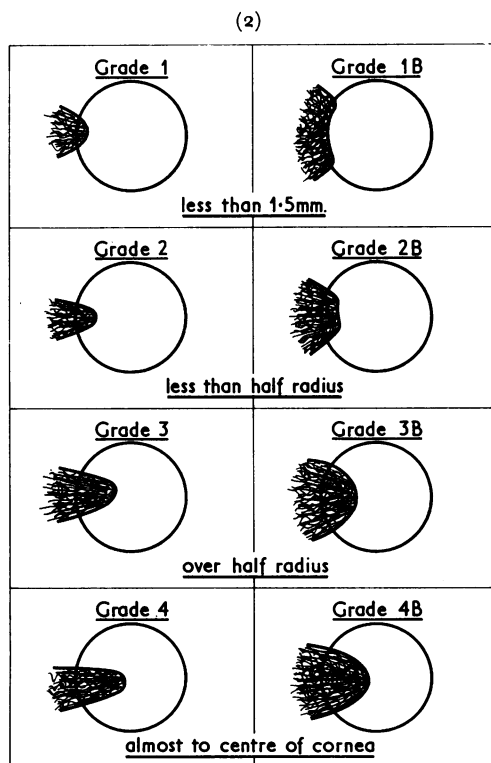


FIG. 3 Number of recurrences (37) related to days of surveillance (up to 200 days). Note that the rise in recurrences increases regularly with time up to 150 days.

FIG. 2 Classification of grades of pterygia

Table I (overleaf) gives the recurrence rates of the various grades.

The figure of 37 per cent. recurrences is almost certainly low. Fig. 3 indicates how the total number of recurrences rises with time, and Table II (overleaf) gives the periods of surveillance of cases in which the lesion had not recurred up to the time of the last examin-

Table I Recurrences in 100 operated cases, by grade

Grade	Total cases	Recurrences No.	Per cent.
1	9	1	11
2	59	17	29
3	26	15	58
4	6	4	67
Total	100	37	—

Table II Periods of surveillance of 63 "non-recurring" cases

Length of surveillance (days)	No. of cases
0 to 7	24
8 to 14	18
15 to 21	6
22 to 28	4
29 to 36	2
37 to 44	3
45 to 52	4
over 52	2
Total	63

ation. Taken together, these data indicate the strong probability that many more pterygia will recur. Table II shows that 52 patients were followed up for 28 days or less. When it is considered that ten pterygia recurred within this period the figure of 37 per cent. recurrences is seen to be unrealistic.

No significant sex bias was found in the recurrent cases, but there was some preponderance of younger patients. The median age was 44 years (range 24 to 70); 27 (73 per cent.) of the patients with recurrences were aged 50 years or less. This observation is in line with the findings of Zauberman (1967), also working in Israel, who found recurrences to be commoner in younger patients, primarily because active lesions were more common in these.

Observations

Perhaps the most interesting observations were those of the natural history of pterygial recurrence as seen on biomicroscopic examination. Initially, it seemed that the theory behind the surgical technique employed was correct: re-epithelialization of the corneal pterygial site, as demonstrated by fluorescein staining, was rapid. Indeed, in several cases, the corneal epithelium was seen to extend well across the limbus and over the bared sclera. At first it was thought that this loss of limbal integrity was advantageous, but subsequent observations led to the conclusion that here, in fact, was one of the principal elements in the pathology of the condition—the loss of ability to determine the demarcating change in epithelial type which is one of the main anatomical features of the limbus. Obviously, such loss of limbal integrity does not result simply from the excision of the epithelial basement membrane and Bowman's membrane, for such an injury in a "non-ptyerygial" eye never leads to pterygium.

In those cases in which extensive baring of the sclera allows translimbal migration of corneal epithelium, the two epithelia (corneal and conjunctival) meet over a line on the sclera remote from the limbus. Two remarkable things happen. First, the conjunctival epithelium seems to take temporary anchorage to the sclera at the point of contact with the corneal epithelium and that point becomes the apex of a rapidly developing, new extracorneal pterygium. This lesion has all the morphological features of a true pterygium. Secondly, the apex of this extracorneal pterygium begins to move towards the limbus, and within a very few weeks, reaches it, crosses over onto the cornea, and, as a rule, proceeds further across the cornea than did the original lesion.

Kamel (1954) has suggested that the morphology of pterygium arises from the mechanics of a situation in which a loose tissue (conjunctiva) contracts while adherent to an unyielding tissue (cornea). This interpretation is, however, inadequate for the observations described above.

It is entirely characteristic of these recurrences that they are of significantly greater area, bulk, and degree of vascularity than the primary pterygium. Moreover, there is ample evidence that subsequent excisions lead to even more rapid and more exuberant regrowth. The significance of these findings is considered below.

Does keratoplasty prevent recurrence?

Five patients, who had suffered repeated recurrences of pterygium, were treated after excision by peripheral 3 mm. wide, 0.4 mm. deep, lamellar grafts of preserved cornea. All the grafts were readily incorporated and all, initially, remained clear. At first it seemed that this would prove to be a satisfactory means of control, but in the three cases which were followed up, an initial gradual revascularization occurred at the graft-host interface and this was followed by a typical recurrence of pterygium *across the top of the graft*, the apex eventually reaching and invading previously apparently normal host cornea central to the graft margin. In these three cases the pterygia were found to have recurred at 138, 71, and 97 days, respectively, the first having been seen at 47 days with no apparent sign of recurrence. One patient was treated with intensive Thio-tepa with no observable response. There would thus appear to be no grounds for optimism about the fate of the other cases which were not followed up.

It is interesting to note that Pierse and Casey (1959) treated nine cases of pterygium by lamellar grafting "with no sign of recurrence in any of our nine cases". Possibly the fact that these cases were treated in England may have a bearing on this happy result.

Discussion

Almost any respectable authority can be quoted to support the view that pterygium is a disease of corneal epithelium, basement membrane, Bowman's membrane, superficial stroma, and conjunctiva. It has never, so far as I know, been suggested that the pathology extends beyond the limits of these tissues. Yet the results of this series clearly demonstrate that this view is too limited and that the pathology cannot be explained without invoking a much more extensive process.

It has been amply demonstrated, in these cases, that radical excision of all nominally diseased tissue by keratectomy and widespread removal of the entire conjunctival lesion to bare sclera, in no way inhibits the regrowth of the pterygium. To suggest, as some authors have done, that a recurrent lesion is not a true pterygium but merely the regrowth of "scar tissue" is disingenuous and inaccurate. Recurrent pterygia do not stop short at the site of the previous apex: they grow inexorably onwards, both radially and tangentially, and they do so over a scleral and corneal site which was, apparently, free of any pathological tissue. Now, it is a matter of common observation that when a superficial corneal wound, involving loss both of Bowman's membrane and of conjunctiva, is allowed to heal, the integrity of the limbus is normally preserved, and the two epithelia extend to cover their respective areas without transgression. At worst, and rarely, conjunctiva may adhere, locally, to corneal stroma so as to produce a pseudo-ptyerygium, but there the matter rests. No further extension on to the cornea, of conjunctival epithelium or of subconjunctival connective tissue, occurs and there is no increase in the vascularity of the translimbal tissues.

The exact nature of the limbal "barrier", in health, is obscure: it is probably a phenomenon of fundamental biological significance paralleling (or partaking of) the basic restraint on tissue growth which determines organismal morphology. What is clear is that in cases of pterygium we are observing a localized breakdown of this barrier so that limbal transgression occurs. Even the radical excision of apparently all pterygial tissue with the insertion of a corneal graft does not restore the barrier. It would seem to follow that the change is not, essentially, in the tissues showing manifest pathological alteration, but rather in the body's reparative processes. It is significant that recurrences of pterygium, after repeated excisions, become progressively larger, so that eventually they may extend beyond the interpalpebral area which is the natural boundary of virgin lesions.

One important fact brought out by this study is that the aetiological factors operate as a "trigger" mechanism, precipitating a chain of events which progresses independently of the continued application of the cause. This fact was recognized by Zauberman (1967), who referred to a "pterygium factor" in the cornea which, once produced, "behaves independently of its original cause". The impressive failure of protective measures to influence the progress of pterygia and the natural history of recurrent lesions clearly demonstrate this point.

The characteristic age/activity relationship and the unquestionable tendency for pterygia to become non-progressive, atrophic, and attenuated in old age, suggest that the perpetuating mechanism weakens with time. On the other hand, the marked activating effect of surgical excision indicates that this mechanism can be reinforced at almost any stage.

All these observations point to one conclusion—that the response to pterygium excision involves a humoral factor and that, in all probability, an antigen-antibody reaction is at the basis of the pathology. It is true that Levy, Levy, and Clapper (1970) were unable to demonstrate circulating antibodies to pterygial culture antigen but, on the other hand, Tan and Stoughton (1969) have demonstrated that UVL-irradiated isolated DNA injected into rabbits stimulated the production of specific antibodies which reacted with the irradiated DNA, and the existence of antibodies against DNA in systemic lupus erythematosus is well known.

One practical outcome of this study is that one is faced with the problem whether pterygium should *ever* be excised. In this context it is of interest to note that surgical treatment of pterygium has been largely abandoned at the Hadassah Medical Centre, Jerusalem (Prof. I. C. Michaelson—personal communication).

The question of β -irradiation of the pterygial site after excision, although outside the scope of this paper, is important. It is possible that this measure may reliably improve the long-term prognosis. Certainly the claims of its advocates would lead one to believe so. Since, however, β -irradiation has no place in the treatment of the unexcised lesion, the indications for its use would seem to be wholly iatrogenic and, as such, suspect.

Summary

The outcome of 100 pterygium operations, using a "bare-sclera" technique, is analysed and the postoperative clinical pathology described. The poor results obtained suggest that the procedure is unsound and provide grounds for the view that pterygium should not be treated surgically.

I am indebted to the Warden and Chief Surgeon of the St. John Ophthalmic Hospital, Jerusalem, Dr. K. L. Batten, and to the Hospitaller of the Order of St. John of Jerusalem, Mr. T. Keith Lyle, for facilities to undertake this study and for their helpful encouragement

References

- ALGER, L. J. (1964) *Amer. J. Ophthalm.*, **57**, 450
- ARATOON, V. (1967) *Ibid.*, **63**, 1778
- BARRONS and KING, J. H. (1961) "An Atlas of Ophthalmic Surgery". Lippincott, Philadelphia
- BERNSTEIN, M., and UNGER, S. M. (1960) *Amer. J. Ophthalm.*, **49**, 1024
- CABANAS, DEL RIO (1953) *Ibid.*, **36**, 267
- CAMPOS, E. (1963) *Rev. bras. Oftal.*, **22**, 149
- ESCAPINI, H. (1958) *Amer. J. Ophthalm.*, **45**, 879
- FRY, W. E. (1959) *Ibid.*, **47**, 248
- HAIK, G. M. (1966) *Ibid.*, **61**, 1128
- HOLLAND, H. cited by Somerset (1940)
- KAMEL, S. (1954) *Amer. J. Ophthalm.*, **38**, 682
- LEVY, W. J., LEVY, J., and CLAPPER, W. E. (1970) *Arch. Ophthalm. (Chicago)*, **83**, 402
- MAJOROS, J. (1950) *Amer. J. Ophthalm.*, **33**, 1289
- NAIB, K. (1964) *Ibid.*, **58**, 861
- NEWTON, F. H. (1957) *Ibid.*, **44**, 258
- D'OMBRAIN, A. (1948) *Brit. J. Ophthalm.*, **32**, 65
- PIERSE, D., and CASEY, T. A. (1959) *Ibid.*, **43**, 733
- RANKINE, T. B. (1961) *Ibid.*, **45**, 816
- ROSENTHAL, J. W. (1953) *Amer. J. Ophthalm.*, **36**, 259
- SANG, Y. K. (1966) *Rinsho Ganka (Jap. J. clin. Ophthalm.)*, **20**, 1231
- SATO, T. (1954) *Amer. J. Ophthalm.*, **37**, 903
- SOMERSET, E. J. (1940) *Brit. J. Ophthalm.*, **46**, 315
- SUGAR, H. S. (1949) *Amer. J. Ophthalm.*, **32**, 912
- TAN, E. M., and STOUGHTON, R. B. (1969) *Proc. nat. Acad. Sci. (Wash.)*, **62**, 708
- WALTER, W. L. (1961) *Amer. J. Ophthalm.*, **51**, 441
- ZAUBERMAN, H. (1967) *Ibid.*, **63**, 1780



Recurrence of pterygium after excision.

R M Youngson

Br J Ophthalmol 1972 56: 120-125
doi: 10.1136/bjo.56.2.120

Updated information and services can be found at:
<http://bjo.bmj.com/content/56/2/120.citation>

Email alerting service

These include:

Receive free email alerts when new articles cite this article. Sign up in the box at the top right corner of the online article.

Notes

To request permissions go to:
<http://group.bmj.com/group/rights-licensing/permissions>

To order reprints go to:
<http://journals.bmj.com/cgi/reprintform>

To subscribe to BMJ go to:
<http://group.bmj.com/subscribe/>