



# Fibrin glue versus sutures for attaching the conjunctival autograft in pterygium surgery: a prospective observer masked clinical trial

S Srinivasan, M Dollin, P McAllum, Y Berger, D S Rootman, A R Slomovic

Department of Ophthalmology,  
Toronto Western Hospital,  
Department of Ophthalmology  
and Vision Sciences, University  
of Toronto, Toronto, Canada

Correspondence to:  
Mr S Srinivasan, Department of  
Ophthalmology, Ayr Hospital,  
Dalmellington Road,  
Ayr KA6 6DX, UK;  
sathish.srinivasan@gmail.com

Presented in part at the  
American Academy of  
Ophthalmology Annual Meeting,  
Las Vegas, November, 2006.

Accepted 26 October 2008  
Published Online First  
19 November 2008

## ABSTRACT

**Aims:** To compare the degree of conjunctival autograft inflammation, subconjunctival haemorrhage (SCH) and graft stability following the use of sutures or fibrin glue (FG) during pterygium surgery.

**Methods:** Prospective, observer masked, clinical trial. 40 eyes of 40 patients undergoing primary pterygium surgery with conjunctival autograft were allocated into two groups. Group 1 (n = 20) had FG (Tisseel) for attaching the conjunctival autograft, whereas group 2 (n = 20) had sutures. Standardised digital slit-lamp photographs were taken at 1 week, 1 month and 3 months postoperatively. Sutures were masked using commercially available photo-editing software. Two masked observers objectively graded the digital photographs for degree of inflammation, SCH and graft stability.

**Results:** 34 of the 40 patients completed the study. When using FG, the degree of inflammation was significantly less than with sutures at 1 month (p = 0.019) and 3 months (p = 0.001) postoperatively. No significant difference was found for inflammation at 1 week postoperatively (p = 0.518). Conjunctival grafts secured with FG were as stable as those secured with sutures (p = 0.258, p = 0.076 and p = 0.624, at 1 week, 1 month and 3 months, respectively). No significant difference was found in degree of postoperative SCH between the groups (p = 0.417, p = 1 and p = 1, at 1 week, 1 month and 3 months, respectively).

**Conclusion:** This is the first prospective clinical trial confirming that conjunctival grafts secured with FG during pterygium surgery not only are as stable as those secured with sutures, but also produce significantly less inflammation.

The prevalence rate of primary pterygium varies from 0.7 to 31% in various populations around the world.<sup>1,2</sup> Recent immunohistochemical studies support the theory that p53-mutated limbal epithelial basal stem cells lead to the development of pterygium.<sup>3</sup> Several surgical techniques have been described for its management.<sup>4</sup> Kenyon *et al* introduced the surgical technique of using conjunctival autograft in the management of primary advanced and recurrent pterygium.<sup>5</sup> Although more time-consuming, this technique was found to be safe and effective in reducing the number of recurrences while avoiding the risk of potentially serious complications.<sup>6,7</sup> A meta-analysis on the surgical techniques for pterygium excision showed that the odds for pterygium recurrence following surgical treatment of primary pterygium are close to six and 25 times higher if no conjunctival autograft placement is performed.<sup>8</sup>

Traditionally, during pterygium surgery the conjunctival autografts are secured in place with either absorbable or non-absorbable sutures. Tisseel (Tisseel, Baxter Corporation, Mississauga, Canada) is a two-component tissue adhesive which mimics the natural fibrin formation. It has been used in neurosurgery, plastic surgery, ear, nose and throat surgery, and ocular surgery.<sup>9</sup> The use of fibrin glue (FG) during pterygium surgery was first described by Cohen *et al* in 1993.<sup>10</sup> Since then there have been several reports on the safety and efficacy of FG during pterygium surgery.<sup>11–13</sup>

A recent retrospective study on a large cohort suggested that pterygium surgery with FG leads to significantly lower recurrence rate when compared with the use of sutures.<sup>14</sup>

Although it is conceptualised that pterygium surgery with FG produces less postoperative inflammation when compared with sutures,<sup>14</sup> to the best of our knowledge, based on a Medline search, there has been no prospective clinical study demonstrating this. We performed a prospective, observer masked clinical trial to compare the degree of conjunctival graft inflammation, subconjunctival haemorrhage (SCH) and graft stability following the use of sutures or FG for attaching the conjunctival autograft during pterygium surgery.

## MATERIALS AND METHODS

### Study population

Between October 2005 and January 2006, from a continuous cohort of 55 patients with primary pterygium referred to the Corneal Service at the Toronto Western Hospital, Toronto, 40 subjects were recruited to undergo primary pterygium excision with conjunctival autograft using FG or 10-0 polyglactin (vicryl) sutures. Institutional review board approval was obtained through the Toronto Academic Health Sciences Network/University Health Network Research Ethics Board, Toronto, Canada. The surgical procedures complied with the tenets of the Declaration of Helsinki. Inclusion criteria were a primary nasal pterygium, for which surgery was recommended, and willingness to participate in the clinical study. Exclusion criteria were subjects on anticoagulants, and recurrent or temporal location of pterygium. All patients gave written informed consent to participate in the study.

### Surgical procedure

The surgical procedures were performed by two surgeons (SS and PM). The surgical procedures for subjects in group 1 (FG group, n = 20) were

**Table 1** Scoring parameters for each of the three outcome variables

Outcome variables	Scoring parameters
Subconjunctival haemorrhage	Grade 0: None
	Grade 1: $\leq 25\%$ of the size of the graft
	Grade 2: $\leq 50\%$ of the size of the graft
	Grade 3: $\leq 75\%$ of the size of the graft
	Grade 4: Haemorrhage involving the entire graft (no subconjunctival vessels visible)
Inflammation	Grade 0: No dilated corkscrew vessel in the graft
	Grade 1: 1 bright red, dilated corkscrew vessel crossing the graft-bed margin
	Grade 2: 2 bright red, dilated corkscrew vessels crossing the graft-bed margin
	Grade 3: three bright red, dilated corkscrew vessels crossing the graft-bed margin
	Grade 4: $\geq 3$ bright red, dilated corkscrew vessels crossing the graft-bed margin
Graft stability	Grade 0: All four sides of the graft margin are well apposed
	Grade 1: Gaping/displacement of one side of the graft-bed junction
	Grade 2: Gaping/displacement of two sides of the graft-bed junction
	Grade 3: Gaping/displacement of three sides of the graft-bed junction
	Grade 4: Graft completely displaced from the bed

performed by SS, while PM performed the procedures for subjects in group 2 (suture group,  $n = 20$ ). The surgical steps and procedures were standardised between the surgeons, with the only difference being the use of sutures or FG for attaching the conjunctival autograft. The procedure was carried out under a combination of topical (Proparacaine 0.5%, Alcaïne, Alcon Canada, Mississauga, Canada) and subconjunctival (Xylocaine 2% with 1:100 000 epinephrine, AstraZeneca Canada, Mississauga, Canada) anaesthetic. All procedures were performed using an operating microscope. Under aseptic conditions, following the insertion of a Liebermann lid speculum, the body of the pterygium was marked using a sterile skin marker, and 0.1 ml of Xylocaine 2% with epinephrine was injected into the pterygium body. A 64 Beaver blade was used to excise the pterygium head from the cornea, and the body of the pterygium along with the underlying tenons was excised using Westcott scissors. A motorised diamond burr was used to smooth the corneal bed. Haemostasis of the scleral bed was achieved with a wet field cautery.

The area of the conjunctival defect was measured with a caliper, and a free conjunctival-limbal autograft measuring the same size as the conjunctival defect was obtained from the superotemporal quadrant of the bulbar conjunctiva. Westcott scissors and Fechtner conjunctival forceps were used to harvest the free conjunctival-limbal autograft. Meticulous dissection was performed to remove most of the tenons tissue in the autograft. The graft was moved over to the area of the conjunctival defect, with care taken to maintain the limbus to limbus and stromal side down orientation. At this stage, depending on the group in which the patients were allocated to, the autograft was secured either with multiple interrupted 10-0 polyglactin sutures or with FG (Tisseel). For subjects in group 1 (FG group,  $n = 20$ ), the graft was placed on the cornea with the stromal side facing upwards. Three drops of the sealant protein and the sealant setting solution mounted on two

separate syringes on a Duploject injection system were then placed on the scleral bed, and the conjunctival graft was immediately flipped over the area of conjunctival defect. The graft was quickly smoothed out with a non-toothed forceps while the thrombin was breaking down the fibrinopeptides to form fibrin clots. For subjects in group 2 (suture group,  $n = 20$ ), multiple interrupted 10-0 polyglactin sutures were used to attach the autograft to the underlying episcleral bed. At the end of the procedure an antibiotic-steroid combination eye-drop, tobramycin-dexamethasone (TobraDex, Alcon Canada, Mississauga, Canada), was placed on all eyes, and all the eyes were patched.

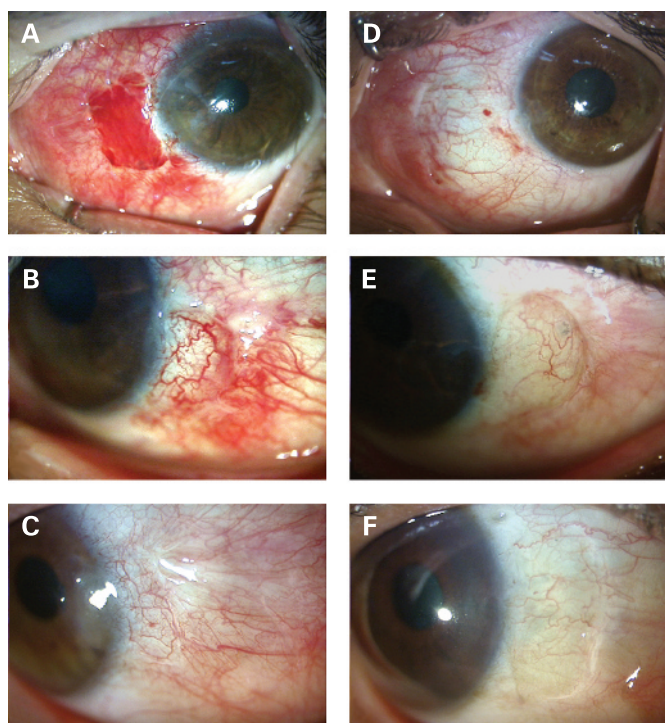
### Patient evaluation and follow-up

Postoperatively, subjects in both groups were treated with tobramycin-dexamethasone four times a day, which was gradually tapered over a period of 2 months. All subjects were seen at 1 day, 1 week, 1 month and 3 months postoperatively. During each postoperative visit, slit-lamp biomicroscopy and applanation tonometry were performed by any of three investigators (SS, PM, YB). Digital slit-lamp photography was performed during each postoperative visit (except on day 1) by the same three investigators (SS, PM, YB) using a Topcon slit lamp with Hitachi HV-C20MU camera (Topcon Corporation, Tokyo). A protocol was followed for obtaining digital slit-lamp photographs, which included the following: topical anaesthesia, lid speculum, and standardised light and magnification settings. The digital pictures obtained from the subjects in group 2 (suture group,  $n = 20$ ) were imported into commercially available photo-editing software (Adobe Photoshop 7.0, Adobe Systems, San Jose, California). Using this software the visible sutures were masked in all the digital pictures by an independent clinician (MD). The digital pictures from both of the groups were then converted into a Tagged Image File Format (TIFF) file and randomly inserted as individual slides

**Table 2** Mann-Whitney U test results for each outcome variable at 1 week, 1 month and 3 months postoperatively

Outcome variables	1 week postop			1 month postop			3 months postop		
	Tisseel mean rank	Suture mean rank	p Value	Tisseel mean rank	Suture mean rank	p Value	Tisseel mean rank	Suture mean rank	p Value
Subconjunctival haemorrhage	18.82	16.18	0.417	17.50	17.50	1.000	17.50	17.50	1.000
Inflammation	16.44	18.56	0.518	13.56	21.44	<b>0.019</b>	11.85	23.15	<b>0.001</b>
Graft stability	19.18	15.82	0.258	19.50	15.50	0.076	16.91	18.09	0.624

Significant p values are highlighted in bold.



**Figure 1** (A–C) Standardised slit-lamp photographs taken at 1 week, 1 month, and 3 months, respectively, following pterygium surgery with conjunctival autograft using sutures. Note that the sutures have been masked in these pictures using a software program. (D–F) Standardised slit-lamp photographs taken at 1 week, 1 month, and 3 months, respectively, following pterygium surgery with conjunctival autograft using fibrin glue.

into a PowerPoint program (Microsoft Office 2003, Microsoft Corporation, Redmond, Washington). Two independent observers (DSR and ARS), who were completely masked to the editing and slide insertion protocol, reviewed the digital PowerPoint slides and graded each picture on the degree of graft inflammation, SCH and stability. The outcome variables and the scoring scale are summarised in table 1.

### Statistical analysis

Statistical analysis was performed using SPSS 13.0 (SPSS, Chicago). Outcome variables between the two groups were compared using the non-parametric Mann–Whitney U Test. The conventional level of significance  $p < 0.05$  was applied in all cases.

### RESULTS

The cohort consisted of 17 (42%) males. The mean age was 47 years (range 32 to 72). Thirty-four of the 40 patients completed the 3 months' follow-up. The results are summarised in table 2.

The degree of inflammation was significantly less in the FG group at both 1 month ( $p = 0.019$ ) and 3 months ( $p = 0.001$ ) postoperatively (fig 1). There was no significant difference in the degree of inflammation between the groups at 1 week postoperatively ( $p = 0.518$ ). Conjunctival graft stability with FG was the same as with sutures over the 3 months' course of follow-up ( $p = 0.258$ ,  $p = 0.076$  and  $p = 0.624$ , at 1 week, 1 month and 3 months, respectively). There was no significant difference in the degree of SCH between the groups at any point

during the follow-up period ( $p = 0.417$ ,  $p = 1$  and  $p = 1$ , at 1 week, 1 month and 3 months, respectively).

### DISCUSSION

Pterygium recurrence is the most common complication of pterygium surgery and is a frequent source of frustration for patients and surgeons. With the aim of reducing recurrence rates, several surgical techniques have been described in the literature. These include bare sclera excision,<sup>15</sup> conjunctival and conjunctival–limbal autograft,<sup>5, 16</sup> and the use of amniotic membrane.<sup>17</sup> In addition, several adjunctive therapies, including the use of beta irradiation<sup>18</sup> and mitomycin C (MMC),<sup>19</sup> have been recommended due to their anti-fibrotic and anti-angiogenic properties.

From 1960 to the early 1980s, bare sclera closure was the most popular method for surgical removal of a primary pterygium.<sup>4</sup> However, it has been shown that it is by far the least satisfactory method with respect to recurrence rates, which can be as high as 80%.<sup>4</sup> The use of conjunctival autograft gained popularity in the 1980s following the landmark article by Kenyon *et al* in 1985.<sup>5</sup> He reported a low recurrence rate of 5.3% using the conjunctival autograft technique. Since his publication, other prospective, randomised studies of conjunctival autografting during pterygium surgery have reported higher recurrence rates (16–39%) in high-risk populations.<sup>19, 20</sup> Nonetheless, a recent detailed review on the treatment of pterygium concluded that conjunctival autograft remains the safest technique and offers the lowest rate of recurrence in the management of primary pterygium.<sup>4</sup>

There is evidence that UV light-induced limbal stem-cell damage can act as precursor to the development of pinguecula and pterygium.<sup>21</sup> Thus, conceptually, one could possibly reduce pterygium recurrence rates by including the limbus in the harvested conjunctival autograft. Conjunctival–limbal autograft has been shown to be effective in the management of both primary and recurrent pterygia.<sup>22</sup> There is very little scientific data on the preoperative morphological appearance, epidemiological status or surgical factors that influence pterygium recurrence rate. Tan *et al* in a prospective study were able to demonstrate that fleshiness of the pterygium is a significant risk factor for recurrence if bare sclera excision is performed.<sup>23</sup>

Tisseel is a commercially available two-component fibrin sealant which mimics the natural fibrin and acts as tissue glue with sealing, haemostatic and gluing properties. The glue has two components: (1) sealant protein, a freeze-dried powder composed of human fibrinogen, fibrinonectin, plasminogen and Factor XIII reconstituted in a bovine aprotinin solution; (2) sealant setting, a solution composed of human thrombin reconstituted in a calcium chloride solution. When both of these solutions interact, through the action of thrombin, the fibrinopeptides are broken down to fibrin monomers. These monomers aggregate by cross-linking, leading to the formation of fibrin clot. Use of FG during pterygium surgery not only is safe and effective<sup>11–14</sup> but also produces less postoperative pain when compared with the use of sutures.<sup>11</sup>

Ti and Tseng demonstrated that increased inflammation during the postoperative period increases the risk of pterygium recurrence.<sup>24</sup> Zuzuki *et al* showed that the use of silk and nylon sutures placed in the conjunctiva can cause inflammation, and migration of Langerhans' cells to the cornea.<sup>25</sup> In a large retrospective study, Koranyi *et al* were able to demonstrate a statistically significant decreased recurrence rate with the use of FG when compared with the use of sutures.<sup>14</sup> They postulated that a possible reduction in the migration of fibroblast cells



caused by the rapid adhesion of the graft with the FG may lead to decreased postoperative inflammation.

In our prospective, photo-documented, observer-masked clinical trial, we were able to demonstrate decreased postoperative inflammation (at both a 1-month and 3-month time gate) with the use of FG compared with polyglactin sutures. Although the aetiopathogenesis of pterygium recurrence may be multifactorial, we believe that reducing postoperative inflammation may play a significant role in reducing the recurrence rate.<sup>24</sup> Larger, prospective studies are required to evaluate the long-term efficacy on the use of FG in reducing the recurrence rate.

**Competing interests:** None.

**Ethics approval:** Ethics approval was provided by the Toronto Academic Health Sciences Network/University Health Network Research Ethics Board, Toronto, Canada.

**Patient consent:** Obtained.

## REFERENCES

1. **Detels R**, Dhir SP. Pterygium: a geographical survey. *Arch Ophthalmol* 1967;**78**:485.
2. **Sivasubramaniam P**. Pterygium in Ceylon. *Br J Ophthalmol* 1971;**55**:55.
3. **Chowers I**, Pe'er J, Zamir E, *et al*. Proliferate activity and p53 expression in primary and recurrent pterygium. *Ophthalmology* 2001;**108**:985–8.
4. **Hirst LW**. The treatment of pterygium. *Surv Ophthalmol* 2003;**48**:145–80.
5. **Kenyon KR**, Wagoner MD, Hettinger ME. Conjunctival autograft transplantation for advanced and recurrent pterygium. *Ophthalmology* 1985;**92**:1461–70.
6. **Starck T**, Kenyon KR, Serrano F. Conjunctival autograft for primary and recurrent pterygia: surgical technique and problem management. *Cornea* 1991;**10**:196–202.
7. **Allan BDS**, Short P, Crawford GJ, *et al*. Pterygium excision with conjunctival autografting: an effective and safe technique. *Br J Ophthalmol* 1993;**77**:698–701.
8. **Sanchez-Thorin JC**, Rocha G, Yelin JB. Meta-analysis on the recurrence rates after bare sclera resection with and without mitomycin C use and conjunctival autograft placement in surgery for primary pterygium. *Br J Ophthalmol* 1998;**82**:661–5.
9. **Schlag G**, Aschler PW, Steinkogler FJ, *et al*. *Fibrin sealing in surgical and nonsurgical fields*, Vol. 5. *Neurosurgery, ophthalmic surgery, ENT*. Berlin: Springer Verlag, 1994.
10. **Cohen RA**, McDonald MB. Fixation of conjunctival autografts with an organic tissue adhesive [letter]. *Arch Ophthalmol* 1993;**111**:1167–8.
11. **Koranyi G**, Seregard S, Kopp ED. Cut and paste: a no suture, small incision approach to pterygium surgery. *Br J Ophthalmol* 2004;**88**:911–14.
12. **Uy HS**, Reyes JM, Flores JD, *et al*. Comparison of fibrin glue and sutures for attaching conjunctival autografts after pterygium excision. *Ophthalmology* 2005;**112**:667–71.
13. **Marticorena J**, Rodriguez-Ares MT, Tourino R, *et al*. Pterygium surgery: Conjunctival autograft using a fibrin adhesive. *Cornea* 2006;**25**:34–6.
14. **Koranyi G**, Seregard S, Kopp ED. The cut-and-paste method for primary pterygium surgery: long-term follow up. *Acta Ophthalmol Scand* 2005;**83**:298–301.
15. **Adamis AP**, Starck T, Kenyon KR. The management of pterygium. *Ophthalmol Clin North Am* 1990;**3**:611–23.
16. **Kenyon KR**, Tseng SC. Limbal autograft transplantation for ocular surface disorders. *Ophthalmology* 1989;**96**:709–23.
17. **Prabhasawat P**, Barton K, Burkett G, *et al*. Comparison of conjunctival autografts, amniotic membrane grafts and primary closure for pterygium excision. *Ophthalmology* 1997;**104**:974–85.
18. **Mackenzie FD**, Hirst LW. Recurrence rate and complications after beta irradiation for pterygia. *Ophthalmology* 1991;**98**:1776–81.
19. **Manning CA**, Loess PM, Diaz MD, *et al*. Intraoperative mitomycin in primary pterygium excision. *Ophthalmology* 1997;**104**:844–8.
20. **Mahar PS**. Conjunctival autograft versus topical mitomycin C in the treatment of pterygium. *Eye* 1997;**11**:790–2.
21. **Dushku N**, John MK, Schultz GS, *et al*. Pterygia pathogenesis: corneal invasion by matrix metalloproteinase expressing altered limbal epithelial basal cells. *Arch Ophthalmol* 2001;**119**:695–706.
22. **Al Favez MF**. Limbal versus conjunctival autograft transplantation for advanced and recurrent pterygium. *Ophthalmology* 2002;**109**:1752–5.
23. **Tan DT**, Chee SP, Dear KB, *et al*. Effect of pterygium morphology on pterygium recurrence in a controlled trial comparing conjunctival autografting with bare sclera excision. *Arch Ophthalmol* 1997;**115**:1235–40.
24. **Ti SE**, Tseng SC. Management of primary and recurrent pterygium using amniotic membrane transplantation. *Curr Opin Ophthalmol* 2002;**13**:204–12.
25. **Suzuki T**, Sano Y, Kinoshita S. Conjunctival inflammation induces Langerhans' cell migration into the cornea. *Curr Eye Res* 2000;**21**:550–3.