




OPEN ACCESS

Clinical science

Biotissue stent for supraciliary outflow in open-angle glaucoma patients: surgical procedure and first clinical results of an aqueous drainage biostent

Tsoncho Ianchulev ^{1,2} Robert N Weinreb,² Gautam Kamthan,³ Ernesto Calvo,⁴ Ravinder Pamnani,⁵ Iqbal K Ahmed⁶¹Ophthalmology, New York Eye and Ear Infirmary of Mount Sinai, New York City, New York, USA²UCSD, La Jolla, California, USA³New York Eye and Ear Infirmary of Mount Sinai, New York City, New York, USA⁴Clínica de Ojos Orillac-Calvo, Panama City, Panama⁵Stanford University, Stanford, California, USA⁶Ophthalmology and Vision Sciences, University of Toronto, Mississauga, Ontario, Canada**Correspondence to**

Dr Tsoncho Ianchulev, Ophthalmology, New York Eye and Ear Infirmary of Mount Sinai, New York City, NY 10003, USA; tianchul@yahoo.com

Received 16 September 2022

Accepted 16 December 2022

Published Online First

2 January 2023

ABSTRACT**Background/aims** To report a first-in-human trial in open-angle glaucoma (OAG) subjects treated with a new microinterventional biostent-reinforced cyclodialysis technique to enhance supraciliary aqueous drainage.**Methods** Subjects (N=10; 74.1±7.9 years old) with OAG and cataracts underwent combined phacoemulsification cataract surgery with implantation of a permanent endoscleral supraciliary biostent to reinforce a controlled cyclodialysis cleft. The biostent comprised decellularised scleral allograft tissue microtrephined into a polymer tubular implant intraoperative/postoperative safety, intraocular pressure (IOP) and glaucoma medications were tracked through 12 months postimplantation.**Results** Baseline medicated IOP averaged 24.2±6.9 mm Hg with subjects using 1.3±0.8 IOP-lowering medications. Successful biostent implantation was achieved in all individuals without significant complications. Immediate IOP lowering was sustained through 1 year. Twelve-month mean IOP was reduced 40% from baseline to 14.6±3.2 mm Hg (p=0.004; paired two-tailed t-test), and 80% of patients achieved >20% IOP reduction. Biostenting reduced glaucoma medication use 62%, from a baseline mean of 1.3 required medications to 0.5 medications (p=0.037) at postoperative 12 months. The biotissue implant was well tolerated and demonstrated good endothelial safety with only 11% endothelial cell loss at 12 months after combined phaco-biostenting surgery, similar to that expected after phacoemulsification alone. Mean BCVA increased from baseline 20/130 Snellen to 20/36 at postoperative 12 months (p=0.001).**Conclusion** Supraciliary biostenting in OAG patients is well tolerated, has a good safety profile and produces long-term IOP-lowering while reducing glaucoma medication requirements.**INTRODUCTION**Glaucoma is a leading cause of irreversible blindness. The mainstay of treatment is intraocular pressure (IOP) lowering through increasing drainage (trabecular or uveoscleral outflow) or reducing inflow.¹ Medical therapies consist of sustained use of eye-drops and are limited by low adherence, polypharmacy, systemic side effects and untoward adverse effects on the ocular surface.^{2–5} Laser trabeculoplasty is also used either as primary treatment or after a trial of medical therapy. For patients in whom such treatments are inadequate or for those who cannot tolerate or afford topical**WHAT IS ALREADY KNOWN ON THIS TOPIC**

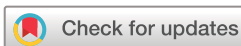⇒ Open-angle glaucoma is often recalcitrant to medication therapy alone and requires surgical intervention to lower intraocular pressure (IOP). Minimally invasive glaucoma surgical approaches such as biostenting promise safe and effective long-term IOP reduction by facilitating outflow of aqueous humour.

WHAT THIS STUDY ADDS

⇒ Minimally invasive supraciliary scleral allograft biostent insertion during phacoemulsification cataract surgery safely lowered IOP by >20% through 1 year in 8/10 patients with open-angle glaucoma and reduced the average number of glaucoma medications needed by 62%.

HOW THIS STUDY MIGHT AFFECT RESEARCH, PRACTICE OR POLICY

⇒ Biostenting with an allograft implant may be a safe and effective approach for reducing IOP for long-term treatment of open-angle glaucoma.

medications in the form of eye-drops, conventional glaucoma surgery such as trabeculectomy and glaucoma drainage shunts have been used. However, such approaches are invasive, characterised by a variable healing response, and are often associated with significant ocular complications.^{6–11}Novel approaches such as minimally invasive glaucoma surgery (MIGS) have provided safer and less invasive options that have become the most prevalent surgical treatment for glaucoma.^{12–16} The trabecular MIGS devices, such as the iStent (Glaukos, San Clemente, California, USA) and the Hydrus (Alcon, Fribourg, Switzerland), are metallic devices implanted in the Schlemm's canal; they are composed of titanium and nickel-titanium, respectively, and are designed for trabecular outflow enhancement. In combination with phacoemulsification, trabecular MIGS implants demonstrate incremental and sustained IOP-lowering efficacy and have comparable safety to phacoemulsification alone (table 1 and figure 1). This has led to their increased adoption in the glaucoma treatment paradigm, particularly in mild-to-moderate disease. The U.S. Food and Drug Administration (FDA)-approved

© Author(s) (or their employer(s)) 2024. Re-use permitted under CC BY-NC. No commercial re-use. See rights and permissions. Published by BMJ.

To cite: Ianchulev T, Weinreb RN, Kamthan G, et al. *Br J Ophthalmol* 2024;**108**:217–222.

Table 1 First and second generation minimally invasive ab-interno suprachoroidal stents

MIGS cyclodialysis device evolution	First generation	First generation	Second generation	Second generation
Name	CyPass	iStent Supra	MINIject	BioStent
Material	Synthetic Polyimide plastic	Synthetic Polyethersulfone and titanium	Synthetic Porous silicon	Biotissue Porous scleral allograft
Stented approach	Cyclodialysis tube Maintainer stent	Cyclodialysis tube Maintainer stent	Porous cyclodialysis Maintainer stent	Porous cyclodialysis Maintainer biostent
Implantation depth control (IDC)*	None	None	None	Goniometric
Implantation Technique	Intraoperative gonioscopy	Intraoperative gonioscopy	Intraoperative gonioscopy	Intraoperative gonioscopy or gonio-free IDC†
Material permeability	Non-permeable Non-hydrophilic	Non-permeable Non-hydrophilic	Porous, hydrophilic, permeable	Porous, hydrophilic and permeable ²⁵
Structural rigidity	Rigid Non-conforming	Rigid Non-conforming	Semirigid Semiconforming	Flexible Conforming
Homologous stenting with endoscopic cleft reinforcement	No	No	No	Yes

Stent images are provided in figure 1.
 *IDC for goniometric deployment.
 †Grierson *et al*³⁰.

indication for these implantable MIGS implants is for use only in conjunction with cataract surgery.^{14 17–19}

Apart from trabecular outflow, the suprachoroidal space offers a compelling approach for outflow enhancement via uveoscleral outflow. Experience from the pharmacological treatment of glaucoma with prostaglandin analogues demonstrates their best-in-class IOP-lowering effect of drugs targeting uveoscleral outflow. MIGS stents targeting uveoscleral outflow such as the CyPass Micro-Stent (Alcon, Fribourg, Switzerland) have validated this therapeutic approach further in the surgical MIGS treatment paradigm. A permanently stented cyclodialysis provides an internal drainage conduit for the aqueous into the suprachoroidal space with subsequent lowering of the IOP. Experience from the COMPASS pivotal trial validated the robust, sustained IOP-lowering effect of the CyPass device up to 2 years in a randomised controlled trial of 505 subjects.²⁰ Another first-generation suprachoroidal implant, the iStent Supra (Glaukos, San Clemente, California, USA) has been shown to provide sustained IOP reduction in patients with refractory glaucoma, when combined with trabecular stenting and postoperative.²¹ Similarly, recent 2-year data of the MINIject (iSTAR Medical, Wavre, Belgium) non-cannulated suprachoroidal implant also demonstrated robust IOP lowering.²² The suprachoroidal approach can be highly complementary to trabecular approaches and advantageous for dual outflow augmentation, further increasing the efficacy of existing MIGS interventions.

One challenge with the ab interno suprachoroidal MIGS procedures is the potential for corneal endothelial cell loss seen in the initial clinical experience of the first generation suprachoroidal implants.^{23 24} This is related to the positional effect of the implantable hardware in the iridocorneal angle being observed primarily in eyes where the device was positioned too anteriorly within the cyclodialysis cleft. The anteriorised position resulted

in residual protrusion into the anterior chamber, which was at risk for contact with the proximal corneal endothelial surface. Additionally, the material composition of the first-generation devices consisted of a non-conforming, rigid synthetic polymer shaft that increased the risk of endothelial contact and damage to the adjacent endothelial tissue. Nevertheless, the stented suprachoroidal approach remains one of the more desirable interventional MIGS targets for IOP reduction because of streamlined surgical approach, ease of implantation and robust IOP-lowering efficacy.

Here, we report a novel technique for suprachoroidal outflow enhancement using a reinforced cyclodialysis with a highly permeable, homologous biotissue scleral allograft. As shown in table 1, there can be significant advantages to this hardware-free biostent for MIGS intervention. Most importantly, it minimises the localised untoward impact of the implantable synthetic foreign body/hardware in the eye. In addition to its highly biocompatible structural properties, the scleral allograft biotissue is highly hydrophilic and porous, even compared with the very permeable corneal stroma.²⁵ This may provide the necessary aqueous conductivity as a spacer in the supraciliary cleft. This is first-in-human clinical experience of a biostent aqueous drainage implant procedure for glaucoma treatment.

METHODS

Ethical oversight

We report the clinical experience, surgical outcomes and postoperative results of a consecutive case series of patients with open-angle glaucoma (OAG) who underwent supraciliary stenting with a biotissue implant, in conjunction with phacoemulsification cataract surgery, performed by three surgeons at a single site. This study met the criteria under 42 CFR 11.22(b) and was not required to be listed on ClinicalTrials.gov. Patients



Figure 1 Evolution of stent design towards the biostent for enhancing transcleral aqueous outflow. Individual stent construction details are provided in table 1.

Br J Ophthalmol: first published as 10.1136/bjo-2022-322536 on 2 January 2023. Downloaded from http://bjo.bmj.com/ on April 18, 2024 by guest. Protected by copyright.

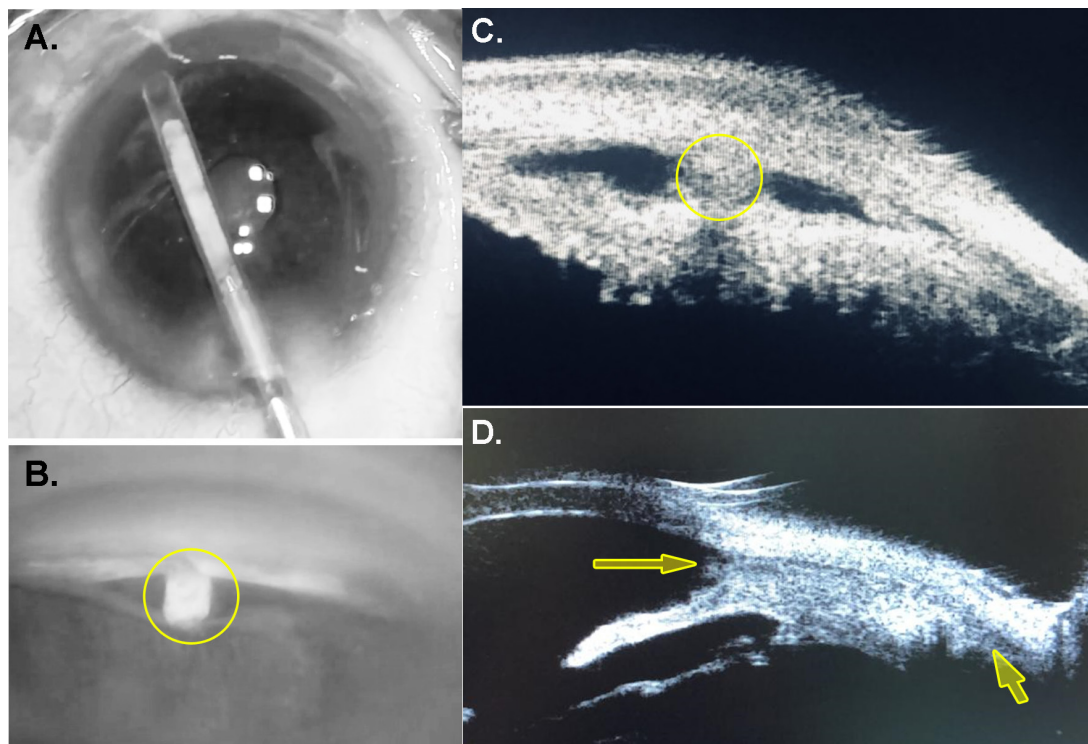


Figure 2 Imaging of biostent device and placement. The biostent is shown within the transparent cyclodialysis cannula prior to implantation (A). After implantation, gonioscopy shows the biostent implant in proper position within the cyclodialysis cleft (B; yellow circle). Ultrasound biomicroscopy images of the biostent postimplantation demonstrating endoscleral reinforcement of the cyclodialysis cleft (cross-sectional, C; and longitudinal, D)). Homologous hydrophilic biotissue implant material (yellow circle and arrows) is iso-dense on imaging and nearly indistinguishable from native scleral tissue.

underwent a standard preoperative workup and consented to receive combined cataract and MIGS glaucoma surgery.

Biostent aqueous drainage implant for cyclodialysis reinforcement and supraciliary stenting

The biostent is a scleral allograft implant made from a homologous acellular matrix using high-precision microtrephination and stent-shaping tools. The human scleral tissue graft is highly permeable and biocompatible and can serve as an excellent substrate for aqueous conductivity and outflow. Scleral allograft tissue is readily available from ocular tissue banks, has been used extensively over the last three decades for ophthalmic implantation as an adjunct to the conventional aqueous drainage devices, and has demonstrated durable safety.^{26 27}

The allograft implant was prepared from a standard sterile scleral allograft/acellular matrix from the eye tissue bank (CorneaGen, Seattle, Washington, USA) which was microtrephined into a minimally modified, shaped biostent implant using a high-precision microtrephine tool (AlloFine, Iantrek, White Plains, New York, USA). The resultant shaped biostent is an elongated cylindrical biotissue implant of approximately 500 μm diameter and 6 mm length that can be used for structural reinforcement, stenting and cleft maintenance of the cyclodialysis in the eye. The biostent was delivered using a cyclodialysis microcannula for ab interno supraciliary intervention (CycloPen, Iantrek). Gonioscopy and ultrasound images of the device placement are provided in figure 2.

Because the tissue is compressed when inserted into the cyclodialysis cannula, the biotissue implant undergoes 10% expansion on deployment from the distal tip of the cyclodialysis cannula.

This expansion may increase the retention of the shaped allograft biostent in the iatrogenic microcyclodialysis.

Study procedures

Patients eligible for the case series had confirmed OAG with angles 3+ in all four quadrants, operable cataract and no exclusionary comorbidities such as prior incisional glaucoma surgery, visual field loss within central 10° or clinically significant corneal opacity. Subjects underwent phacoemulsification cataract surgery, performed by surgeons with extensive experience with MIGS procedures and intraoperative gonioscopy. After the cataract procedure, the eye was positioned for standard MIGS gonio-intervention with the necessary head and microscope tilt for optimal intraoperative gonioscopy.²⁸ Access for device implantation was gained through the same corneal incision used for phacoemulsification. After adequate visualisation and confirmation of an open-angle and accessible gonioanatomy, a cyclodialysis cleft was surgically created using the cannula under viscoelastic maintenance of the anterior chamber. The biostent was then deployed within the cleft. Irrigation/aspiration was performed to evacuate the viscoelastic and complete the procedure. Final postoperative gonioconfirmation was done to verify implant position. Patients received a standard postoperative regimen of topical antibiotics (fourth generation fluoroquinolone) and steroids (prednisolone acetate) 4 \times /daily for 30 days.

Patients returned for postoperative visits at approximately 1-week, 1-month, 6-month and 12-month time points for safety assessments and IOP measurements (Goldman tonometry and slit lamp evaluation). Ocular hypotensive medications were reintroduced based on clinical judgement by the investigator to achieve each patient's individualised target IOP.

Table 2 Baseline characteristics

Sample size, N	10
Age, years, mean±SD	74.1±7.9
Ethnicity: Hispanic, n (%)	10 (100)
Gender: female, n (%)	4 (40)
Primary Open Angle Glaucoma (POAG) Confirmed, n (%)	10 (100)
Phakic lens status, n (%)	10 (100)
Baseline best corrected visual acuity (BCVA), mean, LogMAR (Snellen equivalent)	0.81 (20/130)
Baseline IOP, mm Hg, mean±SD	24.2±6.9
Number of IOP lowering drugs, mean±SD	1.3±0.8
Baseline endothelial cell density, cells/mm ² , mean±SD	2618.9±227.7
IOP, intraocular pressure.	

Statistics

Continuous data are expressed as mean±SD, with differences in starting versus 12-month IOP and medication numbers compared using paired two-tailed t-tests. Categorical data are presented as numbers and percentages, and were compared where indicated using Fisher exact test with 2×2 contingency tables. Statistical significance was defined as p<0.05. Statistical and graphing software included Excel (Microsoft, Redmond, Washington, USA) and Prism V.5.0 (GraphPad Software, La Jolla, California, USA).

RESULTS

The case series consists of 10 patients with OAG. Demographic and baseline characteristics of the subjects are presented in [table 2](#).

At 12 months postoperatively, there was a robust and sustained 40% IOP-lowering effect from baseline (p=0.004, paired t-test), and a significant 62% reduction in IOP-lowering medications required (p=0.037) ([tables 3 and 4](#); [figure 3](#)). All stents remained in place and appeared patent by ultrasound microscopy and gonioscopy ([figure 2](#)). Endothelial cell densities ([table 3](#)) were in-line with outcomes from other similar studies ([table 5](#)).

Table 3 Key safety outcomes

	Baseline	12 months
BCVA LogMAR, mean (Snellen equivalent)	0.81 (20/130)	0.26 (20/36)
IOP, mm Hg, mean±SD	24.2±6.9	14.6±3.2
IOP >30 mm Hg, %	10	0
IOP >20 mm Hg, %	70	0
>2 lines drop in BCVA	–	0%
IOP-lowering drugs, mean, n	1.3	0.5
Endothelial cell density, cells/mm ² , mean±SD	2619±228	2312±210
ECD <2000 cells/mm ² , n	0	0
>25% endothelial cell loss, n	–	0
Inflammation, persistent (>1M)	–	0
Inflammation, severe (grade 4+)	–	0
Hyphema, persistent (>1M)	–	0
Hyphema, severe (>3 mm)	–	0
Corneal oedema, persistent (>1M)	–	0
Stent migration	–	0
Stent-corneal touch	–	0
BCVA, Best Corrected Visual Acuity; ECD, Endothelial Cell Density; IOP, intraocular pressure.		

Table 4 Key efficacy outcomes

	Baseline	1 month	6 months	12 months
	N=10	N=10	N=10	N=10
Mean IOP (mm Hg)	24.2	14.4	13.6	14.6
SD	6.9	1.9	1.8	3.2
% IOP Reduction	–	41	44	40
Noof ular hypotensive meds	1.3	0.9	0.5	0.5
% Meds reduction	–	38	62	62
IOP, intraocular pressure.				

All cases had an uneventful cataract surgery with biostent implantation. There were no intraoperative or postoperative complications ([table 3](#)). In 7 of the 10 cases, there was minimal blood reflux from the supraciliary cleft, which is expected and was not associated with any significant postoperative hyphema. No cases of severe or persistent inflammation or hyphema occurred, and no stent migration or corneal touch was observed through the 12-month follow-up period. Operated eyes had good acuity outcomes, increasing from an average baseline BCVA of 0.81 logMar (20/130 Snellen) to 0.26 logMar (20/36 Snellen) at 12 months (p=0.001); all eyes displayed acuity improvement from baseline. Endothelial cell loss was within expected ranges, and no eye displayed cell densities below 2000/mm² at 12 months.

DISCUSSION

This study provides first-in-human experience of a biostent procedure for treating OAG that consists of allograft implant as a porous hydrophilic implant material to reinforce the cyclodialysis cleft and create a durable conduit for suprachoroidal outflow. This MIGS approach creates a hardware-free, biocompatible and homologous biotissue stenting pathway to lower IOP by enhancing aqueous drainage into the suprachoroidal space.

The allograft tissue biostent was well tolerated with no intraocular adverse events. There was no associated anterior or posterior segment inflammation, bleeding or evidence of local reaction such as peripheral anterior synechiae. Recovery from the combined phacobiostent procedure was similar to what is observed after standard phacoemulsification/IOL implantation alone. All patients received standard post-phaco anti-inflammatory and antibiotic treatment which was tapered and discontinued by postoperative 1 month. There were no cases of prolonged or persistent uveitis. Our experience points to strong biocompatibility and tolerability of the homologous allograft implant when used endosclerally for sustained supraciliary cleft reinforcement.

The biotissue implant appears to remain stably positioned within the cyclodialysis cleft. There was no evidence of postoperative migration or corneal touch as assessed by clinical gonioscopy. Unlike first-generation implants that are made of stiff inflexible hardware and were prone to synthetic foreign body reaction, slippage and anteriorisation, the biostent is shaped from homologous conforming and flexible tissue which adheres well to the endoscleral wall of the cleft. The biostent tissue is porous and hydrophilic to provide for aqueous conductivity, yet it is not made of slippery plastic or metal materials which can be prone to anterior or posterior dislodgement.

In addition to the inherent biocompatible nature of allograft material, other important factors played roles in assuring controlled deployment and postimplantation stability. On deployment and ejection from the sleeve of the cannula, the

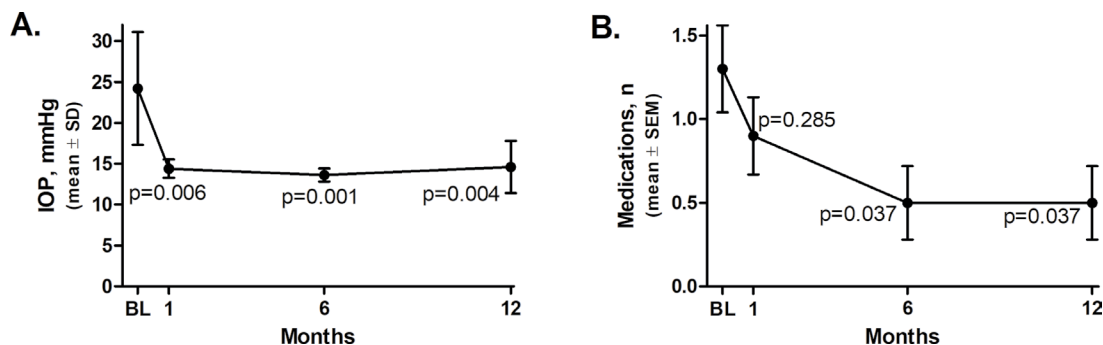


Figure 3 Intraocular pressure (IOP) and glaucoma medication use through 12 months after biostenting eyes with open-angle glaucoma.

compressed biostent expands slightly as it exits into the cleft. This provides further appositional tissue capture and adherence within the supraciliary cleft. Also, a cannula system that has biometric implantation depth control can ensure positional precision of the implant during deployment at the iris insertion plane. This can eliminate the need for postdeployment adjustment. Given the ease of implantation and depth control design, gonioprism-free implantation was performed for some cases with stent position confirmed by gonioscopic visualisation.

Given the inherent hardware-free design characteristics of the homologous biotissue implant material and the controlled depth gonioscopic implantation of the biostent that assures post-implantation positional stability in the supraciliary space, it is not surprising that there were no cases of stent migration, anteriorisation of the material, or corneal/endothelial touch. Using allograft scleral tissue has the inherent advantage that it provides a hardware-free homologous interface with the native endo-scleral wall which is not as prone to slippage because acellular matrix adheres to the neighbouring congruous scleral tissue.

Endothelial health appeared well preserved through 12 months of follow-up after biostent implantation, and is consistent with 24-month data from other commercial MIGS devices in a comparable population of OAG patients undergoing combined phaco+MIGS procedure (table 5). Refractive outcomes were excellent, with average postoperative 12-month BCVA having improved to 20/36 Snellen and all eyes showing improved acuity.

Using homologous scleral biotissue for stenting the cyclodialysis cleft is intended to provide substantial advantages when it comes to the cornea and endothelial health. First generation suprachoroidal stents (eg, CyPass) were stiff non-compliant devices that could cause endothelial cell loss when positioned too anteriorly.^{20,23} Such endothelial cell loss is mostly subclinical and mostly limited to eyes with a suboptimally deployed anteriorised implant where one or more of the retention rings are in the anterior chamber.

This study is the only one to our knowledge to provide clinical experience and feasibility data of successful intraoperative microtrephination and biotissue stent shaping. This case series used a high-fidelity microtrephination instrument to create an allograft biostent of approximately 6 mm length and 500 µm

width using high-precision minimal manipulation of the scleral allograft. The trephined allograft biostent was then compression loaded into the cannula of the delivery device and deployed into the supraciliary pocket/cleft to create a stented conduit for aqueous drainage.

Lastly, the study demonstrates similar IOP-lowering biological effect as seen in clinical trials of other supraciliary stenting procedures, with a significant reduction in baseline IOP down into the mid-teens with a parallel reduction in need for IOP-lowering medications. The IOP-lowering effect was robust and sustained through the duration of the study (↓41% from baseline at month 1 and 40% improvement at month 12). Ocular hypotensive medication dependence was also reduced by 62% from baseline. There were no cases of hypotony and no patient’s IOP increased above 21 mm Hg postoperatively. This is particularly encouraging given that the patients in this cohort appeared to have more severe glaucomatous status at baseline than subjects in other suprachoroidal stent trials where the mean unmedicated baseline IOP was 24 mm Hg compared with the mean medicated IOP of this series of 24 mm Hg on 1.3 IOP lowering medications (implying a potentially higher baseline unmedicated wash-out IOP above 24 mm Hg).²⁹

While these results are encouraging, this study is limited in its size and duration. Performed primarily as a feasibility and safety study, only 12 months of follow-up are available. Other limitations of the study are the retrospective design and single site location. Additionally, while the biostent IOP-lowering effect is robust, it includes the additive IOP lowering effect of the concomitant cataract surgery and further studies in the stand-alone use of this approach will be informative.

Given the promising results of this study, we are planning further evaluation of a larger patient population involving multiple sites globally to validate and extend current findings. As future experiments are conducted, the evidence of validity of this novel biostent can be strengthened and demonstrate its value within the glaucoma surgeon’s armamentarium.

Acknowledgements The authors thank Matthew Silverman PhD, of Biomedical Publishing Solutions (Panama City, FL; mattsilver@yahoo.com) for scientific analytical, statistical and writing assistance.

Table 5 Endothelial cell loss across commercial MIGS technologies

	Biostent+Phaco 12 months	iStent+Phaco 24 months	Hydrus+Phaco 24 months	Phaco alone 24 months	Xen Gel+Phaco 24 months	Omni device
Current study		iStent FDA study	Hydrus FDA study	iStent/Hydrus FDA studies	Clinical study	N/A
% ECL	11	13.1	14	10–12.3	14.3	Unknown

ECL, endothelial cell loss; FDA, US Food and Drug Administration; MIGS, minimally invasive glaucoma surgery; N/A, not available.

Contributors Research conception and design: TI and IKA. Data acquisition and/or research execution: TI, GK and IKA. Data analysis and interpretation: all authors.

Funding The authors have not declared a specific grant for this research from any funding agency in the public, commercial or not-for-profit sectors.

Competing interests TI is a consultant for Iantrek, and holds a patent for the biostent. RNW is a board member and consultant for Iantrek. GK, RP and IKA are consultants for Iantrek.

Patient consent for publication Not applicable.

Ethics approval This study was reviewed by the WCG Institutional Review Board (<https://www.wcgirb.com/>) and certification of exempt status was obtained (#115522041). All patient data were anonymised and treated with confidentiality according to the tenets of the Declaration of Helsinki.

Provenance and peer review Not commissioned; externally peer reviewed.

Data availability statement Data are available on reasonable request.

Open access This is an open access article distributed in accordance with the Creative Commons Attribution Non Commercial (CC BY-NC 4.0) license, which permits others to distribute, remix, adapt, build upon this work non-commercially, and license their derivative works on different terms, provided the original work is properly cited, appropriate credit is given, any changes made indicated, and the use is non-commercial. See: <http://creativecommons.org/licenses/by-nc/4.0/>.

ORCID iD

Tsontcho Ianchulev <http://orcid.org/0000-0002-9893-5909>

REFERENCES

- Flaxman SR, Bourne RRA, Resnikoff S, *et al.* Global causes of blindness and distance vision impairment 1990–2020: a systematic review and meta-analysis. *Lancet Glob Health* 2017;5:e1221–34.
- Prum BE, Rosenberg LF, Gedde SJ, *et al.* Primary Open-Angle Glaucoma Preferred Practice Pattern® Guidelines. *Ophthalmology* 2016;123:P41–111.
- Boland MV, Ervin A-M, Friedman DS, *et al.* Comparative effectiveness of treatments for open-angle glaucoma: a systematic review for the U.S. preventive services Task force. *Ann Intern Med* 2013;158:271–9.
- Bhosle MJ, Reardon G, Camacho FT, *et al.* Medication adherence and health care costs with the introduction of latanoprost therapy for glaucoma in a Medicare managed care population. *Am J Geriatr Pharmacother* 2007;5:100–11.
- Friedman DS, Quigley HA, Gelb L, *et al.* Using pharmacy claims data to study adherence to glaucoma medications: methodology and findings of the glaucoma adherence and persistency study (gaps). *Invest Ophthalmol Vis Sci* 2007;48:5052.
- Musch DC, Gillespie BW, Lichter PR, *et al.* Visual field progression in the Collaborative initial glaucoma treatment study the impact of treatment and other baseline factors. *Ophthalmology* 2009;116:200–7.
- Parrish RK, Feuer WJ, Schiffman JC, *et al.* Five-Year follow-up optic disc findings of the Collaborative initial glaucoma treatment study. *Am J Ophthalmol* 2009;147:717–24.
- Wong MHY, Husain R, Ang BCH, *et al.* The Singapore 5-fluorouracil trial: intraocular pressure outcomes at 8 years. *Ophthalmology* 2013;120:1127–34.
- Fontana H, Nouri-Mahdavi K, Caprioli J. Trabeculectomy with mitomycin C in pseudophakic patients with open-angle glaucoma: outcomes and risk factors for failure. *Am J Ophthalmol* 2006;141:652–9.
- Gedde SJ, Herndon LW, Brandt JD, *et al.* Postoperative complications in the tube versus trabeculectomy (TVT) study during five years of follow-up. *Am J Ophthalmol* 2012;153:804–14.
- Barton K, Feuer WJ, Budenz DL, *et al.* Three-Year treatment outcomes in the Ahmed Baerveldt comparison study. *Ophthalmology* 2014;121:1547–57.
- Richter GM, Coleman AL. Minimally invasive glaucoma surgery: current status and future prospects. *Clin Ophthalmol* 2016;10:189–206.
- Birnbaum FA, Neeson C, Solá-Del Valle D. Microinvasive glaucoma surgery: an evidence-based review. *Semin Ophthalmol* 2021;36:772–86.
- Samuelson TW, Katz LJ, Wells JM, *et al.* Randomized evaluation of the trabecular micro-bypass stent with phacoemulsification in patients with glaucoma and cataract. *Ophthalmology* 2011;118:459–67.
- Craven ER, Katz LJ, Wells JM, *et al.* Cataract surgery with trabecular micro-bypass stent implantation in patients with mild-to-moderate open-angle glaucoma and cataract: two-year follow-up. *J Cataract Refract Surg* 2012;38:1339–45.
- Nichani P, Popovic MM, Schlenker MB, *et al.* Microinvasive glaucoma surgery: a review of 3476 eyes. *Surv Ophthalmol* 2021;66:714–42.
- Ahmed IIK, Fea A, Au L, *et al.* A prospective randomized trial comparing Hydrus and iStent microinvasive glaucoma surgery implants for Standalone treatment of open-angle glaucoma: the compare study. *Ophthalmology* 2020;127:52–61.
- Fea AM, Ahmed IIK, Lavia C, *et al.* Hydrus microstent compared to selective laser trabeculoplasty in primary open angle glaucoma: one year results. *Clin Exp Ophthalmol* 2017;45:120–7.
- Laspras P, Garcia-Feijoo J, Martinez-de-la-Casa JM, *et al.* Three-Year results of Hydrus Microstent with phacoemulsification. *Ophthalmol Glaucoma* 2019;2:440–2.
- Vold S, Ahmed IIK, Craven ER, *et al.* Two-Year COMPASS trial results: supraciliary Microstenting with phacoemulsification in patients with open-angle glaucoma and cataracts. *Ophthalmology* 2016;123:2103–12.
- Myers JS, Masood I, Hornbeak DM, *et al.* Prospective Evaluation of Two iStent® Trabecular Stents, One iStent Supra® Suprachoroidal Stent, and Postoperative Prostaglandin in Refractory Glaucoma: 4-year Outcomes. *Adv Ther* 2018;35:395–407.
- Denis P, Hirneiß C, Reddy KP, *et al.* A First-in-Human Study of the Efficacy and Safety of MINject in Patients with Medically Uncontrolled Open-Angle Glaucoma (STAR-I). *Ophthalmol Glaucoma* 2019;2:290–7.
- Lass JH, Benetz BA, He J, *et al.* Corneal endothelial cell loss and morphometric changes 5 years after phacoemulsification with or without CyPass Micro-Stent. *Am J Ophthalmol* 2019;208:211–8.
- Sandhu A, Jayaram H, Hu K, *et al.* Ab interno supraciliary microstent surgery for open-angle glaucoma. *Cochrane Database Syst Rev* 2021;5:CD012802.
- Prausnitz MR, Noonan JS. Permeability of cornea, sclera, and conjunctiva: a literature analysis for drug delivery to the eye. *J Pharm Sci* 1998;87:1479–88.
- Kitnarong N, Srikulsasitorn B, Aurboonsong T. Glycerin-preserved Human-donor corneoscleral patch grafts for glaucoma drainage devices. *J Glaucoma* 2020;29:1065–9.
- Tsoukanas D, Xanthopoulou P, Charonis AC, *et al.* Heterologous, fresh, human donor sclera as patch graft material in glaucoma drainage device surgery. *J Glaucoma* 2016;25:558–64.
- Pillunat LE, Erb C, Jünemann AG, *et al.* Micro-invasive glaucoma surgery (MIGS): a review of surgical procedures using stents. *Clin Ophthalmol* 2017;11:1583–600.
- Jampel HD, Chon BH, Stamper R, *et al.* Effectiveness of intraocular pressure-lowering medication determined by washout. *JAMA Ophthalmol* 2014;132:390–5.
- Grierson I, Minckler D, Rippey MK, *et al.* A novel suprachoroidal microinvasive glaucoma implant: in vivo biocompatibility and biointegration. *BMC Biomed Eng* 2020;2:10.