

# Results of surgery on macular holes that develop after rhegmatogenous retinal detachment

M Benzerroug, O Genevois, K Siahmed, Z Nasser, M Muraine, G Brasseur

Department of Ophthalmology,  
Charles Nicolle University  
Hospital, Rouen, France

Correspondence to:  
M Benzerroug, Department of  
Ophthalmology, 1 rue Germont,  
Charles Nicolle University  
Hospital, 76000 Rouen, France;  
mounir.benzerroug@free.fr

Accepted 4 August 2007

## ABSTRACT

**Aims:** To evaluate the characteristics and surgical prognosis of macular holes that develop after rhegmatogenous retinal detachment repair.

**Design:** Retrospective, interventional, consecutive case series.

**Methods:** The case records of nine patients who developed a new full-thickness macular hole after prior RD repair were reviewed over 6 years. Optical coherence tomography (OCT) confirmed these holes. They were offered surgical repair with a median follow-up of 13.3 months (1–63 months). Main outcomes included preoperative vitreo-macular status, OCT evaluation and postoperative visual acuity.

**Results:** 1007 eyes underwent surgery for prior retinal detachment between August 1999 and September 2005. Nine eyes developed a full-thickness macular hole (prevalence 0.9%): five developed after scleral buckling surgery, one after pneumatic retinopexy and three after primary vitrectomy. The mean time to macular hole diagnosis after RD was 2.9 months (0.5–18). All patients underwent macular hole surgery by the same surgeon. At 1 month, macular hole repair was noticed in eight eyes. In this group, visual acuity at a median of 11.9 months of follow-up was 20/125 (20/400 – 20/63). Three eyes had an improvement of more than three Snellen lines.

**Conclusions:** Macular holes developing after RD repair is a rare complication (less than 1%). Its physiopathological mechanisms are not well known. Conventional macular hole surgery including pars plana vitrectomy, inconstant internal limiting membrane delamination and long-acting gas tamponade seems to achieve to macular reattachment (89%). The visual outcome seems conditioned by the macular status noticed during the RD.

Idiopathic macular hole is a well-known macular disease. Its origin has been attributed to tangential vitreofoveal traction responsible of centrofoveal defect.<sup>1,2</sup> These data have been confirmed by optical coherence tomography (OCT).<sup>3</sup> Thus, posterior vitreous detachment seems to be a protective factor to macular hole development. However, the occurrence of rhegmatogenous retinal detachment (RD) is often secondary to posterior vitreous detachment.

Macular holes are an uncommon cause of rhegmatogenous RDs but can occur secondary to a retinal detachment associated with peripheral breaks.

The condition has been described after scleral buckling,<sup>4</sup> pneumatic retinopexy<sup>5,6</sup> and vitrectomy.<sup>7,8</sup>

Many surgeons have attempted closure of such macular holes, but the results of surgery have not

been widely published. We describe the characteristics of nine patients with a macular hole that develops after successful rhegmatogenous retinal detachment surgery. All patients underwent surgery to close the macular hole.

## METHODS

The medical records of all patients who had undergone retinal detachment surgery were reviewed from August 1999 to September 2005 retrospectively (1007 eyes). Following surgery, nine eyes developed a full-thickness macular hole (0.9%) as confirmed by OCT (OCT 3, Stratus®, Carl Zeiss Meditec, Dublin, CA). All patients were offered surgery repair of their macular hole.

The data collected included: the visual acuity at the time of retinal detachment and at the time of macular hole diagnosis; foveal involvement whether present or not; the type of surgical procedure for RD repair; the period between RD occurrence and macular hole diagnosis; and the period between macular hole diagnosis and its repair. We reported one case where OCT was performed during RD involving the macula (number 8). The recorded clinical variables were: age, gender, spherical equivalent, phakic status and axial length. Posterior vitreous detachment was determined via slit-lamp biomicroscopy of the posterior segment to allow direct visualisation of the Weiss ring.

The outcome measures for eyes undergoing macular hole repair included the number of Snellen lines of improvement in the visual acuity after macular hole repair, the status of the macula after macular hole repair using OCT, the presence of a cataract surgery after macular hole repair and the duration of the follow-up.

The Student t test was performed for comparison of the visual acuity before and after macular hole repair.

## RESULTS

Nine full-thickness macular holes were diagnosed after RD repair between September 1999 and August 2005 (0.9% of RD operated during the same period). We summarised patients' characteristics (table 1) and outcomes (table 2).

Three men and six women who had a median age of 58 years old (range 43–69 years) were followed up. Six of them were phakic, and the pre-RD median spherical equivalent was –2.7 (range –18.75 to +1.25). The median axial length was 23.41 mm (range 20.53–29.03 mm). Only one eye had an axial length of more than 26 mm.

At the time of RD presentation, seven involved the fovea, and posterior vitreous detachment was

**Table 1** Patients' characteristics

No.	Age, sex	Macular status	PVD	Axial length	Surgical procedure	VA after RD procedure
01	59, F	Off	Yes	25.10	Scleral buckling, gas	20/200
02	49, F	Off	Yes	29.03	Vitrectomy, scleral buckling	20/200
03	61, M	Off	Yes	24.00	Scleral buckling	20/100
04	69, F	Off	No	20.53	Vitrectomy, scleral buckling	20/200
05	43, M	On	Yes	22.95	Vitrectomy, scleral buckling	20/50
06	63, M	Off	Yes	21.00	Scleral buckling, gas	20/400
07	65, F	Off	Yes	21.12	Scleral buckling, gas	20/200
08	62, F	Off	Yes	22.03	Scleral buckling	20/800
09	64, F	On	Yes	24.94	Pneumatic retinopexy	20/100

noticed on eight eyes using slit-lamp biomicroscopy. Retinal tears were observed clinically in all eyes.

Most frequently, macular holes developed after scleral buckling repair (six eyes), as compared with vitrectomy (three eyes) or pneumatic retinopexy (one eye). The median interval between RD repair and macular hole diagnosis was 3.4 months (range 0.5–18 months). At the time of macular hole diagnosis, three eyes had epiretinal membrane (ERM). All patients<sup>9</sup> underwent macular hole repair 3.9 months after the diagnosis (range 1–10 months).

Surgical repair of the macular hole included vitrectomy, macular membrane peeling (three eyes), internal limiting membrane delamination (four eyes) without dye assistance and postoperative face down positioning during ten days.

Anatomic closure of the hole was achieved in eight of nine cases (89%). One macular hole (number 2) remained open after one reintervention; its diameter before surgery was 961 µm, which might explain the failure of surgery.

The best-corrected visual acuity after RD repair was 20/125 (range 20/800–20/50). This improved to a median of 20/100 (range 20/400–20/63) after macular hole repair ( $p = 0.04$ ). Three patients of nine improved three Snellen lines or more. The median length of follow-up after macular hole repair was 13.1 months (range 1–63 months).

Patient number 8 (tables 1 and 2) developed a full-thickness macular hole 2.5 months after scleral buckling. OCT 2 was performed during RD because of fundus cystic macular aspect (fig 1), but no macular hole was found.

After macular hole repair, visual improvement was limited, and OCT 3 showed retinal atrophy (fig 2).

## DISCUSSION

Macular holes that occur frequently in highly myopic patients with posterior staphylomas and myopic degeneration are well described.<sup>9</sup> However, those that develop after RD repair are uncommon. In our series, they represent less than 1% of eyes that have previously undergone a retinal detachment procedure.

This incidence is similar to Brown's first description of three patients who developed a macular hole after scleral buckling (incidence of 0.9%).<sup>4</sup>

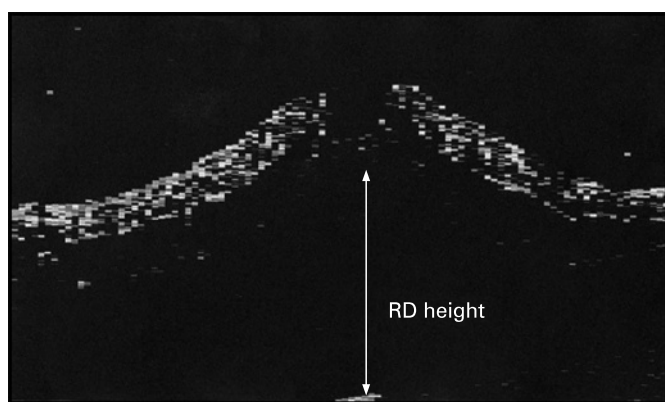
They occurred predominantly in eyes that had RD involving the fovea (seven of nine eyes) within the first 3 months. Scleral buckling was mainly performed (five of nine eyes). Similarly, Moshfeghi *et al*<sup>10</sup> described 12 patients with macular holes after scleral buckling or pneumatic retinopexy. However, in our study, macular holes were noted after vitrectomy (three eyes). Their occurrence was at an age of onset similar to that seen with idiopathic macular holes. It does not seem to be associated also with highly myopic eyes or lens status. Because of the limitation in the number of patients, no statistical comments can be made about the risk factors allowing those macular holes to develop.

In this study, all patients underwent a surgical procedure after an observation period in some cases (numbers 7 and 8). No spontaneous closure was noticed (data not shown). Good anatomic closure was achieved (89%). These macular holes behaved like idiopathic macular holes with a similar success in their anatomic closure.<sup>11–13</sup> However, final visual acuity was limited in our series, even if it was statistically significant ( $p = 0.04$ ). Only three of nine patients gained at least three Snellen lines. Two of them had a RD without macular detachment (table 1). In the other five patients, visual improvement seems to depend on macular status during RD (table 2). These visual outcomes are poorer compared with idiopathic macular holes.<sup>14</sup> However, we believe that with a long-term follow-up, these results might improve.<sup>12</sup>

The mechanism of these macular holes developed after retinal detachment repair is not identified. Tangential perifoveal traction is thought to be responsible for the formation of idiopathic macular holes.<sup>1–3</sup> Despite the fact that PVD and retinal tears were identified in all eyes at the time of RD diagnosis through using biomicroscopy and OCT (patient 8 only), we believe that PVD did not protect against macular hole development. Indeed, it seems to be curious that a MH develops even if PVD was noticed before vitrectomy. Gordon *et al*<sup>15</sup> report

**Table 2** Macular hole diagnosis and surgery, anatomic and visual outcomes

No.	VA at MH diagnosis	Diagnostic delay (months)	Lens status	Final VA	Follow-up	MH closure
01	20/400	2.0	Phakic	20/200	01	Yes
02	20/400	1.0	Pseudophakic	20/200	17	No
03	20/100	1.0	Phakic	20/100	02	Yes
04	20/200	1.0	Pseudophakic	20/200	06	Yes
05	20/100	18.0	Pseudophakic	20/63	06	Yes
06	20/400	1.0	Pseudophakic	20/400	04	Yes
07	20/200	0.5	Phakic	20/100	14	Yes
08	20/400	2.5	Pseudophakic	20/63	06	Yes
09	20/200	4.0	Pseudophakic	20/100	63	Yes



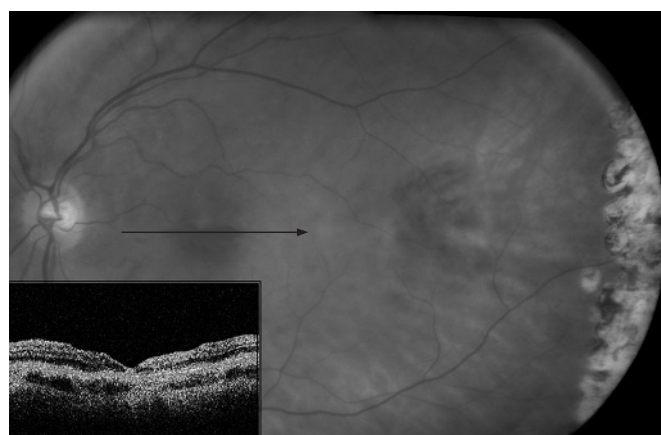
**Figure 1** Patient 8 at initial examination. RD involving the macula with PVD. One horse tear was identified. OCT 2 was performed because of fundus cystic macular aspect.

five patients with idiopathic full-thickness macular hole formation that occurred in the presence of a well-documented complete PVD. Thus, we can evoke three hypotheses to explain the appearance of this MH: has the posterior hyaloid really been removed during vitrectomy? Did the macular detachment induce microcystic degeneration (case 8)? ERM tangential contraction may lead to MH formation.

Yoshida and Kishi<sup>16</sup> suggest that after idiopathic macular hole surgery, ERM can induce a reopening. Thus, the cause of macular holes in this group may be related to the cystic macular oedema induced by RD. The unique architecture of the macula makes it susceptible to fluid accumulation. There is a swelling of the middle/outer macular region associated with a thickening of the foveola (fig 1). The combination of macular reapplication, scleral buckling or pneumatic retinopexy can possibly change the tangential forces across the foveal area of the macula which lead to macular hole formation. It might explain their early development after RD repair (less than 3 months). Tornambe suggests through using a model of hydrated cellulose sponge compared with Optical Coherence Tomography findings that hydration of the middle and outer retinal tissue contributes to full thickness macular hole formation.<sup>17</sup> PVD acts then as a trigger inducing a retinal defect in the inner foveola.

Also, PVD assessment by clinical observation of the Weiss ring still remains an inconsistent method. It confirms the separation between the posterior hyaloid and the optic disk. Uchino *et al*<sup>18</sup> have demonstrated that OCT is helpful in identifying vitreofoveal detachment. In our series, it was performed only in one eye during RD. We did not detect any macular hole or vitreo foveal traction.

In conclusion, these macular holes that develop after RD repair are unusual. They appear after RD involving the macula with PVD most frequently after scleral buckling procedure. Their origin seems to be different from idiopathic macular holes. However, they behave like idiopathic macular holes with an excellent rate of anatomic closure. The visual prognosis would depend on macular status during RD.



**Figure 2** Patient 8. MH was diagnosed 2.5 months after the scleral buckling procedure. After MH surgery, anatomic closure of the hole was achieved. However, visual recuperation was limited. OCT 3 showed MH closure associated with foveal atrophy (foveal retinal thickness: 87  $\mu$ m).

**Competing interests:** None.

## REFERENCES

1. Gass JDM. Idiopathic senile macular hole: its early stages and pathogenesis. *Arch Ophthalmol* 1988;**106**:626–39.
2. Johnson RN, Gass JD. Idiopathic macular holes: observations, stages of formation, and implications for surgical intervention. *Ophthalmology* 1988;**95**:917–24.
3. Gaudric A, Haouchine B, Massin P, *et al*. Macular hole formation: new data provided by optical coherence tomography. *Arch Ophthalmol* 1999;**117**:744–51.
4. Brown GC. Macular hole following rhegmatogenous retinal detachment repair. *Arch Ophthalmol* 1988;**106**:765–6.
5. Hejny C, Han DP. Vitrectomy for macular hole after pneumatic retinopexy. *Retina* 1997;**17**:356–7.
6. Avins LR, Krummenacher TR. Macular holes after pneumatic retinopexy. *Arch Ophthalmol* 1988;**106**:724–5.
7. Tsujikawa M, Saito Y, *et al*. Secondary vitrectomy for the treatment of macular holes occurring after vitrectomy. *Ophthalmic Surg Lasers* 1997;**28**:336–7.
8. Lipham WJ, Smiddy WE. Idiopathic macular hole following vitrectomy: implications for pathogenesis. *Ophthalmic Surg Lasers* 1997;**28**:633–9.
9. Greco GM, Bonavolonta G. Treatment of retinal detachments due to macular holes. *Retina* 1987;**7**:177–9.
10. Moshfeghi AA, Salam GA, Deramo VA, *et al*. Management of macular holes that develop after retinal detachment repair. *Am J Ophthalmol* 2003;**136**:895–9.
11. Haritoglou C, Reiniger IW, Schaumberger M, *et al*. Five-year follow-up of macular hole surgery with peeling of the internal limiting membrane: update of a prospective study. *Retina* 2006;**26**:618–22.
12. Scott IU, Moraczewski AL, Smiddy WE, *et al*. Long-term anatomic and visual acuity outcomes after initial anatomic success with macular hole surgery. *Am J Ophthalmol* 2003;**135**:633–40.
13. Ryan EH, Gilbert Jr and HD. Results of surgical treatment of recent-onset full-thickness idiopathic macular holes. *Arch Ophthalmol* 1994;**112**:1545–53.
14. Ezra E, Gregor ZJ. Morfields Macular Hole Study Group Report No. 1. Surgery for idiopathic full-thickness macular hole: two-year results of a randomized clinical trial comparing natural history, vitrectomy, and vitrectomy plus autologous serum: Morfields Macular Hole Study Group Report no. 1. *Arch Ophthalmol* 2004;**122**:224–36.
15. Gordon LW, Glaser BM, le D, *et al*. Full-thickness macular hole formation in eyes with a pre-existing complete posterior vitreous detachment. *Ophthalmology* 1995;**102**:1702–5.
16. Yoshida M, Kishi S. Pathogenesis of macular hole recurrence and its prevention by internal limiting membrane peeling. *Retina* 2007;**27**:169–73.
17. Tornambe PE. Macular hole genesis: the hydration theory. *Retina* 2003;**23**:421–4.
18. Uchino E, Uemura A, Ohba N. Initial stages of posterior vitreous detachment in healthy eyes of older persons evaluated by optical coherence tomography. *Arch Ophthalmol* 2001;**119**:1475–9.