



Cover image: Rodin, Auguste (1840-1917): Orpheus and Eurydice, French, 1893 New York, Metropolitan Museum of Art, Marble, H. 127.0 cm; W. 76.2 cm; D. 71.1 cm. Inv N: 10.63.2. Cover credit: © 2012. Image copyright The Metropolitan Museum of Art/Art Resource/Scala, Florence. See page 489.

Editors-in-Chief

Harminder S Dua (UK)
Arun D Singh (USA)

Translation Editors

Evelyn Fu (USA)
José Gomes (Brazil)
Alvin Kwok (Hong Kong)
Merce Morral Palau (Spain)
David Pelayes (Argentina)
Daniel de Souza Pereira (Brazil)

Editorial Office

BMJ Publishing Group Ltd,
BMA House, Tavistock Square,
London WC1H 9JR, UK
T: +44 (0)20 7383 6170
F: +44 (0)20 7383 6668
E: bjo@bmjgroup.com

ISSN: 0007-1161 (print)
ISSN: 1468-2079 (online)

Impact factor: 2.934

Disclaimer: British Journal of Ophthalmology is owned and published by BMJ Publishing Group Ltd, a wholly owned subsidiary of the British Medical Association. The owner grants editorial freedom to the Editor of British Journal of Ophthalmology.

British Journal of Ophthalmology follows guidelines on editorial independence produced by the World Association of Medical Editors and the code on good publication practice of the Committee on Publication Ethics.

British Journal of Ophthalmology is intended for medical professionals and is provided without warranty, express or implied. Statements in the journal are the responsibility of their authors and advertisers and not authors' institutions, the BMJ Publishing Group Ltd or the BMA unless otherwise specified or determined by law. Acceptance of advertising does not imply endorsement.

To the fullest extent permitted by law, the BMJ Publishing Group Ltd shall not be liable for any loss, injury or damage resulting from the use of British Journal of Ophthalmology or any information in it whether based on contract, tort or otherwise. Readers are advised to verify any information they choose to rely on.

Copyright: © 2012 BMJ Publishing Group Ltd. All rights reserved; no part of this publication may be reproduced, stored in a retrieval system or transmitted in any form or by any means, electronic, mechanical, photocopying, recording or otherwise with out the prior permission of British Journal of Ophthalmology.

British Journal of Ophthalmology is published by BMJ Publishing Group Ltd, typeset by TNQ Books & Journals, Chennai, India and printed in the UK on acid-free paper by Latimer Trend & Co Ltd, Plymouth.

British Journal of Ophthalmology (ISSN 0007-1161) is published monthly by BMJ Publishing Group and is distributed in the USA by Air Business Ltd. Periodicals postage paid at Jamaica NY 11431 POSTMASTER: send address changes to Journal name, Air Business Ltd, c/o Worldnet Shipping Inc., 156-15, 146th Avenue, 2nd Floor, Jamaica, NY 11434, USA

Contents

Volume 96 Issue 4 | BJO April 2012

Editorials

471 Management of ocular surface exposure
C Lane

473 Retinoblastoma: direct chemotherapeutic drug delivery into the vitreous cavity
S Seregard, A D Singh

Innovations

475 A modified digital slit lamp camera system for transillumination photography of intraocular tumours
J Krohn, B Kjersem

Global issues

478 Prevalence of blindness in Western Australia: a population study using capture and recapture techniques
J Crewe, W H Morgan, N Morlet, A Clark, G Lam, R Parsons, A Mukhtar, J Ng, M Crowley, J Semmens

Original articles Clinical science

482 Clinical factors associated with malignancy and HIV status in patients with ocular surface squamous neoplasia at Kilimanjaro Christian Medical Centre, Tanzania
I I Makupa, B Swai, W U Makupa, V A White, S Lewallen

485 Indications and outcomes for revision of gold weight implants in upper eyelid loading
J C Bladen, J H Norris, R Malhotra

490 The effects of systemic α_1 -adrenoreceptor antagonists on pupil diameter
T M Cooney, A Wu, G Wilkes, J I Finkelstein, D C Musch

494 Long-term surgical outcomes of porous polyethylene orbital implants: a review of 314 cases
S-K Jung, W-K Cho, J-S Paik, S-W Yang

499 Intra-arterial chemotherapy for retinoblastoma in eyes with vitreous and/or subretinal seeding: 2-year results
D H Abramson, B P Marr, I J Dunkel, S Brodie, E C Zabor, S J Driscoll, Y P Gobin

503 Development and validation of a computer-aided diagnostic tool to screen for age-related macular degeneration by optical coherence tomography
P Serrano-Aguilar, R Abreu, L Antón-Canalís, C Guerra-Artal, Y Ramallo-Fariña, F Gómez-Ulla, J Nadal

508 Decreased accommodation during decompensation of distance exotropia
A M Horwood, P M Riddell

514 Variation in optical coherence tomography signal quality as an indicator of retinal nerve fibre layer segmentation error
L S Folio, G Wollstein, H Ishikawa, R A Bilonick, Y Ling, L Kagemann, R J Noecker, J G Fujimoto, J S Schuman

519 A hybrid form of retinopathy of prematurity
G Sanghi, M R Dogra, M Dogra, D Katoch, A Gupta

523 In vivo confocal microscopic findings in patients with limbal stem cell deficiency
A Miri, T Alomar, M Nubile, M Al-aqaba, M Lanzini, U Fares, D G Said, J Lowe, H S Dua

530 In vivo confocal microscopic features of normal limbus
A Miri, M Al-Aqaba, A M Otri, U Fares, D G Said, L A Faraj, H S Dua

537 Refractive profile in oculocutaneous albinism and its correlation with final visual outcome
C Yahalom, V Tzur, A Blumenfeld, G Greifner, D Eli, A Rosenmann, S Glanzer, I Anteby

540 Comparison between graded unilateral and bilateral medial rectus recession for esotropia
L Wang, X Wang

544 Cerebrospinal fluid exchange in the optic nerve in normal-tension glaucoma
H E Killer, N R Miller, J Flammar, P Meyer, R N Weinreb, L Remonda, G P Jaggi

MORE CONTENTS ►



This article has been chosen by the Editor to be of special interest or importance and is freely available online.



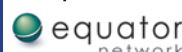
Articles carrying the Unlocked Logo are freely available online under the BMJ Journals unlocked scheme. See <http://bjo.bmj.com/info/unlocked.dtl>

C O P E

COMMITTEE ON PUBLICATION ETHICS

This journal is a member of and subscribes to the principles of the Committee on Publication Ethics

www.publicationethics.org.uk



- 549** Experts do not agree when to treat retinopathy of prematurity based on plus disease
C Slidsborg, J L Forman, A R Fielder, S Crafoord, K Baggesen, R Bangsgaard, H C Fledelius, G Greisen, M la Cour

- 554** Objective perimetry using a four-channel multifocal VEP system: correlation with conventional perimetry and thickness of the retinal nerve fibre layer
F K Horn, C Kaltwasser, A G Jünemann, J Kremers, R P Tornow

- 560** Retinal oxygen saturation is altered in diabetic retinopathy
S H Hardarson, E Stefánsson

- 564** Outcomes of deep anterior lamellar keratoplasty following successful and failed 'big bubble'
U K Bhatt, U Fares, I Rahman, D G Said, S V Maharajan, H S Dua

- 570** 'Kite-tail' fascia lata strips technique: frontalis suspension using a non-endoscopic minimally invasive single-thigh incision approach
C Evereklioglu

- 576** Comparison of scanning laser ophthalmoscopy and high-definition optical coherence tomography measurements of optic disc parameters
L-L Foo, S A Perera, C Y Cheung, J C Allen, Y Zheng, S-C Loon, T Y Wong, T Aung

- 581** IgE and eosinophil cationic protein (ECP) as markers of severity in the diagnosis of atopic keratoconjunctivitis
T H Wakamatsu, Y Satake, A Igarashi, M Dogru, O M A Ibrahim, N Okada, K Fukagawa, J Shimazaki, H Fujishima

Laboratory science

- 587** A shift in the balance of vascular endothelial growth factor and connective tissue growth factor by bevacizumab causes the angi fibrotic switch in proliferative diabetic retinopathy
R J Van Geest, S Y Lesnik-Oberstein, H S Tan, M Mura, R Goldschmeding, C J F Van Noorden, I Klaassen, R O Schlingemann

- 591** Chemosensitivity of conjunctival melanoma cell lines to single chemotherapeutic agents and combinations
H Westekemper, M Freistuehler, G Anastassiou, G Nareyeck, N Bornfeld, K-P Steuhl, M E Scheulen, R A Hilger

- 597** Ischaemia in the Zinn—Haller circle and glaucomatous optic neuropathy in macaque monkeys
M Hiraoka, K Inoue, T Ninomiya, M Takada

Education

- 604** Diagnosis of maternally inherited diabetes and deafness (mitochondrial A3243G mutation) based on funduscopy appearance in an asymptomatic patient
D S Strauss, K B Freund

- 605** Peripheral corneal ring due to hypercarotenaemia in a case of nutritional supplement abuse
J S Chang, P Oellers, C L Karp

PostScript

- 606** Letters

Cover illustration

- 489** Looking back at Orpheus
T Khatib, A D Singh, H S Dua