

Cover image: Taken from Chee S-P, et al. This real-time swept source OCT pre-laser image shows the flat profile of a Morgagnian cataract with a hyperreflective homogenous density liquefied cortex. The hyporeflexive nucleus is positioned more posteriorly and slightly decentered temporally. See page 548.

Editors-in-Chief

Keith Barton (UK)
Jost Jonas (Germany)
James Chodosh (USA)

Editorial Office

BMJ Publishing Group Ltd,
BMA House, Tavistock Square,
London WC1H 9JR, UK
T: +44 (0)20 7111 1105
E: bjo@bmj.com
Twitter: @BJOphthalmology

ISSN: 0007-1161 (print)
ISSN: 1468-2079 (online)

Impact factor: 3.384

Disclaimer: British Journal of Ophthalmology is owned and published by BMJ Publishing Group Ltd, a wholly owned subsidiary of the British Medical Association. The owner grants editorial freedom to the Editor of British Journal of Ophthalmology.

British Journal of Ophthalmology follows guidelines on editorial independence produced by the World Association of Medical Editors and the code on good publication practice of the Committee on Publication Ethics.

British Journal of Ophthalmology is intended for medical professionals and is provided without warranty, express or implied. Statements in the journal are the responsibility of their authors and advertisers and not authors' institutions, the BMJ Publishing Group Ltd or the BMA unless otherwise specified or determined by law. Acceptance of advertising does not imply endorsement.

To the fullest extent permitted by law, the BMJ Publishing Group Ltd shall not be liable for any loss, injury or damage resulting from the use of British Journal of Ophthalmology or any information in it whether based on contract, tort or otherwise. Readers are advised to verify any information they choose to rely on.

Copyright: © 2019 BMJ Publishing Group Ltd. All rights reserved; no part of this publication may be reproduced, stored in a retrieval system or transmitted in any form or by any means, electronic, mechanical, photocopying, recording or otherwise with out the prior permission of British Journal of Ophthalmology.

British Journal of Ophthalmology is published by BMJ Publishing Group Ltd, typeset by Exeter Premedia Services Private Limited, Chennai, India and printed in the UK on acid-free paper.

British Journal of Ophthalmology (ISSN 0007-1161) is published monthly by BMJ Publishing Group and is distributed in the USA by Air Business Ltd. Periodicals postage paid at Jamaica NY 11431 POSTMASTER: send address changes to British Journal of Ophthalmology, Air Business Ltd, c/o Worldnet Shipping Inc., 156-15, 146th Avenue, 2nd Floor, Jamaica, NY 11434, USA.

Reviews

437 Ultrasonic measurement of optic nerve sheath diameter: a non-invasive surrogate approach for dynamic, real-time evaluation of intracranial pressure
L Chen, L Wang, Y Hu, X Jiang, Y Wang, Y Xing

442 Comparative effectiveness and harms of intravitreal antivascular endothelial growth factor agents for three retinal conditions: a systematic review and meta-analysis
A Low, A Faridi, K V Bhavsar, G C Cockerham, M Freeman, R Fu, R Paynter, K Kondo, D Kansagara

Clinical science

452 Choriocapillaris and retinal vascular plexus density of diabetic eyes using split-spectrum amplitude decorrelation spectral-domain optical coherence tomography angiography
F F Conti, V L Qin, E B Rodrigues, S Sharma, A V Rachiatskaya, J P Ehlers, R P Singh

457 Possible connection of short posterior ciliary arteries to choroidal neovascularisations in eyes with pathologic myopia
T Ishida, T Watanabe, T Yokoi, K Shinohara, K Ohno-Matsui

463 Long-term visual outcome and its predictors in macular oedema secondary to retinal vein occlusion treated with dexamethasone implant
C Busch, M Rehak, C Sarvariya, D Zur, M Iglücki, L H Lima, A Invernizzi, F Viola, K Agrawal, S Sinawat, A Couturier, A Mehta, R Juneja, H Jain, A K Agarwal, N Goel, M Nagpal, V Gupta, A Banker, A Loewenstein, M Okada, A O Saatici, A M Mansour, J Chhablani

469 Microvascular abnormalities secondary to radiation therapy in neovascular age-related macular degeneration: findings from the INTREPID clinical trial
F J Freiberg, S Michels, A Muldrew, J Slakter, D O'Shaughnessy, A Czeszynski, L Danielson, T L Jackson, U Chakravarthy

475 Correlation between aqueous flare and residual visual field area in retinitis pigmentosa
K M Nishiguchi, Y Yokoyama, H Kunikata, T Abe, T Nakazawa

481 Premacular membrane formation after scleral buckling for primary rhegmatogenous retinal detachment: prospective study and pathophysiological insights
V Cacioppo, A Govetto, P Radice, G Virgili, A Scialdone

488 Intravitreal chemotherapy in retinoblastoma: expanded use beyond intravitreal seeds
D H Abramson, X Ji, J H Francis, F Catalanotti, S E Brodie, L Habib

494 Efficacy of intravitreal conbercept injection in the treatment of retinopathy of prematurity
Y Bai, H Nie, S Wei, X Lu, X Ke, X Ouyang, S Feng

499 Iris anomalies and the incidence of ACTA2 mutation
K J Taubenslag, H L Scanga, J Huey, J Lee, A Medsinghe, C L Sylvester, K P Cheng, K K Nischal

504 Variability in the ocular phenotype in mucopolysaccharidosis
K Sornalingam, A Javed, T Aslam, P Sergouniotis, S Jones, A Ghosh, J Ashworth

511 White matter microstructural alterations in amblyopic adults revealed by diffusion spectrum imaging with systematic tract-based automatic analysis
T-H Tsai, H-T Su, Y-C Hsu, Y-C Shih, C-C Chen, F-R Hu, W-Y I Tseng

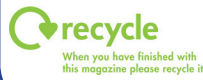MORE CONTENTS ►

This article has been chosen by the Editor to be of special interest or importance and is freely available online.

This article has been made freely available online under the BMJ Journals open access scheme. See <http://authors.bmj.com/open-access>

This journal is a member of and subscribes to the principles of the Committee on Publication Ethics www.publicationethics.org.uk


Member since 2008 JM0005



Br J Ophthalmol: first published as on 1 April 2019. Downloaded from <http://bjo.bmj.com/> on February 1, 2023 by guest. Protected by copyright.

- 517** Compared performance of Spot and SW800 photoscreeners on Chinese children
X Qian, Y Li, G Ding, J Li, H Lv, N Hua, N Wei, L He, L Wei, X Li, J Wang
- 523** Delayed surgical treatment of orbital trapdoor fracture in paediatric patients
Y Su, Q Shen, X Bi, M Lin, X Fan
- 527** Incidence and clinical characteristics of congenital nasolacrimal duct obstruction
S Sathiamoorthi, R D Frank, B G Mohnney
- 530** Clinical presentation and management of corneal fistula
D Singhal, P Sahay, P K Maharana, S P Amar, J S Titiyal, N Sharma
- 534** Is combined cataract surgery associated with acute postoperative endophthalmitis? A nationwide study from 2005 to 2014
C P Creuzot-Garcher, A S Mariet, E Benzenine, V Daien, J-F Korobelnik, A M Bron, C Quantin
- 539** Cataract surgery refractive outcomes: representative standards in a National Health Service setting
K Brogan, C J M Diaper, A P Rotchford
- 544** Femtosecond laser-assisted cataract surgery for the white cataract
S-P Chee, N S-W Chan, Y Yang, S-E Ti
- 551** Evaluation of keratoconus progression
M Shajari, G Steinwender, K Herrmann, K B Kubiak, I Pavlovic, E Plawetzki, I Schmack, T Kohmen
- 558** Biomechanical assessment of healthy and keratoconic corneas (with/without crosslinking) using dynamic ultrahigh-speed Scheimpflug technology and the relevance of the parameter (A1L–A2L)
T A Fuchsluger, S Brettl, G Geerling, W Kaisers, P Franko Zeitz
- 565** Three-year outcomes of small incision lenticule extraction (SMILE) and femtosecond laser-assisted laser in situ keratomileusis (FS-LASIK) for myopia and myopic astigmatism
T Han, Y Xu, X Han, L Zeng, J Shang, X Chen, X Zhou

Laboratory science

- 569** Dual-target, real-time PCR for the diagnosis of intraocular *Toxoplasma gondii* infections
 *C A Gomez, M K Sahoo, G Y Kahn, L Zhong, J G Montoya, B A Pinsky, T Doan*
- 573** Association of human antigen class I genes with cold medicine-related Stevens-Johnson syndrome with severe ocular complications in a Korean population
I Jun, J H Rim, M K Kim, K-C Yoon, C-K Joo, S Kinoshita, K Y Seo, M Ueta