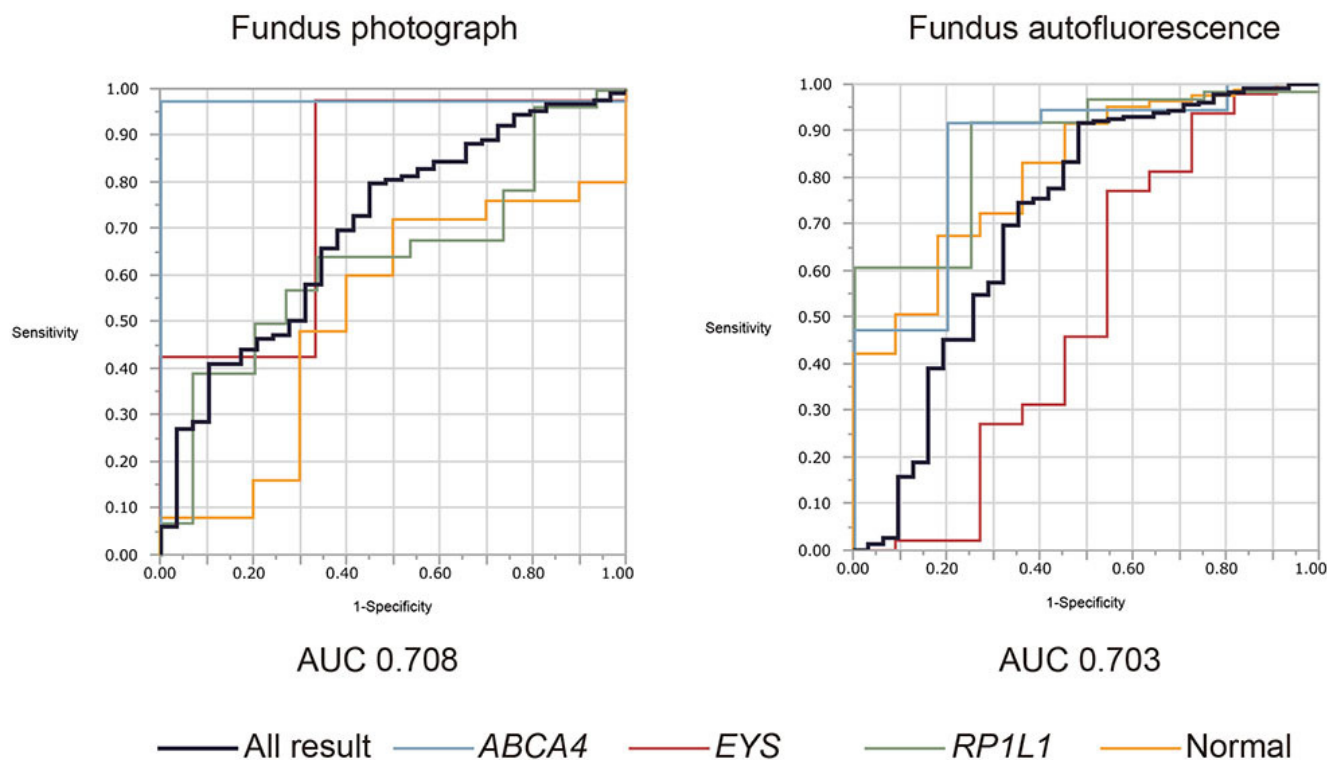


Supplemental Figure 3. Performance of the artificial intelligence (AI) diagnosis model



The receiver operating characteristic (ROC) curves of fundus photography and fundus autofluorescence imaging were generated. The area under the curve (AUC) for each result was 0.708 (95% confidential interval (CI): 0.589-0.829) for fundus photography and 0.703 (95% CI: 0.600-0.808) for fundus autofluorescence imaging. ROC for the four categories was also illustrated: *ABCA4* retinopathy, *EYS* retinopathy, *RP1L1* retinopathy, and normal.