

Supplementary Materials

Search strategies

i. MedLine(OViD) and Embase

- 1exp cornea/
- 2cornea*.tw.
- 31 or 2
- 4exp ophthalmic nerve/
- 5nerve*.tw.
- 6subbasal.tw.
- 7sub-basal.tw.
- 8mm?mm.tw.
- 9neuropath*.tw.
- 10plex*.tw.
- 114 or 5 or 6 or 7 or 8 or 9 or 10
- 12confocal.tw.
- 13microscop*.tw.
- 14"in?vivo".tw.
- 1512 or 13 or 14
- 163 and 11 and 15

ii. The Cochrane library

- 1cornea
- 2nerve*
- 3innervat*
- 4subbasal
- 5sub-basal
- 6mm?mm
- 7neuropath*
- 8plex*
- 9confocal
- 10microscop*
- 11"in?vivo"

- 12 2 or 3 or 4 or 5 or 6 or 7 or 8
- 13 9 or 10 or 11
- 14 1 and 12 and 13

Figure S1. PRISMA study flow diagram

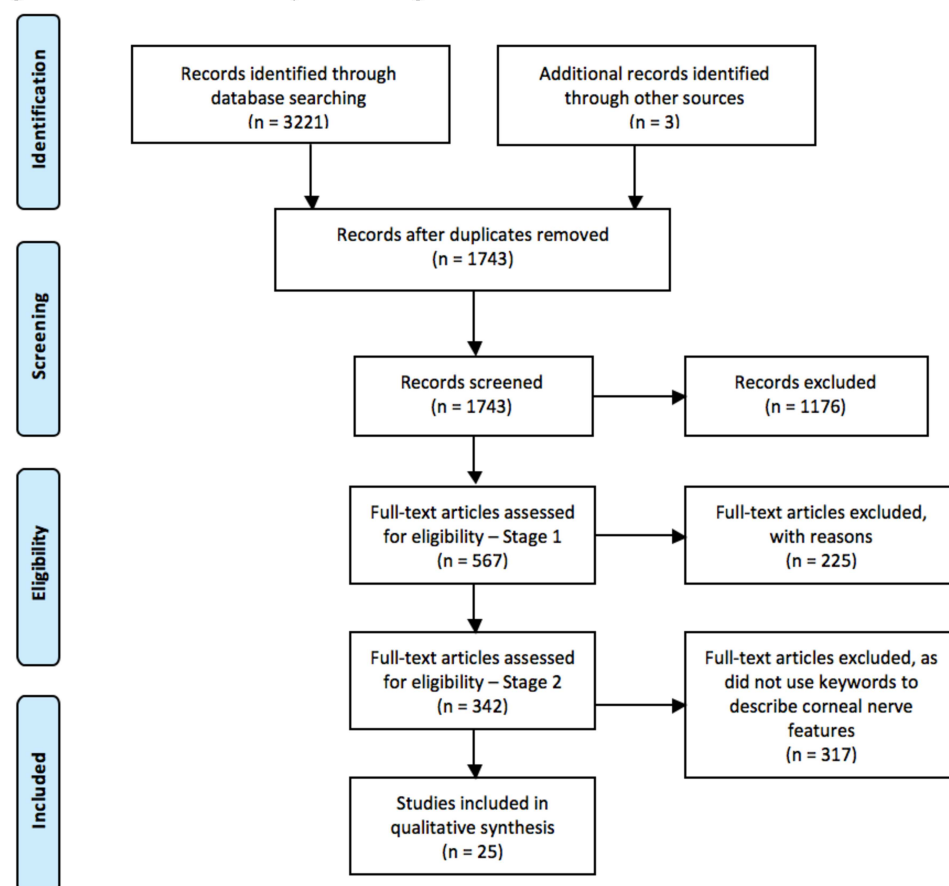


Table S1 – Characteristics of Included Studies

First author (year)	Research question type and study design	Journal	Participants/ Population	Corneal nerve plexus evaluated	Representative corneal IVCN image provided in paper?	Corneal region where nerve feature(s) noted	Number of corneal nerve IVCN images analyzed per participant; IVCN scan mode	Masking of IVCN method: image selection; image analysis	Keyword(s) present (Pathological or Physiological context)
Patel (2005)[13]	Methodological – retrospective cohort	Invest Ophthalmol Vis Sci	Normal eyes (n=3)	Sub-basal	Yes (Figure 5) of “probable sites of perforation of nerves through Bowman’s layer”	Infero-temporal mid-periphery	>373 for each participant; section scan mode	NA	<ul style="list-style-type: none"> • Perforation (Physiological)
Patel (2006)[22]	Methodological – retrospective cohort	Invest Ophthalmol Vis Sci	Eyes with keratoconus (n=4)	Sub-basal	Yes (Figure 4) of “apparent abrupt terminations of sub-basal nerve fiber bundles”	“Region of the cone”	NR; section scan mode	NA	<ul style="list-style-type: none"> • Abnormalities • Abrupt • Perforation (all Pathological)
Hu (2008)[25]	Etiology – case-control	Ophthalmol	Patients with atopic keratoconjunctivitis (n=21) and healthy controls (n=19)	Sub-basal and stromal	Yes (Figure 6) of “abrupt terminations” in sub-basal plexus	Central	“3 clearest images”; sequence scan mode	Selection – NR; Analysis - Yes	<ul style="list-style-type: none"> • Abnormalities • Abrupt • Bifurcation • Sprout (all Pathological)
Niederer (2008)[23]	Etiology – cross-sectional	Invest Ophthalmol Vis Sci	Patients with keratoconus (n=52) and age-matched controls (n=52)	Sub-basal and stromal	Yes (Figure 2), but not of nerve features of interest <i>per se</i>	Central	3 images; section scan mode	Selection – NR; Analysis - NR	<ul style="list-style-type: none"> • Abruptly (Pathological)
Zhao (2008)[26]	Etiology – cross-sectional	Klin Monatsbl Augenheilkd	Patients with various types of polyneuropathy (n=18) and age-matched controls (n=15)	Sub-basal and stromal	Yes (Figure 1) of “abundant sprouting of sub-basal nerve bundles”; (Figure 2B), large hyper-reflective, round features in the sub-basal nerve plexus are shown, but are referred to as "beads".	Central	3 to 5 images; “full layer corneal scans”	Selection – Yes; Analysis - Yes	<ul style="list-style-type: none"> • Sprouting (Pathological)

First author (year)	Research question type and study design	Journal	Participants/ Population	Corneal nerve plexus evaluated	Representative corneal IVCN image provided in paper?	Corneal region where nerve feature(s) noted	Number of corneal nerve IVCN images analyzed per participant; IVCN scan mode	Masking of IVCN method: image selection; image analysis	Keyword(s) present (Pathological or Physiological context)
Lagali (2009)[27]	Etiology – prospective cohort	Invest Ophthalmol Vis Sci	Patients who underwent PTK (n=13)	Sub-basal and stromal	Yes (Figure 3) of “presumed sprouting subbasal nerves” and “presumed sprouts... and mildly tortuous regenerated subbasal nerves”	Scanned “several millimeters of central cornea”	6 images; “cross-sectional images”; and additional confocal scans obtained across a 3- to 4-mm central region of each cornea”	NA	<ul style="list-style-type: none"> • Presumed sprout/ing (Pathological)
Vera (2009)[28]	Etiology – cross-sectional	Cornea	Patients with chronic symptoms of neuropathic corneal pain (n=25)	Sub-basal	Yes (Figure 2) of “nerve sprouting”	Central and peripheral	NR; NR	NA	<ul style="list-style-type: none"> • Sprouting (Pathological)
Rao (2010)[29]	Intervention – prospective cohort	Br J Ophthalmol	Eyes of patients with neurotrophic keratopathy (n=6)	Sub-basal	Yes (Figure 2) of “nerve stumps” and (Figure 4) of “nerve sprouts”	Central	4 randomly-selected images; “sequential” imaging	Selection – NR; Analysis - NR	<ul style="list-style-type: none"> • Sprout • Stump (all Pathological)
Al-Aqaba (2011)[31]	Etiology – case series	Am J Ophthalmol	Eyes (n=25) of bullous keratopathy (n=25) and eyes (n=6) of normal controls (n=6)	Sub-basal and stromal	Yes (Figure 1) of “bulbous terminations of sub-basal nerves”; ”; and (Figure 2) “localized nerve excrescences or thickenings ...suggestive of early sprouting)”	“Central and paracentral (approximately 7mm x 7mm)”	NR, although states “approximately 7x7mm of cornea”; “scanned through all layers”	Selection – NR; Analysis - NR	<ul style="list-style-type: none"> • Bifurcations (Physiological) • Bulb-like (Physiological) • Bulbous termination (Physiological) • Perforation (Physiological) • Sprout/ing (Pathological)

First author (year)	Research question type and study design	Journal	Participants/ Population	Corneal nerve plexus evaluated	Representative corneal IVCN image provided in paper?	Corneal region where nerve feature(s) noted	Number of corneal nerve IVCN images analyzed per participant; IVCN scan mode	Masking of IVCN method: image selection; image analysis	Keyword(s) present (Pathological or Physiological context)
									<ul style="list-style-type: none"> Thickening (Pathological)
Zheng (2011)[32]	Etiology – cross-sectional	Invest Ophthalmol Vis Sci	Patients with unilateral PXF (n=27) and normal controls (n=27)	Sub-basal	Yes (Figure 4) of “nerve sprouts”	Central	“3 best focussed images”; sequence scan mode	Selection – NR; Analysis - Yes	<ul style="list-style-type: none"> Sprout (Pathological)
Deng (2012)[33]	Intervention – prospective cohort	Neural Regen Res	Myopic patients (n=26) who underwent LASIK	Sub-basal and stromal	Yes (Figure 5) of “dilated head ends”	“From the margin of the ablation zone to the center at each four quadrants (superior, inferior, nasal and bitemporal)”	NR; section scan mode	Selection – NR; Analysis - NR	<ul style="list-style-type: none"> Ends Stump (Pathological)
Shaheen (2014)[3]	Review	Surv Ophthalmol	NA	Sub-basal and stromal	Yes (Figure 3), but not of nerve features of interest <i>per se</i>	NR	NA	NA	<ul style="list-style-type: none"> Abrupt (Pathological) Bifurcate/bifurcation (Physiological) Endings (Physiological) Microneuroma

First author (year)	Research question type and study design	Journal	Participants/ Population	Corneal nerve plexus evaluated	Representative corneal IVCN image provided in paper?	Corneal region where nerve feature(s) noted	Number of corneal nerve IVCN images analyzed per participant; IVCN scan mode	Masking of IVCN method: image selection; image analysis	Keyword(s) present (Pathological or Physiological context)
									(Pathological) • Sprout (Pathological)
Aggarwal (2015)[11]	Intervention – retrospective case-control	Ocular Surface	Patients with neuropathy-induced severe photoallodynia (n=16) and normal controls (n=16)	Sub-basal	Yes (Figures 1 and 3) of “neuromas”	Central	“3 images most-representative of the sub-basal nerve plexus”; sequence mode	Selection – Yes; Analysis - Yes	• Abrupt • Endings • Neuroma • Sprouting • Stump • Swelling (all Pathological)
Parissi (2016)[24]	Etiology – prospective cohort	JAMA Ophthalmol	Patients with keratoconus who underwent CXL (n=19) and age-matched healthy controls (n=19)	Sub-basal	Yes (Figure 5) of “abrupt orientation changes after penetration”	Central	3 images meeting quality criteria; sequence scan mode	Selection; NR; Analysis - Yes	• Abrupt • Penetration point (Pathological)
Cruzat (2017)[2]	Review	Ocular Surface	NA	Sub-basal and stromal	Yes (Figure 10) of “neuromas”	Central	NA	NA	• Abrupt • Endings • Microneuroma • Neuroma • Sprouting • Swelling (all Pathological)
Dieckmann (2017)[34]	Review	Ophthalmology	NA	Sub-basal	Yes (Figure 4) of “micro-neuromas”	NR	NA	NA	• Endings • Micro-neuromas • Swelling (all Pathological)

First author (year)	Research question type and study design	Journal	Participants/ Population	Corneal nerve plexus evaluated	Representative corneal IVCN image provided in paper?	Corneal region where nerve feature(s) noted	Number of corneal nerve IVCN images analyzed per participant; IVCN scan mode	Masking of IVCN method: image selection; image analysis	Keyword(s) present (Pathological or Physiological context)
Giannacarre (2017)[12]	Intervention – single-arm open label	Cornea	Patients with ocular surface disease (n=20)	Sub-basal	Yes (Figure 1) of “neuromas”	NR	“3 images most representative”; sequence scan mode	Selection; Yes; Analysis - Yes	<ul style="list-style-type: none"> • Abrupt • Endings • Neuroma • Stumps (all Pathological)
Goyal (2017)[5]	Review	Semin Ophthalmol	NA	Sub-basal and stromal	Yes (Figure 1), but not of nerve features of interest <i>per se</i>	NR	NA	NA	<ul style="list-style-type: none"> • Abnormalities • Bulbous • Neuroma • Sprouts/ing • Swelling (all Pathological)
Cavalcanti (2018)[35]	Etiology – case-control	Ocular Surface	Patients with unilateral HZO (n=24) and the contralateral normal eyes, and 24 normal volunteers as controls	Sub-basal	Yes (Figure 5) of “neuromas”	Central	“minimum of 3 representative images” from “at least 50 good quality images”; sequence scan mode	Selection; Yes; Analysis - Yes	<ul style="list-style-type: none"> • Microneuroma • Neuroma (all Pathological)
Fung (2018)[30]	Intervention – case series	Cornea	Patients with unilateral advanced NK who underwent corneal neurotization (n=2)	Sub-basal and stromal	Yes (Figure 2) of “nerve sprouts”	Central	NR; volume scan mode	Selection – NR; Analysis - NR	<ul style="list-style-type: none"> • Sprout • Stumps (all Pathological)
Morkin (2018)[7]	Intervention – retrospective case series	Ocular Surface	Patients with neuropathic corneal pain who received self-retained cryopreserved amniotic membrane (PROKERA) (n=9)	Sub-basal	Yes (Figure 2), but not of nerve features of interest <i>per se</i>	Central	“4 representative images”; “full-thickness coronal corneal scans”	Selection – Yes; Analysis - Yes	<ul style="list-style-type: none"> • Abrupt endings • Microneuroma (all Pathological)

First author (year)	Research question type and study design	Journal	Participants/ Population	Corneal nerve plexus evaluated	Representative corneal IVCN image provided in paper?	Corneal region where nerve feature(s) noted	Number of corneal nerve IVCN images analyzed per participant; IVCN scan mode	Masking of IVCN method: image selection; image analysis	Keyword(s) present (Pathological or Physiological context)
Aggarwal (2019)[4]	Intervention – retrospective case-control	Ocular Surface	Patients with severe neuropathic corneal pain (n=16) and controls (n=12)	Sub-basal	Yes (Figures 1 and 3) of “micro-neuromas”	Central	“3 images most representative of the subbasal nerve plexus” from 50-100 acquired images; sequence scan mode	Selection – Yes; Analysis - Yes	<ul style="list-style-type: none"> • Micro-neuroma • Stump (all Pathological)
Al-Aqaba (2019)[21]	Review	Prog Ret Eye Res	NA	Sub-basal and stromal	Yes (Figures 12 and 24) of “bulb-like termination of sub-basal nerves”	NR	NA	NA	<ul style="list-style-type: none"> • Bifurcations (Physiological) • Bulb-like termination (Physiological) • Endings (Physiological) • Microneuroma (Pathological) • Perforation (Physiological) • Sprouting (Pathological) • Swelling (Physiological) • Thickened (Pathological)
Ross (2019)[8]	Etiology – cross-sectional	Br J Ophthalmol	Patients who had continuous severe ocular pain for at least 1 year, with minimal or no	Sub-basal and stromal	Yes (Figure 4) of “microneuromas” and “nerve sprouts” in the stroma, and (Figure 5) of “fusiform neuroma”	Central and paracentral	NR; “scanned through all corneal layers”	NA	<ul style="list-style-type: none"> • Abnormalities • Hyper-reflective • Microneuromas • Neuromas

First author (year)	Research question type and study design	Journal	Participants/ Population	Corneal nerve plexus evaluated	Representative corneal IVCN image provided in paper?	Corneal region where nerve feature(s) noted	Number of corneal nerve IVCN images analyzed per participant; IVCN scan mode	Masking of IVCN method: image selection; image analysis	Keyword(s) present (Pathological or Physiological context)
			ocular surface signs and non-response to traditional treatment (n=14 patients, 27 eyes), and 14 eyes from 7 healthy controls						<ul style="list-style-type: none"> • Stump • Swelling (all Pathological)
Shen (2019)[36]	Etiology – case-control	J Pain Research	Patients with episodic migraine (n=10) and age- and sex-matched controls (n=10)	Sub-basal	Yes (Figure 1) of “nerve sprouts”	Central	“3 high quality images”; “scanned through all the corneal layers”	Selection - NR; Analysis - Yes	<ul style="list-style-type: none"> • Injury • Sprouts (all Pathological)

Abbreviations: Am, American; Br, British; CXL, corneal collagen cross-linking; HZO, herpes zoster ophthalmicus; Invest Ophthalmol Vis Sci, Investigative Ophthalmology and Visual Science; IVCN, in vivo confocal microscopy; J, journal; JAMA, Journal of the American Medical Association; LASIK, laser in situ keratomileusis; MDF, map-dot fingerprint; NA, not applicable; NK, neurotrophic keratopathy; NR, not reported; Ophthalmol, ophthalmology; Prog Ret Eye Res, Progress in Retinal and Eye Research; PTK, phototherapeutic keratectomy; PXF, pseudoexfoliation syndrome; Regen, Regenerative; Res, Research; Semin, Seminar; Surv, Survey