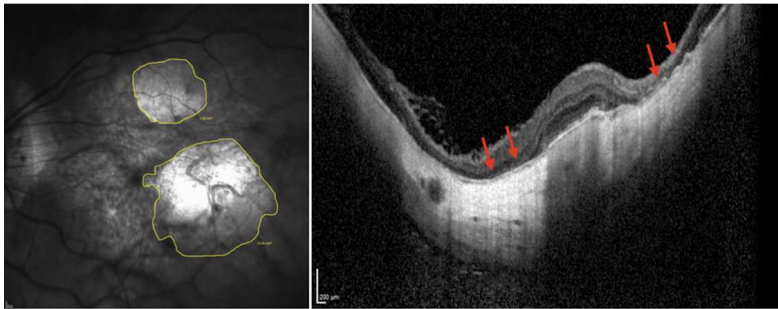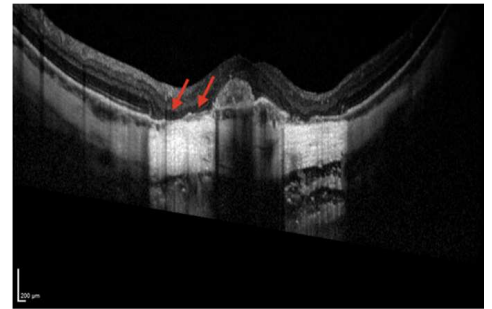
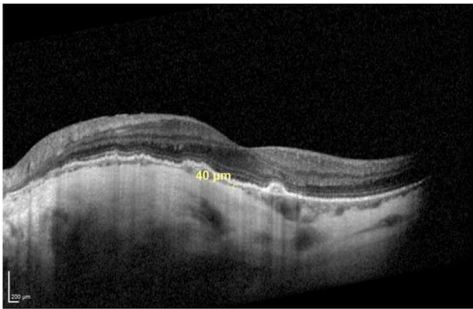


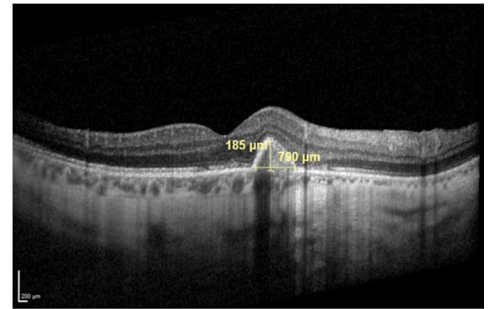
Patchy atrophy



CNV-related macular atrophy



Subfoveal choroidal thickness



CNV size