

Increased incidence of endophthalmitis after vitrectomy relative to face mask wearing during COVID-19 pandemic

Taiji Sakamoto ^{1,2}, Hiroto Terasaki,^{1,2} Toshifumi Yamashita,^{1,2} Hideki Shiihara,^{1,2} Ryoh Funatsu,^{1,2} Akinori Uemura,³ The Japanese Retina and Vitreous Society

► Additional supplemental material is published online only. To view, please visit the journal online (<http://dx.doi.org/10.1136/bjophthalmol-2022-321357>).

¹Department of Ophthalmology, Kagoshima University Graduate School of Medical and Dental Sciences, Kagoshima, Japan

²Japan-Clinical Retina Study Group (J-CREST), Kagoshima, Japan

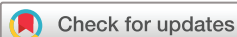³Department of Ophthalmology, Kagoshima City Hospital, Kagoshima, Japan

Correspondence to

Dr Taiji Sakamoto, Ophthalmology, Kagoshima University, Kagoshima, Kagoshima, Japan; tsakamot@m3.kufm.kagoshima-u.ac.jp

TS and HT contributed equally.

Received 3 March 2022
Accepted 22 May 2022
Published Online First
21 June 2022



© Author(s) (or their employer(s)) 2023. No commercial re-use. See rights and permissions. Published by BMJ.

To cite: Sakamoto T, Terasaki H, Yamashita T, et al. *Br J Ophthalmol* 2023;**107**:1472–1477.

ABSTRACT

Background/aims To determine the incidence and causative pathogens of endophthalmitis after vitrectomy during strict face mask wearing in the COVID-19 period.

Methods This was a retrospective multicentre study including 31 ophthalmological institutions of the Japanese Retina and Vitreous Society or Japan-Clinical Retina Study group. Patients who had undergone vitrectomy during 2019, the pre-COVID-19 period, and from July 2020 to June 2021, the COVID-mask period, were studied. The results of cataract surgery were used as a control. The total number of vitrectomies and the total number of postoperative endophthalmitis were determined. Then, the differences in the incidence of postoperative endophthalmitis between the pre-COVID-19 period and the COVID-mask period, and the type of pathogens causing the endophthalmitis were studied.

Results The incidence of postvitrectomy endophthalmitis was significantly lower in the pre-COVID-19 period with 16 568 surgeries and 18 endophthalmitis cases (0.11%) than in the COVID-mask period of 14 929 surgeries and 31 endophthalmitis cases (0.21%; $p=0.031$, $OR=1.913$, 95% CI 1.078 to 3.394). In the pre-COVID-19 period, 4 of the 18 eyes were culture positive, and all were of the *Staphylococcus* family. In the COVID-mask period, 9 of the 31 eyes were culture positive, and 4 cases were related to oral commensals including *Streptococcus* spp, which are reportedly very rare in endophthalmitis after vitrectomy.

Conclusions It is necessary for physicians to be aware of the higher incidence of postvitrectomy endophthalmitis during the COVID-mask period, and to treat their patients appropriately.

INTRODUCTION

COVID-19 has spread worldwide, and it has been shown decisively that wearing a face mask reduces the rate of infections and inhibits the spread of COVID-19 viruses.^{1,2} However, it has been pointed out that when patients wear masks, there can be adverse effects on the eyes of the wearer.^{3,4} It has been proven that when masks are worn improperly, the masks themselves can cause contamination and spread of bacteria around the eyes of the mask wearer.^{4,5} Thus, it has been reported that masks can cause infectious keratitis, which is probably caused by oral flora bacteria contained in the air passing from inside the mask to the eye.^{4,6} Several studies have reported an increase in the incidence

of intraocular inflammation after intravitreal anti-vascular endothelial growth factor (VEGF) injections in patients wearing face masks.^{3,6} It is also known that the wearing of a mask by the physician doing intraocular injections can also reduce the incidence of the postinjection endophthalmitis.^{7,8} This suggested that oral bacteria can cause endophthalmitis. The constant circulation of air around the wearer's eye by a mask can enhance the chance of infections leading to endophthalmitis.

The risk of endophthalmitis is probably greatest at the time of intraocular surgery, and it is also present in the early postoperative period. The wearing of masks by patients at that time may increase the incidence of postoperative endophthalmitis.

The present COVID-19 pandemic is the first time that many people worldwide have been wearing masks for a long duration. There is a strong social obligation to wear masks, especially in East Asia including Japan, and many citizens wear masks accordingly.⁹ However, an accurate assessment of mask wear on endophthalmitis after vitrectomy has not been made.

To obtain information on the current status of retinal diseases in Japan, the Japanese Retina and Vitreous Society (JRVS) has created a registry system; for example, the JRVS reported the actual situation of retinal detachment.^{10,11} We obtained information that the incidence of endophthalmitis after vitrectomy may be related to mask wearing. However, a systematic study of a large number of patients who had undergone vitrectomy during the pre-COVID-19 and the COVID-19 period has not been published.

Thus, the purpose of this study was to determine whether mask wearing affected the incidence of endophthalmitis that develop especially after vitrectomy. To accomplish this, we compared the incidence of endophthalmitis before and after the beginning of mask wearing for COVID-19. The incidence of endophthalmitis during the pre-COVID-19 period was compared with that during the COVID-19 period.

METHODS

Ethics statement

This was a multicentre, retrospective study approved by the Ethics Committee of Kagoshima University Hospital. Members of the Japan Clinical Retina Study group, a private retina research group, and a board member of the JRVS, conducted the

survey. The names of the participating institutions are listed in the Acknowledgments.

Survey method

Data for the number of cataract surgeries, vitreous surgeries without cataract surgery and simultaneous cataract and vitreous surgery were collected. In addition, the total number of postoperative endophthalmitis between January 2019 and June 2021 was analysed. The surgical decisions were made by specialists who met the criteria of the Japanese Ophthalmological Society (JOS), and the diagnosis of postoperative endophthalmitis was made by each surgeon or specialist who were board certified by the JOS. In general, endophthalmitis occurred within 42 days after surgery was diagnosed as postoperative endophthalmitis.¹² For cases of postoperative endophthalmitis, baseline information of age, sex, primary disease, pathogens and preoperative and postoperative visual acuity were examined.

Comparison of incidence before and after mandated mask wearing

COVID-19 was first reported in Japan in February 2020, but it did not spread throughout the country until the summer of 2020. At that time, there was a shortage of commercial surgical masks, and a large percentage of people did not wear masks or used homemade masks. Thus, the COVID-mask period was defined as the 1-year period from July 2020 to June 2021 when surgical masks were sufficiently available.¹³ We defined the year from January 2019 to December 2019, before the first COVID-19 case was reported in Japan, as the period when people did not wear masks routinely as the pre-COVID-19 period. The rate of endophthalmitis was calculated from the number of surgical operations and the total number of postoperative endophthalmitis during these two periods. Pearson's χ^2 test was used to determine the significance of the differences.

Investigations of patient information and pathogens of postoperative endophthalmitis during pre-COVID-19 and the COVID-19-mask periods

We examined the baseline age, sex, primary disease, preoperative visual acuity, pathogens in the intraocular fluid and postoperative visual acuity. The identification of the oral commensals was based on the reports of Aas *et al* and Komiyama *et al*.^{14 15}

RESULTS

Number of surgeries and incidence of postcataract surgery endophthalmitis

The number of cataract surgeries and incidence of postoperative endophthalmitis during the pre-COVID-19 and the COVID-19-mask periods are shown in [table 1](#) and [figure 1](#). There were 32 839 cataract surgeries performed in the pre-COVID-19 period, and 12 (0.037%) of these cases developed postoperative endophthalmitis. In the COVID-19-mask period, 28 061

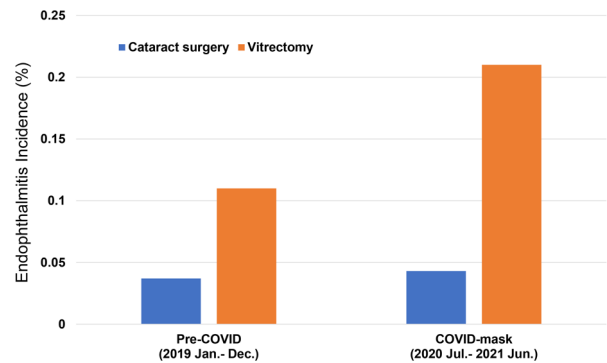


Figure 1 Endophthalmitis incidence after cataract surgery and vitrectomy in pre-COVID-19 and COVID-19-mask period. The incidence of postcataract surgery endophthalmitis did not change between the pre-COVID-19 period (0.037%) and the COVID-19-mask period (0.043%), but postvitrectomy endophthalmitis increased more in the COVID-mask period (0.21%) than in the pre-COVID-19 period (0.11%).

cataract surgeries were performed, and 12 (0.043%) cases of postoperative endophthalmitis were found. The difference in the incidence of endophthalmitis between the two periods was not significant ($p=0.838$).

Incidence of postvitrectomy endophthalmitis

The incidences of endophthalmitis are listed in [table 1](#) and [figure 1](#). The vitrectomies are divided into vitrectomy alone and simultaneous cataract surgery and vitrectomy. In the pre-COVID-19 period, there were 16 568 of both types of surgeries and 18 (0.11%) cases of postoperative endophthalmitis, and in the COVID-19-mask period, there were 14 929 surgeries and 31 (0.21%) cases of postoperative endophthalmitis. The higher incidence during the COVID-19-mask period was significant ($p=0.031$; OR=1.913, 95% CI 1.078 to 3.394). In the pre-COVID-19 period, there were 7864 cases of vitrectomy alone and 8704 cases of combined vitrectomy and cataract surgery. There were 5 (0.064%) cases of endophthalmitis after vitrectomy alone and 13 (0.15%) cases of postoperative endophthalmitis after combined vitrectomy and cataract surgery. In the COVID-mask period, 7233 cases of vitrectomy alone and 7696 cases of combined vitrectomy and cataract surgery were performed. There were 14 (0.19%) cases of postoperative endophthalmitis after vitrectomy alone and 17 (0.21%) cases of postoperative endophthalmitis after combined vitrectomy and cataract surgery.

The incidence of endophthalmitis after vitrectomy alone was significantly higher in the COVID-19-mask period than in the pre-COVID-19 period ($p=0.036$; OR=3.048, 95% CI 1.142 to 8.136), while that after combined vitrectomy and cataract surgeries was not significantly different between the two period ($p=0.360$; OR=1.480, 95% CI 0.729 to 3.004).

Table 1 Incidence of endophthalmitis in pre-COVID-19 period and COVID-19-mask period

Surgery related to endophthalmitis	Pre-COVID-19 period	COVID-19-mask period	OR (95% CI)	P value
	Number of endophthalmitis case/total cases number (%)	Number of endophthalmitis case/total cases number (%)		
Cataract surgery	12/32 839 (0.037)	12/28 061 (0.043)	1.170 (0.536 to 2.554)	0.838
Vitrectomy, total	18/16 568 (0.11)	31/14 929 (0.21)	1.913 (1.078 to 3.394)	0.031
Vitrectomy alone	5/7864 (0.064)	14/7233 (0.19)	3.048 (1.142 to 8.136)	0.036
Phacovitrectomy	13/8704 (0.15)	17/7696 (0.21)	1.480 (0.729 to 3.004)	0.360

Table 2 Culture positive cases of postvitrectomy endophthalmitis in pre-COVID-19 period

Patient	Age range, sex	Primary diseases	Combined cataract surgery	Vitrectomy gauge	Culture results	Preoperative BCVA	Presenting BCVA	Final BCVA
1	70s, M	DR	No	25	<i>Staphylococcus aureus</i>	20/225	NLP	NLP
2	80s, M	ERM	Yes	27	<i>Staphylococcus auricularis</i>	20/125	NA	NLP
3	60s, M	Lens luxation	Yes	25	<i>Staphylococcus aureus</i>	20/33	20/40	20/16
4	70s, F	ERM	Yes	25	<i>Staphylococcus aureus</i>	20/33	NA	20/25

BCVA, best-corrected visual acuity; DR, diabetic retinopathy; ERM, epiretinal membrane; F, female; M, male; NA, not applicable; NLP, non-light perception.

Identifications of pathogens of postvitrectomy endophthalmitis

The cases of postvitrectomy endophthalmitis in which pathogens were detected in the intraocular fluid during the pre-COVID-19 and COVID-19-mask periods are shown in tables 2 and 3. In the pre-COVID-19 period, 4 eyes were culture positive, and all were of the *Staphylococcus* family. In the COVID-mask period, *Staphylococcus* spp. were observed in 5 cases and 2 were *S. aureus*, 1 was *S. epidermidis*, 1 was *S. caprae* and 1 was *S. lugdunensis*. There were 2 cases of *Streptococcus* spp.; 1 case of *Streptococcus mitis* and 1 of *S. salivarius*. Indigenous oral bacteria, based on the reports of Aas *et al* or Komiyama *et al*,^{14 15} were not found in the pre-COVID-19 period, but 3 eyes were found to have oral bacteria during the COVID-19-mask period. The baseline best-corrected visual acuity (BCVA), final BCVA and the change of the BCVA between the final and baseline BCVA were not significantly different in the pre-COVID-19 from that during the COVID-mask period (online supplemental figure S1). There was a tendency for more endophthalmitis cases in the COVID-mask period that had undergone 25G vitrectomy and more vitrectomy procedures alone, but it did not reach statistical significance (online supplemental figure S2).

DISCUSSION

The first case of COVID-19 patient was reported in Japan in January 2020, and the number of patients has increased slowly. Initially, people did not wear masks as strictly as they do now.¹³ Later, people were encouraged by the government to wear masks, but due to the shortage of masks, they were not worn in large numbers until around June 2020. After that, with the increase of COVID-19 cases, strict mask wearing was strongly encouraged by the society, and the people followed it strictly. Therefore, the year 2019 was applied as the pre-COVID-19 period for masks.

The reason why we chose an observation period of 1 year is that the occurrence of postoperative endophthalmitis is seasonal, so it is necessary to study at least one complete year.¹⁶

The results showed that the incidence of endophthalmitis increased significantly after vitrectomy in the COVID-mask period. There are several possible explanations for the increase in the incidence of postvitrectomy endophthalmitis. For example, Garg *et al* compared the pathogens spectrum of endophthalmitis after intravitreal injections (IVI) and vitrectomy, and they reported that 56.3% of the post-IVI endophthalmitis was caused by *Streptococcus* spp, and none of the postvitrectomy endophthalmitis was caused by oral bacteria.¹⁷ In a meta-analysis by McCannel in 2011, streptococcus-related endophthalmitis was found in 30.8% of the cases after IVI of anti-VEGF drug in the culture-positive cases. However, no pathogen relative to oral bacteria was found in the postvitrectomy endophthalmitis.¹⁸ In the literature on the causative organisms of postvitrectomy endophthalmitis reported in 2011 or later,^{17 19–28} 5.95% (5/84 cases) of the culture-positive cases were indigenous oral bacteria in the postvitrectomy endophthalmitis (table 4). Thus, the incidence of endophthalmitis caused by oral bacteria, which is usually rare in postvitrectomy endophthalmitis, clearly increased during the COVID-mask period as was found in this study. These results suggest that the spectrum of causative organisms after IVI of the anti-VEGF drug was somewhat similar to that present after vitrectomy in the COVID-mask period. In addition, inappropriate mask use by patients has been reported to cause bacterial contamination of the periocular area.^{4–6} Taken together, the inappropriate mask wearing could have led to the exposure of an eye to oral bacteria before and after vitrectomy in the COVID-mask period.

Another unexpected finding was that *S. lugdunensis* was the causative pathogen only in the COVID-mask period. *S.*

Table 3 Culture positive cases of postvitrectomy endophthalmitis in COVID-mask period

Patient	Age range, sex	Primary diseases	Combined cataract surgery	Vitrectomy gauge	Culture results	Preoperative BCVA	Presenting BCVA	Final BCVA
1	80s, M	Lens luxation	Yes	27	<i>Proteus mirabilis</i>	20/1000	LP	NA
2	50s, F	Vitreous opacity	No	25	<i>Staphylococcus aureus</i>	20/70	HM	20/50
3	50s, F	RRD	Yes	27	<i>Enterococcus faecalis</i>	20/16	NA	20/16
4	50s, M	RRD	No	25	<i>Staphylococcus aureus</i>	20/500	NA	20/300
5	70s, F	ERM	No	25	<i>Staphylococcus caprae</i>	20/25	NA	20/33
6	70s, F	ERM	Yes	25	<i>Staphylococcus epidermidis</i>	20/40	20/40	20/50
7	60s, F	ERM	Yes	25	<i>Staphylococcus lugdunensis</i>	20/30	HM	20/20
8	60s, M	IOL luxation	Yes	25	<i>Streptococcus salivarius</i>	20/16	HM	20/70
9	60s, F	ERM	No	27	<i>Streptococcus mitis</i>	20/25	NA	20/100

BCVA, corrected visual acuity; ERM, epiretinal membrane; F, female; HM, hand motion; IOL, intraocular lens; LP, light perception; M, male; NA, not applicable; RRD, rhegmatogenous retinal detachment.

Table 4 Reports of postvitrectomy endophthalmitis in the past 10 years

Authors (Ref.)	Year	N of oral bacteria-related endophthalmitis cases	N of culture positive cases	Total N of postvitrectomy endophthalmitis cases	N of total vitrectomy
Wu <i>et al</i> ¹⁹	2011	0	5	8	35 427
Scott <i>et al</i> ²⁰	2011	0	2	3	8554
Chiang <i>et al</i> ²¹	2011	0	0	2	2336
Shi <i>et al</i> ²²	2013	1	9	14	26 793
Park <i>et al</i> ²³	2014	1	17	28	Not described
Garg <i>et al</i> ¹⁷	2016	0	8	19	14 163
Czajka <i>et al</i> ²⁴	2016	1	16	24	16 966
Dave <i>et al</i> ²⁵	2016	1	12	20	38 951
Weiss <i>et al</i> ²⁶	2018	0	6	16	18 886
LaGrow <i>et al</i> ²⁷	2021	0	4	5	4263
Silpa-Archa <i>et al</i> ²⁸	2021	1	5	13	12 989

Above reports were published in 2011 or later.

lugdunensis has been reported to be rare in cases of endophthalmitis after cataract surgery²⁹ and after vitrectomy.²⁷ *S. lugdunensis* has been implicated as the causative pathogens of skin and soft tissue infections. Interestingly, a study that examined the bacterial species on the head before and after hair washing reported that *S. lugdunensis* was still predominant on the backside of the auricle even after washing.³⁰ Normally, the back of the auricle is rarely touched except when putting on a mask. As a result, there is a possibility that it could get on the patient's hands and spread to the periocular area. This raises the suspicion that it is related to the mask wearing. Together, four of the nine cases (44%) were caused by oral bacteria suggesting that there may be a certain degree of influence of daily mask wearing on the increase in endophthalmitis in this study.

It is well known that the frequency of IVI-related endophthalmitis can be reduced by physicians wearing masks and adhering to a 'no talking policy'. These procedures can prevent indigenous oral bacteria from falling into the patients' eyes.^{7,8} On the other hand, inappropriate mask use by patients has been reported to cause bacterial contamination of the periocular area.⁴⁻⁶ This inappropriate wear could have led to exposure to oral bacteria during the period of susceptibility before and after vitrectomy. In Japan, during the COVID-mask period, patients were instructed to wear a mask continuously immediately after surgery, but this may have led to inappropriate mask wearing. This could then lead to exposure to oral bacteria during the period after vitrectomy when the patient is susceptible to infectious endophthalmitis.

The reason for the increase only after vitrectomy and no change after cataract surgery was not definitively determined. Large-scale reports of the incidence of postoperative endophthalmitis after cataract surgery in Japan indicate that the incidence ranges from 0.025% to 0.052%.^{31,32} No report on the incidence of endophthalmitis after vitrectomy in Japan has been reported on a larger scale than this study, but the incidence ranged from 0% to 0.8%.³³⁻³⁷ Without limiting the findings to those from Japan, the incidence of postoperative endophthalmitis after 25G vitrectomy was 0.11% in the meta-analysis reported by Chen *et al*.³⁸ Thus, the incidence of pre-COVID-19 cataract and vitrectomy endophthalmitis in this study is no different from that reported in the past. In animal models, it has been found that endophthalmitis occurs with fewer bacteria in the vitreous cavity than when administered into the anterior chamber, that is, the vitreous cavity has a weaker immune mechanism against bacteria.³⁹ It is conceivable that when the eye becomes more exposed to oral

bacteria due to the inappropriate wearing of masks, there may be an increase in infections after vitrectomy, when the immune mechanism is more vulnerable.

Prophylactic intracameral antibiotics application during cataract surgery, but not in vitrectomy, is common in Europe and USA. However, this is not the case in Japan because the use of intracameral antibiotics is not covered by health insurance. Thus, this effect is unlikely at least in the current study.

We did not investigate the incidence of endophthalmitis after IVI. In a large survey in the USA, the incidence of post-IVI endophthalmitis was not increased even when patients wore masks.⁴⁰ Because the wound after vitreous injection is smaller than that after vitrectomy, the degree of mask wearing may be less likely to cause endophthalmitis after IVI than after vitrectomy. Vitrectomy alone had an increased incidence of endophthalmitis during the COVID-mask period. Phacovitrectomy also had an increased incidence while it was not statistically significant. It is possible that the number of phacovitrectomy cases was not sufficient to reach significance.

There are several possible reasons why changes in the incidences have not been reported in other countries. In the USA and Europe, recommendations have been made to discontinue ophthalmic surgery during the COVID-19 period.^{41,42} In the USA, there was a period when retinal surgeries decreased by more than 80%.⁴¹ On the other hand, COVID-19 in Japan has not spread as severely as in Europe and the USA, and there has not been a massive lockdown. Ophthalmic surgeries were performed under almost normal conditions throughout the period. The nature of the surgery, the subject of the surgery and the indications for surgery at each institution were reported to be unchanged during this study period (personal communication from the director of each institution). In this study, the number of surgeries per year during the COVID-mask period was only 14.5% lower for cataracts and 9.9% lower for vitrectomy. Furthermore, most patients wore masks for a long time, sometimes even at home because there is no strong antimask movement in Japan.¹³ Therefore, it is possible that the postvitrectomy endophthalmitis did not become evident in these countries due to the lower number of vitrectomies and/or sociocultural differences in which masks are less strictly worn.

There are limitations in this study. There was a certain degree of bias because of its retrospective nature. Another limitation was the lack of uniformity in the selection of the type of surgery and the diagnosis of endophthalmitis which were left to the judgement of the surgeon and the institution. This is a point that

cannot be avoided in a multicenter study. This survey may not reflect the entire situation in Japan because it was not a comprehensive survey such as a nationwide survey. On the other hand, the participating facilities were leading ophthalmological institutions that meet the standards of the JOS and have the advantage of providing at least the level of diagnosis and treatment recommended by the JOS. Because the pathogens in most cases could not be identified, it is necessary to be cautious in concluding on the cause of the endophthalmitis based only on the culture-positive cases. The COVID-19 pandemic is the first of its kind in world history, and there are many unknowns. The possible causes of intraocular inflammation are added as follows. First, burnout of the medical personnel may be one factor. As securing a complication-free outcome of a delicate and sophisticated type of surgery such as vitrectomy is a result of complex and coordinated team efforts, the team members involved in patient care need to be at the peak of their work performance. However, the COVID-19 pandemic resulted in a considerably higher than usual level of stress and burnout on healthcare workers worldwide.⁴³ The study in Taiwan showed that endophthalmitis was associated with the presence of several comorbidities.⁴⁴ As the COVID-19 pandemic in general reduced access to healthcare, it is theoretically possible that the comorbidities may have been present or treated less effectively than usual in some of the patients with endophthalmitis. Third, increased levels of stress and anxiety in patients. Although it may be difficult to provide direct evidence specifically for endophthalmitis, the field of psychoneuroimmunology is a well-established one and it has been shown that psychological stress seems able to alter the susceptibility of animals and man to infectious pathologies.⁴⁵ Although we cannot exclude the influence of these factors, we believe that the increase of oral flora as a causative agent suggests a relationship with mask use.

In addition, the culture positive rate on endophthalmitis after vitrectomy was low in this study at 22% (4/18) for the pre-COVID-19 period and 29.3% (9/31) for the COVID-mask period. A nationwide survey of postcataract surgery endophthalmitis in Japan also showed a low infection rate of 7.7% (1/13) of the endophthalmitis cases.³¹ In Japan, when infective endophthalmitis is suspected, a large dose of broad-spectrum antibiotics is always administered in the very early phase. Thus, most of the cases received a large amount of antibiotics in eyes before the patients were sent to the treatment facilities. We suspected that this was likely the reason for the low positivity rate in bacterial cultures. It is necessary to discuss this issue at the JRVS.

In conclusion, the significant increase of endophthalmitis after vitrectomy during the COVID-mask period indicates that clinicians need to follow these patients more vigilantly and instruct patients on the proper method to wear masks. Although COVID-19 vaccines are available worldwide and mask wearing has not been mandated in some areas or countries, there is still a need for mask wearing. With the emergence of the omicron strain of COVID-19 and the expectations of new mutants of COVID-19, the need to wear masks will most likely continue for several years. Because the need for vitreoretinal surgery will continue regardless of the presence of COVID-19, it is important for clinicians to know the present results and treat their patients accordingly.

Correction notice This article has been corrected since it was first published. There was an error in the first column of table 1 and this has now been updated.

Acknowledgements The authors thank Professor Emeritus Duco Hamasaki of Bascom Palmer Eye Institute, University of Miami, FL, for providing critical discussions and suggestions to this study and the editing of the final manuscript.

Collaborators Members of the Japan Clinical Retina Study group (J-CREST), a private retina research group and a board member of the JRVS: Department of Ophthalmology, Diabetes Center, Tokyo Women's Medical University: Shigehiko Kitano, Kunihiro Ishikawa; Department of Ophthalmology, Faculty of Medicine, Miyazaki University: Yasuhiro Ikeda, Naohiro Sugita, Go Mawatari; Department of Ophthalmology, Faculty of Medicine, Saga University: Hiroshi Enaida, Soichiro Yamamoto, Yoshiyuki Kobayashi; Department of Ophthalmology, Kagoshima University Graduate School of Medical and Dental Sciences: Taiji Sakamoto, Toshifumi Yamashita, Hiroto Terasaki, Ryoh Funatsu, Hideki Shiihara; Department of Ophthalmology, Graduate School of Medical Sciences, Kyushu University: Koh-Hei Sonoda, Atsunobu Takeda, Keijiro Ishikawa, Shoji Notomi, Muneo Yamaguchi, Shunji Nakatake; Department of Ophthalmology, Graduate School of Medicine, University of the Ryukyus: Hideki Koizumi, Yukihide Yamauchi, Nobuhiro Terao, Naoya Imanaga, Shota Sawaguchi; Department of Ophthalmology, Faculty of Medicine and Graduate School of Medicine, Hokkaido University: Susumu Ishida, Ryo Ando, Riki Kijima; Department of Ophthalmology, Hyogo College of Medicine: Fumi Gomi, Takashi Araki; Department of Ophthalmology, Institute of Biomedical Sciences, Tokushima University Graduate School: Yoshinori Mitamura; Department of Ophthalmology, Izuro Imamura hospital: Norihito Doi, Takashi Mizushima, Yuko Fujiwara, Shoki Miyake, Yuka Mizushima, Kihoko Kato; Department of Ophthalmology, Kagawa University Faculty of Medicine: Kiyoshi Suzuma, Yuki Nakano, Rie Osaka; Department of Ophthalmology, Kagoshima City Hospital: Akinori Uemura, Keita Yamakiri; Department of Ophthalmology, Kurume University School of Medicine: Shigeo Yoshida, Nobuhiro Kato, Kei Furushima; Department of Ophthalmology, Mie University Graduate School of Medicine: Mineo Kondo, Kumiko Kato; Department of Ophthalmology, Nara Medical University: Nahoko Ogata, Tetsuo Ueda, Yuutarō Mizusawa, Hironobu Jimura; Department of Ophthalmology, National Defense Medical College: Masaru Takeuchi, Takayuki Kanda, Tomohito Sato; Department of Ophthalmology, Sakai Hospital Kinki University Faculty of Medicine; Shunji Kusaka, Chiharu Iwahashi, Sayaka Yamao; Department of Ophthalmology, Sakura Medical Center, Toho University; Takatoshi Maeno, Hidetaka Masahara; Department of Ophthalmology, Shinshu University School of Medicine: Toshinori Murata, Takao Hirano; Department of Ophthalmology, Shiga University of Medical Science: Masahito Ohji, Tomoko Sawada; Department of Ophthalmology, St Luke's International University Yoko Ozawa, Norihiro Nagai; Department of Ophthalmology, St. Marianna University School of Medicine; Hitoshi Takagi, Tatsuya Jujo; Department of Ophthalmology, Tokyo Medical University Hachioji Medical Center: Masahiko Shimura, Masaki Asakage, Kanako Yasuda; Department of Ophthalmology, Tokyo Women's Medical University: Tomohiro Iida, Ichiro Maruko, Taiji Hasegawa, Atsushi Ohnami, Yukari Kodama; Department of Ophthalmology, Tsukazaki Hospital: Hitoshi Tabuchi, Daisuke Nagasato; Department of Ophthalmology, Yokohama City University Medical Center: Kazuaki Kadonosono, Maiko Maruyama-Inoue, Shin Tanaka; Department of Ophthalmology and Visual Sciences, Kyoto University Graduate School of Medicine: Akitaka Tsujikawa, Kenji Suda; Department of Ophthalmology & Visual Science, Nagoya City University Graduate School of Medical Sciences: Tsutomu Yasukawa, Aki Kato; Division of Ophthalmology, Department of Surgery, Kobe University Graduate School of Medicine; Sentaro Kusuhara: Kobe Eye Center; Yasuo Kurimoto, Yasuhiko Hiram, Masayo Takahashi; Kyorin Eye Center, Kyorin University School of Medicine: Makoto Inoue, Akito Hirakata, Takashi Koto, Kazunari Hirota, Tomoka Ishida, Yoshimasa Ando, Masaharu Mizuno, Aya Takahashi.

Contributors TS and HT equally contributed to this study. TS: study conception, interpretation of data, drafting, and revising the work. HT: acquisition and analysis of data and drafting of the work. TY, HS: interpretation of data and revising the work. RF: analysis of data and revising the work. AU: acquisition of data and revising the work. TS is responsible for the overall content as the guarantor. All authors read and approved the final manuscript for submission.

Funding This work was supported in part by JSPS KAKENHI grant number 21H03095.

Competing interests None declared.

Patient consent for publication Not applicable.

Ethics approval This study involves human participants and was approved by the Ethics Committee of Kagoshima University Hospital. Approved No. 210124. The need for informed consent was waived by Kagoshima University Hospital Clinical Research Ethics Committee because of the retrospective nature of the study. Moreover, the research plan was published on the homepage of the participating hospitals according to the instructions of the IRB in accordance with the guaranteed opt-out opportunity.

Provenance and peer review Not commissioned; externally peer reviewed.

Data availability statement Data are available upon reasonable request.

Supplemental material This content has been supplied by the author(s). It has not been vetted by BMJ Publishing Group Limited (BMJ) and may not have been peer-reviewed. Any opinions or recommendations discussed are solely those of the author(s) and are not endorsed by BMJ. BMJ disclaims all liability and responsibility arising from any reliance placed on the content. Where the content

includes any translated material, BMJ does not warrant the accuracy and reliability of the translations (including but not limited to local regulations, clinical guidelines, terminology, drug names and drug dosages), and is not responsible for any error and/or omissions arising from translation and adaptation or otherwise.

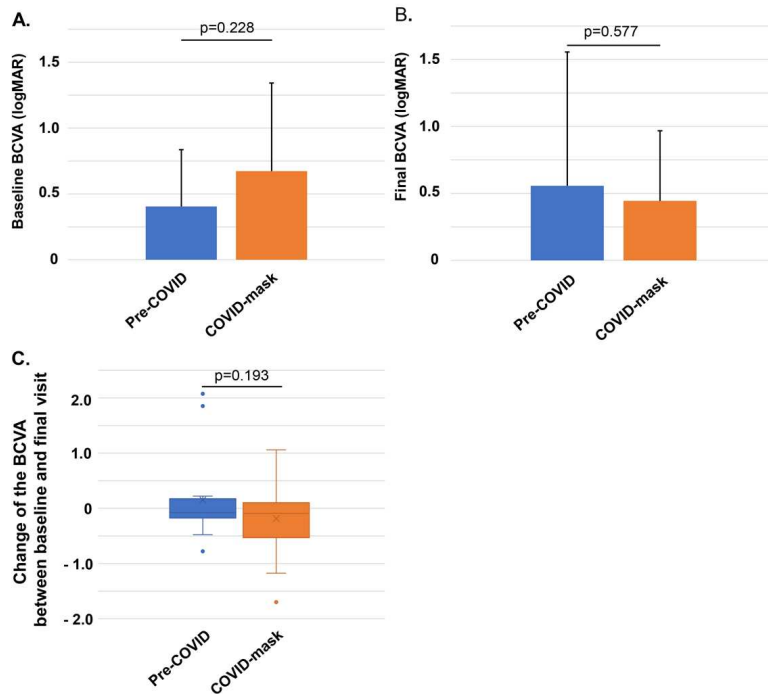
This article is made freely available for personal use in accordance with BMJ's website terms and conditions for the duration of the covid-19 pandemic or until otherwise determined by BMJ. You may download and print the article for any lawful, non-commercial purpose (including text and data mining) provided that all copyright notices and trade marks are retained.

ORCID iD

Taiji Sakamoto <http://orcid.org/0000-0003-0287-3801>

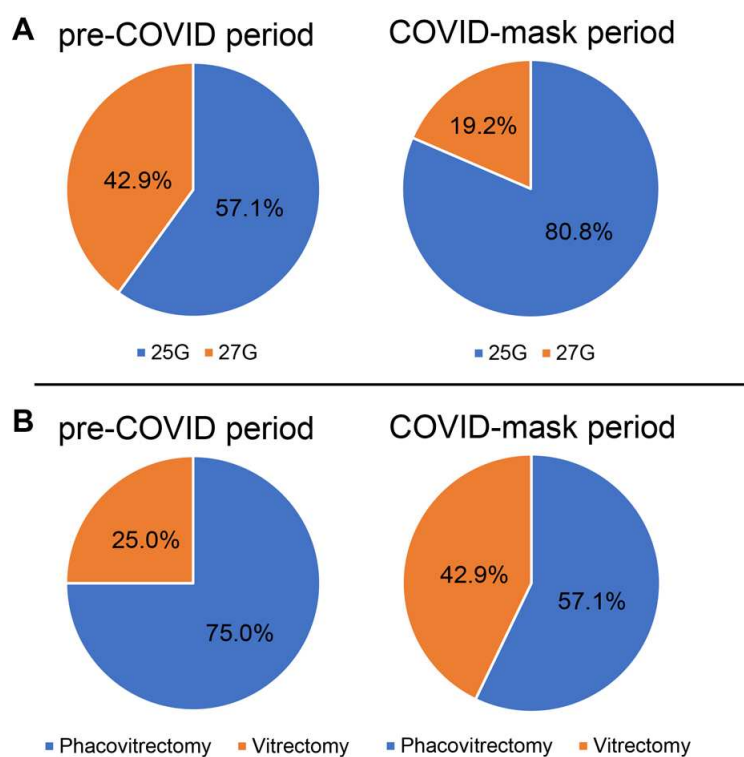
REFERENCES

- Klompas M, Morris CA, Sinclair J, *et al*. Universal masking in hospitals in the Covid-19 era. *N Engl J Med* 2020;382:e63.
- Anfinrud P, Stadnytskyi V, Bax CE, *et al*. Visualizing Speech-Generated oral fluid droplets with laser light scattering. *N Engl J Med* 2020;382:2061–3.
- Blom K, Bragadottir R, Sivertsen MS, *et al*. Mask use by patients in the context of COVID-19 can increase the risk of postinjection endophthalmitis. *Acta Ophthalmol* 2022;100:e859–60.
- Moshirfar M, West WB, Marx DP. Face Mask-Associated ocular irritation and dryness. *Ophthalmol Ther* 2020;9:397–400.
- Raevis JJ, Gjyzeli G, Mittelu M, *et al*. Face masks and bacterial dispersion toward the periocular area. *Ophthalmology* 2021;128:1236–8.
- Chadwick O, Lockington D. Addressing post-operative Mask-Associated dry eye (MADE). *Eye* 2021;35:1543–4.
- Garg SJ, Dollin M, Hsu J, *et al*. Effect of a Strict 'No-Talking' Policy During Intravitreal Injection on Post-Injection Endophthalmitis. *Ophthalmic Surg Lasers Imaging Retina* 2015;46:1028–34.
- Patel SN, Hsu J, Sivalingam MD, *et al*. The impact of physician face mask use on endophthalmitis after intravitreal anti-vascular endothelial growth factor injections. *Am J Ophthalmol* 2021;222:194–201.
- Tsang PM, Prost A. Boundaries of solidarity: a meta-ethnography of mask use during past epidemics to inform SARS-CoV-2 suppression. *BMJ Glob Health* 2021;6:e004068.
- Koto T, Kawasaki R, Yamakiri K, *et al*. Six months primary success rate for retinal detachment between vitrectomy and scleral buckling. *Retina* 2021;41:1164–73.
- Baba T, Kawasaki R, Yamakiri K, *et al*. Visual outcomes after surgery for primary rhegmatogenous retinal detachment in era of microincision vitrectomy: Japan-Retinal detachment Registry report IV. *Br J Ophthalmol* 2021;105:227–32.
- Results of the endophthalmitis vitrectomy study. A randomized trial of immediate vitrectomy and of intravenous antibiotics for the treatment of postoperative bacterial endophthalmitis. endophthalmitis vitrectomy Study Group. *Arch Ophthalmol* 1995;113:1479–96.
- National Institute of infectious diseases. Available: <https://www.niid.go.jp/niid/ja/diseases/ka/corona-virus/2019-ncov/2488-idsc/iasr-news/9729-485p04.html> [Accessed 30 Sep 2021].
- Aas JA, Paster BJ, Stokes LN, *et al*. Defining the normal bacterial flora of the oral cavity. *J Clin Microbiol* 2005;43:5721–32.
- Komiyama EY, Lepesqueur LSS, Yassuda CG, *et al*. Enterococcus species in the oral cavity: prevalence, virulence factors and antimicrobial susceptibility. *PLoS One* 2016;11:e0163001.
- Kim SH, Yu MH, Lee JH, *et al*. Seasonal variation in acute post-cataract surgery endophthalmitis incidences in South Korea. *J Cataract Refract Surg* 2019;45:1711–6.
- Garg SJ, Dollin M, Storey P, *et al*. Microbial spectrum and outcomes of endophthalmitis after intravitreal injection versus pars plana vitrectomy. *Retina* 2016;36:351–9.
- McCannel CA. Meta-analysis of endophthalmitis after intravitreal injection of anti-vascular endothelial growth factor agents: causative organisms and possible prevention strategies. *Retina* 2011;31:654–61.
- Wu L, Berrocal MH, Arévalo JF, *et al*. Endophthalmitis after pars plana vitrectomy: results of the pan American collaborative retina Study Group. *Retina* 2011;31:673–8.
- Scott IU, Flynn HW, Acar N, *et al*. Incidence of endophthalmitis after 20-gauge vs 23-gauge vs 25-gauge pars plana vitrectomy. *Graefes Arch Clin Exp Ophthalmol* 2011;249:377–80.
- Chiang A, Kaiser RS, Avery RL, *et al*. Endophthalmitis in microincision vitrectomy: outcomes of gas-filled eyes. *Retina* 2011;31:1513–7.
- Shi X-yu, Zhao H-shu, Wei W-bin. Analysis of post-operative endophthalmitis after pars plana vitrectomy: a 10-year experience at a single center. *Chin Med J* 2013;126:2890–3.
- Park JC, Ramasamy B, Shaw S, *et al*. A prospective and nationwide study investigating endophthalmitis following pars plana vitrectomy: clinical presentation, microbiology, management and outcome. *Br J Ophthalmol* 2014;98:1080–6.
- Czajka MP, Byhr E, Olivestvedt G, *et al*. Endophthalmitis after small-gauge vitrectomy: a retrospective case series from Sweden. *Acta Ophthalmol* 2016;94:829–35.
- Dave VP, Pathengay A, Basu S, *et al*. Endophthalmitis after pars plana vitrectomy: clinical features, risk factors, and management outcomes. *Asia Pac J Ophthalmol* 2016;5:192–5.
- Weiss SJ, Adam MK, Gao X, *et al*. Endophthalmitis after pars plana vitrectomy: efficacy of intraoperative subconjunctival antibiotics. *Retina* 2018;38:1848–55.
- LaGrow AL, Schatzman SN, Amayem OA, *et al*. Endophthalmitis after transconjunctival pars plana vitrectomy: a 6-year experience without prophylactic intraoperative subconjunctival antibiotics. *Retina* 2021;41:531–7.
- Silpa-Archa S, Kumsiang K, Preble JM. Endophthalmitis after pars plana vitrectomy with reused single-use devices: a 13-year retrospective study. *Int J Retina Vitreous* 2021;7:2.
- Garoon RB, Miller D, Flynn HW. Acute-onset endophthalmitis caused by *Staphylococcus lugdunensis*. *Am J Ophthalmol Case Rep* 2018;9:28–30.
- Shamoto I, Komatsu M. Staphylococcal contamination on the head skin and hairs of hospital patients and the effect of shampoo technique on the elimination of the contamination. *Bulletin of Aichi Prefectural University School of Nursing & Health* 2015;2015:21–9. (in Japanese).
- Inoue T, Uno T, Usui N, *et al*. Incidence of endophthalmitis and the perioperative practices of cataract surgery in Japan: Japanese prospective multicenter study for postoperative endophthalmitis after cataract surgery. *Jpn J Ophthalmol* 2018;62:24–30.
- Oshika T, Hatano H, Kuwayama Y, *et al*. Incidence of endophthalmitis after cataract surgery in Japan. *Acta Ophthalmol Scand* 2007;85:848–51.
- Shinkai Y, Oshima Y, Yoneda K, *et al*. Multicenter survey of sutureless 27-gauge vitrectomy for primary rhegmatogenous retinal detachment: a consecutive series of 410 cases. *Graefes Arch Clin Exp Ophthalmol* 2019;257:2591–600.
- Sakamoto T, Enaida H, Kubota T, *et al*. Incidence of acute endophthalmitis after triamcinolone-assisted pars plana vitrectomy. *Am J Ophthalmol* 2004;138:137–8.
- Shimada H, Nakashizuka H, Hattori T, *et al*. Incidence of endophthalmitis after 20- and 25-gauge vitrectomy causes and prevention. *Ophthalmology* 2008;115:2215–20.
- Oshima Y, Kadosono K, Yamaji H, *et al*. Multicenter survey with a systematic overview of acute-onset endophthalmitis after transconjunctival microincision vitrectomy surgery. *Am J Ophthalmol* 2010;150:716–25.
- Mutoh T, Kadoya K, Chikuda M. Four cases of endophthalmitis after 25-gauge pars plana vitrectomy. *Clin Ophthalmol* 2012;6:1393–7.
- Chen G, Tzekov R, Li W, *et al*. Incidence of endophthalmitis after vitrectomy: a systematic review and meta-analysis. *Retina* 2019;39:844–52.
- Shockley RK, Jay WM, Fishman PH, *et al*. Effect of inoculum size on the induction of endophthalmitis in aphakic rabbit eyes. *Acta Ophthalmol* 1985;63:35–8.
- Writing committee for the Post-Injection Endophthalmitis Study Group, Patel SN, Tang PH, *et al*. The influence of universal face mask use on endophthalmitis risk after intravitreal anti-vascular endothelial growth factor injections. *Ophthalmology* 2021;128:1620–6.
- Breazzano MP, Nair AA, Arevalo JF, *et al*. Frequency of urgent or emergent vitreoretinal surgical procedures in the United States during the COVID-19 pandemic. *JAMA Ophthalmol* 2021;139:456–63.
- Roshanshad A, Binder S. Retinal detachment during COVID-19 era: a review of challenges and solutions. *Spektrum Augenheilkd* 2022;36:1–6.
- Nonaka S, Makiishi T, Nishimura Y. Prevalence of burnout among internal medicine and primary care physicians before and during the COVID-19 pandemic in Japan. *Intern Med* 2021.
- Weng T-H, Chang H-C, Chung C-H, *et al*. Epidemiology and Mortality-Related prognostic factors in endophthalmitis. *Invest Ophthalmol Vis Sci* 2018;59:2487–94.
- Biondi M, Zannino LG, stress P. Psychological stress, neuroimmunomodulation, and susceptibility to infectious diseases in animals and man: a review. *Psychother Psychosom* 1997;66:3–26.



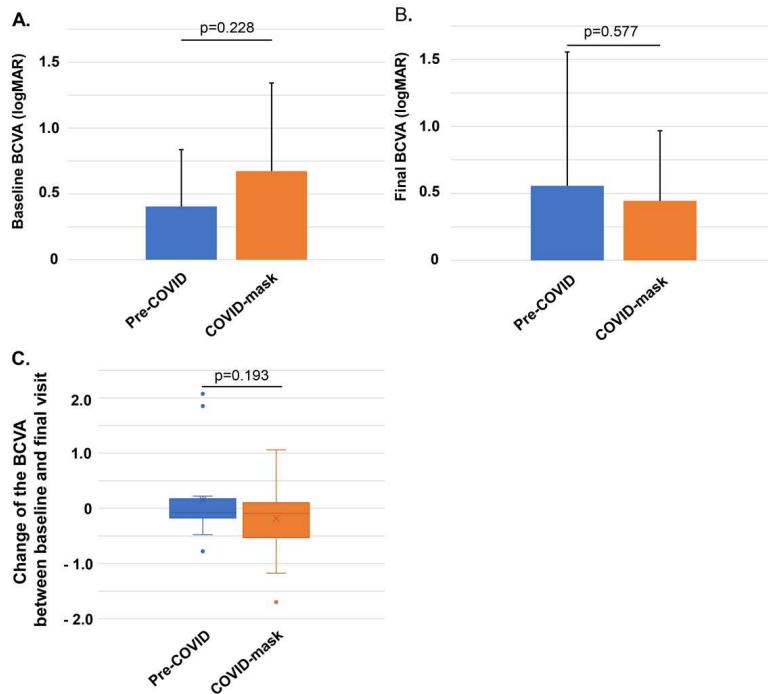
online supplemental figure S1: Baseline and final best-corrected visual acuity (BCVA) in pre-COVID and COVID-mask period.

Baseline and final BCVA of post-vitreotomy endophthalmitis in pre-COVID and COVID-mask periods were compared. Baseline BCVA (A), final BCVA (B), and the change of the BCVA between final and baseline BCVA (C) were not significantly different in the pre-COVID and during COVID-mask period.



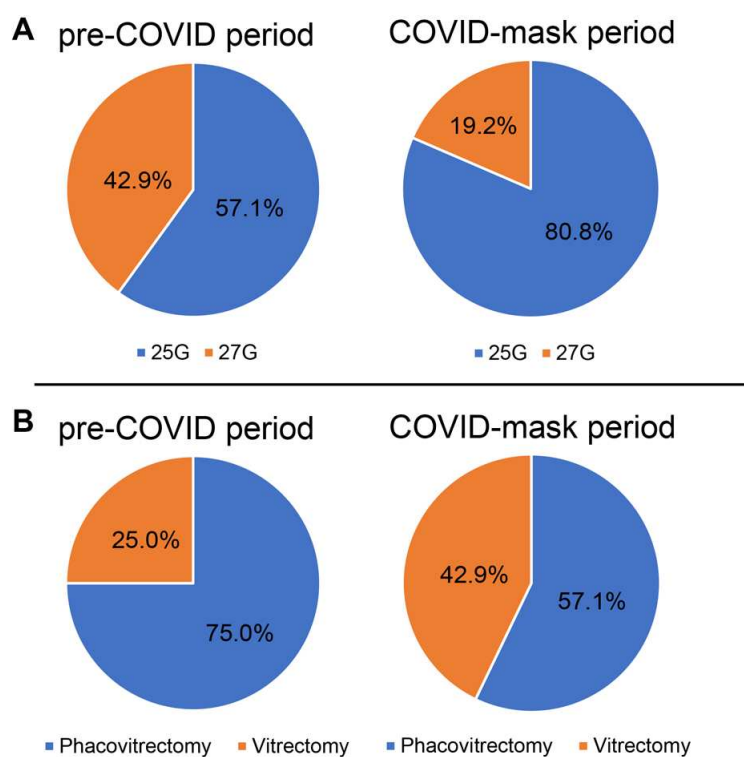
online supplemental figure S2: Breakdown of vitrectomy in the pre-COVID and COVID-mask periods: the size of vitrectomy probes and the vitrectomy alone/phacovitrectomy.

There was a tendency for more endophthalmitis cases in the COVID-mask period that had undergone 25G vitrectomy (A) and more vitrectomy procedures alone (B), but it did not reach statistical significance.



online supplemental figure S1: Baseline and final best-corrected visual acuity (BCVA) in pre-COVID and COVID-mask period.

Baseline and final BCVA of post-vitreotomy endophthalmitis in pre-COVID and COVID-mask periods were compared. Baseline BCVA (A), final BCVA (B), and the change of the BCVA between final and baseline BCVA (C) were not significantly different in the pre-COVID and during COVID-mask period.



online supplemental figure S2: Breakdown of vitrectomy in the pre-COVID and COVID-mask periods: the size of vitrectomy probes and the vitrectomy alone/phacovitrectomy.

There was a tendency for more endophthalmitis cases in the COVID-mask period that had undergone 25G vitrectomy (A) and more vitrectomy procedures alone (B), but it did not reach statistical significance.