





OPEN ACCESS

Worldwide outcomes of nasal transposition of the split lateral rectus muscle for strabismus associated with 3rd-nerve palsy

Ankoo S Shah ^{1,2}, Mary-Magdalene Ugo Dodd,^{1,2} Birsen Gokyigit,³ Birgit Lorenz,⁴ Erick Laurent,⁵ Mohammad Ali Ayaz Sadiq,^{6,7} Chong-Bin Tsai ⁸, Nicolas Gravier,⁹ Mitra Goberville,¹⁰ Sotirios Basiakos,^{11,12} David Zurakowski,¹³ Linda R Dagi,^{1,2} for the NTSRL3NP Study Group

► Additional supplemental material is published online only. To view, please visit the journal online (<http://dx.doi.org/10.1136/bjophthalmol-2021-319667>).

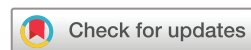For numbered affiliations see end of article.

Correspondence to

Dr Linda R Dagi, Ophthalmology, Boston Children's Hospital, Boston, Massachusetts, USA; linda.dagi@childrens.harvard.edu

Association of Pediatric Ophthalmology and Strabismus Annual Meeting, March 2018 (subset of data presented). Joint meeting of the European and International Strabismological Associations, April 2021

Received 13 May 2021
Accepted 13 November 2021
Published Online First
8 December 2021



© Author(s) (or their employer(s)) 2023. Re-use permitted under CC BY-NC. No commercial re-use. See rights and permissions. Published by BMJ.

To cite: Shah AS, Dodd M-MU, Gokyigit B, *et al.* *Br J Ophthalmol* 2023;**107**:725–731.

ABSTRACT

Background/aims To determine success rate and complications associated with nasal transposition of the split lateral rectus muscle (NTSLR) for treating strabismus from 3rd-nerve palsy.

Methods An international, multicentre, registry of patients with unilateral 3rd-nerve palsy treated with NTSLR was created. Patients with concurrent surgery on the contralateral eye were excluded. Primary outcome was horizontal alignment within 15 prism dioptres (PD) of orthotropia. Incidence of technical difficulties and vision-threatening complications by 6 months post-procedure were reported.

Results Ninety-eight patients met inclusion criteria. Median age was 33.5 years (IQR 10.75–46). Aetiologies included congenital (31%), neoplastic (16%) and traumatic (15%). Twenty-five per cent of patients had prior ipsilateral strabismus surgery. Median exotropia decreased from 70PD preoperatively (IQR 50–90) to 1PD postoperatively (IQR 0–15.5), with a success rate of 69%. Performing concurrent superior oblique muscle tenotomy (SOT) was independently associated with success ($p=0.001$). Technical challenges occurred in 30% of cases, independently associated with a history of ipsilateral strabismus surgery ($p=0.01$). Eleven per cent of patients had vision-threatening complications, independently associated with more posterior placement of the split lateral rectus (LR) muscle ($p<0.001$), and most commonly transient serous choroidal effusion. Surgical placement of the split LR muscle within 4.25 mm of the medial rectus (MR) muscle insertion *reduced* this risk.

Conclusion NTSLR significantly improved primary position alignment altered by 3rd-nerve palsy. Concurrent SOT and placement of the split LR muscle ≤ 4.25 mm posterior to the MR muscle insertion optimised outcomes. NTSLR proved technically challenging when prior ipsilateral strabismus surgery had been performed.

INTRODUCTION

Treating the complex, incomitant, strabismus associated with complete 3rd-nerve palsy poses a challenge. Numerous surgical options have been described to address the associated exotropia such as medial rectus (MR) muscle resection combined with lateral rectus (LR) muscle

recession, disinsertion and anchoring of the LR muscle to the lateral orbital wall,¹ or LR muscle myectomy² or extirpation.³ Results of anchoring the globe to the periosteum along the medial orbital wall^{4–6} and transposition of the superior oblique muscle tendon to the superior border of the MR muscle have been detailed as well.^{7,8}

Taylor introduced the novel concept of reducing exotropia in 3rd-nerve palsy by transposition of the LR muscle to the nasal side of the globe.⁹ Kaufmann reported a modification wherein the LR muscle was split into superior and inferior halves with medial transposition of each half close to the superior and inferior vortex veins.¹⁰ Gokyigit *et al* introduced a new technique transposing the split halves of the LR muscle close to the MR muscle insertion.¹¹ Shah *et al* added adjustable sutures to enable more precise ocular alignment.¹² Saxena and colleagues augmented the impact with placement of posterior fixation sutures.¹³ Basiakos *et al* published the largest cohort of patients confirming efficacy of nasal transposition of the split lateral rectus muscle (NTSLR).¹⁴ However, technical challenges and vision threatening complications have been noted.^{12,14–18}

Given the numerous single-centre studies reporting varying degrees of success with NTSLR, the rarity of 3rd-nerve palsy, and the possibility of vision threatening complications, we disseminated a cloud-based registry internationally to improve our understanding of outcomes and risks associated with NTSLR.

MATERIAL AND METHODS

This multi-centre, retrospective, non-randomised, cohort study was initiated at Boston Children's Hospital, Boston, Massachusetts, USA.

Data collection

A research electronic data capture (REDCap) registry was designed. Invitation to participate was announced through paediatric ophthalmology electronic mailing lists, a WhatsApp group of Indian paediatric ophthalmologists, the European Strabismological Association, and presentation at the American Association of

Pediatric Ophthalmology and Strabismus Annual Meeting in 2018. The registry opened in August 2017 and closed in June 2018.

This registry prompted entry of demographic data including aetiology of the 3rd-nerve palsy, laterality, sex, age at diagnosis, age at surgery, surgeon and history of strabismus surgery. Examination data included best-corrected visual acuity, sensorimotor examination evaluation before and after NTSLR, all variations in surgical technique, and intraoperative and postoperative complications.

Demographic inclusion/exclusion criteria

All patients with *unilateral* 3rd-nerve palsy and completed REDCap data entry through 6 months postprocedure were included. Patients treated for bilateral 3rd-nerve palsy or unilateral 3rd-nerve palsy with NTSLR augmented by concurrent surgery on the *contralateral* eye were excluded.

Sensorimotor examination

Horizontal alignment at 1/3 m was noted in prism dioptres (PD). If alignment at 1/3 m was not available, alignment at 3 m was substituted. Both preoperative and postoperative horizontal alignment was measured by simultaneous prism and cover testing (SPCT) while fixating with the non-paretic eye in primary position or estimated by Krinsky method if an SPCT measurement was unavailable. Vertical alignment at 1/3 metre was noted in PD with preference for SPCT, then Krinsky, or finally alternate prism and cover test fixating with the non-paretic eye. Fusion was queried as a binary variable indicating any evidence of binocular vision including appropriate compensatory head posture, motor fusion, sensory fusion on Worth-4-dot testing, or stereopsis.

Details pertaining to surgery

The distance from the superior or inferior border of the MR muscle insertion for each half of the nasally transposed LR muscle was reported in mm. Zero millimetre was designated for transposition to the MR muscle insertion with a positive value denoting a location posterior to the MR muscle insertion. The *mean* of the reported distance of the superior and inferior halves of the nasally transposed LR muscle from the MR muscle insertion was used to study the impact of transposition *location* on postoperative horizontal alignment, change in horizontal alignment, and technical and vision-threatening complications. Surgical modifications specifically queried included concurrent superior oblique muscle tenotomy (SOT), inferior oblique muscle (IO) myectomy, adjustable suture technique or augmentation suture(s).

Technical difficulties encountered during this surgery such as partial muscle rupture or inability to adequately transpose the split LR muscle segments were analysed as 'technical difficulties'. Any reduction in postoperative best-corrected visual acuity or postoperative examination findings that might threaten vision such as altered chorioretinal or anterior segment circulation, or optic nerve function, were included in the analysis under 'vision-threatening complications'.

Outcomes

The primary outcome was successful postoperative horizontal alignment within 15PD of orthotropia.¹⁹ Impact of the aetiology, age at surgery, surgeon, magnitude of preoperative exotropia, mean location of the transposed halves of the LR muscle, and concurrent SOT or IO myectomy were queried by univariate

and multivariable analysis with respect to success. Secondary outcome measures were (i) incidence of technical difficulties, (ii) incidence of vision-threatening complications and (iii) factors associated with postoperative fusion. Baseline and intraoperative factors were queried by univariate and multivariable logistic regression analyses with respect to these outcomes.

Statistical analyses

Raw data from the REDCap database were exported to Excel (Microsoft Corporation, Redmond, Washington, USA) and filtered to include cases based on the criteria noted. Statistical analyses were performed in IBM SPSS Statistics V.27.0 (IBM, Armonk, NY, USA). Continuous data were summarised using medians and IQRs and were compared by the Mann-Whitney U test. Categorical data were expressed as frequencies and percentages. Binary variables were compared by Pearson χ^2 test and Fisher exact test, as appropriate. Univariate analysis identified variables showing significant differences and relevant variables were subject to multivariable logistic regression analyses. Multiple linear regression analysis with backward selection was used to understand factors that might predict the magnitude of correction afforded by NTSLR. Related-samples Wilcoxon signed-rank tests were used to compare preoperative and postoperative alignment. Comparisons with p values <0.05 were considered statistically significant. A receiver-operating characteristic for vision threatening complications was planned to establish thresholds.

RESULTS

Demographics

Thirty-six surgeons in North America, South America, Europe, Middle East or Asia entered 146 cases of NTSLR into the REDCap registry. One hundred and thirty-four entries were complete and 98 met inclusion criteria (online supplemental eFigure 1) with demographic characteristics shown in table 1. The median age at surgery was 33.5 years (IQR 10.75–46). Forty-eight per cent of patients were female, 48% of cases involved the right eye and 25% of cases had a history of ipsilateral strabismus surgery. The most common aetiologies were congenital (31%), neoplastic (16%) and traumatic (15%). The median preoperative exotropia was 70PD (IQR 50–90). The median preoperative hypotropia was 4PD (IQR 10–0).

Table 1 Demographic data of patients who underwent nasal transposition of the split lateral rectus muscle for strabismus from unilateral 3rd-nerve palsy

Demographic	Number
Unilateral 3rd-nerve palsy cases	98
Age at surgery in years (median, IQR)	33.5 (10.75–46)
Sex, female	47 (48%)
Affected eye, right	47 (48%)
Prior strabismus surgery on the ipsilateral eye	24 (24.5%)
3rd-nerve palsy aetiology	
Congenital	31 (31.6%)
Neoplastic	16 (16.3%)
Traumatic	15 (15.3%)
Postneurosurgical	8 (8.2%)
Ischaemic	7 (7.1%)
Aneurysmal	3 (3.1%)
Other/unclassified	18 (18.4%)

Table 2 Surgical details of patients undergoing unilateral nasal transposition of the split lateral rectus muscle for strabismus associated with 3rd-nerve palsy

Surgical detail	Entire cohort	NTSLR	NTSLR+other ipsilateral horizontal surgery
Number	98	88	10
Median placement of the split LR (mm, IQR)	0 (0 to 4.5)	0 (0 to 3.375)	10 (1.5 to 16.75)
IO myectomy (n, %)	7 (7.1)	7 (8.0)	0 (0)
SO tenotomy (n, %)	16 (16.3)	16 (18.2)	0 (0)
Adjustable suture technique (n, %)	17 (17.3)	17 (19.3)	0 (0)
Augmentation suture technique	5 (5.1)	4 (4.5)	1 (10)
Median preoperative exotropia (PD, IQR)	70 (50 to 90)	65 (50 to 90)	90 (48.75 to 116)
Median postoperative exotropia (PD, IQR)	1 (0 to 15.5)	0 (0 to 18)	5 (−0.50 to 14.5)
Median change in horizontal alignment (PD, IQR)	60 (46 to 81)	60 (45.5 to 80)	82.5 (45.75 to 121.5)
Median preoperative hypotropia (PD, IQR)	−4 (−10 to 0)	−2 (−10 to 0)	−4 (−12.5 to 0)
Median postoperative hypotropia (PD, IQR)	−2 (−7 to 0)	−1.5 (−7.75 to 0)	−2 (−7 to 0)

IO, inferior oblique muscle; LR, lateral rectus muscle; NTSLR, nasal transposition of the split lateral rectus muscle; PD, prism dioptres; SO, superior oblique muscle.

Surgical details

Ninety-eight unilateral NTSLR surgeries were completed with median placement of the superior and inferior split ends of the LR muscle 0 mm (IQR 0–4.5) posterior to the insertion of the MR muscle. Eighty-eight patients underwent NTSLR surgery with common concurrent variations: IO myectomy (n=7), SOT (n=16), adjustable sutures (n=17) or augmentation sutures (n=4). Ten patients underwent NTSLR surgery plus *other ipsilateral horizontal eye alignment surgery* such as MR muscle tuck or resection, superior oblique muscle transposition nasally and inferiorly, or fascia lata lengthening of the LR muscle (online supplemental eFigure 1 bottom row, online supplemental eTable 1). Table 2 outlines the surgical details of each population.

Success

NTSLR surgery was successful in 69% (68/98) of cases (figure 1, online supplemental eTable 2). The subset treated by NTSLR surgery without additional ipsilateral horizontal surgery was

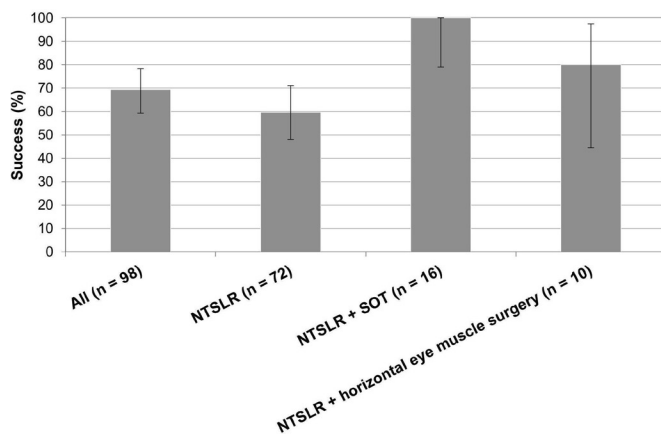


Figure 1 Success of the nasal transposition of the split lateral rectus muscle (NTSLR) in correcting strabismus associated with unilateral 3rd-nerve palsy for all cases and for the subsets of NTSLR surgery: NTSLR surgery (without superior oblique muscle tenotomy (SOT)), NTSLR surgery with SOT and NTSLR plus other ipsilateral, horizontal eye muscle surgery. Success is defined as a postoperative horizontal eye alignment within 15 prism dioptres of orthotropia within 6 months of surgery. The bars denote the 95% CI. Note that patients who had NTSLR surgery, both with and without SOT, belong to the cohort of 88 patients, who had no additional horizontal surgery.

successful in 67% (59/88), and the subset treated by NTSLR surgery augmented by other ipsilateral horizontal alignment surgery was successful in 80% (8/10).

To isolate the effect of NTSLR surgery, motor outcomes were calculated on the subset of 88 patients without additional horizontal surgery (median preoperative exotropia 65PD (IQR 50–90)). The median postoperative alignment was 0PD of exotropia (IQR 0–18) with a median reduction of exotropia of 60PD (IQR 45.5–80). The median postoperative hypotropia was 1.5PD (IQR 0–7). Eighty-three per cent of patients expressed satisfaction with their postoperative eye alignment (73/87, 1 entry did not report patient satisfaction).

By univariate analysis, surgeon (p=0.06), age at surgery (p=0.87), sex (p=0.60), history of strabismus surgery on the ipsilateral eye (p=0.07), aetiology (p=0.09), concurrent IO myectomy (p=0.09), mean placement of the NTSLR muscle relative to the MR muscle (p=0.07), use of an adjustable suture technique (p=0.73) and use of augmentation sutures (p=0.73) did not impact success. Univariate analysis showed an association of success with concurrent SOT (p=0.002) and magnitude of preoperative exotropia (p=0.01). Multivariable logistic regression analysis showed that concurrent SOT was independent of history of strabismus surgery, magnitude of the preoperative exotropia and mean placement of the split LR muscle (p=0.001). All 16 patients (100%) who underwent concurrent SOT had a successful outcome, while 43 of the 72 patients (60%) without concurrent SOT had a successful outcome (p<0.001).

Multiple linear regression analysis showed that the magnitude of exotropia correction afforded by NTSLR surgery was dependent on the preoperative deviation ($R^2=0.75$) meaning that greater correction was obtained in patients with larger preoperative exotropia. This characteristic was demonstrated to be independent of history of strabismus surgery, mean placement of the split LR muscle and SOT (p<0.001) (figure 2).

Thirty-four per cent of patients (30/87) demonstrated postoperative binocular fusion (data unavailable in one case). Univariate analysis demonstrated that older age at diagnosis (p<0.001) and history of prior binocularity (p<0.001) were positively associated with postoperative binocular fusion whereas congenital aetiology of 3rd-nerve palsy and longer time between diagnosis and surgery (p=0.007) were negatively associated with postoperative fusion (p=0.003). Multivariable logistic regression analysis showed an independent association of both longer time between diagnosis and surgery (OR 0.89, 95th percentile CI 0.81 to 0.97, p=0.01) and congenital aetiology (OR 0.10, 95%

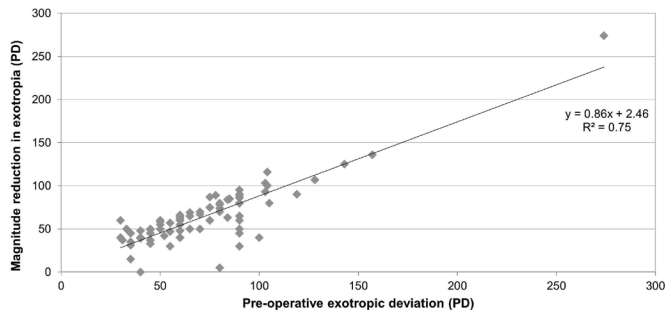


Figure 2 Magnitude of reduction in exotropia afforded by nasal transposition of the split lateral rectus muscle for 3rd-nerve palsy is dependent on the preoperative exotropia ($p < 0.001$). PD, prism dioptres.

CI 0.02 to 0.70, $p = 0.02$) with absence of postoperative fusion (table 3). Sixteen per cent (14/88) demonstrated a postoperative head turn to maintain fusion.

Technical challenges

Technical challenges completing NTSLR were encountered in 30% of the entire group (29/98, table 4). There were three cases where a split half of the LR muscle was pulled-in-two, one case of a difficult to transpose LR, one case where the inferior half of the LR muscle was too taut to transpose and one case where the transposed superior half of the LR muscle slipped off the suture. There were six other cases where difficulties with splitting were encountered. Comments included ‘it was very hard to do’, ‘I worried about globe compression’ and ‘I may have lost or torn a bit of muscle’. Technical challenges were unrelated to age at time of procedure ($p = 0.65$), time from diagnosis to surgery ($p = 0.14$), magnitude of preoperative exotropia ($p = 0.85$), aetiology ($p = 0.10$) and to the intraoperative manoeuvres including SOT ($p = 0.77$) and IO myectomy ($p = 0.42$) by univariate analysis. Technical challenges were associated with prior history of strabismus surgery ($p = 0.01$) by univariate analysis; multivariable logistic regression analysis showed history of strabismus

Table 4 Technical difficulties and complications encountered intraoperatively and postoperatively with nasal transposition of the split lateral rectus muscle. Each technical difficulty is not mutually exclusive; each vision threatening is mutually exclusive

	Detail	N (%)
Technical difficulty	Difficulties with LR muscle splitting	13 (13.3)
	Globe compression	9 (9.2)
	Surgery difficult to complete	9 (9.2)
	Scleral perforation	0 (0)
Vision threatening complication	Serous choroidal effusion	7 (7.1)
	Vision decline of unclear aetiology	3 (3.1)
	Anterior segment ischaemia	1 (1)
	Ocular hypertension	1 (1)
	Choroidal haemorrhage	0 (0)

LR, lateral rectus muscle.

surgery to be independent of all preoperative and intra-operative factors ($p = 0.01$).

Vision-threatening complications

Vision-threatening complications were encountered in 11% of the entire group (11/98, table 4). Surgeons reported seven cases of serous choroidal effusion self-resolving over weeks to 2 months, one case of presumed anterior segment ischaemia (diagnosed by iris depigmentation), one case of transient ocular hypertension to 30 mm Hg relieved by anterior chamber paracentesis (this case also had a serous choroidal effusion) and three cases of mild vision decline of unknown cause. Vision-threatening complications were unrelated to age at time of surgery ($p = 0.77$), time from diagnosis to surgery ($p = 0.58$) and history of strabismus surgery ($p = 0.27$) and to intraoperative manoeuvres including SOT ($p = 0.20$) and IO myectomy ($p = 1.00$) by univariate analysis. Vision-threatening complications were associated with greater magnitude of preoperative exotropia ($p = 0.004$) and mean placement of the split LR

Table 3 Demographic data of patients who underwent nasal transposition of the split lateral rectus muscle for strabismus from unilateral 3rd-nerve palsy dichotomised by whether they achieved binocular vision

Demographic	Postoperative binocular fusion		Statistical analysis (p value)	
	Absent (n=57)	Present (n=30)	Univariate analysis	Multivariable logistic regression
Age at diagnosis in years (median, IQR)	1.0 (0.0–29.25)	36.5 (20.75–47.25)	0.00	0.41
Time between diagnosis and surgery in years (median, IQR)	6.0 (2.0–18.40)	3.0 (2.0–6.0)	0.007	0.01
Prior strabismus surgery on the ipsilateral eye (n, %)	14 (24.6)	6 (20.0)	0.63	
3rd-nerve palsy aetiology (n, %)				
Congenital	29 (50.9)	2 (6.7)	0.003	0.02
Neoplastic	6 (10.5)	7 (23.3)	0.84	
Traumatic	6 (10.5)	7 (23.3)	0.84	
Postneurosurgical	4 (7.0)	2 (6.7)	0.49	
Ischaemic	4 (7.0)	1 (3.3)	0.26	
Aneurysmal	0 (0.0)	3 (10.0)	1.0	
Other/unclassified	8 (14.0)	8 (26.7)	Ref cat	
History of prior binocular fusion (n, %)	8 (14.0)	16 (53.3)	<0.001	0.87
Median preoperative exotropia (PD, IQR)	65.0 (50.0–90.0)	60.0 (46.25–87.50)	0.41	
Superior oblique muscle tenotomy (n, %)	8 (14.0)	8 (26.7)	0.15	
Adjustable suture technique (n, %)	9 (15.8)	7 (23.3)	0.39	

Bold values were statistically significant by univariate and multivariable analysis. N, number; PD, prism dioptres; Ref cat, reference category.

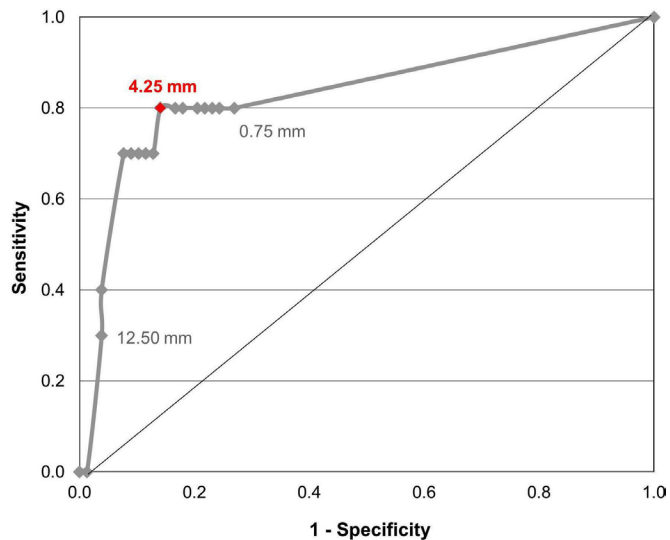


Figure 3 Receiver operating characteristic curve showing the relationship of mean placement of the split lateral rectus (LR) muscle with respect to the insertion of the medial rectus (MR) muscle and the risk of vision threatening complication. Mean placement of the split LR muscle within 4.25 mm of the MR muscle insertion minimises the risk of encountering a vision threatening complication. The area under the curve is 0.83 with a 95% CI of 0.67 to 0.99.

muscle with respect to the MR muscle insertion ($p < 0.001$) by univariate analysis. Multivariable logistic regression analysis demonstrated that only mean placement of the split LR muscle remained associated with vision-threatening complications ($p < 0.001$). For those patients *without* vision-threatening complications, the median of the mean placement of the split LR muscle was 0 mm (IQR 0–2.5) posterior to the MR muscle insertion and for those *with* vision-threatening complications, the median of the mean placement of the split LR muscle was 10 mm (IQR 4.5–13) posterior to the MR muscle insertion. A receiver operating characteristic curve illustrated that mean placement of the split LR muscle within 4.25 mm of the MR muscle insertion minimised the risk of encountering a vision threatening complication (figure 3). Of the 11 patients with vision threatening complications, 5 returned to full preoperative visual acuity, 3 declined mildly (2 declined from 20/40 to 20/60 and 1 from 20/20 to 20/30) and 3 ‘recovered’ without specific acuity information available according to the investigator. Moreover, vision-threatening complications did not adversely affect the outcome of fusion ($p = 0.73$).

DISCUSSION

Third-nerve palsy is a rare disorder causing complex, incommittant ocular misalignment, intractable diplopia and social stigma. Most publications describing options for strabismus repair are single-centre case series of modest size.^{1–14} Although case series provide a critical forum for describing and critiquing a surgical approach,^{9–14} larger datasets are necessary to validate outcomes and risks associated with any procedure. We designed a REDCAP-based registry as the first large-scale, multicentre, international collaboration on the outcomes of any strabismus procedure for 3rd-nerve palsy.

The definition of success was postoperative horizontal alignment within 15PD of orthophoria as Chan *et al* demonstrated that lay observers rarely identify exotropia until it exceeds 15PD.¹⁹ We found that 69% of patients had a successful outcome, and this

increased to 100% if treated with concurrent SOT. Eighty-three per cent of patients were satisfied, and 1/3 of patients demonstrated binocular fusion. Predictably, achievement of binocular fusion was most likely in cases with non-congenital aetiology and a shorter time interval between diagnosis and surgery. These outcomes suggest that NTSLR surgery for correction of strabismus from 3rd-nerve palsy is a compelling option.

Prior reports have documented a tendency towards under correction after NTSLR surgery in the presence of very large angles of preoperative exotropia.^{10–11} Gokyigit *et al* added MR muscle resection or contralateral LR muscle recession in such cases.¹¹ Erbagci *et al* added MR resection for undercorrection.²⁰ Sukhija *et al* required additional surgery in two of three patients with preoperative exotropia of 80–90PD.²¹ Saxena *et al* augmented NTSLR with fixation sutures 8 mm posterior to the MR muscle insertion to reduce residual exotropia in three cases.¹³ Ten patients in the current series had augmentative ipsilateral surgery as well.

We have demonstrated, however, that the net reduction in exotropia from NTSLR correlates with the magnitude of the preoperative exotropia (figure 2). A larger angle of preoperative exotropia may be associated with a more taut LR muscle that, once transposed, will transmit greater adducting tone to the eye. In addition, it has been our experience that postoperative alignment under general anaesthesia is highly predictive of alignment postrecovery. We suggest completing NTSLR with concomitant SOT and checking alignment under anaesthesia before considering additional surgery.

Our definition of successful alignment in the postoperative period did not address residual vertical misalignment. We found that the magnitude of preoperative and postoperative hypotropia was small with a median of 4PD before and 2PD after surgery, where a meaningful change in vertical alignment would be difficult to demonstrate. Finally, 16 patients had SOT and 7 had IO myectomy, both potentially altering vertical alignment.

Technical challenges associated with performing NTSLR surgery occurred in 30% of cases. These challenges were associated with prior strabismus surgery. Prior LR muscle recession results in sarcomere shortening, and a shorter LR muscle is more technically difficult to split and to transpose. In addition, scar tissue from prior surgery might hinder transposition around the globe. Surgeons contemplating NTSLR surgery should have an alternative plan in cases with a history of ipsilateral strabismus surgery. Lengthening of the split LR muscle with fascia lata has proven successful at times.²²

Vision-threatening complications were present in 11% of the cohort. Serous choroidal effusion was the most common cause, with variable onset and duration. This was previously reported in 33% of 29 cases by Basiakos *et al*¹⁴ and in single cases by Sorenson and Soni¹⁵ and Shah *et al*.¹² Transposition of split LR halves that are too short (inadequately split), or excessively taut, may compromise retinochoroidal circulation^{23–24} just beneath the transposed segments or at adjacent vortex veins. It is notable that these effusions were associated with more posterior placement of the split ends of the LR muscle, on average, 10 mm posterior to the MR insertion. Transposition that is more posterior on the globe may have greater impact on posterior circulation and on the vortex veins. Transposition of the split ends closer to the MR muscle insertion, in contrast, may produce an anterior arc of contact with the globe, diminishing impact on posterior circulation.

It is also possible that NTSLR may share characteristics associated with placement of a scleral buckle. Subretinal fluid that

mimics central serious chorioretinopathy has been reported to occur after scleral buckle placement²⁵ as has diminished retinochoroidal circulation²³ and anterior segment ischaemia.²⁶ Presumed anterior segment ischaemia was reported in one of our patients.

Finally, it is also possible that small choroidal effusions were present in more cases than reported. Though not performed in our cohort, relaxing the transposition may treat choroidal effusion,²⁷ but alter alignment as well.

This study has limitations inherent in analysing data from 36 surgeons who may have varied in their approach to measuring, performing surgery and reporting outcomes in a retrospective manner. Since the same investigator would be reporting preoperative and postoperative alignment, we do not believe investigator-to-investigator differences had a significant impact on our results. Technical difficulties may have been under-reported as operative notes may not include difficulties that were overcome. Sensory outcomes are similarly limited because our registry asked surgeons to enter the presence or absence of fusion but not to grade binocularity or associated functional benefits. Torsion was also not queried. Finally, the presence of vision threatening complications may have been under-reported as postoperative funduscopic examinations were not standardised but should be considered.

Author affiliations

- ¹Ophthalmology, Boston Children's Hospital, Boston, Massachusetts, USA
- ²Ophthalmology, Harvard Medical School, Boston, Massachusetts, USA
- ³Pediatric Ophthalmology and Strabismus, Prof Dr N Reşat Belger Beyoglu Education and Research Eye Hospital, Istanbul, Turkey
- ⁴Ophthalmology, Justus-Liebig-University, Universitätsklinikum Gießen und Marburg GmbH, Gießen, Germany
- ⁵Centre d'Ophtalmologie du Lez, Clinique St Jean, Montpellier, France
- ⁶Institute of Ophthalmology, King Edward Medical University, Lahore, Pakistan
- ⁷Institute of Ophthalmology, Mayo Hospital Lahore, Lahore, Pakistan
- ⁸Ophthalmology, Chiayi Christian Hospital, Chia-Yi, Taiwan
- ⁹Unité de Strabologie-Polyclinique de l'Atlantique, Nantes-Saint-Herblain Cedex, France
- ¹⁰Centre Ophtalmologique Lauriston, Paris, France
- ¹¹Ophthalmology, Justus Liebig Universität Giessen, Giessen, Germany
- ¹²Thessaloniki, Central Macedonia, Greece
- ¹³Anesthesia, Boston Children's Hospital, Boston, Massachusetts, USA

Twitter Mohammad Ali Ayaz Sadiq @MA_Sadiq

Collaborators NTSLR3NP Study Group: Sumita Agarkar (India), Francois Audren (France), Ana Luiza Costa (Brazil), Linda R Dagi (USA), Mary-Magdalene Ugo Dodd (USA), Jan Tjeerd de Faber (Netherlands), Amr Elkamshoushy (Egypt), Ronit Friling (Israel), Mitra Goberville (France), Birsan Gokyigit (Turkey), Michael Gräf (Germany), Nicolas Gravier (France), Mauro Goldchmit (Brazil), Gena Heidary (USA), David Hunter (USA), Laila Jeddawi (Saudi Arabia), Madhu Karna (India), Erick Laurent (France), Birgit Lorenz (Germany), Ningdong Li (China), Iason S Mantagos (USA), Pilar Merino-Sanz (Spain), Faruk Orge (USA), Sanket R Nirgude (India), Mohammad Ali Sadiq (Pakistan), Rohit Saxena (India), Ankoor S Shah (USA), Veeral Shah (USA), Pradeep Sharma (India), James Banks Shepherd (USA), Ajay Soni (USA), Claude Speeg-Schatz (France), Alain Spielmann (France), Mitchell Strominger (USA), Jaspreet Sukhija (India), Chong-Bin Tsai (Taiwan), Federico G Velez (USA), Tamara Wygnanski-Jaffe (Israel).

Contributors ASS: conceptualisation, methodology, software, formal analysis, investigation, resources, data curation, writing – original draft, visualisation. M-MUD: methodology, software, formal analysis, data curation, writing – original draft. BG: investigation, writing – review and editing. BL: investigation, writing – review and editing. EL: investigation, writing – review and editing. MAAS: investigation, writing – review and editing. C-BT: investigation, writing – review and editing. NG: investigation, writing – review and editing. MG: investigation, writing – review and editing. SB: investigation, writing – review and editing. DZ: methodology, formal analysis, visualisation. LRD: guarantor, conceptualisation, methodology, software, formal analysis, investigation, data curation, writing – original draft, visualisation, supervision, funding acquisition.

Funding Children's Hospital Ophthalmology Foundation Chair funds held by senior author.

Competing interests ASS: Medtronic (Stock interest); Rebion (Royalties); Pfizer (Stock interest). LRD: honoraria for speaking at academic centres: Texas Children's Hospital, Canadian Ophthalmological Society, UCSF Department of Ophthalmology, Kellogg Eye Center where early data were discussed, Pfizer (Stock interest).

Patient consent for publication Not applicable.

Ethics approval Institutional Review Board (IRB) approval was obtained. This work complied with the Health Insurance Portability and Accountability Act of the USA and adhered to the tenets of the Declaration of Helsinki. All contributors obtained local IRB approval (or exemption). Boston Children's Hospital IRB-P00023775.

Provenance and peer review Not commissioned; externally peer reviewed.

Data availability statement Data are available upon reasonable request. All data relevant to the study are included in the article or uploaded as supplementary information. Deidentified participant data are stored in a RedCAP registry administered by Boston Children's Hospital and available from LRD, MD (linda.dagi@childrens.harvard.edu).

Supplemental material This content has been supplied by the author(s). It has not been vetted by BMJ Publishing Group Limited (BMJ) and may not have been peer-reviewed. Any opinions or recommendations discussed are solely those of the author(s) and are not endorsed by BMJ. BMJ disclaims all liability and responsibility arising from any reliance placed on the content. Where the content includes any translated material, BMJ does not warrant the accuracy and reliability of the translations (including but not limited to local regulations, clinical guidelines, terminology, drug names and drug dosages), and is not responsible for any error and/or omissions arising from translation and adaptation or otherwise.

Open access This is an open access article distributed in accordance with the Creative Commons Attribution Non Commercial (CC BY-NC 4.0) license, which permits others to distribute, remix, adapt, build upon this work non-commercially, and license their derivative works on different terms, provided the original work is properly cited, appropriate credit is given, any changes made indicated, and the use is non-commercial. See: <http://creativecommons.org/licenses/by-nc/4.0/>.

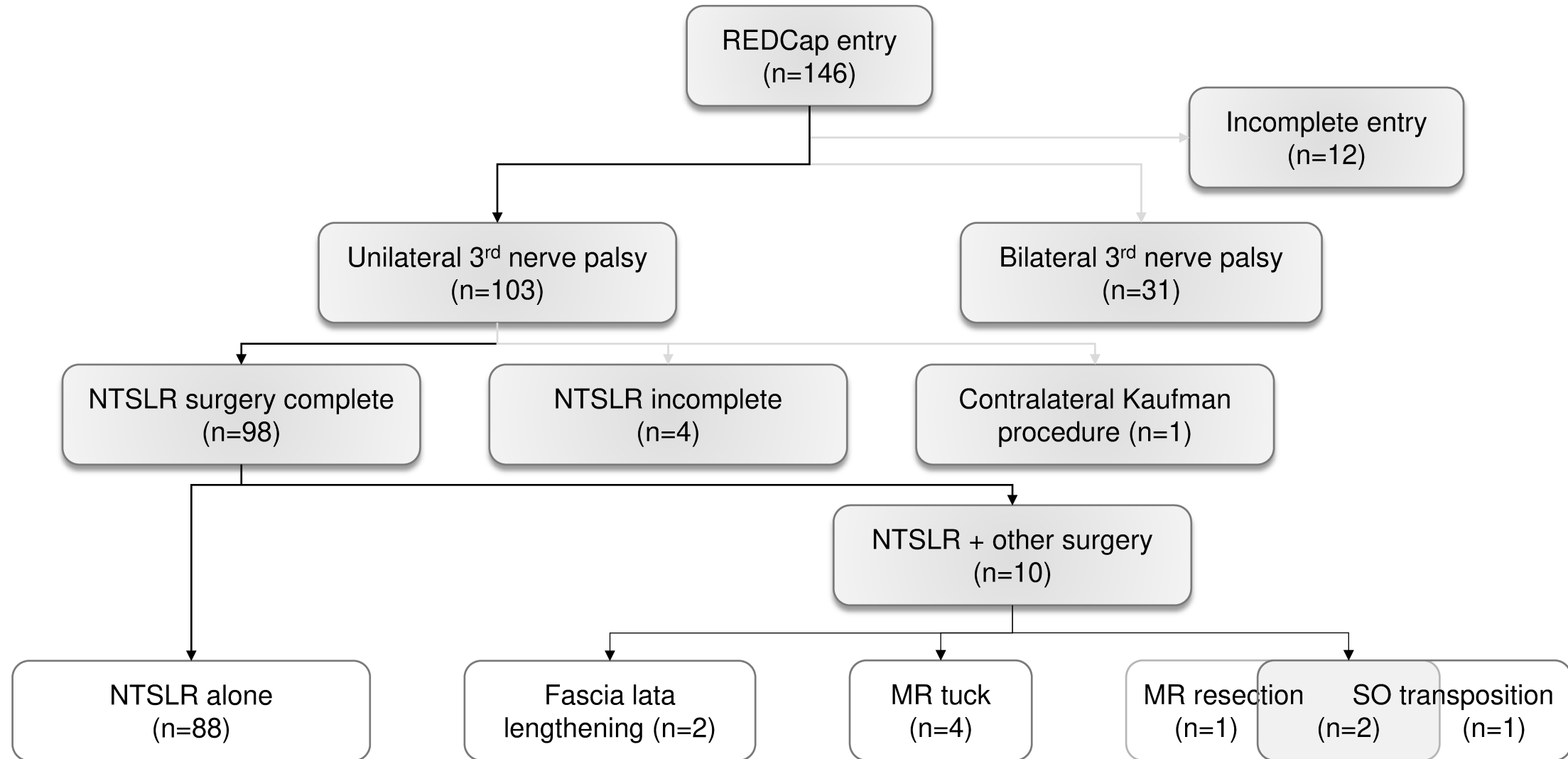
ORCID iDs

Ankoor S Shah <http://orcid.org/0000-0003-3777-2250>
Chong-Bin Tsai <http://orcid.org/0000-0002-4229-4946>

REFERENCES

- 1 Velez FG, Thacker N, Britt MT, *et al*. Rectus muscle orbital wall fixation: a reversible profound weakening procedure. *J Aapos* 2004;8:473–80.
- 2 Sato M, Maeda M, Ohmura T, *et al*. Myectomy of lateral rectus muscle for third nerve palsy. *Jpn J Ophthalmol* 2000;44:555–8.
- 3 Shah AS, Cooley R, Donahue SP. *Innovative surgical approaches for the treatment of third nerve palsy*. San Francisco: Focal Points, 2020.
- 4 Saxena R, Sinha A, Sharma P, *et al*. Precaruncular periosteal anchor of medial rectus, a new technique in the management of complete external third nerve palsy. *Orbit* 2006;25:205–8.
- 5 Saxena R, Sinha A, Sharma P, *et al*. Precaruncular approach for medial orbital wall periosteal anchoring of the globe in oculomotor nerve palsy. *J Aapos* 2009;13:578–82.
- 6 Sharma P, Gogoi M, Kedar S, *et al*. Periosteal fixation in third-nerve palsy. *J Aapos* 2006;10:324–7.
- 7 Saunders RA, Rogers GL. Superior oblique transposition for third nerve palsy. *Ophthalmology* 1982;89:310–6.
- 8 Young TL, Conahan BM, Summers CG, *et al*. Anterior transposition of the superior oblique tendon in the treatment of oculomotor nerve palsy and its influence on postoperative hypertropia. *J Pediatr Ophthalmol Strabismus* 2000;37:149–55.
- 9 Taylor JN. Surgical management of oculomotor nerve palsy with lateral rectus transplantation to the medial side of globe. *Aust N Z J Ophthalmol* 1989;17:27–31.
- 10 Kaufmann H. ["Lateralis splitting" in total oculomotor paralysis with trochlear nerve paralysis]. *Fortschr Ophthalmol* 1991;88:314–6.
- 11 Gokyigit B, Akar S, Satana B, *et al*. Medial transposition of a split lateral rectus muscle for complete oculomotor nerve palsy. *J Aapos* 2013;17:402–10.
- 12 Shah AS, Prabhu SP, Sadiq MAA, *et al*. Adjustable nasal transposition of split lateral rectus muscle for third nerve palsy. *JAMA Ophthalmol* 2014;132:963–9.
- 13 Saxena R, Sharma M, Singh D, *et al*. Medial transposition of split lateral rectus augmented with fixation sutures in cases of complete third nerve palsy. *Br J Ophthalmol* 2016;100:585–7.
- 14 Basiakos S, Gräf M, Preisung MN, *et al*. Splitting of the lateral rectus muscle with medial transposition to treat oculomotor palsy: a retrospective analysis of 29 consecutive cases. *Graefes Arch Clin Exp Ophthalmol* 2019;257:2005–14.
- 15 Sorenson R, Soni A. Central serous chorioretinopathy following medial transposition of split lateral rectus muscle for complete oculomotor nerve palsy. *J Aapos* 2017;21:161–2.

- 16 Hunter DG, Yonekawa Y, Shah AS, *et al.* Central serous chorioretinopathy following medial transposition of split lateral rectus muscle for complete oculomotor nerve palsy. *J Aapos* 2017;21:517–8.
- 17 Sorenson R, Soni A. Reply. *J Aapos* 2017;21:518–9.
- 18 Khan SS, Shah AS, Dagi LR, *et al.* Complication and management of optic nerve edema resulting from nasal transposition of the split lateral rectus muscle. *J Pediatr Ophthalmol Strabismus* 2021;58:e12–15.
- 19 Chan KW, Deng L, Weissberg EM. Detection of strabismus by Non-Health care professionals in an ethnically diverse set of images. *JAMA Ophthalmol*. In Press 2016;134:30–6.
- 20 Erbagci I, Öner V, Coskun E, *et al.* A new surgical treatment option for chronic total oculomotor nerve palsy: a modified technique for medial transposition of split lateral rectus muscle. *J Pediatr Ophthalmol Strabismus* 2016;53:150–4.
- 21 Sukhija J, Kaur S, Singh U. Nasal lateral rectus transposition combined with medial rectus surgery for complete oculomotor nerve palsy. *J Aapos* 2014;18:395–6.
- 22 Tsai C-B, Fang C-L. Fascia lata augmented nasal transposition of split lateral rectus in complete oculomotor nerve palsy with a previous failed surgery. *Eur J Ophthalmol* 2020;30:608–11.
- 23 Lincoff H, Stopa M, Kreissig I, *et al.* Cutting the encircling band. *Retina* 2006;26:650–4.
- 24 Nagahara M, Tamaki Y, Araie M, *et al.* Effects of scleral buckling and encircling procedures on human optic nerve head and retinochoroidal circulation. *Br J Ophthalmol* 2000;84:31–6.
- 25 Giuffrè C, Carnevali A, Codenotti M, *et al.* Persistent subretinal fluid mimicking central serous retinopathy after scleral buckling surgery: possible vortex vein compression role. *Eur J Ophthalmol* 2017;27:e54–6.
- 26 Papakostas TD, Vavvas D. Postoperative complications of scleral buckling. *Semin Ophthalmol* 2018;33:70–4.
- 27 Yadav N, Sharma P, Panwar V. Choroidal effusion with neurosensory detachment after medial transposition of Y split lateral rectus in third nerve palsy. *Indian J Ophthalmol* 2021;1:299–301.



eTables

eTable 1: Details of cases where nasal transposition of the split lateral rectus muscle (NTSLR) plus an ipsilateral augmentative surgery affecting horizontal eye alignment was performed. A minus number in the deviations columns indicates esotropia.

Abbreviations: PD – prism diopters; Y – yes; N – no; MR – medial rectus muscle; mm – millimeters; SO – superior oblique muscle.

Case	Etiology	Other surgery affecting horizontal eye alignment	Pre-operative horizontal deviation (PD)	Post-operative horizontal deviation (PD)	Success (Y/N)	Complication
1	Neoplastic	Fascia lata lengthening	45	0	Y	Superior half of LR was pulled in two
2	Traumatic	Fascia lata lengthening	45	45	N	Inferior half of LR was pulled in two
3	Other	MR tuck 7.0 mm	214	14	Y	None
4	Ischemic	MR tuck 10.0 mm	115	-14	Y	None
5	Post neurosurgical	MR tuck 10.0 mm	90	7	Y	Serous retinal detachment
6	Neoplastic	MR tuck 12.0 mm	119	0	Y	Globe compression noted with muscle transposition
7	Other	MR resection 3.0 mm	90	16	N	Difficulty with LR muscle splitting
8	Neoplastic	MR resection adjustable; SO transposition	80	-2	Y	None
9	Traumatic	MR resection adjustable; SO transposition	50	4	Y	None
10	Post neurosurgical	SO transposition	90	6	Y	None

eTable2: Success of nasal transposition of the split lateral rectus muscle surgery alone when used for correction of exotropia associated with 3rd-nerve palsy.

<i>Etiology of 3rd-nerve palsy</i>	<i>N (% total)</i>	<i>Success (%)</i>
<i>Congenital</i>	31 (31.6)	23 (73.2)
<i>Neoplastic</i>	16 (16.3)	10 (62.5)
<i>Traumatic</i>	15 (15.3)	7 (46.7)
<i>Post neurosurgical</i>	8 (8.2)	8 (100.0)
<i>Ischemic</i>	7 (7.1)	4 (57.1)
<i>Aneurysmal</i>	3 (3.1)	1 (33.3)
<i>Other/unclassified</i>	18 (18.4)	15 (83.3)
Total	98 (100)	68 (69.4)