



OPEN ACCESS

# Risk factors for epiretinal membrane in eyes with primary rhegmatogenous retinal detachment that received silicone oil tamponade

Qintuo Pan , Zhiqiang Gao, Xuting Hu, Qi Wu, Jing Wei Zheng, Zong-Duan Zhang

► Additional supplemental material is published online only. To view, please visit the journal online (<http://dx.doi.org/10.1136/bjophthalmol-2021-320121>).

Ophthalmology, Eye Hospital and School of Ophthalmology and Optometry, Wenzhou Medical University, Wenzhou, China

## Correspondence to

Dr Zong-Duan Zhang, Wenzhou Medical University, Wenzhou, Zhejiang, China; [zzduan@yeah.net](mailto:zzduan@yeah.net)

QP and ZG contributed equally.

QP and ZG are joint first authors.

Received 19 July 2021  
Accepted 12 January 2022  
Published Online First  
19 February 2022

## ABSTRACT

**Background/aims** This study investigated the risk factors for epiretinal membrane (ERM) in eyes with primary rhegmatogenous retinal detachment (RRD) that received silicone oil (SO) tamponade.

**Methods** This retrospective analysis included 1140 patients (1140 eyes) with RRD who underwent primary vitrectomy and SO tamponade. The prevalence of ERM was estimated and possible risk factors (eg, type 2 diabetes, proliferative vitreoretinopathy (PVR), SO tamponade time (SOTT), photocoagulation, vitreous haemorrhage, choroidal detachment, cryotherapy and retinal tear size) were analysed via multiple logistic regression.

**Results** The prevalence of ERM was 12.3% (140/1140), and the accuracy of preoperative ERM diagnosis was 40.5%. Multivariate logistic regression analysis showed that risk factors for ERM in eyes with SO tamponade included preoperative PVR (OR=4.336, 95% CI 2.533 to 7.424,  $p<0.001$ ), type 2 diabetes (OR=3.996, 95% CI 2.013 to 7.932,  $p<0.001$ ), photocoagulation energy (OR=1.785, 95% CI 1.306 to 2.439,  $p<0.001$ ) and SOTT (OR=1.523, 95% CI 1.261 to 1.840,  $p<0.001$ ). No statistically significant associations were observed between the incidence of ERM and other risk factors. Preoperative PVR showed the strongest association with risk of ERM. The risk of ERM was positively associated with SOTT, photocoagulation energy and preoperative PVR grade.

**Conclusion** In eyes with RRD that received SO tamponade, the prevalence of ERM was 12.3%, while the accuracy of preoperative ERM diagnosis was low. Preoperative PVR, type 2 diabetes, photocoagulation energy and SOTT were the main risk factors for ERM.

## INTRODUCTION

Silicone oil (SO) is a tamponade for retinal detachment repair that helps to heal detached retinas. Unlike long-acting gases, SO does not spontaneously reabsorb; therefore, it requires a second surgery for removal. However, the advantages of SO over long-acting gases include no air travel restriction and avoidance of the requirement for strict prone positioning.<sup>1</sup> Because of SO pressure, the detached retina can be appropriately reattached for an extended duration after surgery; this approach is now widely used in various vitreoretinal surgeries. During SO tamponading, patients can experience hyperopia, as well as various pathological complications, such as epiretinal membrane (ERM), SO maculopathy, SO

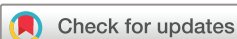emulsification, SO migration, cataracts, glaucoma, corneal lesions, or re-detachment of the retina.<sup>2–6</sup> Corneal oedema is noted after SO removal in eyes with SO touch when the aqueous layer comes back into contact with the damaged corneal endothelium.<sup>7</sup> Sachdeva *et al* reported that SO is involved in the formation of proliferative vitreoretinopathy (PVR) as an adjunct to retinal detachment repair.<sup>8</sup> Because there is increasing evidence of possible detrimental effects caused by SO endotamponade, a safety study is required.<sup>9–12</sup>

Importantly, we speculate that the onset of ERM is not solely caused by SO. Age, smoking and other factors have also been identified as risk factors for ERM.<sup>13–15</sup> Although there is no obvious explanation, we have encountered many patients with retinal detachment on whom SO was used to help the retina heal; the SO tamponade generated the preretinal proliferating membrane. However, the operative and baseline characteristics (eg, age, diabetes and hypertension) conditions can differ among SO tamponading procedures; thus, there is a need to analyse the operative and basic conditions of patients who have eyes with SO tamponade and ERM, enabling acquisition of desired results.

The formation of a proliferative membrane in front of the retina is generally not well understood. Here, we compared the basic and operative conditions of patients who had eyes with SO tamponade, without and with ERM. The purpose of this study was to determine the risk factors for ERM in eyes with primary rhegmatogenous retinal detachment (RRD) that received SO tamponade.

## MATERIALS AND METHODS

In this retrospective cohort study, we reviewed all medical records of patients with primary RRD who underwent vitrectomy and SO tamponade in our hospital from June 2017 to February 2020. Patients with varying degrees of PVR were also included. Exclusion criteria included history of trauma, history of severe eye infections or inflammatory disease, diabetic retinopathy, type 1 diabetes and severe data loss. Preoperative data were obtained from medical records, including name, age, gender, medical history, visual acuity, preoperative vitreous haemorrhage (VH), PVR grade, lens status, surgical procedure and surgical parameters, SO tamponade time (SOTT), best-corrected visual acuity before and after surgery, preoperative choroidal detachment (CD), preoperative and postoperative intraocular pressure, and



© Author(s) (or their employer(s)) 2023. Re-use permitted under CC BY-NC. No commercial re-use. See rights and permissions. Published by BMJ.

**To cite:** Pan Q, Gao Z, Hu X, *et al.* *Br J Ophthalmol* 2023;**107**:856–861.

perioperative complications. Postoperative data included visual acuity, intraocular pressure, morphology of the macular area and postoperative complications at 3 months after SO removal.

The surgery was performed by two experienced vitreoretinal surgeons. We used a 23-gauge vitrectomy system to remove SO from the vitreous cavity. If an ERM was present, we used 23-gauge pincers to remove the ERM. Furthermore, if the ERM was involved in the macular area, we also removed the internal limiting membrane with the aid of indocyanine green staining. In accordance with the surgeon's judgement, RT SIL-OL 5000 (5000 cm; Carl Zeiss Meditec AG company, Germany) SO was used for retinal detachment. If a patient was required to undergo multiple vitreoretinal surgeries, all surgeries were performed by the same surgeon.

The primary endpoint of measurement was the macular condition at 3 months after the last SO removal. The presence of a proliferative membrane in front of the retina was determined during the oil extraction surgery. In eyes with SO tamponade, the following factors were evaluated: SOTT, preoperative CD, presence of VH before and after the first surgery, photocoagulation energy during surgery, number of photocoagulation points, whether electrocoagulation was performed, and whether cryotherapy was performed.

We classified PVR into grades A, B, C1, C2, C3, D1, D2 and D3, in accordance with the 1983 International Retinal Association classification guidelines. Grades B, C1, C2, C3, D1, D2 and D3 were regarded as higher grades.

The SOTT was divided into five groups according to length: level 1, 2–3 months; level 2, 4–6 months; level 3, 7–9 months; level 4, 10–12 months; and level 5, >12 months.

Photocoagulation energy was divided into four groups according to the energy used during the first operation: first level, 120–165 mV; second level, 166–210 mV; third level, 211–255 mV and fourth level, 256–300 mV.

The condition of the retina after SO tamponading was evaluated by a trained professional. Proliferative membrane found in the macular area of the fovea, the peripheral retina, and any other areas was defined as ERM. Before and after surgery, macular optical coherence tomography was used to observe the morphology of the macular area. A panoramic 200 scanning laser ophthalmoscope (Opel) was used to observe the state of the retina, and a B-ultrasound scan was used to confirm the retinal morphology and eyeball state after surgery. All patients underwent medical optometry and intraocular pressure examinations before and after surgery.

Statistical analysis was performed using SPSS Statistics V24.0. The Kolmogorov-Smirnov test was used to determine whether continuous numerical variables exhibited normal distributions. Univariate analysis of categorical variables was performed by the  $\chi^2$  test or Fisher's exact test. Univariate analysis of continuous variables was performed using the Wilcoxon rank-sum test; Student's t-test was used to compare the mean values of normally distributed variables. Logistic regression analysis was used to determine the risk factors for ERM formation. Stepwise regression analysis was used to rule out the effects of collinearity of related factors, prior to the final multivariate logistic regression analysis. Statistical significance was determined using a threshold of  $p < 0.05$ .

## RESULTS

### General results

In total, 1446 eyes with SO tamponade in 1446 patients were reviewed. Sixty eyes were excluded because of a history of trauma, 144 eyes were excluded because of diabetic retinopathy and 102 eyes were excluded because of a history of serious eye infections

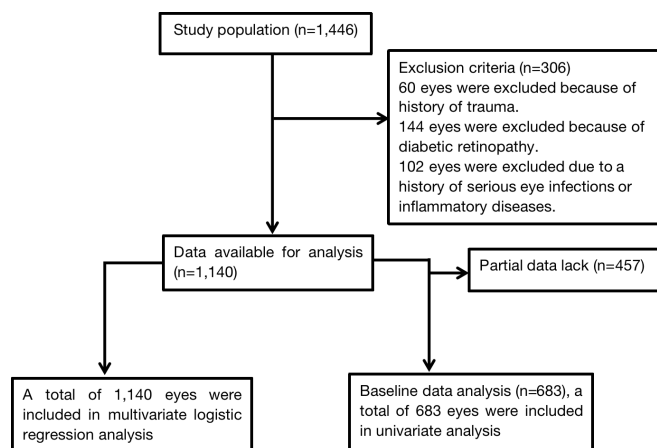


Figure 1 Flow chart of patient inclusion.

or inflammatory diseases. Thus, 1140 eyes with primary RRD were included in the analysis. The incidence of ERM in all 1140 eyes with SO tamponade was 12.3% (140/1140). The success rate of the first operation was 94.1% (1073/1140), and recurrent retinal detachment was found in 67 eyes (5.9% of 1140) during SO removal surgery. After the recurrent retinal detachment had been repaired, gas ( $C_3F_8$ ) tamponade was performed in 60 eyes (90.0% of 67), and all eyes were cured. The remaining seven eyes (10.0% of 67) received SO tamponade; all eyes were cured after SO removal 3 months later.

### Baseline data analysis results

Because some data were missing for 457 eyes, 683 eyes were included in the baseline data analysis (figure 1). The mean follow-up interval for all patients was  $12 \pm 6$  months. Furthermore, 79 eyes with ERM (11.6% of 683) were intraoperatively diagnosed using the operating room microscope, while only 32 eyes with ERM (4.7% of 683) were preoperatively diagnosed using optical coherence tomography and Opel (online supplemental table 1). The incidence of ERM significantly differed between the operating room microscope and the optical coherence tomography/Opel diagnostic methods ( $\chi^2$  test,  $p < 0.001$ ).

Among the 184 eyes (26.9% of 683) that underwent preoperative VH, 20 (25.0% of 184) exhibited ERM during SO removal surgery. Among the 683 eyes, 499 (73.0% of 683) did not exhibit preoperative VH before the first surgery. Notably, 59 eyes (11.8% of 499) exhibited ERM during the second operation. The incidence of ERM significantly differed between first and second surgeries ( $\chi^2$  test,  $p < 0.001$ ).

Among the 683 patients, 154 (22.5% of 683) had type 2 diabetes and received SO tamponade; 17 eyes (11.0% of 154) exhibited ERM during SO removal surgery. Among the remaining 529 patients (ie, patients without diabetes; 77.5% of 683), only 62 (11.7% of 529) exhibited ERM. The incidence of ERM significantly differed between patients with type 2 diabetes and patients without diabetes ( $\chi^2$  test,  $p < 0.001$ ).

Among 97 eyes (14.2% of 683) with preoperative PVR (all grades) before the first vitrectomy, proliferative membranes were found in 49 eyes (50.5% of 97) during SO removal surgery. Among 586 eyes (85.8% of 683) without PVR before the primary surgery, 30 (5.1% of 586) exhibited ERM during SO removal surgery. The incidence of ERM significantly differed between eyes with and without PVR ( $\chi^2$  test,  $p < 0.001$ ).

Among 97 eyes (14.2% of 683) with preoperative PVR before the first vitrectomy, 76 eyes (78.4% of 97) underwent ILM

peeling during the original operation due to ERM involved the macula. Recurrent macular ERM were found in five eyes (6.6% of 76) during SO removal surgery. Among the other 21 eyes (21.6% of 97) without peeling ILM during the original operation, only 1 eye (4.8% of 21) exhibited macular ERM during SO removal surgery. The incidence of recurrent macular ERM was similar between the two groups (Fisher's exact test,  $p=0.357$ ).

SOTT, photocoagulation energy and number of photocoagulation points were all positively associated with the incidence of ERM ( $p<0.001$ ). There were no statistically significant associations of ERM with postoperative VH, preoperative CD or retinal tear size (table 1).

### Multivariate logistic regression analysis results

To identify risk factors for the formation of ERM, 1140 eyes were included in the logistic regression analysis. Collinearity was suspected among diabetes, preoperative VH, preoperative PVR and other factors; therefore, we used stepwise regression analysis to rule out the effects of collinearity among potentially related factors prior to the final multivariate logistic regression analysis. Finally, preoperative VH was excluded because it demonstrated collinearity with diabetes.

The results showed that ERM in eyes with SO tamponade was associated with preoperative PVR ( $p<0.001$ ), type 2 diabetes ( $p<0.001$ ), photocoagulation energy ( $p<0.001$ ) and SOTT ( $p<0.001$ ). There were no statistically significant associations of ERM with other risk factors (table 2). The risk of ERM was positively associated with preoperative PVR grade, type 2 diabetes, photocoagulation energy and SOTT. Preoperative PVR showed the strongest association with risk of ERM. Eyes with preoperative PVR had a 1.467-fold increased risk of ERM ( $\text{Exp}(B)=4.336$ ) (figure 2).

### DISCUSSION

Complications after retinal detachment surgery and the relationship with SO have been extensively investigated, and the incidence of SO-related visual loss is reportedly 30%.<sup>16</sup> SO tamponade may cause ERM formation, leading to recurrent retinal detachment or macular occlusion, which can progress to vision loss.<sup>4 6 8</sup> Xiao *et al* reported that 9.1% of the general population had some forms of ERM.<sup>15</sup> However, the present study showed that this proportion increased to 12.3% in eyes with SO tamponade. Although we cannot yet explain the mechanism underlying ERM formation in SO-filled eyes, our findings indicated that diabetes, preoperative PVR, SOTT, and photocoagulation energy were significant risk factors for ERM.

Previous studies generally focused on the progression of diabetes toward diabetic retinopathy and fibroproliferative membrane formation, but did not address the relationship between diabetes as a systemic disease and the formation of ERM.<sup>17-19</sup> Patients with diabetic retinopathy were excluded from this study, and the results showed that type 2 diabetes was a significant risk factor for ERM in eyes with SO tamponade. The pathogenesis of ERM may be related to fibrocyte infiltration into vitreous fluid; fibrocytes and tenascin-C reportedly participate in ERM formation in patients with diabetes.<sup>17 18</sup> Hyperglycaemia causes a chain of events that leads to retinal vascular endothelial dysfunction, thus increasing the risk of ERM.<sup>20</sup> Stabilisation of glycaemia with medication, combined with dietary and lifestyle modifications, may reduce this risk.<sup>21</sup>

For patients with preoperative PVR before SO tamponade, the reported incidences of postoperative ERM and recurrent retinal detachment are significantly increased.<sup>6 22</sup> In this study,

**Table 1** The baseline data of silicone oil tamponaded eyes

Category	Eyes with ERM (n=79)	Eyes without ERM (n=604)	P value
Gender (%)			0.041
Male	36 (46)	327 (54)	
Female	42 (54)	277 (46)	
Age (%)			0.359
I ≤40	12 (15)	91 (15)	
II 41–50	17 (22)	111 (18)	
III 51–60	32 (41)	218 (36)	
IV 61–70	13 (16)	153 (26)	
V >70	5 (6)	31 (5)	
Follow-up time (month, median ±IQR)	12±6.3	12±5.8	0.998
SOTT (%)			<0.001
I (2–3)	55 (70)	341 (57)	
II (4–6)	14 (18)	195 (32)	
III (6–9)	5 (6)	32 (5)	
IV (9–12)	1 (1)	18 (3)	
V (>12)	4 (5)	18 (3)	
Photocoagulation energy (mV, %)			<0.001
I (120–165)	7 (9)	94 (16)	
II (166–210)	61 (77)	420 (69)	
III (211–255)	8 (10)	78 (13)	
IV (256–300)	3 (4)	12 (2)	
Photocoagulation points (NO, %)			<0.001
I (120–200)	19 (24)	115 (19)	
II (201–400)	21 (27)	149 (25)	
III (401–600)	12 (15)	82 (14)	
IV (601–800)	11 (14)	68 (11)	
V (>800)	16 (20)	190 (31)	
Electric coagulation (%)			0.001
Yes	23 (29)	246 (40)	
No	56 (71)	358 (60)	
Cryotherapy (%)			0.156
Yes	13 (16)	142 (24)	
No	66 (84)	462 (76)	
Preoperative VH (%)			<0.001
Yes	20 (25)	164 (27)	
No	59 (75)	440 (73)	
Postoperative VH (%)			0.989
Yes	1 (1)	6 (1)	
No	78 (99)	598 (99)	
Type 2 diabetes (%)			<0.001
Yes	17 (22)	137 (23)	
No	62 (78)	467 (77)	
Hypertension (%)			0.016
Yes	22 (28)	167 (28)	
No	57 (72)	437 (72)	
Retinal aperture size (%)			0.435
H<2	52 (66)	423 (70)	
2≤H<4	21 (27)	127 (21)	
4≤H<6	6 (7)	42 (7)	
H≥6	0 (0)	12 (2)	
Preoperative PVR (%)			<0.001
No	30 (38)	556 (92)	
PVR(A)	0 (0)	0 (0)	
PVR(B)	1 (1)	0 (0)	

Continued

Table 1 Continued

Category	Eyes with ERM (n=79)	Eyes without ERM (n=604)	P value
PVR(C1)	4 (5)	3 (1)	
PVR(C2)	16 (20)	8 (1)	
PVR(C3)	12 (15)	17 (2)	
PVR(D1)	10 (13)	7 (1)	
PVR(D2)	4 (5)	10 (2)	
PVR(D3)	2 (3)	3 (1)	
Preoperative CD (%)			0.522
Yes	17 (22)	30 (5)	
No	62 (78)	574 (95)	
ERM diagnostic method (%)			<0.001
Intraoperative diagnosis	47 (59)	0 (0)	
Preoperative diagnosis	32 (41)	604 (100)	

CD, choroidal detachment; ERM, epiretinal membrane; PVR, proliferative vitreoretinopathy; SOTT, silicone oil tamponade time; VH, vitreous haemorrhage.

the incidence of ERM in eyes with SO tamponade was strongly positively associated with preoperative PVR grade. ERM formation may be a continuation of previous PVR diseases.<sup>22</sup> Extravascular leakage of various growth factors might also contribute to ERM recurrence.<sup>23</sup> Moreover, CD, pigment release during endodrainage, inflammation and other factors are reportedly associated with the incidence of ERM.<sup>22-24</sup> Most of these factors are clearly associated with inflammation. Thus, anti-inflammatory strategies (eg, steroid use) may be effective in the prevention of ERM.<sup>25 26</sup>

Previous studies reported ILM peeling is associated with a reduction of recurrence rate of ERM.<sup>27-29</sup> However, ILM peeling may damage the Müller cells which connected to the ILM's basal lamina.<sup>30-33</sup> Ultrastructural damage to the inner retina caused by ILM peeling may be responsible for the increased macular thickness and reduced foveal light sensitivity.<sup>34</sup> In this study, the ILM was removed only when ERM involved the macula to prevent recurrence. But the recurrence of macular ERM in eyes underwent ILM peeling during SO removal surgery was similar to that without peeling ILM (6.6% vs 4.8%). Therefore, routinely peeling ILM is not recommended in cases with preoperative

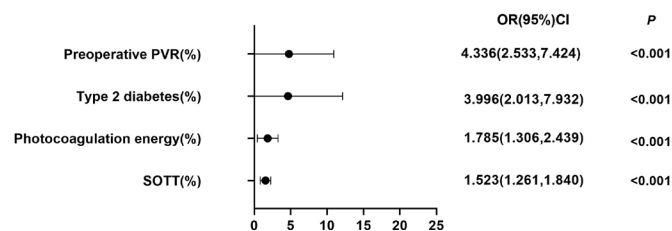


Figure 2 Forest plot of the results of multifactor analysis. PVR, proliferative vitreoretinopathy; SO, silicone oil tamponade time.

PVR, and its risks may outweigh the benefits. However, this conclusion needs to be further verified by more rigorously designed controlled studies.

SO tamponade facilitates the gradual formation of firm retinal adhesions around tears and prevents fluid from flowing into the breaks.<sup>35</sup> Some researchers presume that SO can temporarily resist retinal contact-induced proliferation and may slow ERM recurrence by limiting dissemination and circulation of related cells and factors.<sup>22 36</sup> However, other studies have suggested that SO stimulates the release of various mitotic factors.<sup>37</sup> However, SO bubbles occupy most of the vitreous cavity and may increase proliferation by concentrating active factors near the retina.<sup>22 36</sup> The results of our study showed that longer SOTT was associated with greater incidence of ERM. Prolonged tamponading causes SO to move into the retina and other ocular tissues, leading to intraocular inflammation and increased intraocular pressure.<sup>24 38</sup> Furthermore, prolonged SOTT leads to greater abundance of retinoblasts in the RPE, thus increasing the likelihood of ERM formation. We suspect that SO removal at an appropriate time (eg,  $\leq 3$  months after the initial surgery) may reduce the incidence of ERM.

Retinal laser photocoagulation has been widely used for several decades because it is minimally invasive and can rapidly enhance retinal choroidal adhesion.<sup>39</sup> The laser can effectively stabilise the retina and allow gradual SO removal.<sup>38</sup> A previous study indicated that broad application of photocoagulation can enhance intraocular inflammation and stimulate intravitreal proliferation, thus aggravating PVR.<sup>4</sup> ERM formation with ILM wrinkling may occur as a late complication of laser photocoagulation<sup>40</sup>; however, the contributing roles of photocoagulation

Table 2 The outcome of logistic analysis of SO-tamponaded eyes with or without epiretinal membrane

Category	Univariate analysis		Multi-factor analysis	
	OR (95% CI)	P value	OR (95% CI)	P value
Gender	1.143 (1.021 to 1.855)	0.045	1.117 (0.761 to 1.640)	0.573
Age	0.951 (0.878 to 1.166)	0.936	1.034 (0.870 to 1.228)	1.034
SOTT	1.503 (1.331 to 1.656)	<0.001	1.523 (1.261 to 1.840)	<0.001
Preoperative VH	2.744 (2.036 to 3.563)	<0.001	1.083 (0.577 to 2.035)	0.803
Postoperative VH	0.536 (0.183 to 2.336)	0.604	0.854 (0.130 to 5.613)	0.869
Cryotherapy	0.685 (0.583 to 0.938)	0.009	1.354 (0.830 to 2.209)	0.224
Electric coagulation	1.514 (1.036 to 1.882)	0.007	0.838 (0.552 to 1.272)	0.406
Photocoagulation energy	2.154 (1.682 to 2.783)	<0.001	1.785 (1.306 to 2.439)	<0.001
Photocoagulation points	1.383 (1.131 to 1.413)	<0.001	1.033 (0.890 to 1.200)	0.668
Retinal aperture size	0.934 (0.783 to 1.138)	0.525	0.959 (0.718 to 1.281)	0.776
Type 2 diabetes	4.125 (3.144 to 5.458)	<0.001	3.996 (2.013 to 7.932)	<0.001
Hypertension	1.525 (1.124 to 2.086)	0.003	1.208 (0.783 to 1.854)	0.396
Preoperative PVR	12.74 (9.342 to 17.53)	<0.001	4.336 (2.533 to 7.424)	<0.001
Preoperative CD	1.142 (0.786 to 1.613)	0.555	1.579 (0.946 to 2.635)	0.080

CD, choroidal detachment; PVR, proliferative vitreoretinopathy; SOTT, silicone oil tamponade time; VH, vitreous haemorrhage.

energy and the number of photocoagulation points remain controversial. Our findings indicate that ERM formation is positively associated with photocoagulation energy, rather than the number of photocoagulation points. We hypothesise that, during retinal self-repair, the accompanying mitosis and energy-induced damage will cause more extensive cell repair, leading to a macrophage-mediated inflammatory response, retinal pigment epithelium proliferation and a substantial Müller cell response; accordingly, proliferative lesions form at photocoagulation sites.<sup>4,41</sup> Therefore, we recommend the avoidance of intraoperative high-energy photocoagulation in eyes with RD.

Other risk factors for PVR (eg, cryotherapy, retinal tear size and CD) have been reported,<sup>42–44</sup> but they were not associated with ERM in this study. These discrepancies are presumably because ERM in this study occurred in eyes with SO tamponade, and the inclusion criteria and intraocular environment differed with respect to the previous studies.

Gupta *et al*<sup>45</sup> demonstrated that a complete set of preoperative eye examinations is often insufficient to make an accurate diagnosis; this influences the choice of surgical method. In our study, the accuracy of preoperative ERM diagnosis was only 40.5% (32/79). This low accuracy might be attributed to preoperative refractive media opacity in some parts of eyes with SO tamponade, which affects fundus observations. We recommend that surgeons carefully examine the entire retina after SO removal (during the operation) to avoid missing instances of ERM.

The main advantages of this study were its large sample size and the comprehensive analysis of multiple factors. The findings provide insights for the diagnosis and treatment of ERM in eyes with SO tamponade. The major limitation of this study was its retrospective design. Further prospective clinical studies are needed to determine when ERM occurs and elucidate its underlying pathogenesis. Additionally, the mean follow-up interval in this study was short (12±6 months). Retinal detachment may recur several years after the initial surgery in some people because ERM can occur several years after SO extraction.<sup>46</sup> Beyond this, due to lack of glycosylated haemoglobin (HbA1c) data in non-diabetic patients, the effect of hyperglycaemic on ERM formation cannot be further analysed based on HbA1c level.

In conclusion, the prevalence of ERM was 12.3% in eyes with primary RRD that received SO tamponade, and the accuracy of preoperative ERM diagnosis was only 40.5%. The main risk factors for ERM in eyes with SO tamponade were preoperative PVR, type 2 diabetes, photocoagulation energy, and SOTT.

**Acknowledgements** We thank Ryan Chastain-Gross, PhD, from Liwen Bianji (Edanz) ([www.liwenbianji.cn/](http://www.liwenbianji.cn/)) for editing the English text of a draft of this manuscript.

**Contributors** QP and ZG contributed to research design, data acquisition, data analysis and manuscript preparation. XH contributed to data analysis and manuscript preparation. QW and JWZ contributed to data acquisition. Z-DZ contributed to research design and data acquisition. QTP is the guarantor.

**Funding** The authors have not declared a specific grant for this research from any funding agency in the public, commercial or not-for-profit sectors.

**Competing interests** None declared.

**Patient consent for publication** Not applicable.

**Ethics approval** This study does not involve human participants. The study protocol was approved by the Eye Hospital and School of Ophthalmology and Optometry ethics committee of Wenzhou Medical University and was performed in accordance with the Declaration of Helsinki.

**Provenance and peer review** Not commissioned; externally peer reviewed.

**Data availability statement** Data are available upon reasonable request. Data may be obtained from a third party and are not publicly available. All data relevant

to the study are included in the article or uploaded as supplementary information. Not applicable.

**Supplemental material** This content has been supplied by the author(s). It has not been vetted by BMJ Publishing Group Limited (BMJ) and may not have been peer-reviewed. Any opinions or recommendations discussed are solely those of the author(s) and are not endorsed by BMJ. BMJ disclaims all liability and responsibility arising from any reliance placed on the content. Where the content includes any translated material, BMJ does not warrant the accuracy and reliability of the translations (including but not limited to local regulations, clinical guidelines, terminology, drug names and drug dosages), and is not responsible for any error and/or omissions arising from translation and adaptation or otherwise.

**Open access** This is an open access article distributed in accordance with the Creative Commons Attribution Non Commercial (CC BY-NC 4.0) license, which permits others to distribute, remix, adapt, build upon this work non-commercially, and license their derivative works on different terms, provided the original work is properly cited, appropriate credit is given, any changes made indicated, and the use is non-commercial. See: <http://creativecommons.org/licenses/by-nc/4.0/>.

#### ORCID iDs

Qintuo Pan <http://orcid.org/0000-0003-4556-1234>

Zong-Duan Zhang <http://orcid.org/0000-0002-9509-231X>

#### REFERENCES

- Scott IU, Flynn HW, Azen SP, *et al*. Silicone oil in the repair of pediatric complex retinal detachments. *Ophthalmology* 1999;106:1399–408.
- Abdalkader M, Takumi K, Chapman MN, *et al*. Subretinal and Retrolaminar migration of intraocular silicone oil detected on CT. *AJNR Am J Neuroradiol* 2019;40:1557–61.
- Adhi MI, Siyal N. Retinal re-detachments after removal of silicone oil: frequency and timings in a retrospective clinical study. *J Pak Med Assoc* 2019;69:1822–6.
- Algere PV, Hallnäs K, Dafgård E, *et al*. Panretinal photocoagulation aggravates experimental proliferative vitreoretinopathy. *Graefes Arch Clin Exp Ophthalmol* 1990;28:461–6.
- Dormegny L, Jeanjean LC, Liu X, *et al*. Visual impairment and macular vascular remodeling secondary to retrograde maculopathy in retinal detachment treated with silicon oil tamponade. *Retina* 2021;41:309–16.
- Zilis JD, McCuen BW, de Juan E, *et al*. Results of silicone oil removal in advanced proliferative vitreoretinopathy. *Am J Ophthalmol* 1989;108:15–21.
- Newsom RSB, Johnston R, Sullivan PM, *et al*. Sudden visual loss after removal of silicone oil. *Retina* 2004;24:871–7.
- Sachdeva MM, Jakobiec FA, Stagner AM, *et al*. Clinical and ultrastructural studies of epiretinal pigmentary deposits after Retinectomy with silicone oil. *Ophthalmology* 2016;123:2595–602.
- Christensen UC, la Cour M. Visual loss after use of intraocular silicone oil associated with thinning of inner retinal layers. *Acta Ophthalmol* 2012;90:733–7.
- Miller JB, Papakostas TD, Vavvas DG. Complications of emulsified silicone oil after retinal detachment repair. *Semin Ophthalmol* 2014;29:312–8.
- Prazeres J, Magalhães O, Lucatto LFA, *et al*. Heavy silicone oil as a long-term endotamponade agent for complicated retinal detachments. *Biomed Res Int* 2014;2014:1–7.
- Schwarzer H, Mazinani B, Plange N, *et al*. Clinical observations and occurrence of complications following heavy silicone oil surgery. *Biomed Res Int* 2014;2014:1–5.
- Koh V, Cheung CY, Wong W-L, *et al*. Prevalence and risk factors of epiretinal membrane in Asian Indians. *Invest Ophthalmol Vis Sci* 2012;53:1018–22.
- Ng CH, Cheung N, Wang JJ, *et al*. Prevalence and risk factors for epiretinal membranes in a multi-ethnic United States population. *Ophthalmology* 2011;118:694–9.
- Xiao W, Chen X, Yan W, *et al*. Prevalence and risk factors of epiretinal membranes: a systematic review and meta-analysis of population-based studies. *BMJ Open* 2017;7:e014644.
- Scheerlinck LM, Schellekens PA, Liem AT, *et al*. Incidence, risk factors, and clinical characteristics of unexplained visual loss after intraocular silicone oil for MACULA-ON retinal detachment. *Retina* 2016;36:342–50.
- Tamaki K, Usui-Ouchi A, Murakami A, *et al*. Fibrocytes and fibrovascular membrane formation in proliferative diabetic retinopathy. *Invest Ophthalmol Vis Sci* 2016;57:4999–5005.
- Kobayashi Y, Yoshida S, Zhou Y, *et al*. Tenascin-C promotes angiogenesis in fibrovascular membranes in eyes with proliferative diabetic retinopathy. *Mol Vis* 2016;22:436–45.
- Li X, Liu X, Guo H, *et al*. The significance of the increased expression of phosphorylated MeCP2 in the membranes from patients with proliferative diabetic retinopathy. *Sci Rep* 2016;6:32850.
- Cheung N, Mitchell P, Wong TY. Diabetic retinopathy. *The Lancet* 2010;376:124–36.
- Wong TY, Sabanayagam C. Strategies to tackle the global burden of diabetic retinopathy: from epidemiology to artificial intelligence. *Ophthalmologica* 2020;243:9–20.
- Lewis H, Burke JM, Abrams GW, *et al*. Perisilicone proliferation after vitrectomy for proliferative vitreoretinopathy. *Ophthalmology* 1988;95:583–91.

- 23 Tano R, Kakurai K, Sakurai T, *et al.* Intravitreal bevacizumab (Avastin) combined with vitrectomy for recurrences of proliferative vitreoretinopathy in von Hippel-Lindau disease. *Acta Ophthalmol* 2012;90:e157–8.
- 24 Schiff W *et al.* Safety and efficacy assessment of chimeric ribozyme to proliferating cell nuclear antigen to prevent recurrence of proliferative vitreoretinopathy. *Arch Ophthalmol* 2007;125:1161–7.
- 25 Chen W, Chen H, Hou P, *et al.* Midterm results of low-dose intravitreal triamcinolone as adjunctive treatment for proliferative vitreoretinopathy. *Retina* 2011;31:1137–42.
- 26 Fernandes-Cunha GM, Saliba JB, Siqueira RC, *et al.* Determination of triamcinolone acetonide in silicone oil and aqueous humor of vitrectomized rabbits' eyes: application for a pharmacokinetic study with intravitreal triamcinolone acetonide injections (Kenalog® 40). *J Pharm Biomed Anal* 2014;89:24–7.
- 27 Azuma K, Ueta T, Eguchi S, *et al.* Effects of internal limiting membrane peeling combined with removal of idiopathic epiretinal membrane: a systematic review of literature and meta-analysis. *Retina* 2017;37:1813–9.
- 28 Fang X-L, Tong Y, Zhou Y-L, *et al.* Internal limiting membrane peeling or not: a systematic review and meta-analysis of idiopathic macular pucker surgery. *Br J Ophthalmol* 2017;101:1535–41.
- 29 Far PM, Yeung SC, Ma PE, *et al.* Effects of internal limiting membrane peel for idiopathic epiretinal membrane surgery: a systematic review of randomized controlled trials. *Am J Ophthalmol* 2021;231:79–87.
- 30 Uemoto R, Yamamoto S, Aoki T, *et al.* Macular configuration determined by optical coherence tomography after idiopathic macular hole surgery with or without internal limiting membrane peeling. *Br J Ophthalmol* 2002;86:1240–2.
- 31 Uemura A, Kanda S, Sakamoto Y, *et al.* Visual field defects after uneventful vitrectomy for epiretinal membrane with indocyanine green-assisted internal limiting membrane peeling. *Am J Ophthalmol* 2003;136:252–7.
- 32 Treumer F, Wacker N, Junge O, *et al.* Foveal structure and thickness of retinal layers long-term after surgical peeling of idiopathic epiretinal membrane. *Invest Ophthalmol Vis Sci* 2011;52:744–50.
- 33 Pichi F, Lembo A, Morara M, *et al.* Early and late inner retinal changes after inner limiting membrane peeling. *Int Ophthalmol* 2014;34:437–46.
- 34 Russo A, Morescalchi F, Gambicorti E, *et al.* Epiretinal membrane removal with FOVEAL-SPARING internal limiting membrane peeling: a pilot study. *Retina* 2019;39:2116–24.
- 35 Coffee RE, Jiang L, Rahman SA. Proliferative vitreoretinopathy: advances in surgical management. *Int Ophthalmol Clin* 2014;54:91–109.
- 36 Gonvers M. Temporary silicone oil tamponade in the management of retinal detachment with proliferative vitreoretinopathy. *Am J Ophthalmol* 1985;100:239–45.
- 37 Semeraro F, Russo A, Morescalchi F, *et al.* Comparative assessment of intraocular inflammation following standard or heavy silicone oil tamponade: a prospective study. *Acta Ophthalmol* 2019;97:e97–102.
- 38 Steel DH, Weir P, James CR. Silicone assisted, argon laser confinement of recurrent proliferative vitreoretinopathy related retinal detachment: a technique to allow silicone oil removal in problem eyes. *Br J Ophthalmol* 1997;81:765–70.
- 39 Yoon YH, Marmor MF. Rapid enhancement of retinal adhesion by laser photocoagulation. *Ophthalmology* 1988;95:1385–8.
- 40 Pacioc-Beja M, Garcia G, Dalma J, *et al.* Epiretinal membrane after laser in situ keratomileusis. *Case Rep Ophthalmol Med* 2013;2013:1–3.
- 41 Zhou C, Qiu Q. 360° versus localized demarcation laser photocoagulation for macular-sparing retinal detachment in silicone oil-filled eyes with undetected breaks: a retrospective, comparative, interventional study. *Lasers Surg Med* 2015;47:792–7.
- 42 Bonnet M, Fleury J, Guenoun S, *et al.* Cryopexy in primary rhegmatogenous retinal detachment: a risk factor for postoperative proliferative vitreoretinopathy? *Graefes Arch Clin Exp Ophthalmol* 1996;234:739–43.
- 43 Girard P, Mimoun G, Karpouzas I, *et al.* Clinical risk factors for proliferative vitreoretinopathy after retinal detachment surgery. *Retina* 1994;14:417–24.
- 44 Wickham L, Bunce C, Wong D, *et al.* Retinal detachment repair by vitrectomy: simplified formulae to estimate the risk of failure. *Br J Ophthalmol* 2011;95:1239–44.
- 45 Gupta D, Ching J, Tomambe PE. Clinically undetected retinal breaks causing retinal detachment: a review of options for management. *Surv Ophthalmol* 2018;63:579–88.
- 46 Sigler EJ, Randolph JC, Calzada JL, *et al.* Anatomical and visual outcomes after two-port pars plana vitrectomy reoperation under silicone oil for epimacular membrane or recurrent retinal detachment. *Retina* 2014;34:1939–44.

Supplementary Table 1. BCVA before and after SO removal in eyes with ERM.

Category	BCVA before SO removal (logMAR)	Final BCVA (logMAR)	<i>p</i>
Total eyes with ERM (n=79)	1.00±0.05	0.50±0.10	<0.001
macula area involved (n=56)	1.20±0.12	1.00±0.05	0.035
macular area non-involved (n=23)	0.75±0.02	0.35±0.15	<0.001
<i>p</i>	0.023	<0.001	

BCVA, best-corrected visual acuity; SO, silicone oil; logMAR, logarithm of the minimum angle of resolution; ERM, epiretinal membrane;