




OPEN ACCESS

Clinical science

Long-term outcomes of deep anterior lamellar versus penetrating keratoplasty for keratoconus

Vincent Michel Borderie ^{1,2}, Cristina Georgeon,^{1,2} Otman Sandali ^{1,2},
N Bouheraoua^{1,2}

► Additional supplemental material is published online only. To view, please visit the journal online (<http://dx.doi.org/10.1136/bjo-2023-324230>).

¹Ophthalmology, Hôpital National des 15-20, Paris, Île-de-France, France

²GRC 32, Sorbonne Université, Paris, France

Correspondence to

Professor Vincent Michel Borderie, Ophthalmology, Hôpital National des 15-20, Paris, Île-de-France, France; vincent.borderie@upmc.fr

Received 13 July 2023

Accepted 3 September 2023

Published Online First

27 October 2023

ABSTRACT

Aims To compare the long-term outcomes of deep anterior lamellar keratoplasty (DALK) with penetrating keratoplasty (PK) in keratoconus.

Methods Retrospective comparative case series (228 DALKs and 274 PKs). A biphasic linear model was used to describe the postoperative outcome of the endothelial cell density (ECD). Visual acuity, specular microscopy, corneal topography and optical coherence tomography findings were recorded.

Results Graft survival of the 502 keratoconus eyes was 96.7 at 10 years and 95.6% at 20 years. Visual acuity improved from 20/378±5.1 lines preoperatively to 20/32±2.1 lines at 30 months. The corneal ECD decreased from 2494±382 cells/mm² to 1521±659 cells/mm² at 10 years. The mean simulated keratometry increased from 44.88±2.54 D at 1 year to 46.60±3.0 D at 3 years. The mean follow-up was 103.4 months for DALKs and 106.1 months for PKs. The cumulated incidence of postoperative ocular hypertension requiring treatment was significantly higher in PKs than in DALKs. The early- and late-phase rates of ECD loss were significantly lower in DALKs than in PKs. These figures in DALKs were 50% of those observed in PKs. The simulated mean keratometry was significantly higher in DALKs than in PKs in the mid but not in the long term. No significant differences in visual acuity were observed between both groups. Manual dissection-DALK featured slower visual recovery than PK and big bubble-DALK, whereas big bubble-DALK and PK featured similar visual recovery.

Conclusions DALK featuring higher endothelial survival and lower risk of postoperative ocular hypertension may be superior to PK when indicated for keratoconus.

WHAT IS ALREADY KNOWN ON THIS TOPIC

⇒ Deep anterior lamellar keratoplasty (DALK) and penetrating keratoplasty (PK) provide high mid-term graft survival and visual recovery in keratoconus eyes. However, major long-term differences between both techniques have not been evidenced.

WHAT THIS STUDY ADDS

⇒ Both techniques provide high 20-year graft survival and good visual recovery. However, DALK features dramatically higher long-term endothelial survival and a lower risk of postoperative ocular hypertension compared with PK.

HOW THIS STUDY MIGHT AFFECT RESEARCH, PRACTICE OR POLICY

⇒ DALK should be preferred to PK for treating keratoconus.

keratoconus patients candidates for transplantation are usually young recipients for whom extended graft survival is expected. Determining whether DALK or PK may offer the best graft survival in the long term and the lowest risk of adverse events is an unmet need.

The objective of the present retrospective single-centre cohort study was to compare the long-term results of deep lamellar anterior keratoplasty with those of PK in keratoconus eyes.

PATIENTS AND METHODS

Study design

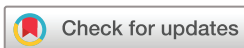The study was a retrospective, comparative case series and was designed from a consecutive series of keratoplasties performed in a single centre. Inclusion criteria were keratoplasty procedures performed by one surgeon (VMB) between January 1993 and December 2021 for optical indication in eyes with keratoconus. As we aimed to produce a real-life study, secondary cases (ie, the fellow eye of a previously grafted patient, n=66) were not excluded from the analysis nor were excluded patients from the learning curves. All patients were prospectively followed after transplantation with no time limit as required by French regulation.

INTRODUCTION

Compared with penetrating keratoplasty (PK), deep anterior lamellar keratoplasty (DALK) presents several advantages that make it currently considered by many corneal surgeons as the first-choice surgical procedure in patients with keratoconus.¹⁻³ Good visual recovery with few postoperative adverse events is a feature of DALK for keratoconus in mid-term studies.⁴ However, the level of evidence is still insufficient to determine which technique may offer better overall outcomes.⁵ Patients with keratoconus may require transplantation during the first three decades of life. Corneal transplantation features good results in young patients with keratoconus even those aged 16 or younger.⁶ As a result,



► 10.1136/bjo-2023-324685



© Author(s) (or their employer(s)) 2024. Re-use permitted under CC BY-NC. No commercial re-use. See rights and permissions. Published by BMJ.

To cite: Borderie VM, Georgeon C, Sandali O, et al. *Br J Ophthalmol* 2024;**108**:10–16.

The study group (DALK group) included all DALK procedures that met the inclusion criteria (n=228). These surgical procedures were performed between September 2002 and December 2021. The control group (PK group) included all PK procedures performed between January 1993 and December 2021 that met the inclusion criteria (n=274). From January 1993 to August 2002, all patients with keratoconus underwent PK. From September 2002 to December 2021, they were considered for DALK except when general anaesthesia was contraindicated and in eyes with major posterior stromal scar after hydrops. Eleven DALK procedures were converted intraoperatively to PK and were assigned to the PK group. No intraoperative complications were recorded. Donor corneas were stored at 31C in an organ culture medium before surgery.⁷ All donor corneas were processed with the same technique during the study period.

Ethics statement

The described research adhered to the tenets of the Declaration of Helsinki. All patients were included in the CCK-CONE cohort study following informed consent. Ethics committee approval was obtained from the Institut National des Données de Santé (#255645) following approval by the CERES (13 February 2020). The data protection process was in agreement with the reference methodology MR-004 and the conformity declaration was approved by the CNIL (23 March 2020). The cohort protocol is available on the Health Data Hub (<https://www.health-data-hub.fr/projets/observatoire-de-la-prise-en-charge-des-patients-presentant-un-keratocone-du-centre-de-0>).

Surgical procedures

All transplants were performed at a single institution. DALK was performed under general anaesthesia.⁸ A first non-penetrating trephination was performed using the Hanna or Moria-One recipient trephines (Moria, Antony, France) in the recipient cornea (trephination depth, 80% of corneal central thickness), and the anterior and middle stroma were removed using a crescent blade. Air was injected into the posterior stroma either before or after anterior stroma removal. In 118 out of 228 cases (52%), air injection induced detachment of Dua's layer (type 1 big bubble) or Descemet membrane (type 2 big bubble). Sodium hyaluronate was then injected into the bubble and the remaining posterior stroma was removed using scissors (big-bubble subgroup). When no big bubble could be obtained after repeated air injection (110 out of 228 cases; 48%), deep posterior stromal dissection was performed using a crescent blade (manual dissection subgroup). Dissection depth was controlled using a slit-lamp or intraoperative optical coherence tomography. Donor tissue used for DALK was trephined from the posterior corneal surface and the Descemet membrane was removed. The PKs were performed using the Hanna or Moria-One recipient trephines (Moria, Antony, France). Graft suturing was performed according to standardised methods in all patients (DALK and PK), with mixed suturing (eight interrupted sutures and a 16-bit running suture) used in most patients. Sutures were removed after at least 18 months. All the patients were treated with topical dexamethasone (1 mg/mL) and neomycin (3400 IU/mL). This treatment was tapered for several months without standardisation of postoperative corticosteroid management. The initial corticosteroid regimen was 1 drop hourly in patients with vascularised corneas and 1 drop every 6 hours in the other patients. Corticosteroid use was never stopped in the former patients, and it was discontinued when all the sutures were removed in the latter.

Recipients and transplantation outcome

High-risk recipients were defined as having a vascularised cornea (>2 quadrants of corneal vascularisation). No eyes had a limbal deficiency. Patients were examined prospectively at 1 and 2 weeks; 1, 3, 6, 9, 12, 18, 24, 30 and 36 months, and 4, 5, 6, 7, 8, 10, 15, 20 and 30 years after surgery.

Manifest refraction (with spectacle-correction), corneal central thickness (ultrasound pachymetry or spectral domain optical coherence tomography), intraocular pressure (IOP; mean of two measurements obtained along the steepest and flattest corneal meridians using the Goldmann applanation tonometer) and graft transparency were recorded at each examination. The criteria for graft failure were irreversible graft stromal oedema and corneal opacification. One, 3, 5, 7, 10, 15 and 20 years after keratoplasty, the graft was evaluated using wide-field specular microscopy (Topcon, Clichy, France) as part of routine care. At each examination, specular corneal topography was recorded using the Orbscan II device (Bausch & Lomb, Utah, USA) or the M39 device (CSO, Firenze, Italy). From November 2009, spectral-domain optical coherence tomography was recorded at each examination using the RTVue device (Optovue, Fremont, California, USA).

Statistical analysis

To describe postoperative endothelial cell loss, the biphasic linear model was fitted to grafts with at least three endothelial cell density (ECD) measurements in time. The endothelial density was described as a mixed piecewise linear model in time with a change in slope 1 year after surgery: $ECD = ECD_0 - (t^*E)$, for $t < 1$ year; $ECD = A - (t^*L)$, for $t > 1$ year; where E is the slope of the early phase endothelial cell loss and L is the slope of the late phase endothelial cell loss. The least squares estimates were used to calculate the coefficients of the model for each patient. Graft survival was assessed with the Kaplan-Meier method and the log-rank test was used to compare the groups of patients.

For statistical analysis of visual acuity, astigmatism, corneal thickness, IOP and ECD, only eyes with clear grafts were included. Visual acuity was converted to LogMAR units before statistical analysis. Changes in quantitative variables between two timeframes were assessed with the paired t-test (ie, only eyes with available data for both timeframes were included). For quantitative variables, the unpaired t-test was used to compare the DALK group with the PK group, and analysis of variance was used to compare the three subgroups. Qualitative variables were analysed using the χ^2 test. As we aimed to show real-life data, we included fellow eyes of patients previously grafted. We analysed our data including either only primary cases (ie, first graft performed for each patient, n=436) or all cases (n=502). Similar comparison results were obtained with primary and overall cases (online supplemental table). Statistical analysis was performed using a software programme (Statistica V.6.1; Stat-Soft France, Maisons-Alfort, France).

RESULTS

Baseline comparison of DALKs with PKs

Table 1 shows the baseline comparison of the DALK group with the PK group. Compared with the PK group, the DALK group featured a significantly higher percentage of eyes with preoperative elevated IOP and higher recipient trephination size. Conversely, no significant differences in the percentage of high-risk recipients, donor and recipient ages, graft trephination size and follow-up time were observed between both groups.

Table 1 Baseline comparison of deep anterior lamellar keratoplasty with penetrating keratoplasty

Variable	DALK group (n=228)	PK group (n=274)	P value
Recipient rejection status			
Low-risk	226 (99.1%)	271 (98.9%)	0.81
High-risk	2 (0.9%)	3 (1.1%)	
Preoperative intraocular pressure			
≤20 mm Hg and no history of glaucoma	220 (96.5%)	273 (99.6%)	0.008
>20 mm Hg and/or history of glaucoma	8 (3.5%)	1 (0.4%)	
Donor trephination size (mm)	8.24 (0.09) (7.50; 8.50)	8.19 (0.19) (7.25; 8.50)	0.24
Recipient trephination size (mm)	8.11 (0.14) (7.50; 8.50)	7.99 (0.12) (7.00; 8.25)	<0.00001
Recipient age (years)	34.2 (11.4) (13; 77)	32.6 (13.2) (10; 77)	0.16
Donor age (years)	70.4 (13.1) (27; 96)	69.9 (13.9) (34; 97)	0.70
Follow-up (months)	103.4 (58.1) (1; 224) (median, 102)	106.1 (94.5) (1; 332) (median, 70)	0.70
Number of eyes examined			
Preoperatively	228 (100.0%)	274 (100.0%)	
At 1 year	220 (96.5%)	256 (93.4%)	
At 3 years	192 (84.2%)	199 (72.6%)	
At 5 years	171 (75.0%)	149 (54.4%)	
At 10 years	88 (38.6%)	94 (34.3%)	
At 15 years	45 (19.7%)	81 (29.6%)	

Numbers (percentages), mean (SD) and range are shown.
DALK, deep anterior lamellar keratoplasty; PK, penetrating keratoplasty.

Natural history of keratoplasty in 502 keratoconus eyes

The average follow-up time was 105±80 months (mean±SD, range 1–332 months). The observed graft survival at 10 and 20 years were 96.7±1.0% (mean±SD) and 95.6±1.4% (figure 1).

The LogMAR visual acuity significantly improved from 1.28 (20/378)±5.1 lines preoperatively to 0.21 (20/32)±2.1 lines at 30 months postoperatively (online supplemental figure), then

remained stable. Refractive astigmatism significantly decreased between 3 and 6 months with selective interrupted suture removal and significantly increased between 7 and 10 years (online supplemental figure). The IOP significantly increased from 11.3±3.3 mm Hg preoperatively to 18.0±5.8 mm Hg at 3 months postoperatively (online supplemental figure 2). It then significantly decreased to 14.8±3.9 mm Hg at 18 months

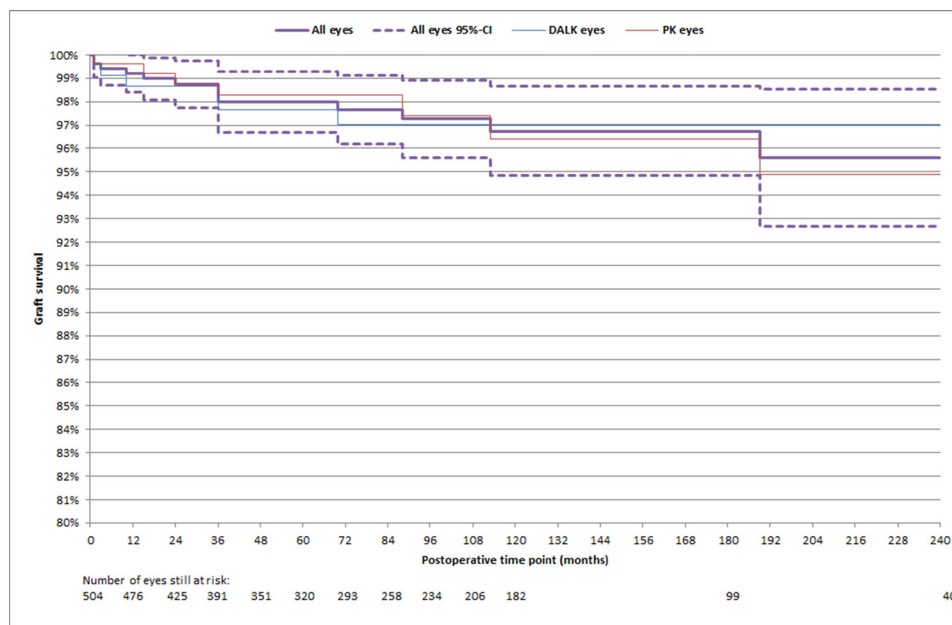


Figure 1 Graft survival in 502 keratoconus eyes. Shown are the graft survival estimate (Kaplan-Meier method) and its 95% CI.

with progressive steroid eye drops tapering and between 4 and 5 years. The central corneal thickness (CCT) significantly decreased between 1 and 6 months and significantly increased between 4 and 5 years and between 7 and 10 years (online supplemental figure). The corneal ECD significantly decreased from 2494 ± 382 cells/mm² preoperatively to 1521 ± 659 cells/mm² at 10 years (online supplemental figure). Changes in ECD between two timeframes were all significant. Among 485 grafts that remained clear at the last examination, the last ECD was at least 500 cells/mm² in 482 eyes (99.4%). The mean simulated keratometry significantly increased from 44.88 ± 2.54 D at 1 year to 46.60 ± 3.0 D at 3 years (online supplemental figure), then remained stable.

Comparison of outcomes of DALKs and PKs

Table 2 shows the observed outcomes in both groups. Graft failure was observed in 6 DALK eyes and 11 PK eyes ($p=0.39$). Six eyes in the DALK group and five in the PK group were regrafted. Those repeat keratoplasties were not included in the study as the indication for transplantation was a failed graft. The observed graft survival at 10/20 years was 96.40/94.9% in the PK group and 97.0/97.0% in the DALK group ($p=0.97$). The cumulated incidence of postoperative ocular hypertension requiring treatment was significantly higher in PKs than in DALKs. No significant differences for other complications including rejection, late endothelial failure, postoperative infections, postoperative trauma, epithelial complications and cataracts were observed between both groups. The ECD was significantly higher in DALKs than in PKs at all postoperative time points (figure 2). The same differences were observed when both DALK subgroups were compared with PKs. In contrast, no significant differences were observed between big-bubble and manual-dissection DALKs.

The mean topographic simulated keratometry was significantly higher in DALKs than in PKs at all postoperative time points except at the last examination (ie, follow-up longer than 10 years). No significant differences in best-corrected visual acuity were observed between both groups at all postoperative time points except at 3 years. Manual dissection-DALKs featured lower visual recovery than PKs and big bubble-DALKs during the first 5 years, whereas big bubble-DALKs and PKs featured similar visual recovery. After 5 years, these differences were no longer significant. No significant differences in refractive astigmatism and IOP were observed between both groups at all postoperative time points except 1 year for IOP. Both groups had no significant differences in CCT at all postoperative time points except at the last examination with PKs featuring higher CCT than DALKs (figure 3). Big bubble-DALKs were thinner than both manual dissection-DALK and PKs. Manual dissection-DALKs were thicker than PKs at 1 and 3 years. This difference was no longer observed from 5 years to the last examination.

Table 3 shows the postoperative endothelial cell loss. The early-phase and late-phase rates of endothelial cell loss were significantly lower in DALKs than in PKs. These figures in DALKs were approximately half of those obtained in PKs. The same differences were observed when both DALK subgroups were compared with PKs, whereas no significant differences were observed between the two DALK subgroups.

DISCUSSION

In the present long-term cohort study, corneal transplantation in keratoconus featured high long-term graft survival (ie, 96.7% and 95.6% at, respectively, 10 and 20 years), satisfying visual

recovery, acceptable post-keratoplasty astigmatism and low incidence of cataract. Follow-up was quite long in our study (on average 105 months) allowing 10- and 20-year survival estimates to be calculated. These high graft survival estimates appear to surpass those reported in registry studies probably due to the monocentric design with a prospective follow-up of patients resulting in fewer cases belonging to the surgeon learning curve and early diagnosis and treatment of postoperative complications. In the 2021/2022 report of the Australian corneal graft registry, the 10-year graft survival in keratoconus eyes with PK was 82% (survival estimate calculated from 2997 transplanted eyes with 393 at risk at 10 years).⁹ Analysis of the Michigan Corneal Transplantation Patient Registry showed an 88%-graft survival at 20 years in keratoconus eyes.¹⁰ In the present study, visual acuity improved progressively during the first 30 months following transplantation as a result of the decrease in graft astigmatism after suture management and, probably, an increase in graft transparency.

Overall, DALKs featured a lower risk of adverse events than PKs in our study. Higher postoperative ECD and lower risk of postoperative ocular hypertension requiring treatment were the main advantages of DALK over PK. Of note, significantly more DALKs featured a preoperative IOP >20 mm Hg and/or a history of glaucoma. However, these advantages did not result in higher long-term graft survival. We previously described a joint regression model fitted on the observed graft survival and postoperative endothelial cell loss to predict very long-term graft survival in eyes with stromal disorders.¹¹ Using this model, the 50-year predicted survival was dramatically higher after DALK than after PK in eyes with stromal disorders. This result is not reached in the present study. However, the mean follow-up of patients (ie, 9 years) is still too short for late endothelial failures to be evidenced after PK. The exact ECD threshold of endothelial decompensation is not precisely known but a 400–500 cell/mm² ECD is often considered as a relevant threshold. Most of our PKs were still above this threshold at the last examination. In our practice, the typical mean (\pm SD) ECD in corneal transplant tissues used for surgery for optical indications during the last three decades was 2360 ± 330 cells/mm².

We observed no differences between DALK and PK in the incidence of rejection and immune failure in the long term as opposed to the short term.¹² Stromal rejection in DALK triggered by interface neovascularisation may occur late after keratoplasty. Epithelial, subepithelial and stromal immune reactions seem to be more common after DALK compared with PK and they may be asymptomatic for months.¹³ Conversely, endothelial rejection is not possible after DALK as the donor endothelium is not transplanted.

CCT in PKs increased with postoperative time whereas it was stable in DALKs after 3 years (figure 3). In addition, PKs were thicker than big-bubble DALKs at all postoperative time points. These findings may result from progressive impairment of the graft endothelial function in PK and weaker function compared with DALK which preserves the recipient endothelium.

No significant differences were observed between DALKs and PKs in visual recovery in the mid-term and long-term after transplantation as reported in other studies.^{14–18} Big-bubble DALKs were thinner than manual dissection DALKs and PKs. Manual dissection DALKs were associated with slower visual recoveries and thicker grafts compared with PKs. After 5 years, differences in visual acuity and CCT were no longer significant. However, the former technique featured better survival of the corneal endothelium compared with the latter at all postoperative time points.

Table 2 Postoperative outcomes after deep anterior lamellar keratoplasty (DALK) and penetrating keratoplasty (PK) in keratoconus eyes

Outcomes	DALK group (n=228)	Big bubble-DALK subgroup (n=118)	Manual dissection-DALK subgroup (n=110)	PK group (n=274)	P value (DALK versus PK)
Postoperative complications					
Immune failure	1 (0.4%)	0 (0.0%)	1 (0.9%)	4 (1.5%)	0.25
At least one rejection episode	38 (16.7%)	17 (14.4%)	21 (19.1%)	52 (19.0%)	0.50
Non-immune failure‡	6 (2.6%)	4 (3.4%)	2 (1.2%)	4 (1.5%)	0.35
Late endothelial failure	0 (0.0%)	0 (0.0%)	0 (0.0%)	3 (1.1%)	0.11
Elevated IOP requiring treatment	27 (11.8%)	11 (9.3%)*	16 (14.6%)	59 (21.5%)	0.004
Infection	4 (1.7%)	3 (2.5%)	1 (0.9%)	7 (2.6%)	0.54
Epithelial complications	5 (2.2%)	3 (2.5%)	2 (1.8%)	2 (0.7%)	0.16
Trauma	2 (0.9%)	1 (0.9%)	1 (0.9%)	9 (3.3%)	0.07
Cataract	7 (3.1%)	3 (2.5%)	4 (3.6%)	6 (2.2%)	0.53
Other postoperative complications§	21 (9.2%)	10 (8.5%)	11 (10.0%)	18 (6.6%)	0.27
15-year graft survival	97.1%	96.1%	98.1%	96.4%	0.97
15-year rejection-free graft survival	71.3%	73.7%	68.1%	67.6%	0.40
15-year ocular hypertension-free graft survival	82.9%	85.7%*	80.1%	73.6%	0.03
15-year infection-free graft survival	97.7%	97.0%	98.5%	97.8%	0.92
15-year trauma-free graft survival	96.4%	97.7%	95.3%	96.6%	0.66
Best spectacle-corrected visual acuity (LogMAR)					
1 year	0.29 (2.4 lines)	0.20 (1.8 lines)*†	0.39 (2.6 lines)*	0.30 (2.7 lines)	0.61
3 years	0.23 (2.2 lines)	0.15 (1.9 lines)†	0.32 (2.3 lines)*	0.18 (2.1 lines)	0.03
5 years	0.21 (2.8 lines)	0.12 (1.8 lines)†	0.29 (3.3 lines)*	0.14 (1.7 lines)	0.06
10 years	0.17 (1.6 lines)	0.13 (3.9 lines)	0.20 (1.5 lines)	0.23 (3.9 lines)	0.21
Last examination	0.19 (1.9 lines)	0.15 (1.5 lines)	0.23 (2.1 lines)	0.22 (3.3 lines)	0.54
Refractive astigmatism (D)					
1 year	3.8 (2.1)	3.9 (2.3)	3.7 (1.9)	3.7 (2.0)	0.57
3 years	3.9 (1.9)	3.5 (2.1)	4.4 (1.6)*†	3.4 (1.8)	0.06
5 years	4.2 (1.9)	4.1 (2.1)	4.3 (1.9)	4.0 (2.1)	0.53
10 years	4.6 (1.9)	4.8 (2.1)	4.5 (1.8)	4.5 (2.1)	0.84
Last examination	4.6 (2.2)	5.0 (2.5)	4.3 (2.2)	5.0 (2.5)	0.37
IOP (mm Hg)					
1 year	15.7 (3.6)	15.9 (3.6)	15.6 (3.4)	14.9 (3.6)	0.04
3 years	14.6 (3.0)	14.9 (3.6)	14.3 (3.0)	14.3 (3.6)	0.50
5 years	14.0 (3.0)	14.1 (2.9)	13.8 (3.0)	13.6 (3.0)	0.43
10 years	13.7 (2.6)	12.7 (2.4)	14.2 (2.6)	13.5 (3.3)	0.71
Last examination	14.2 (3.4)	14.8 (3.9)	13.6 (2.7)	13.3 (3.1)	0.14
Central corneal thickness (µm)					
1 year	541.7 (47.6)	520.3 (37.7)*†	561.2 (47.5)*	537.1 (50.6)	0.41
3 years	559.3 (48.3)	543.9 (47.4)†	574.6 (44.4)*	550.2 (43.9)	0.14
5 years	562.7 (61.3)	544.9 (75.3)†	579.1 (38.8)	564.2 (48.6)	0.86
10 years	564.8 (50.6)	543.9 (47.1)*†	578.0 (48.7)	576.0 (56.8)	0.25
Last examination	562.5 (42.6)	551.1 (39.2)*†	572.7 (43.5)	583.6 (45.0)	0.006
Corneal endothelial cell density (cells/mm²)					
1 year	2372 (471)	2402 (448)*	2342 (494)*	1814 (457)	<0.00001
3 years	2234 (452)	2258 (417)*	2210 (485)*	1490 (490)	<0.00001
5 years	2120 (416)	2131 (335)*	2110 (471)*	1187 (446)	<0.00001
10 years	1966 (397)	1916 (421)*	2010 (373)*	827 (269)	<0.00001
Last examination	2022 (428)	1945 (397)*	2102 (450)*	733 (206)	<0.00001
Topographic simulated mean keratometry (D)					
1 year	44.8 (2.5)	44.9 (2.3)*	44.7 (2.6)*	43.3 (2.5)	0.0009
3 years	47.0 (3.1)	47.1 (3.1)*	46.8 (3.1)*	45.0 (2.0)	0.0003
5 years	47.7 (3.2)	48.0 (3.4)*	47.5 (2.9)*	45.4 (2.1)	0.0003
10 years	47.8 (2.7)	48.1 (2.6)*	47.6 (2.8)*	46.0 (2.3)	0.0002
Last examination	47.9 (3.0)	48.6 (3.3)	47.2 (2.5)	46.6 (2.9)	0.06

Shown are the number (percentage) and mean (SD). The number of eyes with clear graft assessed for complications, visual acuity, refractive astigmatism, IOP, CCT and ECD at 1 year/3 years/5 years/10 years/last exam (ie, >10 years) was, respectively, 405/309/237/143/135. This figure for simulated keratometry was, respectively, 161/190/170/188/94.

*p<0.05 versus PK group.

†p<0.05 versus manual dissection-DALK subgroup.

‡Excluding late endothelial failure.

§Elevated IOP not requiring treatment (n=27), surgical correction of high astigmatism (n=5), double anterior chamber after DALK (n=5), late peripheral hydrops after PK (n=1), significant cornea guttata after PK (n=1). CCT, central corneal thickness; ECD, endothelial cell density; IOP, intraocular pressure.

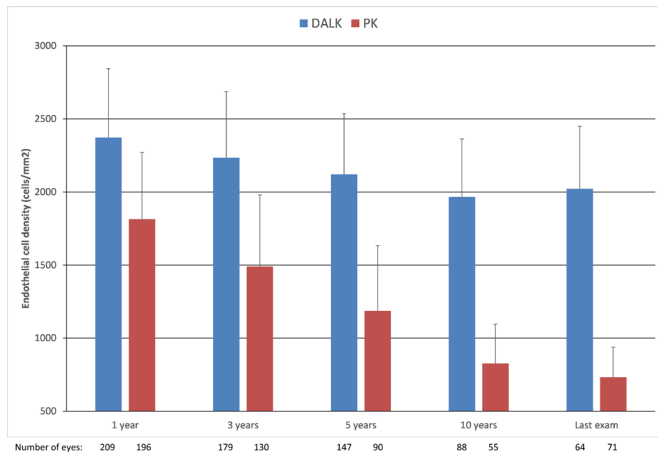


Figure 2 Outcomes of the corneal endothelial cell density (ECD) after deep anterior lamellar keratoplasty (DALK) and penetrating keratoplasty (PK) in keratoconus eyes. Shown is the average ECD (cells/mm²)±SD.

In the present study, DALKs were steeper than PKs during the first 10 years as reported by others.¹⁹ When DALK was introduced in 2002, we used the same recipient/donor trephination sizes for DALK and PK (ie, a 0.25 mm oversized graft) which resulted in steeper DALK grafts compared with PK.²⁰ We further increased our recipient trephination size in DALK (as reflected by the significant difference in recipient trephination size between DALKs and PKs in the present study) to obtain normal postoperative DALK graft curvature. No trends toward graft steepening with postoperative time were observed during the study period except during the first 3 years. Keratoconus progression in the recipient peripheral corneal and graft–host junction was not observed in the present study using corneal topography evolution analysis. Refraction has been shown to stabilise 6 months after complete DALK suture removal in a mid-term follow-up study.²¹ Conversely, keratoconus eyes with 7 mm PK have been shown to present inferior graft and host corneal thinning, and corneal protrusion in the long term (on average 27 years after PK).²² In addition, routine practice shows that some patients with keratoconus who underwent PK 40 or 50 years ago end with steep, still transparent, grafts and severe irregular astigmatism as a result of peripheral corneal thinning. However, those patients often received a small-diameter (ie, 6 or 7 mm) graft. From our data, we cannot determine whether the current standard 8 mm diameter of penetrating and deep anterior lamellar grafts will be large enough to prevent this long-term keratoplasty complication, nor can we determine whether DALKs will differ from PKs regarding this issue. However, large-diameter DALK has been shown to reduce postoperative myopia and astigmatism

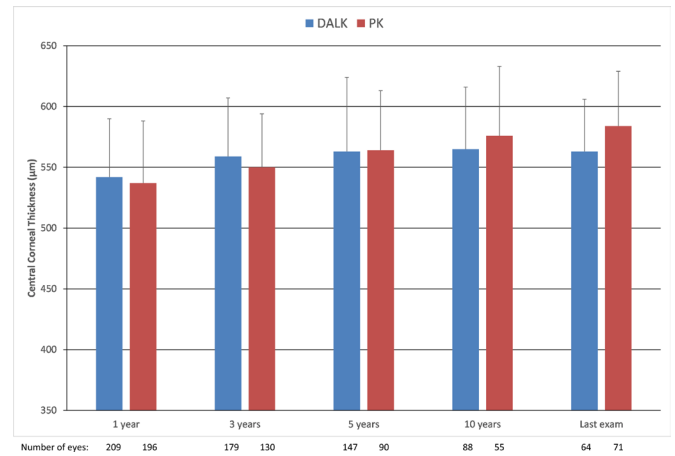


Figure 3 Outcomes of the corneal central thickness (CCT) after deep anterior lamellar keratoplasty (DALK) and penetrating keratoplasty (PK) in keratoconus eyes. Shown is the average CCT (µm)±SD.

and improve visual recovery in keratoconus compared with small-diameter DALK in a randomised trial.²³

Very long follow-up of patients is needed to determine whether the preservation of the recipient corneal endothelium will result in higher graft survival. Current long-term follow-up studies do not show differences in graft survival between DALK and PK.^{8,24} In the present study, follow-up was quite long (on average 9 years with a maximum of 27 years). However, as a low ECD allows graft transparency to be maintained, a 20- to 30-year-mean follow-up with at least some patients followed for 40 or 50 years is probably required to observe enough late endothelial failures after PK and the resulting decrease in graft survival. To our knowledge, such very long-term studies have not currently been reported. Only three late endothelial failure were observed in our study, all in the PK group. Another long-term cohort study reported 1 failure out of 56 PKs for keratoconus.²⁴ Conversely, given the late-phase endothelial cell loss observed in our PKs, it is unlikely that those grafts will be still transparent in the very long term.¹⁷

Compared with PK, DALK provides dramatically higher survival of the corneal endothelium and a lower risk of postoperative elevated IOP in keratoconus eyes. For those reasons, DALK should be preferred to PK for treating keratoconus. However, our data do not allow us to determine whether DALK is finally better than PK in keratoconus and whether PK should be abandoned. The primary endpoint of corneal transplantation in young patients such as patients with keratoconus is graft survival. The mean follow-up of our patients was longer than most previous studies addressing this issue but no differences in

Table 3 Postoperative endothelial cell loss after deep anterior lamellar keratoplasty (DALK) and penetrating keratoplasty (PK) in keratoconus eyes

Outcomes	DALK group (n=228)	Big bubble-DALK subgroup (n=118)	Manual dissection-DALK subgroup (n=110)	PK group (n=274)	P value (DALK versus PK)
Percentage of endothelial cell loss per year					
Early phase	−9.2 (7.5)	−8.6 (6.6)*	−9.7 (6.6)*	−16.9 (12.7)	<0.00001
Late phase	−2.3 (3.0)	−2.2 (2.7)*	−2.3 (3.2)*	−5.5 (4.3)	<0.00001
Endothelial cell loss (cells/mm ²) per year					
Early phase	−214 (460)	−190 (576)*	236 (456)*	−593 (692)	<0.00001
Late phase	−52 (134)	−48 (152)*	−54 (127)*	−100 (126)	<0.00001
Slopes were calculated using the biphasic linear model with a change in slope at 1 year postoperatively. Shown is the mean (SD)					
*p<0.05 versus PK group.					

graft survival between DALKs and PKs could be evidenced. From our data, it seems unlikely that a standard 8 mm penetrating graft could remain transparent in the very long term (ie, 50 years after transplantation) as opposed to small-diameter penetrating grafts that may stay transparent for decades. However, the latter grafts feature high irregular astigmatism that results in poor vision. Conversely, the observed endothelial cell loss in DALK eyes is compatible with the maintenance of a normal endothelial function in the very long term. If the size of the DALK graft is large enough to prevent the occurrence of high irregular astigmatism, this could result in no need for repeat keratoplasty in the long term.

Contributors Conceptualisation: VMB; Data curation: VMB, CG, NB and OS; Formal analysis: VMB and OS; Funding acquisition: VMB; Investigation: VMB, CG, NB and OS; Methodology: VMB and OS; Project administration: VMB; Supervision: VMB; Validation: VMB, NB and OS; Writing—original draft: VMB; Writing—review and editing: VMB, CG, NB and OS. Guarantor: VMB.

Funding Supported by Sorbonne Université, Paris, France.

Competing interests None declared.

Patient consent for publication Not applicable.

Ethics approval This study involves human participants and was approved by Institut National des Données de Santé, #255645. Participants gave informed consent to participate in the study before taking part.

Provenance and peer review Not commissioned; externally peer reviewed.

Data availability statement Data are available upon reasonable request.

Supplemental material This content has been supplied by the author(s). It has not been vetted by BMJ Publishing Group Limited (BMJ) and may not have been peer-reviewed. Any opinions or recommendations discussed are solely those of the author(s) and are not endorsed by BMJ. BMJ disclaims all liability and responsibility arising from any reliance placed on the content. Where the content includes any translated material, BMJ does not warrant the accuracy and reliability of the translations (including but not limited to local regulations, clinical guidelines, terminology, drug names and drug dosages), and is not responsible for any error and/or omissions arising from translation and adaptation or otherwise.

Open access This is an open access article distributed in accordance with the Creative Commons Attribution Non Commercial (CC BY-NC 4.0) license, which permits others to distribute, remix, adapt, build upon this work non-commercially, and license their derivative works on different terms, provided the original work is properly cited, appropriate credit is given, any changes made indicated, and the use is non-commercial. See: <http://creativecommons.org/licenses/by-nc/4.0/>.

ORCID iDs

Vincent Michel Borderie <http://orcid.org/0000-0002-1395-8483>

Otman Sandali <http://orcid.org/0000-0001-9133-5786>

REFERENCES

- Shimmura S, Tsubota K. Deep anterior lamellar keratoplasty. *Curr Opin Ophthalmol* 2006;17:349–55.
- Kawashima M, Kawakita T, Den S, et al. Comparison of deep lamellar keratoplasty and penetrating keratoplasty for lattice and macular corneal dystrophies. *Am J Ophthalmol* 2006;142:304–9.
- Krumeich JH, Knülle A, Krumeich BM. Deep anterior lamellar (DALK) vs. penetrating keratoplasty (PKP): a clinical and statistical analysis. *Klin Monbl Augenheilkd* 2008;225:637–48.
- Romano V, Iovieno A, Parente G, et al. Long-term clinical outcomes of deep anterior lamellar keratoplasty in patients with keratoconus. *Am J Ophthalmol* 2015;159:505–11.
- Keane M, Coster D, Ziaei M, et al. Deep anterior lamellar keratoplasty versus penetrating keratoplasty for treating keratoconus. *Cochrane Database Syst Rev* 2014;CD009700.
- Wajnsztajn D, Hopkinson CL, Larkin DFP, et al. Keratoplasty for keratoconus in young patients: demographics, clinical features, and post-transplant outcomes. *Am J Ophthalmol* 2021;226:68–75.
- Borderie VM, Scheer S, Touzeau O, et al. Donor corneal tissue selection before penetrating keratoplasty. *Br J Ophthalmol* 1998;82:382–8.
- Borderie VM, Werthel A-L, Touzeau O, et al. Comparison of techniques used for removing the recipient stroma in anterior lamellar keratoplasty. *Arch Ophthalmol* 2008;126:31–7.
- Keane MC, Coffey NE, Jones VJ, et al. The Australian corneal graft registry. 2021/22. Adelaide, Australia.
- Niziol LM, Musch DC, Gillespie BW, et al. Long-term outcomes in patients who received a corneal graft for keratoconus between 1980 and 1986. *Am J Ophthalmol* 2013;155:213–9.
- Borderie VM, Sandali O, Bullet J, et al. Long-term results of deep anterior lamellar versus penetrating Keratoplasty. *Ophthalmology* 2012;119:249–55.
- Borderie VM, Guilbert E, Touzeau O, et al. Graft rejection and graft failure after anterior lamellar versus penetrating keratoplasty. *Am J Ophthalmol* 2011;151:1024–29.
- Hos D, Matthaei M, Bock F, et al. Immune reactions after modern lamellar (DALK, DSAEK, DMEK) versus conventional penetrating corneal transplantation. *Prog Retin Eye Res* 2019;73:100768.
- Pedrotti E, Passilongo M, Fasolo A, et al. Refractive outcomes of penetrating keratoplasty and deep anterior lamellar keratoplasty in fellow eyes for keratoconus. *Int Ophthalmol* 2017;37:911–9.
- Zhang Y, Wu S, Yao Y. Long-term comparison of full-bed deep anterior lamellar keratoplasty and penetrating keratoplasty in treating keratoconus. *J Zhejiang Univ Sci B* 2013;14:438–50.
- Amayem AF, Hamdi IM, Hamdi MM. Refractive and visual outcomes of penetrating keratoplasty versus deep anterior lamellar keratoplasty with hydrodissection for treatment of keratoconus. *Cornea* 2013;32:e2–5.
- Williams KA, Keane MC. Outcomes of corneal transplantation in Australia, in an era of lamellar keratoplasty. *Clin Exp Ophthalmol* 2022;50:374–85.
- MacIntyre R, Chow SP, Chan E, et al. Long-term outcomes of deep anterior lamellar keratoplasty versus penetrating keratoplasty in Australian keratoconus patients. *Cornea* 2014;33:6–9.
- Huang T, Hu Y, Gui M, et al. Comparison of refractive outcomes in three corneal transplantation techniques for keratoconus. *Graefes Arch Clin Exp Ophthalmol* 2015;253:1947–53.
- Borderie VM, Georgeon C, Borderie M, et al. Corneal radius of curvature after anterior lamellar versus penetrating keratoplasty. *Graefes Arch Clin Exp Ophthalmol* 2014;252:449–56.
- Javadi MA, Feizi S, Rahmani S, et al. Refractive stability after deep anterior lamellar keratoplasty for keratoconus. *Cornea* 2018;37:1506–10.
- Yoshida J, Toyono T, Shirakawa R, et al. Risk factors and evaluation of keratoconus progression after penetrating keratoplasty with anterior segment optical coherence tomography. *Sci Rep* 2020;10:18594.
- Huang T, Hu Y, Gui M, et al. Large-diameter deep anterior lamellar keratoplasty for keratoconus: visual and refractive outcomes. *Br J Ophthalmol* 2015;99:1196–200.
- Bidaut-Garnier M, Monnet E, Prongué A, et al. Evolution of corneal graft survival over a 30-year period and comparison of surgical techniques: a cohort study. *Am J Ophthalmol* 2016;163:59–69.