




OPEN ACCESS

Clinical science

# Characterisation of ectasia after penetrating keratoplasty in keratoconus eyes using anterior segment optical coherence tomography

Julia M Weller , Lisa Hübner, Friedrich E Kruse, Theofilos Tourtas

Department of Ophthalmology, Friedrich-Alexander-Universität Erlangen-Nürnberg, Erlangen, Germany

**Correspondence to**

Dr Julia M Weller, Department of Ophthalmology, Friedrich-Alexander-Universität Erlangen-Nürnberg, Erlangen 91054, Germany; julia.weller@uk-erlangen.de

Received 3 November 2022

Accepted 2 March 2023

Published Online First

20 March 2023

**ABSTRACT**

**Background/aims** Ectasia of the cornea can occur decades after penetrating keratoplasty (PK), especially in keratoconus eyes. The purpose of this study was to characterise ectasia after PK by morphological findings in anterior segment optical coherence tomography (AS-OCT).

**Methods** In this retrospective, single-centre case series, 50 eyes of 32 patients with a history of PK at an average of  $25 \pm 10$  years earlier were included. The eyes were classified either as ectatic ( $n=35$ ) or as non-ectatic ( $n=15$ ). The main parameters included central corneal thickness (CCT), lowest corneal thickness at the interface (LCTI), anterior chamber depth, graft–host interface angle at the thinnest point and host cornea–iris angle. Furthermore, steep and flat keratometry readings obtained by AS-OCT (CASIA-2, Tomey) and Scheimpflug tomography (Pentacam, Oculus) were assessed. OCT findings were correlated with clinical grading of ectasia.

**Results** There was a highly significant difference in LCTI, graft–host interface angle and anterior chamber depth (in pseudophakic eyes) between the groups. The ratio calculated by the quotient of LCTI divided by CCT was significantly lower in ectatic than non-ectatic eyes ( $p < 0.001$ ). In eyes with an LCTI/CCT ratio of  $\leq 0.7$ , the OR for the occurrence of a clinical detectable ectasia was 2.4 (CI 1.5 to 3.7). Steep keratometry values were significantly higher in ectatic eyes.

**Conclusion** AS-OCT is a helpful tool to recognise and quantify ectasia in post-PK eyes objectively.

**INTRODUCTION**

Keratoconus is one of the most common corneal diseases. Much effort has been made in the early diagnosis of keratoconus and treatment. In 2015, the *Global Delphi Panel of Keratoconus and Ectatic Diseases* has defined the mandatory findings of keratoconus: abnormal posterior elevation, abnormal corneal thickness distribution and clinical non-inflammatory corneal thinning.<sup>1</sup> In this consensus paper, other forms of ectatic disorders as pellucid marginal degeneration, keratoglobus and ectasia after refractive surgery have been described as well.

Ectasia can also occur years or decades after penetrating keratoplasty (PK) in keratoconus eyes. Rarely, ectasia can occur after PK in non-keratoconus eyes as well: In an analysis of 149 eyes with PK 20 years or more ago, ectasia was noted in 39.6% of eyes. Among them, the reason for PK had

**WHAT IS ALREADY KNOWN ON THIS TOPIC**

⇒ Ectasia can occur years or decades after penetrating keratoplasty (PK) in keratoconus eyes. Up to now, the diagnosis of ectasia has been made clinically at the slit lamp. Objective measurements and descriptions of late ectasia after PK are missing.

**WHAT THIS STUDY ADDS**

⇒ Ectatic corneas can be distinguished from non-ectatic corneas by anterior segment optical coherence tomography (AS-OCT). They have a deeper anterior chamber, steeper graft–host interface angle and lower corneal thickness at the interface.

**HOW THIS STUDY MIGHT AFFECT RESEARCH, PRACTICE OR POLICY**

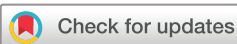⇒ AS-OCT is a useful tool to describe eyes with late ectasia after PK in clinical practice.

been keratoconus in 91.5% and Fuchs' endothelial corneal dystrophy in 8.5% of eyes.<sup>2,3</sup>

The subtype of ectatic disease following PK has been defined poorly in the literature. The terminology of this condition is not consistent: different terms have been used including 'recurrence of keratoconus', 'late ectasia after PK', 'ectasia of the host corneal rim', 'recurrent ectasia in corneal grafts' and 'graft protrusion'.<sup>4–8</sup>

The exact pathomechanism of this condition has not been elucidated. Histological analyses show missing Bowman's layer in the host rim leading to a weakening of the cornea rim.<sup>9</sup> Consequently, the graft bulges forward. A repopulation of the donor stroma by host keratocytes might also lead to a remodelling of the grafted cornea towards keratoconus properties.<sup>5</sup>

Progression of keratoconus has been defined by steepening of the anterior and posterior surface and thinning by the *Global Delphi Panel*.<sup>1</sup> Since the thinning and ectasia is located mainly in the periphery of the cornea in eyes with ectasia after PK, standard corneal keratometric devices as topography or Scheimpflug tomography fail because they display mainly the central and mid-peripheral cornea.<sup>10</sup> Anterior segment optical coherence tomography (AS-OCT) is a relatively new tool which is able to measure corneal curvatures and thickness.



© Author(s) (or their employer(s)) 2024. Re-use permitted under CC BY-NC. No commercial re-use. See rights and permissions. Published by BMJ.

**To cite:** Weller JM, Hübner L, Kruse FE, et al. *Br J Ophthalmol* 2024;**108**:506–512.

In contrast to Scheimpflug tomography, measurements with AS-OCT are also possible in corneas with opacity. A better reliability of measurements of the posterior curvature and corneal thickness using swept-source AS-OCT compared with Scheimpflug tomography has been found in keratoconus eyes.<sup>11</sup>

The purpose of this study was to describe AS-OCT features of eyes with ectasia after PK in order to contribute to a better morphological definition of this condition.

## MATERIALS AND METHODS

### Patients

In this retrospective, single-centre study, 50 eyes of 32 patients (n=22 male, n=10 female) with a history of PK at least 8 years ago, who presented between December 2021 and May 2022, were included. As healthy control group, 30 eyes of 15 age-matched patients were examined. All examinations were performed at the Department of Ophthalmology, Friedrich-Alexander-University Erlangen-Nürnberg (FAU), Erlangen, Germany.

Medical records were analysed regarding age at PK, gender, laterality, interval since PK, diagnosis leading to PK and age at examination. Visual acuity was not assessed since confounders as cataract, dry eye disease or glaucoma were common, and the aim of this study was focused on the morphological characterisation of ectasia.

The study was in adherence to the tenets of the Declaration of Helsinki.

### Measurements

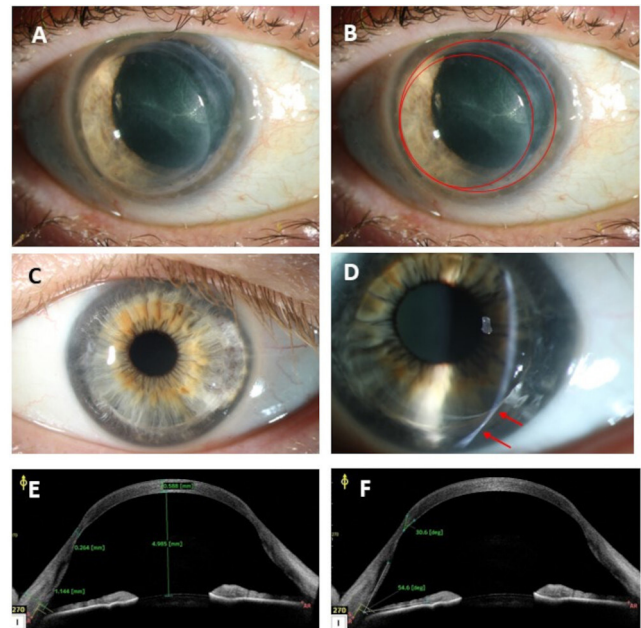
All eyes were assessed using slit lamp examination and classified as ectatic or non-ectatic by two independent corneal experts (TT, FK). Furthermore, presence of corneal oedema as sign for endothelial dysfunction was evaluated.

Clinical signs of ectasia were thinning of the stroma at the graft–host interface, elongation of the interface zone and two visible interface lines: the more central ring corresponds with the superficial graft–host junction, the more peripheral ring with the deep graft–host junction (figure 1).

AS-OCT measurements of the cornea were routinely taken with the device CASIA-2 (Tomey Corporation, Nagoya, Japan) in all patients with previous PK by an independent examiner, who did not know the clinical grading of ectasia. Global scan patterns were chosen to take a 360° visualisation of the entire cornea. The following morphological parameters of the anterior segment were assessed by AS-OCT: central corneal thickness, lowest corneal thickness at the interface (LCTI), corneal thickness at the limbus, anterior chamber (AC) depth (measured from corneal back surface to anterior lens surface), size of graft, graft–host interface angle at the thinnest point, host cornea–iris angle, presence of detachments of Descemet’s membrane.

The location of the most thinned/ectatic area differed between the study subjects. To determine the LCTI, the corneas were screened for thinned/ectatic areas manually by scrolling through the scans over 360° using the software of the OCT device (CASIA-2). The study person who performed this analysis (JMW) did not know the clinical appearance of the cornea at the slit lamp. The assessment whether ectasia was clinically present or not was performed by two independent clinicians at the slit lamp (TT, FK). In eyes without thinning/ectasia and in the control group, the measurement was performed at the 6 o’clock/270° position.

In non-ectatic eyes without thinning at the interface, the LCTI was measured at a line perpendicular to the surface crossing the middle of the interface line. LCTI could not be measured in healthy control eyes because they have no interface. Instead,



**Figure 1** Clinical pictures. Overview photographs of the anterior segment showing: case #1: (A) a severely ectatic cornea; (B) two graft–host interface lines can be seen, which are highlighted in red. The ‘double-ring’ sign can be explained by an elongation of the graft–host interface. The inner ring corresponds with the superficial graft–host junction, the outer ring with the deep junction. Case #2: (C) overview of another ectatic cornea (same as D–F); (D) slit lamp photograph of the same cornea. The upper arrow points to the superficial graft–host junction, the lower arrow to the deep junction. (E) AS-OCT with measurements of AC depth and corneal thickness. (F) AS-OCT: measurement of interface angle and host cornea–iris angle. AC, anterior chamber; AS-OCT, anterior segment optical coherence tomography.

the thickness was measured at a position 4 mm inferior to the corneal centre (corresponding to an 8 mm diameter graft).

Furthermore, the steep and flat keratometry values were measured with AS-OCT (CASIA-2: topography tool, real axial power readings) and Scheimpflug tomography (Pentacam HR; Oculus, Wetzlar, Germany).

### Statistics

The programme SPSS for Windows (V.24, SPSS Inc) was used for statistical analysis of the data. Normal distribution of the data was examined with the Kolmogorov-Smirnov test showing no normal distribution. Mean values and SDs ( $\pm$ SD) are presented for metric values. Mann-Whitney U test (MWU test) was used for comparison of parameters of two groups with a significance level set at 5% ( $p=0.05$ ). Applying the Bonferroni correction for multiple statistical tests, the significance level for this study has to be set at 0.002 (26 single tests).

## RESULTS

### Patients’ characteristics

Fifty eyes with previous PK were included in the study. Mean age at time of examination was  $63 \pm 11$  years. Mean interval between PK and time of AS-OCT examination was  $25 \pm 10$  years. PK had been performed at an average age of  $38 \pm 13$  years. Apart from the 50 post-PK eyes, 30 healthy age-matched eyes were included as control group (mean age:  $62 \pm 14$  years,  $p=0.857$ ).

Thirty per cent of post-PK eyes were assessed as morphologically normal, that is, there were no clinical signs of ectasia

(n=15), 70% as ectatic (n=35, figure 1A–D). In patients with ectasia, the interval since PK was significantly longer than in normal eyes (ectatic eyes: 29±9 years, non-ectatic eyes: 16±7 years, p<0.001). There was no significant difference in the age at time of examination between the two groups (ectatic eyes: 64±10 years, non-ectatic eyes: 61±13 years, p=0.497). Keratoplasty surgery had been performed at a younger age in eyes with ectasia than in eyes without ectasia (45±14 years, p=0.024). However, this difference was not significant after Bonferroni correction for multiple tests.

Eighteen patients (out of 32) had a history of PK in both eyes. Of them, 10 patients had bilateral ectasia, 4 patients unilateral ectasia and 4 patients no ectasia in both eyes.

All but 3 patients had the primary diagnosis of keratoconus as reason for PK. Two patients (four eyes) had been treated with PK for Fuchs endothelial corneal dystrophy (FECD) in both eyes between 13 and 21 years ago, and one eye had PK for corneal scars 10 years ago. Ectasia occurred only in eyes with keratoconus as primary diagnosis.

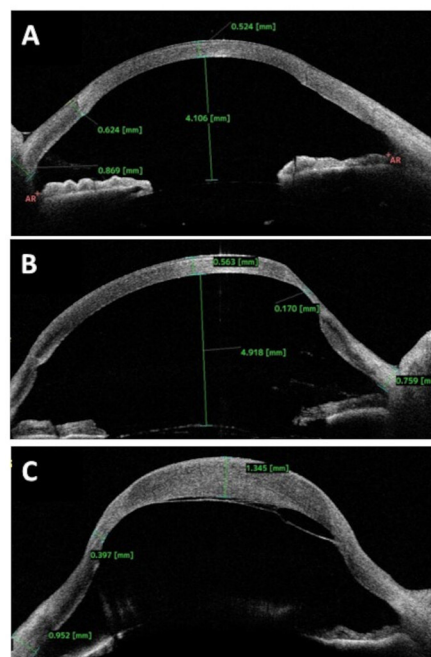
At the time of examination, 60% of eyes (n=30) were phakic and 40% (n=20) pseudophakic.

Six eyes revealed detachment of Descemet’s membrane with overlying stromal oedema at first presentation. These eyes have been described in detail previously by our group.<sup>9</sup> In total, 10 eyes—including the six eyes with detached Descemet’s membrane—had stromal oedema due to endothelial failure or missing contact between Descemet’s membrane and stroma. AS-OCT measurements in these eyes were taken into account after treatment of endothelial failure by endothelial keratoplasty (n=6). In four eyes, treatment of endothelial failure was pending. Therefore, measurements of central corneal thickness (CCT) and LCTI of these four eyes were not included into the statistical analysis.

**AS-OCT—morphometric results**

Regarding all post-PK eyes, mean CCT was 555±39 µm, and mean LCTI was 398±135 µm (n=46, table 1). Morphometric data of both post-PK groups and the control group are shown in table 1. There was a highly significant difference (p<0.001) of LCTI between eyes with ectasia (343±108 µm) and without ectasia (537±89 µm). Representative AS-OCT images are shown in figure 2.

Because of the general variability of CCT, a ratio was calculated by the quotient of LCTI divided by CCT. This ratio was also significantly lower in ectatic eyes than in eyes without ectasia (p<0.001). CCT and thickness at the limbus were not different



**Figure 2** AS-OCT findings (thickness measurements). The OCT findings of exemplary cases are shown: (A) pseudophakic eye 17 years after PK for keratoconus without clinical signs of ectasia (non-ectatic group). The LCTI/CCT ratio is 624 µm/524 µm=1.2. (B) Pseudophakic eye 36 years after PK for keratoconus (ectasia group). The LCTI/CCT ratio is 170 µm/563 µm=0.3. (C) Phakic eye 46 years after PK showing severe ectasia, detached Descemet’s membrane and oedematous graft. The LCTI/CCT ratio was not calculated because of severe oedema biasing the ratio. AS-OCT, anterior segment optical coherence tomography; CCT, central corneal thickness; LCTI, lowest corneal thickness at interface; PK, penetrating keratoplasty.

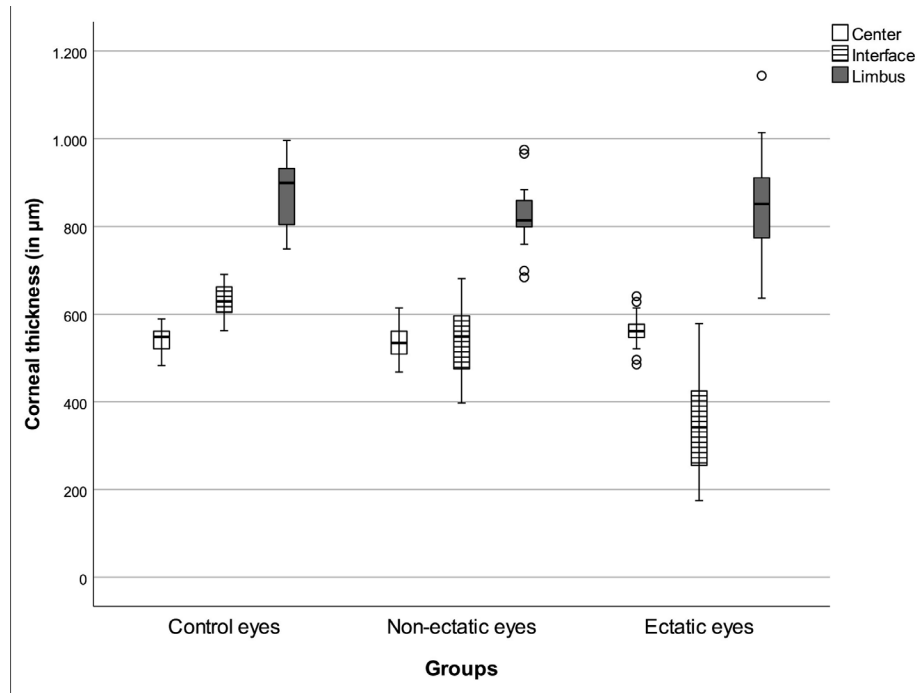
in the three groups (figure 3). In eyes with an LCTI/CCT ratio of ≤0.7, the OR for the occurrence of a clinical detectable ectasia was 2.4 (CI 1.5 to 3.7). The thickness distribution at the centre, at the interface and at the limbus has an hourglass-like form (figure 3).

Apart from thickness measurements, the graft–host interface angle at the thinnest point was measured. The interface line can be detected in AS-OCT scans as delicate oblique line between the host cornea and the graft (figure 4). In normal eyes without ectasia, the interface line runs more perpendicularly (53° ± 11),

**Table 1** Morphometric results—measurements were taken by CASIA-2

	Central corneal thickness (CCT) (in µm)*	Lowest corneal thickness at interface (LCTI) (in µm)*	Ratio LCTI/CCT*	Graft–host interface angle (in degrees)	Angle between host cornea and iris plane (in degrees)	Anterior chamber depth (in mm)	Graft diameter (in mm)	Corneal diameter (in mm)†
Healthy control group (n=30)	539±32	631±36	1.2±0.1	–	39±9	3.1±0.5	–	11.7±0.3
Non-ectatic group (n=15)	536±43	537±89	1.0±0.2	53±11	45±4	3.8±0.6	8.0±0.4	11.8±0.4
Ectasia group (n=35)	563±35	343±108	0.6±0.2	33±7	51±7	4.4±0.8	7.8±0.4	11.8±0.5
P value (MWU between control group and non-ectatic group)	0.574	<0.001	<0.001	–	0.005	<0.001	–	0.359
P value (MWU test between non-ectatic and ectatic group)	0.029	<0.001	<0.001	<0.001	0.009	0.007	0.138	0.420

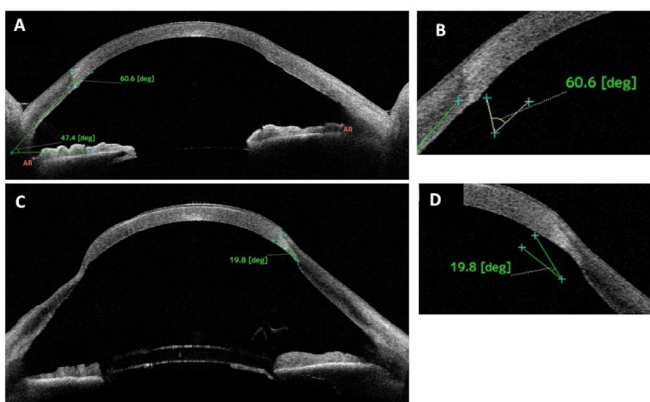
Significant p values (after Bonferroni correction for multiple testing) are marked in bold letters.  
 \*Only eyes without endothelial decompensation of the graft are included in the analysis of CCT (n=76).  
 †White-to-white distance measured by Pentacam Scheimpflug imaging.  
 MWU, Mann-Whitney U test.



**Figure 3** Corneal thickness measurements by OCT. Boxplot showing the distribution of mean corneal thickness at the centre, at the interface and at the limbus in the three groups (control group, non-ectatic group, ectatic group). In eyes with ectasia, there is a pronounced thinning of the cornea at the interface compared with the centre and the limbus. OCT, optical coherence tomography.

whereas in ectatic eyes, the interface has an acute angle ( $33^\circ \pm 7$ ,  $p < 0.001$ ). The elongated interface zone can be seen clinically by two circular interface lines: the inner ring corresponds with the superficial graft–host junction, the outer ring with the deep graft–host junction (figure 1). Histologically, this correlates well with an elongated interface zone.<sup>9</sup>

In ectatic eyes, the cornea becomes thinner and steeper at the periphery: The angle between the host cornea and the iris plane was measured. In ectatic eyes, this angle was higher than in non-ectatic eyes ( $p = 0.009$ , not significant after Bonferroni correction).



**Figure 4** AS-OCT findings (angle measurements). The graft–host interface can be seen as delicate line in the stroma. (A) In an eye without ectasia, the graft–host interface runs rather perpendicular with an angle of  $60.6^\circ$ . (B) In an eye with ectasia, the interface line is elongated with an angle of  $19.8^\circ$ . (C) Enlarged angle measurement of case A. (D) Enlarged angle measurement of case B. AS-OCT, anterior segment optical coherence tomography.

Mean AC depth was  $4.2 \pm 0.8$  mm in the entire cohort, with a borderline significant difference between the groups (table 1). However, since AC depth was significantly deeper in pseudophakic ( $n = 20$ ) compared with phakic ( $n = 30$ ) eyes ( $p < 0.001$ ), these groups were analysed separately: in phakic eyes ( $n = 30$ ), the AC depth was  $4.0 \pm 0.8$  mm in the ectasia group compared with  $3.4 \pm 0.5$  mm in the non-ectatic group ( $p = 0.040$ ). In pseudophakic eyes ( $n = 20$ ), the AC was significantly ( $p < 0.001$ ) deeper in the ectasia group ( $4.9 \pm 0.4$  mm) compared with the non-ectatic group ( $4.2 \pm 0.2$  mm). AC depth was significantly, but weakly correlated with steep K ( $p = 0.017$ ,  $\rho = 0.349$ ).

Since PK had been performed at a mean interval of 25 years before, the surgery reports were not available anymore. Therefore, trephine size was unknown, and graft size was measured by AS-OCT. Mean graft size was  $7.9 \pm 0.4$  mm, and there was no significant difference in graft size between the groups ( $p = 0.289$ ). Mean white-to-white distance (WTW, Pentacam) was  $11.8 \pm 0.4$  mm, without significant difference between the groups. The ratio graft size/WTW distance was  $0.67 \pm 0.03$  and did not differ between ectatic and non-ectatic eyes.

### Keratometry results

Keratometry readings measured by Scheimpflug tomography and optical coherence tomography are shown in table 2. The mean steep keratometry values were significantly different between ectatic and non-ectatic eyes, and between non-ectatic eyes and control eyes, respectively.

### DISCUSSION

In the present study, the purpose was to describe morphological parameters of ectatic corneas after PK using AS-OCT. We found an acute graft–host interface angle, steep keratometry value, deep AC and a stromal thinning at the interface as significant signs of ectasia. A ratio calculated by the relation between the

Table 2 Keratometry results

	Pentacam K flat (in diopters)	Pentacam K steep (in diopters)	Pentacam Cylinder value (in diopters)	CASIA-2 K flat (in diopters)	CASIA-2 K steep (in diopters)	CASIA-2 Cylinder value (in diopters)
Healthy control group (n=30)	42.8±1.2	43.8±1.3	1.0±0.5	41.8±1.1	42.6±1.2	0.8±0.5
Non-ectatic group (n=15)	44.7±2.6	48.8±2.9	4.1±2.1	44.2±3.7	49.0±3.8	4.7±2.1
Ectasia group (n=35)	47.5±6.3	55.4±6.6	7.9±5.5	48.5±6.9	56.2±7.8	7.8±3.9
P value (MWU between control group and non-ectatic group)	0.124	<0.001	<0.001	0.105	<0.001	<0.001
P value (MWU test between non-ectatic and ectatic group)	0.142	<0.001	0.046	0.120	0.007	0.030

Keratometry was measured using Scheimpflug tomography (Pentacam) and anterior segment optical coherence tomography (CASIA-2).  
MWU, Mann-Whitney U test.

thinnest point at the interface and the central corneal thickness was significantly lower in ectatic eyes.

Late ectasia after PK has been poorly defined in the literature. Yoshida *et al*<sup>4</sup> defined ectasia by 'acute hydrops or visible graft protrusion and thinning observed by slit lamp examination', whereas Pramanik *et al*<sup>12</sup> described 'paracentral thinning and Vogt striae' as signs of ectasia/recurrent keratoconus. However, clear morphological criteria or cut-off values to define ectasia have not been developed although this late complication after PK is relatively common. Up to 36% of eyes with a history of PK for keratoconus develop ectasia decades after surgery.<sup>4</sup>

Onset of late ectasia is usually decades following PK.<sup>5 6 12</sup> The interval between PK and examination was significantly longer in eyes with ectasia compared with non-ectatic eyes in our study.

This is remarkable since the underlying disease—keratoconus—is usually less progressive with increasing patients' age. This latency has been explained in the literature by a slow remodelling of the graft by immigrating host keratocytes, which produce abnormal collagen.<sup>13 14</sup> Furthermore, the physiological covering of the graft with epithelium from the host within weeks to months might lead to alterations of the epithelium–stromal interaction and metabolism.<sup>12</sup>

The risk factors for late ectasia remain unclear. In a case series, eye rubbing by scleral lenses has been described as possible risk factor.<sup>15</sup> Sleep apnoea has been found as risk factor for progression of keratoconus.<sup>16</sup> In a study by our group about cases with late detachment of Descemet's membrane, three out of six cases had a history of obstructive sleep apnoea.<sup>9</sup>

Yoshida *et al*<sup>4</sup> analysed risk factors for development of recurrent keratoconus after PK: eyes with recurrent keratoconus had significantly smaller graft diameters and were older at time of last examination. In contrast, there was no difference in graft diameter and occurrence of ectasia in our study. However, the original graft size was unknown and the graft diameter was measured by AS-OCT.

Raecker *et al*<sup>17</sup> compared long-term changes of keratometry readings in eyes with keratoconus and FECD. They found changing values in keratoconus eyes but not in FECD eyes. This finding favours the theory that disease-specific alterations lead to late ectasia in keratoconus eyes instead of surgery-related or suture-related factors as wound slippage. However, it is unknown how many of the cases reported in the literature are true recurrences of keratoconus in the graft or progression of the keratoconus in the peripheral rim.

Histological examinations of explanted failed corneal grafts after PK for keratoconus display different features: Some specimens reported in the literature showed typical signs of keratoconus in the graft itself, that is, disruption of Bowman's layer

and stromal thinning.<sup>5 18</sup> These cases can be considered as true recurrence of keratoconus in the graft and can be explained by either repopulation of the graft by host keratocytes or by an inadvertent transplantation of a graft by a donor with subclinical keratoconus.<sup>18</sup>

Patel *et al*<sup>13</sup> investigated 36 eyes of 25 patients with recurrent keratoconus after PK. In contrast to our patient cohort, they focused on eyes with true recurrence of keratoconus. Histologically, they found typical breaks in Bowman's layer and thinning of the stroma, consistent with keratoconus.

Bourges *et al*<sup>19</sup> described keratoconus-typical histological findings in all 12 analysed corneal buttons 10–28 years after PK for keratoconus: Breaks in Bowman's layer, deposits in the stroma, but no thinning of the stroma (probably due to oedema) were found.

Pramanik *et al*<sup>12</sup> studied the long-term outcomes of PK for keratoconus and reported 6 cases of recurrent keratoconus among 112 eyes, which had either clinically unambiguous signs of keratoconus (Vogt striae) or histologically characteristic findings and 7 cases with suspected recurrence. They calculated a probability rate for recurrent keratoconus of 7% 20 years after PK, and 12% after 25 years, respectively.<sup>12</sup> The authors did not differentiate between recurrence in the graft and an ectatic host rim.<sup>12</sup>

In contrast, Raecker *et al*<sup>17</sup> found no typical histological signs of keratoconus in four excised corneal grafts, which had been treated with repeat PK for recurrent ectasia. They also described a thinning of the host stroma at the graft–host junction as seen in our study.

In a very elaborate examination of an excised corneal button with graft failure after PK for keratoconus using X-ray and electron microscopy, the arrangement, fibre diameter and distribution of collagens within the cornea was investigated by Hayes *et al*.<sup>14</sup> The structural abnormalities they found did not resemble corneas with keratoconus, but were located mainly within the inferior graft–host junction zone.<sup>14</sup> Electron microscopy images revealed a disruption of collagens in all layers in the inferior periphery, but not in the centre.<sup>14</sup> Breaks in Bowman's layer, which are typical for keratoconus, were not found.

Only two of the eyes included in our study has been treated with repeat PK since they had excessive oedema due to Descemet's membrane detachment. We found focal disruptions in Bowman's layer of the graft, but the major alterations were in the host corneal rim with completely missing Bowman's layer and thinned stroma.<sup>9</sup>

In these cases, the focus of the alterations is located in the periphery and the ectasia of the host rim destabilises the graft leading to forward bulging with increasing

astigmatism. This condition should rather be termed ectasia or progressive keratoconus of the host corneal rim rather than ‘recurrence of keratoconus’ since the keratoconus had always been present in the peripheral rim and thus cannot ‘recur’. These findings support the idea that recurrence of keratoconus in the graft should not be confused with ectasia of the host corneal rim.

Interestingly, there was a significant difference of several morphometric and keratometric parameters between the healthy control eyes and the post-PK eyes classified clinically as non-ectatic. This could be explained either by the steep and thinned corneal recipient rim in keratoconus eyes or by early manifestation of ectasia, which is clinically not yet visible.

Ectasia after PK is difficult to treat since the periphery of the cornea is thin and the adaptation of a new graft is difficult. The *Global Delphi Panel of Keratoconus and Ectatic Diseases* stated that verbal guidance for patients not to rub their eyes is one important non-surgical measure in patients with keratoconus or ectatic diseases.<sup>1</sup> In terms of late ectasia after PK, avoidance of mechanical stress to the graft and the host rim by rubbing should be counselled as well. Patients might believe that they have been cured from keratoconus after PK, but they should be told that the disease persists in the host rim and can progress.

Several therapeutical options are possible: scleral lenses, repeat PK, wedge resections, peripheral anterior lamellar keratoplasty and deep anterior lamellar keratoplasty have been described and discussed in the literature.<sup>20–23</sup>

Corneal cross-linking has become a widespread method to halt progression of keratoconus.<sup>24</sup> Cross-linking of the host might contribute to a stabilisation of the peripheral rim.<sup>7</sup> Our study might help to describe morphological characteristics of host ectasia in AS-OCT. Progression of these AS-OCT findings over time might be a hint to find candidates requiring cross-linking to avoid increasing ectasia with astigmatism or complications as Descemet’s membrane detachment.

The study is limited by the relatively small sample size and the manual reading of AS-OCT measurements. Up to now, there are no automatic tools to analyse the parameters included, but the examiners searched manually by scrolling through the scans over 360°. Automatic segmentation and measurements by the software of the AS-OCT device are desirable.

Furthermore, the value of the morphological characterisation of ectatic corneas using AS-OCT is limited insofar as the decision whether to perform surgical or other intervention is based on reduced visual function rather than altered corneal morphology. Since objective and subjective measurements of refraction might prove to be difficult in ectatic eyes, AS-OCT measurements could serve as surrogate markers for progressive ectasia over time, but should not be used for surgical decision-making. Further studies to investigate progression of ectasia longitudinally in the course of several years, as well as correlation analyses between visual dysfunction and morphological alterations are desirable in the future.

In conclusion, typical AS-OCT findings in late ectasia after PK for keratoconus have been described in this study. The parameters may help to recognise and quantify ectasia in post-PK eyes objectively.

**Correction notice** The licence for this paper has been updated to Open Access since it was first published.

**Contributors** JMW, LH, FK and TT drafted the conception of the work together. The OCT data were obtained by JMW and LH. FK and TT assessed the patients clinically for signs of ectasia and interpreted the findings. JMW performed the data analysis and wrote the manuscript. LH, FK and TT controlled the data and revised the manuscript thoroughly. All authors approved the submitted version of the manuscript and agreed to be accountable for all aspects of the work in ensuring that questions related to the accuracy and integrity of any part of the work are appropriately investigated and resolved.

**Funding** The authors have not declared a specific grant for this research from any funding agency in the public, commercial or not-for-profit sectors.

**Competing interests** None declared.

**Patient consent for publication** Not applicable.

**Ethics approval** This study involves human participants and was approved by Institutional Review Board (IRB)/Ethics Committee of the Friedrich-Alexander University Erlangen-Nürnberg (number 22-391-Br). Participants gave informed consent to participate in the study before taking part.

**Provenance and peer review** Not commissioned; externally peer reviewed.

**Data availability statement** All data relevant to the study are included in the article or uploaded as supplementary information.

**Open access** This is an open access article distributed in accordance with the Creative Commons Attribution Non Commercial (CC BY-NC 4.0) license, which permits others to distribute, remix, adapt, build upon this work non-commercially, and license their derivative works on different terms, provided the original work is properly cited, appropriate credit is given, any changes made indicated, and the use is non-commercial. See: <http://creativecommons.org/licenses/by-nc/4.0/>.

#### ORCID iD

Julia M Weller <http://orcid.org/0000-0003-4805-4748>

#### REFERENCES

- Gomes JAP, Tan D, Rapuano CJ, *et al*. Global consensus on keratoconus and ectatic diseases. *Cornea* 2015;34:359–69.
- Felipe AF, Hammersmith KM, Nottage JM, *et al*. Indications, visual outcome, and ectasia in clear corneal transplants 20 years old or more. *Cornea* 2013;32:602–7.
- Moramarcó A, Gardini L, Iannetta D, *et al*. Post penetrating keratoplasty ectasia: incidence, risk factors, clinical features, and treatment options. *J Clin Med* 2022;11:2678.
- Yoshida J, Murata H, Miyai T, *et al*. Characteristics and risk factors of recurrent keratoconus over the long term after penetrating keratoplasty. *Graefes Arch Clin Exp Ophthalmol* 2018;256:2377–83.
- Bechrakis N, Blom ML, Stark WJ, *et al*. Recurrent keratoconus. *Cornea* 1994;13:73–7.
- Kit V, Kriman J, Vasquez-Perez A, *et al*. Descemet membrane detachment after penetrating keratoplasty for keratoconus. *Cornea* 2020;39:1315–20.
- Malbran ES, Price FW Jr, Argañaraz Olivero JE, *et al*. Peripheral reconstructive lamellar keratoplasty for late ectasia after penetrating keratoplasty in keratoconus eyes. *Cornea* 2019;38:1377–81.
- Patel SV, Hodge DO, Treichel EJ, *et al*. Predicting the prognosis of Fuchs endothelial corneal dystrophy by using scheinpluf tomography. *Ophthalmology* 2020;127:315–23.
- Weller JM, Kruse FE, Schloetzer-Schrehardt U, *et al*. Management of late descemet’s membrane detachment after penetrating keratoplasty in keratoconus. *Cornea* 2022;41:1503–11.
- Oatts JT, Keenan JD, Mannis T, *et al*. Multimodal assessment of corneal thinning using optical coherence tomography, scheinpluf imaging, pachymetry, and slit-lamp examination. *Cornea* 2017;36:425–30.
- Chan TCY, Biswas S, Yu M, *et al*. Comparison of corneal measurements in keratoconus using swept-source optical coherence tomography and combined placido-scheinpluf imaging. *Acta Ophthalmol* 2017;95:e486–94.
- Pramanik S, Musch DC, Sutphin JE, *et al*. Extended long-term outcomes of penetrating keratoplasty for keratoconus. *Ophthalmology* 2006;113:1633–8.
- Patel SV, Malta JB, Banitt MR, *et al*. Recurrent ectasia in corneal grafts and outcomes of repeat keratoplasty for keratoconus. *Br J Ophthalmol* 2009;93:191–7.
- Hayes S, Young R, Boote C, *et al*. A structural investigation of corneal graft failure in suspected recurrent keratoconus. *Eye (Lond)* 2010;24:728–34.
- Murillo SE, Shariff A, Lass JH, *et al*. Acute corneal edema decades after penetrating keratoplasty for keratoconus in eyes wearing scleral contact lenses. *Cont Lens Anterior Eye* 2021;44:108–14.
- Pellegrini M, Bernabei F, Friehmann A, *et al*. Obstructive sleep apnea and keratoconus: a systematic review and meta-analysis. *Optom Vis Sci* 2020;97:9–14.
- Raecker ME, Erie JC, Patel SV, *et al*. Long-term keratometric changes after penetrating keratoplasty for keratoconus and Fuchs endothelial dystrophy. *Am J Ophthalmol* 2009;147:227–33.

- 18 Duisdieker V, Loeffler KU, Holz FG, *et al.* Corneal graft failure? *Ophthalmologie* 2016;113:955–6.
- 19 Bourges J-L, Savoldelli M, Dighiero P, *et al.* Recurrence of keratoconus characteristics: a clinical and histologic follow-up analysis of donor grafts. *Ophthalmology* 2003;110:1920–5.
- 20 Pullum K, Buckley R. Therapeutic and ocular surface indications for scleral contact lenses. *Ocul Surf* 2007;5:40–8.
- 21 Lake D, Hamada S, Khan S, *et al.* Deep anterior lamellar keratoplasty over penetrating keratoplasty for host rim thinning and ectasia. *Cornea* 2009;28:489–92.
- 22 Ilari L, Daya SM. Corneal wedge resection to treat progressive keratoconus in the host cornea after penetrating keratoplasty. *J Cataract Refract Surg* 2003;29:395–401.
- 23 de la Paz MF, Sibila GR, Montenegro G, *et al.* Wedge resection for high astigmatism after penetrating keratoplasty for keratoconus: refractive and histopathologic changes. *Cornea* 2010;29:595–600.
- 24 Nath S, Shen C, Koziarz A, *et al.* Transepithelial versus epithelium-off corneal collagen cross-linking for corneal ectasia: a systematic review and meta-analysis. *Ophthalmology* 2021;128:1150–60.