

Conclusions

Whilst this series of cases is too small to allow of any final opinion I think it may fairly justify the following conclusions:

1. That in diathermy we have a method of cauterization for the treatment of retinal detachment preferable to the thermo-cautery used by Gonin or the solid caustic potash used by Guist. Further, the technical difficulties are considerably less than in the latter operation.

2. Cases where no hole can be found and those in which a previous operation for detachment, of any type, has been done, offer small hope of success.

3. The age of the patient is of small importance but the prognosis is much less favourable when the symptoms of detachment are of long standing.

4. Finally, as might be expected, almost all cases showing inflammatory signs, post-cortical lens changes, gross vitreous opacities, and hypotension do badly, while those with a relatively clear vitreous, discrete hole or holes, and a normal tension, are the most favourable.

A new diathermy apparatus has now been installed at Moorfields to replace that used in this series of cases. This machine, which was supplied by Messrs. John Weiss & Co., has been specially made for this operation. It generates a diathermy current of low frequency and has a milliamperemeter which gives rapid readings up to 100 milliamperes. I have had no practical experience with it but I understand that, using a current of approximately 60 milliamperes, results have been very encouraging.

I would like to express to the Honorary Staff of Moorfields Eye Hospital my gratitude for their permission to publish these cases.

THE HISTOLOGICAL APPEARANCES OF AN EYE SUCCESSFULLY TREATED BY DIATHERMY FOR RETINAL DETACHMENT. FATAL TERMINATION FROM PULMONARY THROMBOSIS ON THE NINETEENTH DAY AFTER OPERATION

BY

H. B. STALLARD

LONDON

THE opportunities for histological examination of human eyes subjected to the surgical treatment of retinal detachment are rare. Gonin's cauterization of retinal tears has been succeeded by Guist's multiple trephines and caustic applications and now Larsson's

diathermy is under trial. This brief report concerns a patient treated in the last manner. The eye was obtained at post-mortem 19 days after operation.

Clinical Notes

J. H., aged 74 years, was admitted to St. Thomas's Hospital under the care of Mr. P. G. Doyne, on September 9, 1932, with defective right vision of a few days' duration. A large retinal detachment was present in the upper temporal quadrant with a tear in the 10 o'clock meridian between the equator and ora serrata. The retina of the left eye had been detached some years before.

On September 21, 1932, Mr. Doyne operated under local anaesthesia using a modified Larsson's technique. Diathermy applications were made to the sclera in the upper temporal quadrant of the globe between the equator and ora serrata and finally a puncture was made with the electro-cautery at the assumed site of the retinal tear.

During the fortnight after operation the retina became completely re-apposed and a few scattered white spots were seen at the site of the former detachment. On the 13th night after operation the patient had a small pulmonary infarct at the right base and

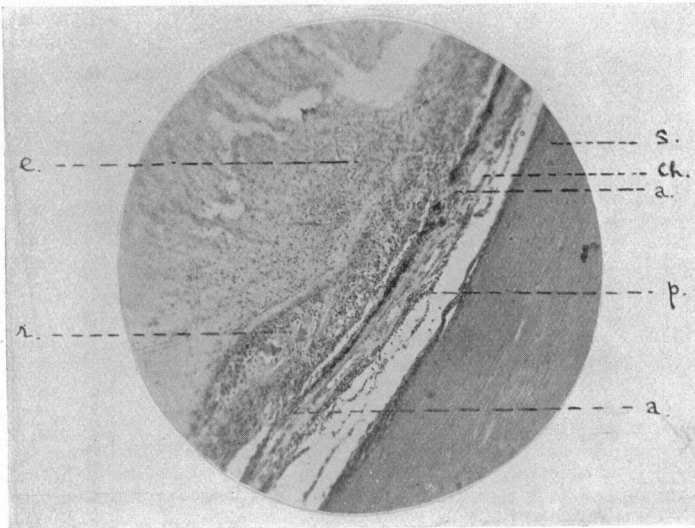


FIG. 1.

s. Sclera. *Ch.* Choroid. *r.* Retina. *a.a.* Adhesions between choroid and retina. *p.* Plasma cells and lymphocytes in the choroid. *e* Exudate, fibrin and polymorphonuclear leucocytes in the vitreous.

on the 19th day he died, 20 minutes after an extensive pulmonary thrombosis.

At post-mortem the whole pulmonary vascular system and also the iliac and femoral vessels were filled with ante-mortem clot. The right eye was removed through the roof of the orbit, fixed in Zenker's solution and serial sections cut through the site treated by diathermy.

Pathological Report

The sclera, at the points touched by the diathermy, shows a zone of hyaline degeneration staining a sherry-brown colour with haematoxylin and eosin for about one-eighth mm. in depth. Nowhere was there any considerable tissue loss, serious damage or necrosis.

The choroid beneath the site treated by diathermy presents aggregations of lymphocytes, plasma cells and a few giant cells.

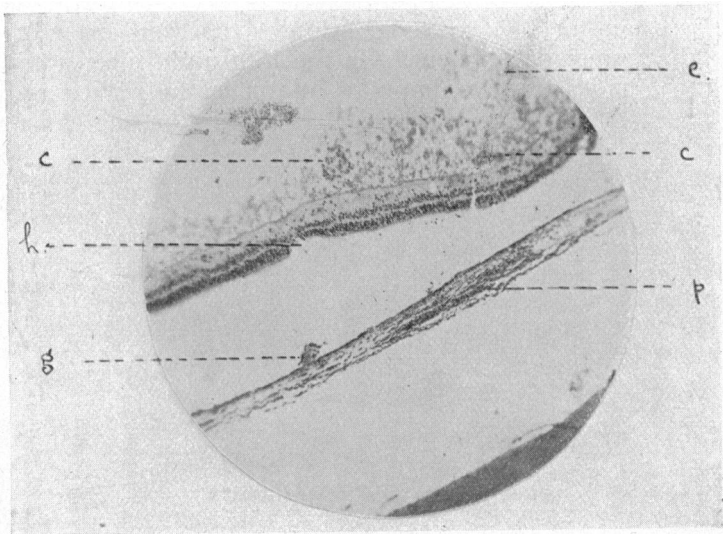


FIG. 2.

The separation of the retina from the choroid and the choroid from the sclera is an artefact. The bud of granulation tissue *g* was adherent to the outer layers of the retina and the site of this is represented by a gap in the retina at *h*.

e. Granular exudate in the vitreous. *c.c.* Clumps of large mononuclear cells, polymorphs and lymphocytes. *g*. Bud of granulation tissue herniating through Bruch's membrane and the retinal pigment epithelium. *p*. Infiltration of the choroid by plasma cells and lymphocytes. *h*. Gap in the outer layers of the retina where a bud of granulation tissue from the choroid was adherent.

Small clumps of inflammatory cells have burst through Bruch's membrane and the retinal pigment epithelial layer, and these assist in forming adhesions between the choroid and retina, at which points fibroblasts are in evidence (see Figs. 1 and 2).

The inflammatory response has extended forwards into the ciliary body and iris, and the non-pigmented layer of ciliary epithelium has proliferated excessively.

Fibroblasts are present in the circum-lental space.

The retina shows degeneration of the rod and cone layer throughout the detached area, and fibroblasts and plasma cells infiltrate its disorganized structure.

Clumps of large mononuclear leucocytes, polymorphs and lymphocytes are present on the hyaloid membrane and in the adjacent vitreous (see Fig. 2).

The vitreous is drawn forward and is adherent to the retina and pars plana of the ciliary body at and near the site of the diathermy application. Exudate, polymorphonuclear leucocytes and strands of fibrin are present in it.

Conclusion

The histological picture induced by the application of diathermy to the sclera in the treatment of retinal detachment is that of a localized uveitis. Buds of granulation tissue herniating through Bruch's membrane play an important part as the grappling irons that secure the detached retina when it has come alongside the choroid after the sub-retinal fluid has been drained. These buds of granulation tissue contain fibroblasts, the precursors of fibrous tissue. Repair is eventually perfected by choroido-retinal fibrous tissue adhesions.

It is evident from this specimen that diathermy applied near the ora serrata is liable to induce a cyclitis, and the amount of fibrous tissue formed in the circum-lental space prophesies more remote complications to follow.

I thank Mr. P. G. Doyne for sending me the specimen and for permission to publish this case, and his house surgeon, Mr. H. Ridley, for supplying me with the clinical notes.

