

## COMMUNICATIONS

### HYALINE INFILTRATION OF THE EYELID\*

BY

NORMAN ASHTON AND ANTOINE REY

*From the Department of Pathology, Institute of Ophthalmology, London,  
and Curepipe, Mauritius*

THERE is a rare type of infiltration of the conjunctiva and eyelid usually described under the generic heading of "hyaline, amyloid, and colloid degeneration"; before adding a further case to the literature it would appear desirable to examine the above terms and to attempt to define them in the light of modern knowledge.

#### DEFINITIONS

The term "hyaline degeneration", first employed by von Recklinghausen (1883), denotes a physical state rather than a chemical composition. "Hyalin" includes a heterogeneous group of substances which share the properties of being translucent, refractile, and structureless (Gk, *hyalos*—glass). They stain readily with acid dyes, are resistant to strong acids and alkalis, and are all of a protein nature. The term is applicable to such apparently unrelated conditions as the arterial sub-endothelial thickening of arteriosclerosis, scar tissue, stromal degeneration in tumours, the degenerative changes of the islets of the diabetic pancreas, and the corpora amylacea of the brain and prostate. It is clear that this wide term should also include "amyloid" (Gk, *amylon*—starch, *eidos*—form), a hyaline substance as defined above which is only entitled to a special name on account of its characteristic anatomical distribution, its typical staining reactions, and the fact that it is the only one of these substances having a known chemical composition.

It is now generally agreed that amyloid is a glyco-protein, in which the carbohydrate ester, chondroitin sulphuric acid, has become attached to a globulin. It is probable, however, that its chemical composition varies, for the staining reactions are by no means constant. Indeed, Raehlmann (1881, 1882) and Kubli (1881) regarded hyalin as the precursor of amyloid; others, who distinguish strongly between the two, admit that they form related although independent end-products of kindred processes (Duke-Elder, 1938). Schmiedeberg (1920) also considers hyalin to represent a transition

---

\* Received for publication November 13, 1949.

stage from albumen to amyloid-albumen; he explains the variable staining reactions as follows:

methyl violet staining is a property of the amyloid as a whole, whereas staining with iodine and sulphuric acid is related to the fraction containing chondroitin sulphuric acid; if this latter substance is absent, no iodine staining results.

Klebs gave the name "achromatic amyloid" to deposits which give neither of these staining reactions; a type which appears indistinguishable from hyalin. The two infiltrations of hyalin and amyloid often present a very similar pathological picture, as may be seen, for instance, in the glomerular changes of amyloidosis and Kimmelstiel-Wilson's disease.

The term "colloid" (Gk, *kolla*—glue) used in this connection represents another attempt to describe the physical properties of the deposits, which are already fully covered by the adjective "hyaline". Unfortunately its use implies a protein known to be differently constituted and most pathologists are now agreed that "colloid" should be reserved for the glue-like substance of the thyroid secretion. Herbert (1902) was responsible for introducing the term "colloid degeneration of the conjunctiva", firstly because he was under the erroneous impression that the word hyalin was reserved by pathologists for small refractile spheres, such as corpora amylacea, secondly because he considered colloid more nearly suggested an origin from normal collagen (from which he thought it to originate), and thirdly because it brought the condition into line with the rare disease of colloid degeneration of the skin described by Unna who named the deposits "collacin". However, we have no certain knowledge of the origin of these substances, and, apart from amyloid, even less information about their chemical structure; no purpose is to be served by applying to them a variety of names, based upon their appearances or supposed source, and the practice has also led to considerable confusion in the literature. The terms "fibrous, myxomatous, and mucoid degeneration" have also been used; these are obviously inappropriate and need not concern us further.

With the possible exception of Zenker's degeneration of voluntary muscle, the microscopical examination of tissues affected with both hyaline and amyloid degeneration, shows that the material is situated exclusively extra-cellularly, and, as Wright (1950) has pointed out, the use of the term "degeneration", which should be restricted to disorders of an intra-cellular kind, is undesirable in the interests of consistent terminology. Schmidt (1904) has also pointed out that the process is one of infiltration and not of transformation.

We propose, therefore, to speak of "hyaline infiltration of the conjunctiva and eyelid" and to regard amyloid infiltration as a particular variety of this condition.

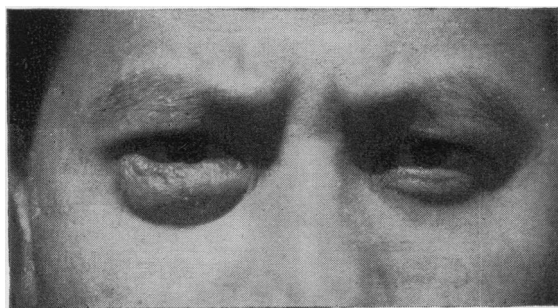


FIG. 1.—Clinical photograph showing extent of tumour in right lower lid.

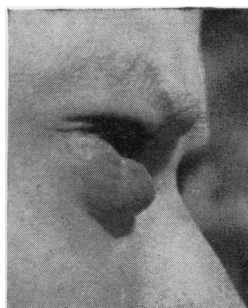

FIG. 2.—Clinical photograph of swelling bulging forward in right lower lid.

#### CASE REPORT

**CLINICAL HISTORY.**—The patient, a male aged 22, was born of Chinese parents in Siam. When seen for the first time on February 25, 1943, he complained of a swollen right lower lid. There was no pain or irritation. On examination two small tumours the size of peas were visible in the thickness of the lid. A diagnosis of Meibomian cysts was made and extirpation advised, but the patient did not keep the appointment. Five years later, on June 15, 1948, he returned with a cartilagenous induration of the lid which bulged forward considerably (Figs 1 and 2). The tumour was imbedded in the whole thickness of the tissues; it was irregular, granular, and adherent to the conjunctiva. A fold of the neo-formation occupied the inner side of the lower fornix; its surface was smooth and its upper border free from adhesions to the eyeball or lid. The mass protruded between the globe and lid, its base being intimately connected with the deeper structures in the lower fornix. Irritation was still absent and the movements of the eye were normal. The pre-auricular gland was not enlarged and the cornea and inner structures of the eye were normal.

There was no evidence of trachoma and no history of previous eye disease. His general condition was healthy.

The tumour was excised on October 26, 1948. An incision was made in the skin of the lid, 2 mm. from the ciliary margin. The mass was removed to the greatest possible extent but the intimate connections with the conjunctiva rendered this difficult and a small perforation ensued. The tissues were found to be diffusely infiltrated and no clearly defined boundary could be found. The lid was sutured and recovery was uneventful. Two small lumps of the tumour remained in the inner and outer canthi; they were treated by diathermo-coagulation 15 days later and disappeared.

The patient was last seen on November 9, 1950. A slight thickening of the lid remained and some strands of cicatricial tissue extended from the lid to the bulbar conjunctiva but the movements were not impaired.

Dr. Cheng-Hin, Government Pathologist, Mauritius, found the Kahn test negative and the blood sedimentation rate and a complete blood count normal. No parasites or ova were found in the stools.

**PATHOLOGY.**—The tissue removed at operation consisted of a hard irregular mass, measuring 23 x 14 x 15 mm. The central portion was removed for section and the cut surface showed the mass to consist of an aggregation of brownish translucent irregular nodules resembling resin.

**Sections.**—Situated immediately beneath a normal conjunctival epithelium there is a diffuse non-encapsulated tumour consisting of

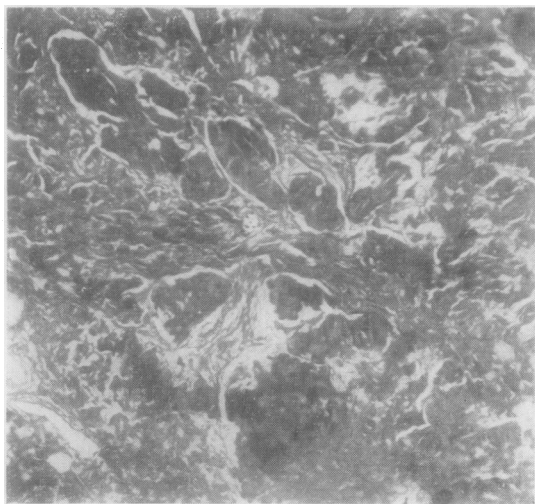


FIG. 3.—General view of histology of tumour. The tissue is infiltrated with elliptical and roughly circular hyaline masses separated by compressed fibrous tissue. Masson stain  $\times 44$ .

elliptical and roughly circular hyaline eosinophilic masses of varying size, separated by strands of compressed fibrous tissue in which chronic inflammatory cells may be seen (Fig. 3). Some of the smaller masses are closely related to blood vessels and in some areas the hyaline material is deposited in the vessel walls, transforming them into broad hyaline rings which, partially or completely, obliterate the lumina (Fig. 4). The hyaline globules have fused together to form large irregular masses within which

lymphocytes, plasma cells, and sebaceous glands are trapped and isolated; in these areas no relation to a vessel wall may be traced. Many of the hyaline blocks are well defined and show lamination (Fig. 5) and central calcification (Fig. 6); those which lie separate in the stroma are seen to be encapsulated by a condensation in the surrounding tissue. One mass was encircled with foreign-body giant cells. The picture suggests a deposition of hyalin within and without the blood-vessel walls; there is nothing in the sections to indicate an origin from connective-tissue cells.

#### *Staining Reactions of Hyaline Masses:*

<i>Haematoxylin and eosin</i>	...	Pink with eosin
<i>Van Gieson</i> ...	...	Yellow—intervening tissue red
<i>Iodine reaction</i>	...	Negative for amyloid
<i>Iodine and sulphuric acid</i>	...	Negative for amyloid
<i>Methyl violet</i>	...	Negative for amyloid
<i>Congo red</i>	...	Negative for amyloid
<i>Methylene blue</i>	...	No selective staining
<i>Crystal violet</i>	...	No selective staining
<i>Mallory triple stain</i>	...	Hyaline substance blue—tissue pink
<i>Phloxine-tartrazine</i>	...	Hyaline masses slate grey—connective tissue yellow
<i>PAS (McManus)</i>	...	Masses pink—faintly positive
<i>Toluidine blue</i>	...	Metachromatic staining of the masses

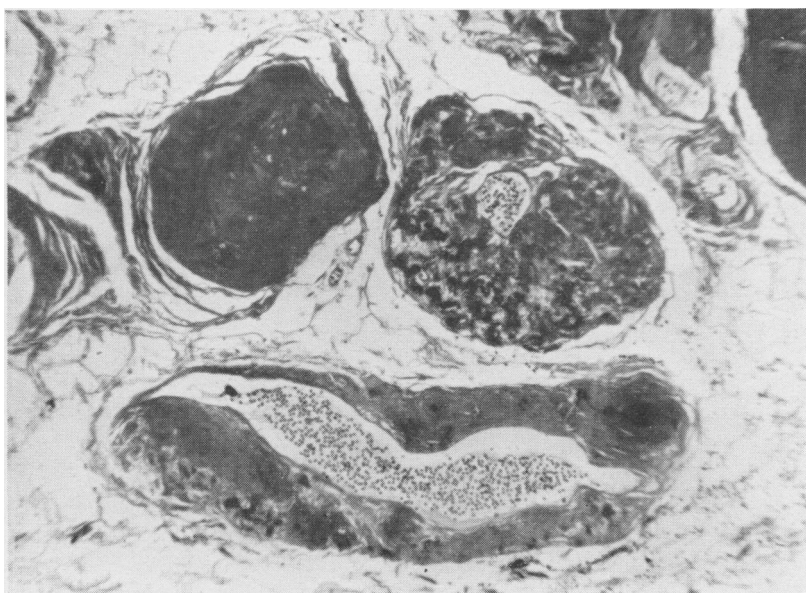


FIG. 4.—Hyaline material deposited in vessel walls, transforming them into broad hyaline rings which, partially or completely, obliterate the lumina. Masson stain  $\times 118$ .

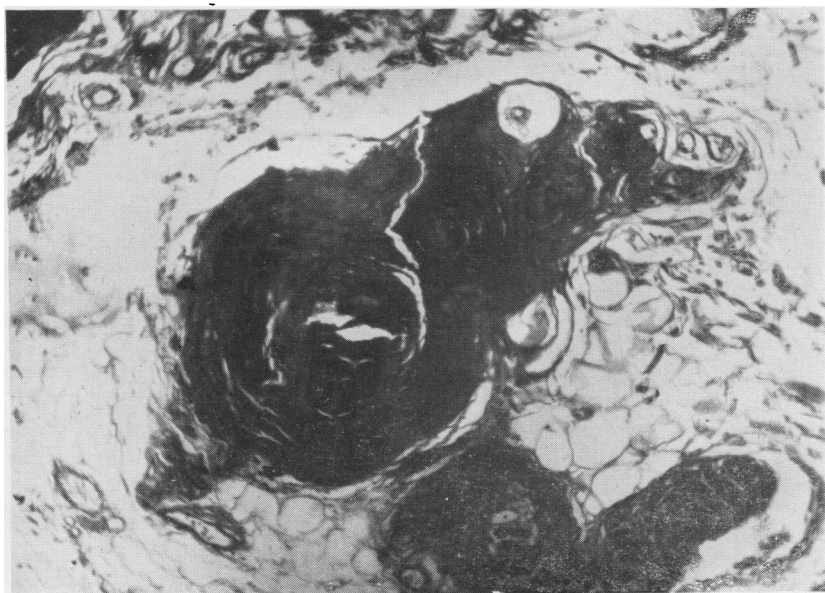

FIG. 5.—Lamination in a hyaline mass. Masson stain  $\times 125$ .

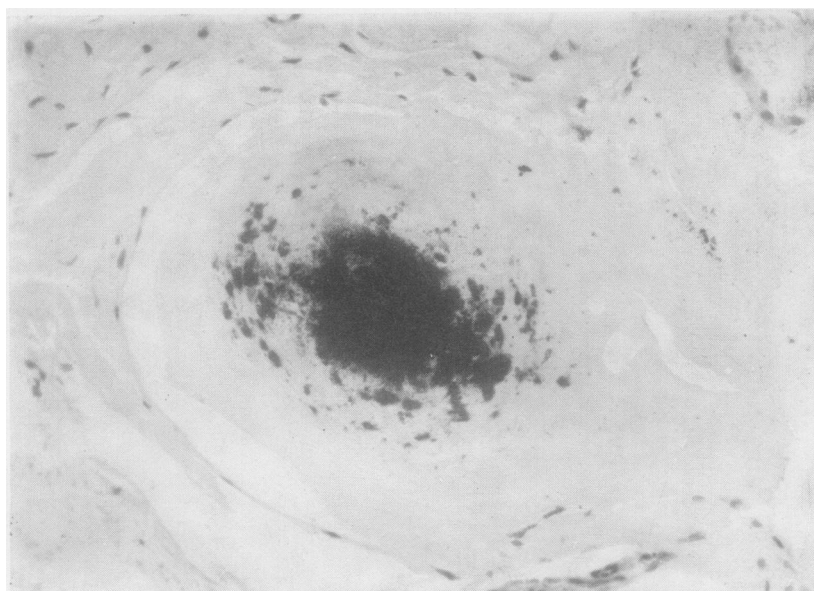


FIG. 6.—Central calcification in a hyaline mass. Haematoxylin and eosin  $\times 200$ .

*Chemical Analysis.*—Under the stereoscopic microscope nodules of hyalin were dissected from the tumour tissue, and Mr. A. M. Woodin of the Ophthalmological Research Unit, Institute of Ophthalmology, kindly carried out an analysis. Although there was insufficient material for a complete analysis or duplication of the experiments, his report is recorded here in the hope that the procedure may be of value in the chemical investigation of similar pathological material.

#### CHEMISTRY OF HYALINE MATERIAL

The material was provided as a suspension in alcohol. After being dried *in vacuo* at room temperature it weighed 4.5 mg. It was suspended in distilled water and dialysed for 48 hours against N/1000 HCl at 0°C. and then for a further 48 hours against distilled water. This dialysis would remove any non-colloidal material and would convert a Na salt of an acid polysaccharide to the free acid. The contents of the dialysis sac were centrifuged and the supernatant freeze-dried in a weighed tube. The water soluble fraction weighed less than 0.4 mg. and so was combined with the water insoluble fraction and hydrolysed in 1 ml. N HCl for 6 hours at 100°C. Only part of the hyalin was hydrolysed by this procedure and the insoluble fraction was removed by centrifugation and washed till free from chloride. The supernatant and washings were combined and repeatedly evaporated to dryness *in vacuo* over solid NaOH to remove the free HCl. The material remaining insoluble after the treatment with N HCl was heated in a boiling water bath for 10 hours with 1 ml. 5 N H<sub>2</sub>SO<sub>4</sub>. After cooling the hydrolysate was brought to pH 4.5 with Ba(OH)<sub>2</sub> and the BaSO<sub>4</sub> centrifuged off. The sulphate-free supernatant and washings were evaporated to dryness *in vacuo*.

The hydrolysate from the HCl treatment weighed 4.7 mg., and that from the  $H_2SO_4$  treatment 1.7 mg. (The combined weights are greater than that of the original material since in the hydrolysate amino acids are present as the hydrochlorides or sulphates.)

The hydrolysates were tested as follows:

(1) *For Ester Sulphate*.—0.01 ml.  $BaCl_2$  (0.5 M) were placed on a microscope slide and 0.02 ml. of the original HCl hydrolysate (1 ml.) added and the combined solution examined for a deposit of  $BaSO_4$ . No precipitate was produced, while 0.01 ml. N/500  $H_2SO_4$  treated under identical conditions gave a definite precipitate. The hyaline material hence contained less than 50% ester sulphate.

(2) *For Reducing Sugars*.

(a) The solid remaining after repeated evaporation of the HCl hydrolysate was dissolved in 0.02 ml.  $H_2O$  and half of this put on each of two filter-paper strips and run as a partition chromatogram in the conventional manner (Partridge, 1948). Collidene was used to develop the chromatogram. Glucosamine and glucurone were included as reference sugars. After removal of the solvent, one paper was treated with silver nitrate and NaOH, and the other paper with the Elson and Morgan reagents, specific for hexosamines. The hydrolysate from the hyalin showed no reducing sugars, nor did it react with the Elson and Morgan reagents, but there was considerable interference from the chloride ion. From the percentage of the original hyalin in the hydrolysate and the observed sensitivity of the spraying reagents it is possible to state that the original material had less than 3 per cent. of any one reducing sugar or of a hexosamine.

(b) The hydrolysate from the 5N  $H_2SO_4$  treatment was dissolved in 0.02 ml. water and the entire material put as a small spot on paper and run in collidene. The developed chromatogram was treated with  $AgNO_3$  and NaOH. There was no reducing substance in the hyaline hydrolysate.

**CONCLUSIONS.**—In assessing the results from the paper chromatography it must be remembered that although there were no substances apparently present with the properties of monosaccharides a considerable quantity of material was originally present in the spot. It is not known to what extent such an amount of amino acids would interfere with the spraying reagents. With larger amounts of hyalin some of these interfering materials could be removed with ion exchange resins. Again it was necessary to make rather *a priori* assumptions about the conditions of hydrolysis necessary to liberate the constituents of the hyaline material. The treatment with N HCl is sufficient to liberate the ester sulphate present in chondroitin sulphate (Meyer and Rapport, 1950), and has been found to liberate some, but not all, of the hexosamine in the mucopolysaccharide from cornea. With these reservations it can be concluded that if the hyaline material contained a polysaccharide component, there was less than 10 per cent. of it in the dry weight. Such a conclusion is in keeping with the staining reactions described.

## DISCUSSION

Hyaline infiltration of the conjunctiva and lid is of considerable rarity except in Russia where the condition has been fully investigated by Raehlman (1881, 1882), Kubli (1881), and Vossius (1889). It may occur either as an incident in other disease processes or it may present as an entirely separate and completely localized disease and these two types of presentation are seen also with amyloidosis where it is customary to speak of a generalized secondary type and a localized primary type.

As an incident in other disease processes, hyaline infiltration has been noted in association with long-standing cases of spring catarrh, old trachoma, and syphilis, and it is seen also in pinguecula, and pterygium, and as a senile change. Dimmer (1903) reported advanced changes in a case of old trachoma: the infiltration was associated with both calcification and ossification, and, as in our case, amyloid reactions were negative. He believed that the whole picture resulted from exudation following an acute inflammation super-imposed upon old trachoma, and that the hyalin originated both intra-cellularly from degenerating lymphocytes, and extra-cellularly from the blood stream. Steiner (1904), who worked in the Malay peninsula, placed on record a case of amyloid degeneration of the conjunctiva and tarsus in both of the upper lids in a case of severe trachoma. The thickened tissue corresponded to the tarsus; masses of it were removed and it was found that the normal structure had been replaced by amyloid material. Elliot (1920) has stated that

in Eastern practice, one meets from time to time with patients suffering from a very unusual lid condition . . . the whole lid becomes slowly increased in size, until it is many times as thick as it normally should be. The upper lid is affected most frequently and most severely, but both may suffer. There is evidence of past, long-standing chronic inflammation of the conjunctiva.

The pathology of these cases was found to vary between "fibrous, myxomatous, and amyloid degeneration". Hyaline infiltration of the lid is less common and is usually secondary to or associated with hyalinization of the conjunctiva. In our case, however, as also in the case reported by Rogman (1898) which was similar in other respects, the conjunctiva appeared normal. Rogman's patient was 55 years old, and had suffered with ptosis of the left upper lid since the age of 16; there was no pain or irritation and he complained only of obstruction of vision. On examination there was a mass in the upper lid, which on histological examination revealed blocks of hyalin beneath a normal conjunctival epithelium. Staining for amyloid was completely negative and in view of the extreme chronicity of this case Rogman considered his findings as evidence against the hypothesis that amyloid develops from hyalin.

The histological findings in our case are very similar to those found in primary amyloidosis seen in the tongue, alimentary tract, heart, and pericardium, in which the characteristic features are the absence of preceding disease, no involvement of organs or tissues usually affected in the secondary form, involvement of mesodermal tissue, *variation in staining reactions, and a tendency to nodular deposits*. These criteria were listed by Reimann and others (1935), and our case resembles that reported by them in all its histological features, except that we found no evidence of connective-tissue change. Nevertheless the hyaline substance is probably formed

locally from some unknown metabolic perversion, and is gradually deposited within the vessel wall and throughout the adjacent tissue. It is thought that the hyaline and amyloid masses are both due to changes occurring in inert protein exudates or secretions, and should not be regarded as completely different entities.

In conclusion, therefore, it may be said that hyaline infiltration of the lid and conjunctiva is a rare condition which may be confined to the conjunctiva, or extend into or arise primarily in the lid. It may be a localized disease or part of a generalized infiltration; it may exist alone or be associated with a chronic infective, inflammatory, or degenerative process. The staining properties of the deposits may be positive, variable, or negative for amyloid.

#### SUMMARY

The clinical and pathological findings in a case of hyaline infiltration of the eyelid, of seven years' duration, in a male aged 22 years are described. Similar cases in the literature are compared and discussed.

A multiplicity of names has been given to this condition, and it is pointed out that until the exact chemical nature of the deposits is known such a nomenclature can only lead to confusion. In the present state of our knowledge it is suggested that the term "hyaline infiltration of the lid and conjunctiva" (in which amyloid is considered as a particular variety of the condition) is the most suitable name for this group of diseases.

Our thanks are due to Dr. Peter Hansell for the photomicrographs and to Mr. A. M. Woodin for the chemical analysis.

#### REFERENCES

- DIMMER, F. (1903). *Z. Augenheilk.*, **9**, 474.  
 DUKE-ELDER, S. (1938). "Textbook of Ophthalmology", vol. 2, p. 1440. Kimpton, London.  
 ELLIOT, R. H. (1920). "Tropical Ophthalmology", p. 346. Oxford University Press, London.  
 HERBERT, H. (1902). *Trans. ophthal. Soc., U.K.*, **22**, 261.  
 KLEBS. Quoted by Leupold.  
 KUBLI, T. (1881). *Arch. Augenheilk.*, **10**, 430.  
 LEUPOLD, E. (1918). *Beitr. path. Anat.*, **64**, 347.  
 MEYER, K., and RAPPORT, M. M. (1950). *Arch. Biochem.*, **27**, 287.  
 PARTRIDGE, S. M. (1948). *Biochem. J.*, **42**, 238.  
 RAEHLMANN, E. (1881). *Arch. Augenheilk.*, **10**, 129.  
 ——— (1882). *Ibid.*, **11**, 402.  
 RECKLINGHAUSEN, F. v. (1883). "Handbuch der allgemeinen Pathologie des Kreislaufs". In *Deutsche Chirurgie*, Stuttgart.  
 REIMANN, H. A., KOUCKY, R. F., and EKLUND, C. M. (1935). *Amer. J. Path.*, **11**, 977.  
 ROGMAN, A. (1898). *Ann. Oculist., Paris*, **120**, 89.  
 SCHMIEDEBERG, O. (1920). *Arch. exp. Path. Pharmac.*, **87**, 47.  
 SCHMIDT, M. B. (1904). Quoted by Leupold (1918). *Beitr. path. anat.*, **64**, 347.  
 STEINER, L. (1904). *Zbl. prakt. Augenheilk.*, **28**, 33.  
 UNNA. "Histopathology of the Skin", p. 988. Cited by Herbert.  
 VOSSIUS, A. (1889). *Beitr. path. Anat.*, **4**, 337; **5**, 293.  
 WRIGHT, G. PAYLING (1950). "An Introduction to Pathology", p. 201. Longmans, London.