

## CLINICAL EXPERIENCE IN THE INTRA-OCULAR USE OF ACETYLCHOLINE\*†

BY

G. V. CATFORD AND E. MILLIS

*St. George's Hospital, London*

ACETYLCHOLINE is not a new substance, having been first synthesized by Baeyer (1867). Dale (1914) showed its pharmacological importance and Loewi (1921a, b; 1924a, b, c) and Loewi and Navratil (1924a, b) demonstrated its role as the chemical mediator of the nerve impulse.

One of the first references to the use of acetylcholine in ophthalmic surgery was that of Amsler and Verrey (1949), who stated that a rapid and intense miosis was produced after its injection into the anterior chamber. Barraquer (1964) concluded that a 1 : 100 dilution was the most effective and reliable. Harley and Mishler (1964) stated that the miosis was effective but must be augmented by a longer-acting miotic, dilutions of 1 : 200 and 1 : 100 being the most effective.

Our own experience indicates that the advances in intra-ocular surgery have made operative techniques more numerous and complicated; it has been found that in anterior segment surgery greater control of the pupil size can best be achieved by using the naturally occurring miotic acetylcholine.

It has been the custom in cataract surgery to instill pilocarpine (2 per cent.) as the last zonular attachments were broken or where the anterior vitreous face was seen to be bulging after the use of alpha-chymotrypsin. The miotic produced a small pupil and disaster was often averted. However, in the course of post-operative management, eyes treated in this way tended to develop irritation and iritis, which settled down in 1 to 2 weeks but did prolong convalescence. This adverse effect might be attributed to the preservative or to the pilocarpine itself. As acetylcholine has been shown to be superior to other miotics in anterior segment surgery, it was decided to investigate whether it also showed a tendency to produce an irritable eye or iritis post-operatively. A series of intracapsular extractions was therefore carried out using acetylcholine, and the present paper outlines the results of this clinical experience.

### Medication

Miochol, the preparation used, is a sterile, stable lyophilized acetylcholine chloride in powder form which, in its two-chamber vial, allows the solution to be made up and drawn at the moment when it is required during the operation. The 1 : 100 solution of acetylcholine is in a sterile 5 per cent. mannitol solution.

---

\* Received for publication November 10, 1965.

† Address for reprints: 6 Devonshire Place, London, W.1.

The pre-operative treatment in this series was uniform throughout. The following local drops were used:

Gutt. phenylephrine 10 per cent.  
 Gutt. homatropine 2 per cent.  
 Gutt. cocaine 2 per cent. and 4 per cent.  
 Gutt. adrenaline 1 : 3000.

Six drops of each were given in all cases commencing one hour before operation. Local or general anaesthesia was used according to general indications.

*Local Anaesthesia.*—Pethidine and promethazine hydrochloride were given as a pre-medication and on one occasion chlorpromazine hydrochloride also. In these cases lignocaine 1 : 50 with adrenaline 1 : 80,000 were injected for the retrobulbar and facial blocks.

*General Anaesthesia.*—Gas and oxygen, with gallamine triethiodide or curare was administered, and no local injections were used.

### Surgical Method

The incision was made with a von Graefe knife or with a keratome and scissors and a direct buried suture was placed.

One peripheral iridectomy was made at 12 o'clock. Alpha-chymotrypsin, if used, was then injected behind the pupil and through the iridectomy. The enzyme was washed from the wound immediately, and after 2 minutes the remainder was irrigated from behind the

TABLE  
RESULTS OF NINE

Case No.	Sex	Age (yrs)	Side	Anaesthetic*	Section	Iridectomy	Alpha-Chymotrypsin Used
1	F	76	Right	LA	Graefe knife	1 peripheral	Yes
2	F	68	Left	GO	Keratome and Scissors	1 peripheral	Yes
3	F	82	Right	LA	Graefe knife	1 peripheral	Yes
4	F	82	Left	LA	Keratome and Scissors	1 peripheral	No
5	F	82	Left	LA	Graefe knife	1 peripheral	Yes
6	M	57	Left	GO	Keratome and Scissors	1 peripheral + sphincterotomy	Yes
7	F	79	Left	LA	Keratome and Scissors	1 peripheral	Yes
8	F	65	Left	GO	Graefe knife	1 peripheral	Yes
9	M	80	Right	GO	Graefe knife	1 peripheral	Yes

\*LA = Lignocaine and Adrenaline

GO = Gas and Oxygen

pupil. The lens was then extracted with forceps or erisophake, and the wound closed with the suture.

At the same time the acetylcholine solution was injected into the anterior chamber and the constriction of the pupil was observed while injecting. Reposition of the iris was rarely required unless the pupil was held, for example, by a blood clot. The section closure was completed and the pupil constriction maintained by drops of pilocarpine 4 per cent.

In the series of nine cases recorded in the Table, measurements of pupil size were taken in two meridia immediately after extraction of the lens, since there was often a change in size from the initial pupil diameter with the use of alpha-chymotrypsin. Further measurements were taken from the time of acetylcholine injection until maximal constriction of the pupil appeared to have been obtained.

It may be noted that the larger the initial pupil diameter, the better the response and effect of the miotic.

### Results

The results in this series are shown in the Table. Case 6 requires special attention.

This patient had inverse glaucoma as the result of a dislocated lens and vitreous in the anterior chamber. He also had post-gastrectomy anaemia which required treatment before operation.

Pre-operative acetazolamide and intravenous urea were given.

During the operation, after the injection of alpha-chymotrypsin, the lens slid back into the

#### INTRACAPSULAR EXTRACTIONS

Pupil Diameter (mm.)		Average Miosis Obtained (mm.)	Time for Maximum Constriction (sec.)	Remarks
Before	After			
6.5 × 6.5	5 × 5	1.5	70	Slight post-operative inflammation from the 4th day which rapidly settled
5 × 3	4 × 2	1	110	Suffused eye on the 4th post-operative day only
8.5 × 8.5	5 × 3.5	4	75	Blood clot in anterior chamber held up pupil, but constriction soon achieved with a good response No post-operative inflammatory reaction
5 × 7	3 × 4	3	45	Good response No post-operative reaction
4.5 × 4.5	2.5 × 2.5 2 × 2	2 2.5	50 255	Second eye of Case 3
4 × 4	3 × 3	1	60	See text
4 × 4.5	2.5 × 3.5	1.5	25	The patient was restless post-operatively and developed hyphaema and choroidal detachment Both conditions settled without complications
6 × 4	5 × 3.5	1	120	Satisfactory pupil constriction No reaction Figs 1 and 2
8 × 8	6 × 4 4 × 2	(2-4) 3 (4-6) 5	25 45	Satisfactory pupil constriction No reaction

vitreous. A sphincterotomy was made from the peripheral iridectomy at 12 o'clock and the lens was extracted with a vectis and forceps without vitreous loss. The pupil constricted more than the measured amount.

Convalescence was complicated by atropine sensitivity and iris prolapse. The iris was abscised, and the eye settled satisfactorily.

When these results were reviewed, it was found that the average pupil size after removal of the lens, but before miotic injection, was 5.6 mm. After injection the pupil constricted to 3.5 mm., an average change in pupil size of 2.2 mm. This effect was achieved in an average of 76.6 seconds (range 25 seconds to 255). A typical successful example (Case 8) is shown in Figs 1 and 2.

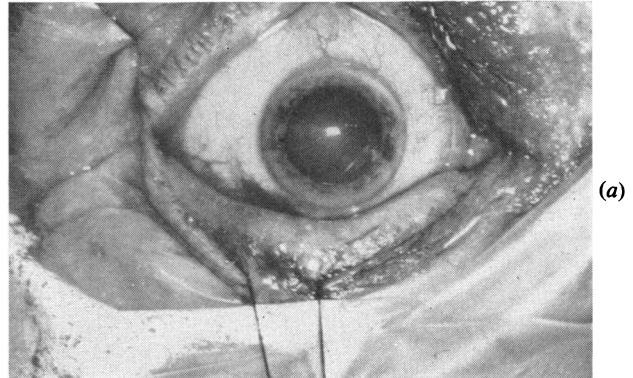


FIG. 1—(a). 8 mm. pupil dilatation before operation. (b). Pupil after lens extraction and before injection of miotic.

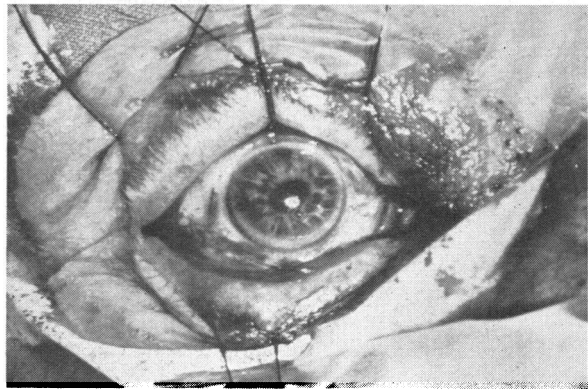
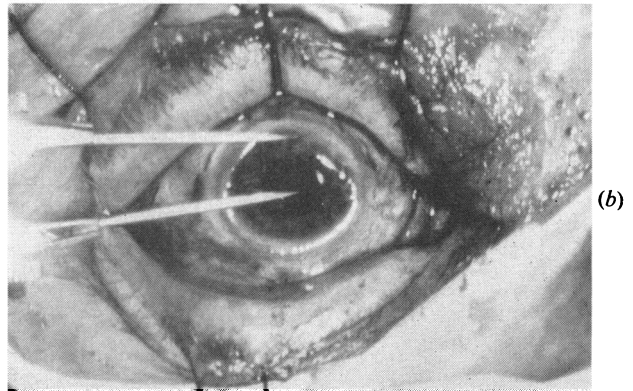


FIG. 2.—Constricted pupil after injection of miotic.

It should be noted that acetylcholine applied locally to the eye does not act as a miotic unless employed in strong concentrations (1 : 20) with massage.

### Discussion

Acetylcholine thus appears to be a suitable miotic for use in anterior segment surgery. It has advantages over pilocarpine in that it appears not to cause an irritable eye or iritis, but at the present time there is no clear indication whether it is the preservative or the pilocarpine itself which causes such irritation. Pilocarpine acts by direct action on the cells innervated by post-ganglionic cholinergic fibres and it would seem logical to use the naturally-occurring chemical transmitter rather than to substitute a substance foreign to the anterior chamber.

The acetylcholine injected is of course completely destroyed by the cholinesterases present in the eye, as is the intrinsically released acetylcholine. What happens to the pilocarpine and the breakdown products if any is open to speculation.

Another advantage is that acetylcholine usually produces a round pupil miosis not always associated with the use of pilocarpine.

### Summary

Acetylcholine for injection (Miochol) has been used in a small series of cases and found to cause little or no reaction either immediate or delayed.

The solution is made up during the operation from a double-compartment single vial.

If, after removal of the cataractous lens, the section is closed and acetylcholine is injected into the anterior chamber, marked constriction of the pupil can be noted while injecting and keeping the anterior chamber under observation. The pupil constriction is regular so that a round pupil is achieved at the end of the operation. No adverse effects have been noted to date.

Acknowledgment is made to the Nursing and Photographic Staffs of St. George's Hospital. The acetylcholine was supplied by Smith Miller & Patch Ltd.

### REFERENCES

- AMSLER, M., and VERREY, F. (1949). *Ann. Oculist. (Paris)*, **182**, 936.  
 BARRAQUER, J. I. (1964). *Amer. J. Ophthalm.*, **57**, 406.  
 BAEYER, A. (1867). *Ann. Chem. Pharm. (Lpz.)*, **142**, 322 (quoted by Goodman and Gilman, 1955, p. 442).  
 DALE, H. H. (1914). *J. Pharmacol. exp. Ther.*, **6**, 147.  
 GOODMAN, L. S., and GILMAN, A. (1955). "The Pharmacological Basis of Therapeutics", 2nd ed. Macmillan, New York.  
 HARLEY, R. D., and MISHLER, J. E. (1964). *Amer. J. Ophthalm.*, **57**, 817.  
 LOEWI, O. (1921a). *Pflügers Arch. ges. Physiol.*, **189**, 239.  
 ——— (1921b). *Ibid.*, **193**, 201.  
 ——— (1924a). *Ibid.*, **203**, 408.  
 ——— (1924b). *Ibid.*, **204**, 361.  
 ——— (1924c). *Ibid.*, **204**, 629.  
 ——— and NAVRATIL, E. (1924a). *Ibid.*, **206**, 123.  
 ——— (1924b). *Ibid.*, **206**, 135.