

# Optic atrophy following eyelid injury

J. LEVY AND R. K. CHATFIELD

*Glasgow Eye Infirmary*

Injury to the optic nerve leading to optic atrophy may be direct or indirect. Direct injury may result from laceration of the nerve fibres by a missile or sharp instrument penetrating the orbit, by a displaced fragment of bone in fracture of the optic canal, or by avulsion of the nerve at the globe. Indirect injury is well recognized in contusion injuries of the head, especially the brow, and is generally attributed to tearing of sub-arachnoid bloodvessels through movement of the nerve within its sheath, where this is attached to the bony optic canal (Traquair, 1929, 1945). An extensive personal series and the relevant literature were reviewed by Brodie Hughes (1962).

Although damage to the optic nerve as a result of lid injury, particularly by a sharp and pointed instrument, is also well known, large series of lid injuries, together with eye injuries in children, have been documented without including any such cases (Werner, 1952; Kobor, 1965). When it does occur, it is generally accepted as being due to direct laceration of the nerve (Duke-Elder, 1954; Walsh, 1957).

Four cases of optic atrophy with complete unilateral blindness following wounds of the lower eyelids are presented. Although the immediate clinical picture is very different from forehead contusion, the optic atrophy follows a similar course. We suggest that the injury to the nerve may be similarly indirect, through tearing of blood vessels by its displacement in the bony canal, rather than through direct laceration.

## Case reports

**Case 1, a boy born in February, 1955**, fell onto a toy "tin" sword, cutting his right lower eyelid, in July, 1961, when he was 6 years old. He had had no previous eye trouble. He was taken to Glasgow Eye Infirmary that evening and admitted by the house surgeon who noted that the right cornea was intact, the media clear, and the fundus normal. No note was made of the pupil reactions. The site of the lid laceration is shown in Fig. 1 (overleaf). The wound was sutured the following morning under general anaesthesia. It healed well and he was discharged home after 6 days on July 17.

Shortly after he returned home, his mother noticed the right eye turning out. Ophthalmoscopic examination with a mydriatic on July 25 again showed a normal fundus and the eye movements were full. The orthoptist found that the visual acuity in the right eye was hand movements, and in the left 6/5 with numbers. At no time did the child complain that he could not see with one eye. On August 22 it was first noted that the pupil reactions indicated amaurosis of the right eye and that the right disc was pale and atrophic. The left eye was normal. X rays of the skull and right orbit on that day showed no abnormality.

He attended thereafter as an out-patient until October 12, 1962, with no apparent change apart from increasing whiteness of the right disc. We re-examined him on December 22, 1967, and found no change in the right divergent squint or pupil reactions. The scar on the right lower eyelid was barely visible. It followed the lower orbital margin fairly closely. The right disc was paper white and flat but not cupped. There was no perception of light. The fundus was otherwise normal, including the retinal vessels.

The left fundus was normal and the left visual field was full to 3/1000 white, with normal blind spot. The visual acuity was 6/5 with  $-0.25$  D sph.

**Case 2, a boy born in April, 1957**, first attended the out-patient department at Glasgow Eye Infirmary on September 25, 1962, when he was 5 years old. He had fallen onto a pencil, cutting his right cheek, 2 weeks previously, and his mother sought advice because the right eye had been turning out since the injury. There was a recent, healed scar below the right orbital margin (Fig. 2). The right eye was divergent and hypertropic with slight weakness of adduction. The pupil reaction indicated right amaurosis. There was no perception of light. The visual acuity in the left eye was 6/6 with the "E" test.

The right disc was pale but the fundi were otherwise normal. Clinical photographs and radiological examination of the right orbit were arranged but not carried out until January 22, 1967. The X rays showed no abnormality. The right optic nervehead showed increasing pallor.

We re-examined him on September 15, 1967, when we found a variable right divergent squint with amaurotic pupil reactions. The fundi, except for the right optic disc, were normal. The left visual field was full to 5/1000 white. The right eye was quite blind, but the visual acuity in the left eye was 6/5 unaided.

**Case 3, a girl born in December, 1962**, was found by her mother on August 8, 1967, in a dazed state in the garden with a small wound and swelling of the left lower lid. The history could not be obtained with certainty because of the child's age and upset state, but it is thought probable that she fell onto the spoke of an umbrella with which she was playing. Her mother took her to a local hospital where she was X rayed and allowed home, and later to another hospital because of vomiting and a dilated left pupil. She was transferred to the regional neurosurgical unit on August 11, when she was found to be alert and co-operative. She had a raised temperature on admission, but it was normal thereafter. There was a small healing wound under the left eye with slight peri-orbital swelling; the pupil reactions indicated left amaurosis and it was thought that the left eye had no perception of light. The left fundus was normal. No other abnormality was found. She was given tetanus toxoid and systemic antibiotics and discharged after 2 weeks. She was referred to the Glasgow Eye Infirmary for follow-up and was seen there on September 8, 1967. There was a small angle of left convergent squint, which her mother said had not been present before the accident, full eye movements, and a moderately pale left optic disc. The fundi were otherwise normal. The site of the lid injury is shown in Fig. 3. On December 1, 1967, the left eye was quite blind but the visual acuity in the right eye was 6/9 unaided with "E" test.

**Case 4, a young man born in August, 1950**, slipped at work while lifting a heavy carboy on November 21, 1967, and fell onto a projecting part of the wire cage, striking his left lower lid. He had had no previous eye trouble. He attended the Glasgow Eye Infirmary about one hour later and was found to have a laceration of the left lower eyelid (Fig. 4). Abduction of the left eye was absent. The pupil reactions indicated amaurosis of the left eye. The left fundus was normal. There was no perception of light. The visual acuity in the right eye was 6/5 unaided.

In the operating theatre that evening, with local anaesthesia, the wound was probed and explored. It appeared to be 5 mm. in depth at the most. It was cleaned and sutured and healed well. X rays of the skull and left orbit on admission showed no abnormality. Forced duction of the left eye on November 29, 1967, with local anaesthesia, showed full passive movements. He was discharged home on December 2. At his first out-patient visit on December 12, the left optic disc was paler than the right. The visual acuity was unchanged and there was still no abduction of the left eye. The right visual field showed no defect. By December 19 abduction of the left eye had partly recovered. The left optic disc was definitely atrophic but the fundi were otherwise normal.

Fluorescein retinal angiography carried out on November 30 had shown no abnormality of the central retinal vessels nor of the blood supply to the optic nervehead.

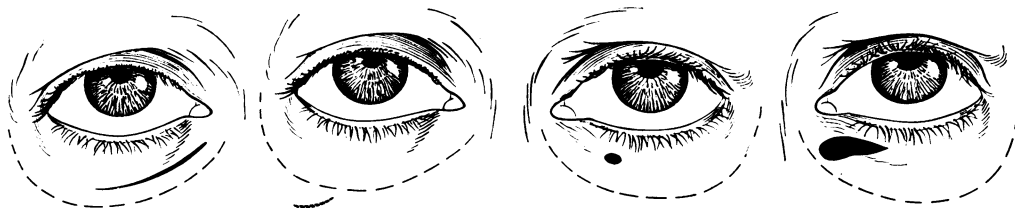


FIG. 1 Laceration of right lower lid (Case 1)

FIG. 2 Scar below right orbital margin (Case 2)

FIG. 3 Site of injury to left lower lid (Case 3)

FIG. 4 Laceration of left lower lid (Case 4)

## Discussion

These four cases were observed over a 7-year period at Glasgow Eye Infirmary, in one unit which sees approximately 2,100 new cases per year. All occurred in young people, three under the age of 7 years. They were all the result of a fall onto a semi-sharp object, *i.e.* the body weight contributed to the force of the injury. In this, they resemble the optic atrophy following head injury which, in civilian accidents, is most often due to a fall, particularly from a bicycle, when these were more popular (Traquair, 1929). The immediate clinical picture is quite different. Young children do not complain of unilateral blindness, and the typical presentation is as a lower lid injury, not apparently very severe, but followed in about 2 weeks by squint. Until the optic nervehead becomes pale, the only objective sign is the amaurotic pupil reaction, and therefore we must emphasize the importance of examining the pupil reflexes in children with lid injuries.

The mechanism of damage to the optic nerve in these cases will probably remain hypothetical as surgical or pathological evidence is unlikely. As the retinal vessels are normal and the visual field of the other eye in the three children old enough for testing shows no defect, the optic nerve must be damaged between the entry of the retinal vessels and the chiasmal knee. The most obvious explanation would appear to be that the sharp object, after piercing the lid, has passed below the lower fornix into the deeper orbital tissues, directly severing the optic nerve. We feel, however, that it is more likely that the injury to the optic nerve is indirect, with tearing of the inter-vaginal blood vessels in the region of the optic canal as in forehead contusions. Falling onto a sharp object, probably halted by impinging on part of the orbital wall or margin, would produce a similar sudden deceleration of the cranium, while the brain, optic nerve, and eye continue to move forward, causing displacement between the optic nerve and the dural sheath where it is attached to bone, *i.e.* in the optic canal. The shallow orbit in the child may enhance this effect. Bony damage in the canal, long a question of discussion in head injuries, seems very unlikely in this type of case. Radiological studies were uniformly negative, although not sufficiently detailed to exclude fracture indubitably.

The pallor of the optic nervehead appeared 2 to 3 weeks after injury as in forehead contusion. In all cases, loss of perception of light was complete and there was no recovery. If it is due to direct laceration of the nerve, this would indicate its complete section, which seems unlikely with the comparatively blunt objects causing the injuries. One would expect the rounded optic nerve, in liquid orbital fat, to roll aside from such trauma. Whatever the mode of injury to the nerve, it is certain that it is not amenable to treatment, and surgical exploration is not justified. In view of the diversity of the causative factors, prophyllaxis also appears impractical.

### Summary

Four cases of lower lid injury followed by optic atrophy are presented. All occurred in young persons, three under the age of 7 years. All resulted in complete unilateral blindness. It is pointed out that, in young children, damage to the optic nerve may easily be missed initially, if the pupil reactions are not elicited. It is suggested that the damage to the optic nerve may be indirect by tearing of the inter-vaginal blood vessels in the region of the optic canal, rather than by direct laceration of the nerve.

We wish to thank our colleagues at Glasgow Eye Infirmary and the regional Neurosurgical Unit, Killearn, for their co-operation and assistance, and Prof. W. S. Foulds for the facilities for fluorescein studies at the Tennent Institute of Ophthalmology, Glasgow.

### References

- DUKE-ELDER, S. (1954) "Text-book of Ophthalmology", vol. 6, p. 6117. Kimpton, London
- HUGHES, BRODIE (1962) *Bull. Johns Hopk. Hosp.*, **111**, 98
- KOBOR, J. (1965) *Klin. Mbl. Augenheilk.*, **146**, 740
- TRAQUAIR, H. M. (1929) *Trans. ophthal. Soc. U.K.*, **49**, 348
- (1945) *Ibid.*, **65**, 63
- WALSH, F. B. (1957) "Clinical Neuro-Ophthalmology", 2nd ed., p. 1089. Williams and Wilkins, Baltimore
- WERNER, S. (1952) *Acta ophthal. (Kbh.)*, **307**, 97